

True Digital Artery Aneurysm - A Clinical Vignette

Chirra Likhitha Reddy*

1. Department of Burns & Plastic Surgery,
All India Institute of Medical Sciences
(AIIMS), Mangalagiri, India

ABSTRACT

Swellings of the hand are commonly seen in routine clinical practice. Ninety five percent of them are benign and most common diagnoses include ganglions, epidermoid inclusion cysts, and giant cell tumours of the tendon sheath. It is very uncommon to find true digital aneurysms in the hand. In this clinical vignette I present a case of true digital artery aneurysm, with the tell tale clinical features and the photographs which help to identify such cases in a 22 yr married female from India.

Please cite this paper as:

Likhitha Reddy C. True Digital Artery Aneurysm - A Clinical Vignette. World J Plast Surg. 2023;12(1):72-74.
doi: 10.52547/wjps.12.1.72

CASE PRESENTATION

A 22 yr married female who is a homemaker, presented with swelling over the right little finger of 2 years duration with pain for 2 months, hindering her daily activities.

Examination revealed a compressible, pulsatile swelling along the entire length of the finger on the radial side with tenderness (Figure 1).

Finger Allen test was positive with occlusion of radial digital artery at the base of the finger. Digital artery aneurysm was suspected and MRI with contrast was done.

MRI showed fusiform aneurysm of the radial digital artery of the right little finger of size 3.7cms x 0.7 cm x 0.5cms extending from the proximal interphalangeal joint to the tip of the finger sparing the common digital artery.

The patient was managed with excision of the aneurysmal segment, via a mid-lateral incision after, confirming the vascularity of the finger through ulnar digital vessel, by clamping the radial digital vessel proximal to the aneurysmal segment (Figure 2). Post operatively, crepe bandage was applied to reduce edema and suture removal was done by day 10. Scar massage and physiotherapy done to prevent contracture. At Present patient has resumed normal daily activities

True aneurysm of the digital artery is rare and very few case reports have been described in literature¹. The etiology of these aneurysms is repetitive micro trauma (commonly)², congenital³ secondary to inflammation or atherosclerosis⁴, or idiopathic¹. These aneurysms are usually painless, but long standing aneurysms may have thrombus⁵ formation leading to pain. Treatment options include excision with or without the need for interposition vein/arterial graft to preserve blood flow depending on the formation of collaterals.

*Corresponding Author:

Chirra Likhitha Reddy

Dept of Burns & Plastic Surgery,
All India Institute of Medical
Sciences (AIIMS), Mangalagiri -
522503

Tel.: + 9591241574

Email: drlikhithareddy@gmail.com

Received: 24/12/2023

Accepted: 30/03/2023



This work is licensed under a Creative Commons Attribution-NonCommercial 4.0 International license (<https://creativecommons.org/licenses/by-nc/4.0/>). Non-commercial uses of the work are permitted, provided the original work is properly cited.

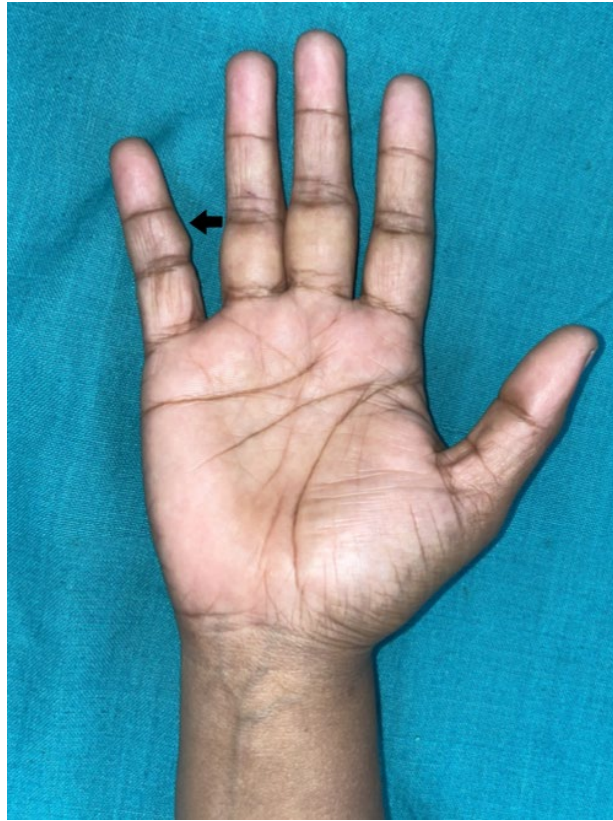


Figure 1: Photograph of the right hand showing the swelling over the radial aspect of the little finger (black arrow).

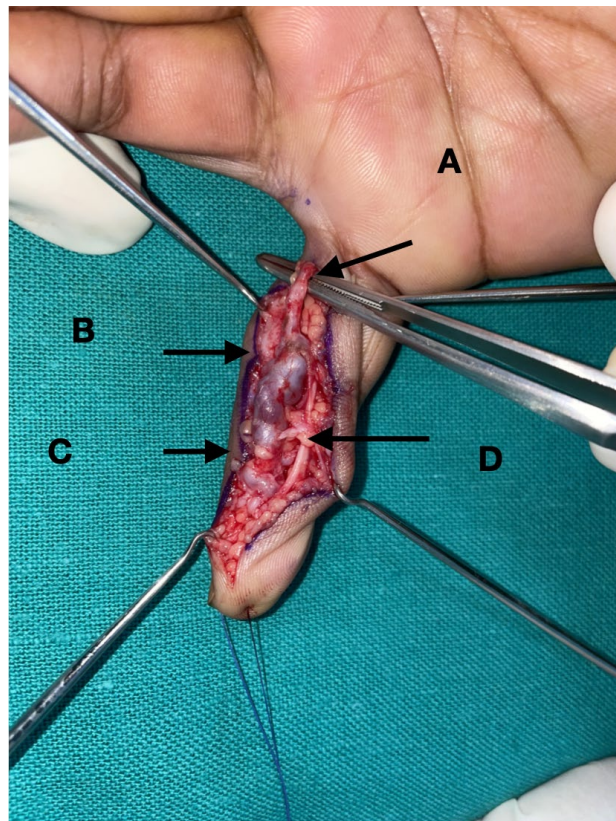


Figure 2: Photograph showing
 A) Normal segment of artery, B) Thrombosis within the artery, C) Tortuous fusiform aneurysm of the digital artery, D) Digital nerve accompanying the artery.

CONFLICT OF INTEREST

The authors declare that there is no conflict of interests.

REFERENCES

- 1) Sheikh Z, Selvakumar S, Goon P. True aneurysm of the digital artery: a case report and systematic literature review. *Journal of Surgical Case Reports* 2020 Feb;**2020**(2):rjz400.
- 2) Strauch B, Melone C, McClain SA, Lee BT. True aneurysms of the digital artery: case report. *The J Hand Surg Am* 2004 Jan 1;**29**(1):54-8.
- 3) Dean RA, Fleming SI, Zvavanjanja RC, Marques ES, Greives MR. Congenital aneurysm of the palmar digital artery: a case report and literature review. *Radiology Case Reports* 2019 Jan 1;**14**(1):83-7.
- 4) Berrettoni BA, Seitz Jr WH. Mycotic aneurysm in a digital artery: case report and literature review. *J Hand Surg Am* 1990 Mar 1;**15**(2):305-8.
- 5) Lee YH, Teo YS, Lim YW. True digital artery aneurysm of the ring finger: a case report. *J Orthop Surg* 2006 Dec;**14**(3):343-5.