

Medial Canthal Reconstruction - Scar Restricting Vision in Only Seeing Eye of a 75-year-old Female

Aayush Sharma^{1*}; Alexandros Georgolios²

1. Chicago Medical School, Rosalind Franklin University, North Chicago, IL 60064, USA
2. Poplar Bluff Regional Medical Center, Poplar Bluff, MO 63901, USA

ABSTRACT

Scarring is a common post-injury outcome that can precipitate functional impairment. We present the case of a 75-year-old female who presented with diminished upper eyelid excursion in her right (only seeing) eye due to scarring associated with a facial laceration. She had a history of right eye corneal transplantation and necessitated urgent excision of the scar to release upper eyelid motion. The scar was excised, and a full-thickness skin graft (FTSG) was used, harvested from the skin of the right supraclavicular neck. Post-operative recovery was excellent, and the patient was relieved of restriction of her right upper eyelid opening.

KEYWORDS

Medial canthus; Reconstruction; Full-thickness skin graft; Z-plasty

Please cite this paper as:

Sharma A., Georgolios, A. Medial Canthal Reconstruction - Scar Restricting Vision in Only Seeing Eye of a 75-year-old Female. *World J Plast Surg.* 2023;12(1):75-79.
doi: 10.52547/wjps.12.1.75

INTRODUCTION

The periorbital region is anatomically complex and houses numerous structures that are integral to proper functioning. Direct injury to this region may cause functional impairments ranging from motor impairment to damage to the lacrimal drainage system. Surgical interventions are beneficial in restoring functionality to this area; however, scarring is a common post-operative outcome that may also precipitate cosmetic concerns and functional impairment.

When scars pose cosmetic concerns for the patient, surgical revision might be considered to improve quality of life. A common method of scar revision is Z-plasty in which two equal flaps are raised and transposed along an equal axis¹. This is a safe and effective procedure for improving cosmetic and functional impairments of scars; however, this can be technically complicated around the periorbital region, although it has been performed^{2,3}. An alternative to Z-plasty for scar revision is full-thickness skin grafting (FTSG). This can be an effective means to replace the scar tissue and provide functional and cosmetic improvement in periorbital reconstructive surgeries⁴.

We present the case of a patient that suffered from restriction in opening upper eyelid in her only seeing, post-corneal transplant eye due to scarring of a forehead laceration that involved the right medial canthus.

*Corresponding Author:

Aayush Sharma

Medical Student – Chicago Medical School at Rosalind Franklin University

1205 University Circle, North Chicago, IL 60064, USA

Tel.: +1(302) 563-6270

Email: aayush.sharma@my.rfums.org

Received: 2022/12/4

Accepted: 2023/3/9



This work is licensed under a Creative Commons Attribution-NonCommercial 4.0 International license (<https://creativecommons.org/licenses/by-nc/4.0/>). Non-commercial uses of the work are permitted, provided the original work is properly cited.

CASE PRESENTATION

The patient was a 75-year-old female, who initially presented in the Emergency Room after sustaining a mechanical fall at home. She was on antiplatelet regimen (aspirin and clopidogrel) due to a history of nonobstructive coronary artery disease. Her other medical history included dyslipidemia, hypothyroidism and was status post corneal transplantation in the right eye, which was her only seeing eye per her report. The patient was taken to the operating room urgently due to bleeding profusely from a laceration extending from her right medial canthus to the skin of the glabella and a concomitant development of an extensive hematoma in her forehead. The hematoma was drained, and the laceration was repaired. She returned to our office three months later, concerned about her inability to keep her right eye open which was limiting severely her vision. On examination a thick scar band was noticed extending from the medial aspect of her upper eyelid to the glabellar skin, resulting in severe restriction of the palpebral fissure when compared to her immediate postoperative photographs (Figure 1). The patient requested an urgent revision due to her limited vision and we proceeded to the operating room for excision of the scar and release of the upper eyelid.

We proceeded to the operating room approximately three months after the initial procedure. The scar was marked and excised on its entirety (Figure 2). The residual surface was covered with a full thickness

skin graft which was harvested from the skin of the right supraclavicular fossa. The full thickness skin graft was harvested relatively redundant to the covering surface (10-20 percent larger) to anticipate for future contraction. A minor area in the medial canthus, was left to heal on secondary intention, to avoid creating retraction healing forces from the medial canthus to the upper eyelid. The patient healed uneventfully and had immediate postoperative improvement on her upper eyelid function. Redundancy of the skin graft was noticed in the three months postoperative follow up (Figure 3), but the patient was satisfied with the improved function and stated no cosmetic concerns.

The content of this manuscript is in accordance with the declaration of Helsinki for Ethics. No committee approval was required. Informed consent has been given by the patient for obtaining the clinical images and no breach of confidentiality applies in publication, as patient cannot be identified.

DISCUSSION

Scarring is a common post-injury and post-surgical outcome that may lead to functional impairments. Surgical scar revision is an effective intervention that can be used to provide cosmetic and functional improvement for patients; however, different revision techniques may be more appropriate for certain regions. The medial canthal region is anatomically complex, involving the medial canthal tendon, which is formed by the fusing of

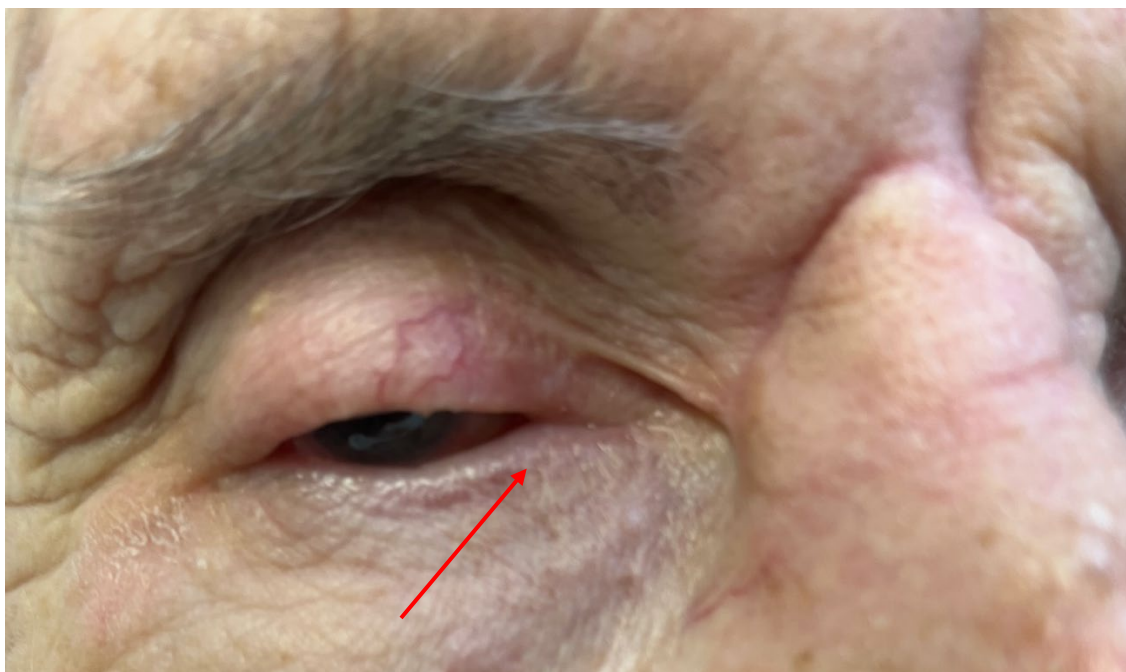


Figure 1: Forehead laceration scar involving the right medial canthus. Note the limited mobility of the upper eyelid.

two tendinous arms of the anterior and posterior lacrimal crests, as well as the lacrimal canaliculi⁵. Injury and scarring in this area may impact daily functioning as presented in this case. While Z-plasty is a common and effective technique used to repair scars, FTSG is an appropriate alternative for certain cases. This case demonstrated the utility of FTSG in improving restriction of the upper eyelid for the patient. A review of different surgical techniques for medial canthal reconstruction and the reasons for the choice of FTSG for revision will be described below.

Z-plasty is a common and useful technique for distributing tension forces along a different axis that leads to improvement of skin contractures and increased mobility of affected tissue. This involves creating two flaps that are transposed along an axis, often using an angle of 60 degrees, which results in a 75% gain in length and a 90-degree change in scar direction. There are some complications of Z-plasties that must be considered. One is the potential gain in scar length. Another complication is the trapdoor effect in which the scars tend to become depressed while the tissue circumscribed by them tend to bulge⁶. Within the field of periorbital reconstructive surgery, Z-plasty has been utilized for medial canthal reconstruction^{2,3}; however, it may have greater applications in epicanthal corrective

surgeries⁷.

Other flap techniques may also be used for medial canthal reconstruction⁸. Regional flaps may be used in which tissue is replaced with skin of a similar texture and color. This also provides the benefit of controlling tension vectors and preventing tension on the lid margin; however, it is advised that flaps be created superior to the defect since contractile forces during healing will result in an upward traction on the wound. Failure to create a superior flap may result in lower eyelid ectropion and retraction.

Regional flaps may be further broken down into different categories: Rhomboid flap⁹, Bilobed Rotational flap¹⁰, Paramedian Forehead Flap¹¹, and V to Y flap¹². Like the name suggests, a rhomboid flap uses a rhomboid shape for the transposition process. A bilobed rotational flap utilizes a similar technique in which a bilobed area of skin is transposed in a clockwise/counterclockwise manner, replacing the transected skin. A paramedian forehead flap utilizes a portion of the forehead skin to replace affected tissue. After healing, there is often some excess skin and adipose tissue in the repaired area; therefore, the healed area is often again surgically corrected to provide better cosmetic outcomes. A V to Y flap involves created a "V" shaped flap that is pulled away from the excision to cover another area; final suturing results in a "Y" shaped area, hence the

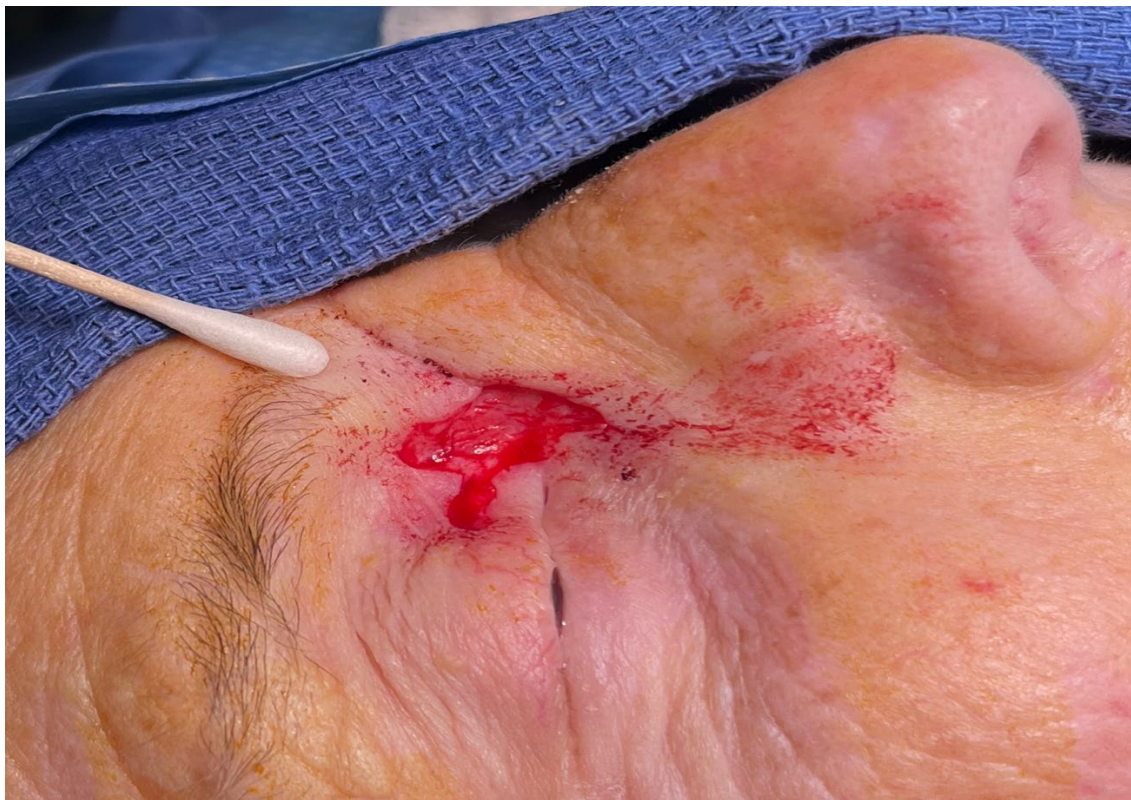

Figure 2: Intraoperative removal of scar tissue.

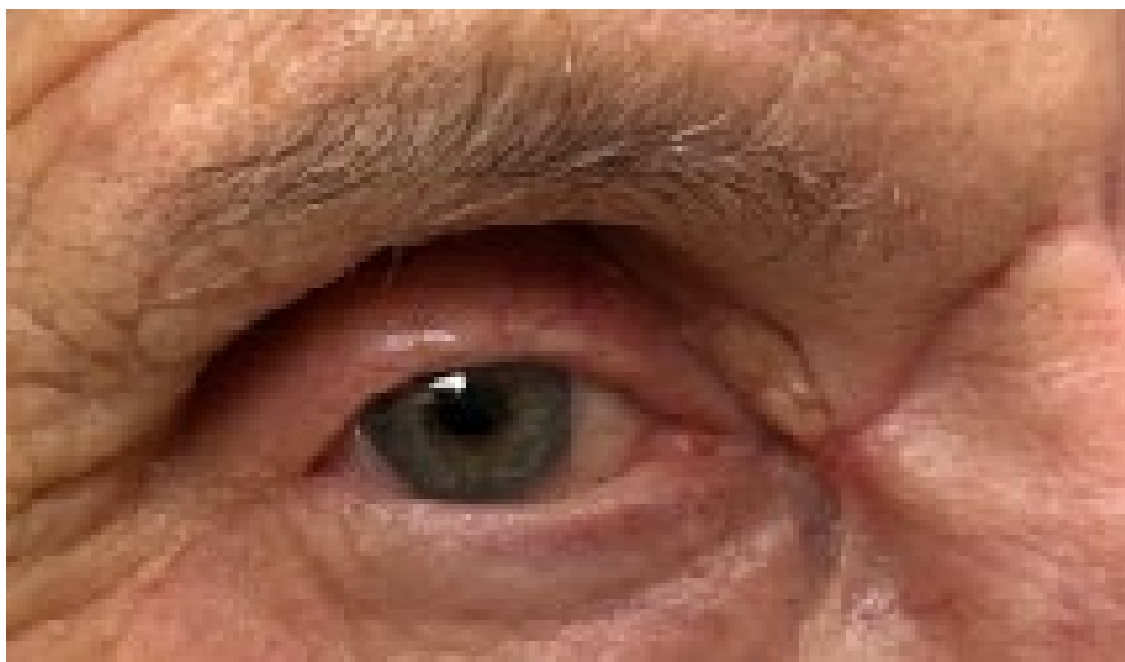

Figure 3: 3-month postoperative follow-up. Patient is able to sustain eye opening

name. While these are effective techniques in their own regards and have been used previously, they seemed less applicable given the patient described in the case. If a flap technique is used for medial canthus repair, it is recommended that it comes from an area of skin that matches in terms of texture, thickness, and color. Skin from the eyelids is often an excellent match for use in revision; however, this may confer the risk of contracture or subsequent limitations in mobility for the patient¹³. Median forehead flaps confer the risk of changing the medial brow position¹³.

Among these surgical techniques, FTSG or Z-plasty seemed to provide the most favorable post-operative outcomes for the patient; however, we chose to proceed with FTSG due to a few reasons. First, Z-plasty is a cumbersome technique when applied to the periorbital region. Previous periorbital reconstructive surgeries that utilized Z-plasty involved multiple transpositions in succession, from a double Z-plasty to ones involving three pairs of flaps^{3,14}. Creating more flaps can confer a greater risk of post-operative complications, including flap necrosis, infection, hematoma, or a trap door effect¹⁵. Second, FTSG is effective at reducing the chance of scar contractures¹⁶. This reduces the risk of skin restriction following the post-operative healing process. Third, the periorbital region has a rich vascular supply, which allows for excellent survival of FTSGs⁸. Fourth, the required amount of skin can be estimated and harvested, allowing for full replacement of the skin, and avoiding anterior

lamellar shortage¹³. Our goal was to improve quality-of-life for the patient as well as minimize the risk for subsequent scarring and contracture, which was best met through the FTSG procedure.

CONCLUSION

FTSG can be an effective alternative to Z-plasty scar revision in periorbital reconstructive surgeries. This unique case demonstrates the FTSG's utility in restoring upper eyelid opening and function, in a patient with vision only on the right eye, status post right corneal transplantation.

CONFLICT OF INTEREST

None declared by authors.

REFERENCES

1. Zito PM, Jawad BA, Mazzoni T. Z Plasty. In: StatPearls [Internet]. Treasure Island (FL): StatPearls Publishing; 2022 [cited 2022 Nov 11]. Available from: <http://www.ncbi.nlm.nih.gov/books/NBK507775/>
2. Kim BJ, Lee SJ. Correction of a post-traumatic scar fold in the lateral canthus using modified Z-plasty. *Arch Craniofac Surg* 2018 Mar;**19**(1):51–4.
3. Harvey J. Modified “double-Z-plasty” in the closure of medial canthal defects. *Ophthalmic Surg* 1987 Feb;**18**(2):120–2.
4. Rathore DS, Chickadasarahilli S, Crossman R, Mehta P, Ahluwalia HS. Full Thickness Skin Grafts in Periocular Reconstructions: Long-Term Outcomes.

- Ophthalmic Plastic & Reconstructive Surgery* 2014 Dec;**30**(6):517–20.
5. Czyz CN, Cahill KV, Foster JA, Michels KS, Clark CM, Rich NE. Reconstructive options for the medial canthus and eyelids following tumor excision. *Saudi J Ophthalmol* 2011 Jan;**25**(1):67–74.
 6. Kim CH, Son KM, Choi WY, Cheon JS. Evaluation of Triamcinolone Injection and Subcision as a First-Line Non-Surgical Treatment of Post-Traumatic Acute Trap-Door Deformity. *Arch Aesthetic Plast Surg* 2018 Jun 30;**24**(2):62–7.
 7. Li G, Fu A, Zhang B, Ding W, Ouyang H, Xu S, et al. Epicanthus correction with a modified asymmetric Z-plasty. *JPRAS Open* 2022 Sep;**33**:57–62.
 8. Suzanne K. Freitag, N. Grace Lee, Daniel R. Lefebvre. Eyelid Reconstruction [Internet]. New York: Thieme; 2020 [cited 2022 Dec 4]. Available from: https://search.ebscohost.com/login.aspx?direct=true&db=nl_ebk&AN=2323588&site=eds-live&scope=site
 9. Corredor-Osorio R. Preauricular full-thickness skin grafting in medial canthal reconstruction. *Our Dermatol Online* 2018 Jan 9;**9**(1):57–61.
 10. Mehta JS, Olver JM. Infraglabellar Transnasal Bilobed Flap in the Reconstruction of Medial Canthal Defects. *Arch Ophthalmol* 2006 Jan 1;**124**(1):111–5.
 11. Gupta R, John J, Hart J, Chaiyasate K. Medial Canthus Reconstruction with the Paramedian Forehead Flap. *Plast Reconstr Surg Glob Open* 2022 Jul 13;**10**(7):e4419.
 12. Stewart CM, Norris JH. Reconstruction of extensive medial canthal defects using a single V-Y, island pedicle flap. *Orbit* 2018 Sep 3;**37**(5):331–4.
 13. de Jongh FW, Pouwels S, Weenen C, van den Bosch WA, Paridaens D. Medial Canthal Reconstruction of Skin Defects With Full-Thickness Skin Grafts. *Dermatol Surg* 2021 Aug;**47**(8):1135–7.
 14. Allen R. Multiple z-plasties for medial canthal web [Internet]. 2017 [cited 2022 Nov 13]. Available from: <https://eyerounds.org/atlas-video/multiple-z-plasties.htm>
 15. Salam GA, Amin JP. The Basic Z-Plasty. *Am Fam Physician* 2003 Jun 1;**67**(11):2329–32.
 16. Imahara SD, Klein MB. 5 - Skin grafts. In: Orgill D, Blanco C, editors. *Biomaterials for Treating Skin Loss* [Internet]. Woodhead Publishing; 2009 [cited 2022 Nov 13]. p. 58–79. (Woodhead Publishing Series in Biomaterials). Available from: <https://www.sciencedirect.com/science/article/pii/B9781845693633500055>