

# Autologous Platelet-Rich Plasma Injection and Platelet-Rich Fibrin Glue Insertion for the Treatment of Extensive Suprlevator Anorectal Fistula: A Case Report

Amin Dalili<sup>1,2</sup>, Daryoush Hamidi Alamdari<sup>1,2</sup>, Alimohamad Dalili<sup>1,2</sup>,  
Maryam Sarkardeh<sup>1,2</sup>, Alireza Rezapanah<sup>1,2</sup>, Nooshin Tafazoli<sup>3\*</sup>

1. Surgical Oncology Research Center, Faculty of Medicine, Mashhad University of Medical Sciences, Mashhad, Iran
2. Department of Surgery, Imam Reza hospital, Mashhad University of Medical Sciences, Mashhad, Iran
3. MD, Faculty of Medicine, Mashhad University of medical sciences, Mashhad, Iran

## ABSTRACT

Suprlevator fistula stays a challenge in general surgery. We present a case with suprlevator anorectal fistula and subsequent retroperitoneal necrotizing fasciitis in which autologous platelet-rich plasma and platelet-rich fibrin glue were used for fistula closure. A 59-year-old man was admitted with pelvic pain and fever. Abdominopelvic sonography and CT scan reported a deep horseshoe-shaped anorectal abscess with extension to the pelvic floor, suprlevator, psoas, retroperitoneal muscles, and kidneys. He was managed with antibiotics, abscess drainage, repeated radical surgical debridement, and necrosectomy. After 30 days, he was discharged, but he returned to the office with the complaint of purulent discharge from the hypogastric region and a diagnosis of fistula formation. Platelet-rich plasma was injected around the fistula into the tissue, and platelet-rich fibrin glue was introduced to the fistula tract. At the 11-month follow-up, the patient did not have voiding dysfunction, constipation, diarrhea, or fistula tract infection. Autologous platelet-rich plasma injection and platelet-rich fibrin glue insertion suggest a secure and effective approach for treating suprlevator anorectal fistula.

## KEYWORDS

Suprlevator anorectal Abscess; Necrotizing Fasciitis; Platelet-Rich Plasma; Platelet-Rich Fibrin Glue

## Please cite this paper as:

Dalili A., Hamidi Alamdari D., Dalili A., Sarkardeh M., Rezapanah A., Tafazoli N. Autologous Platelet-Rich Plasma Injection and Platelet-Rich Fibrin Glue Insertion for the Treatment of Extensive Suprlevator Anorectal Fistula: A Case Report. *World J Plast Surg.* 2023;12(1):58-62.  
doi: 10.52547/wjps.12.1.58

## \*Corresponding Author:

Nooshin Tafazoli

Student Research Committee,  
Faculty of Medicine, Mashhad  
University of medical sciences,  
Mashhad, Iran

Tel.: +989105003361

Email: tafazzolin931@mums.ac.ir

Received: 1/4/2023

Accepted: 4/2/2023

## INTRODUCTION

Suprlevator abscesses can cause rare clinical complications, like perineal necrotizing fasciitis, an unusual but potentially critical and rapidly spreading soft-tissue infection<sup>1</sup>. The main presenting symptoms of necrotizing fasciitis (NF) are localized pain, fever, and systemic toxicity, and it is often fatal unless immediately recognized and aggressively treated. Treatment modalities include surgery, antibiotics, supportive care, and hyperbaric oxygen<sup>2</sup>. Retroperitoneal NF should be considered in any patient with symptoms of sepsis<sup>3</sup>. The rapid worsening of the patient also provides a clue towards the diagnosis<sup>4</sup>.



This work is licensed under a Creative Commons Attribution-NonCommercial 4.0 International license (<https://creativecommons.org/licenses/by-nc/4.0/>). Non-commercial uses of the work are permitted, provided the original work is properly cited.

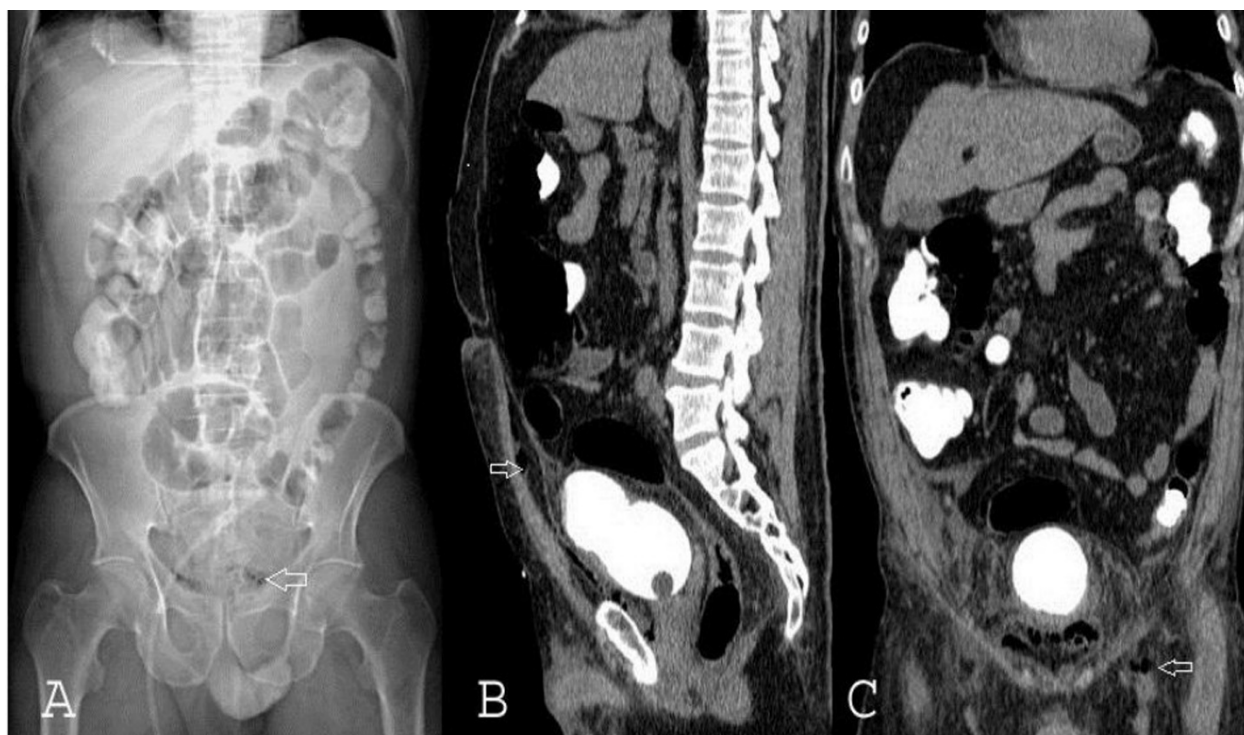
Fibrin glue has been successfully used to cure different types of fistulas. The installation of fibrin glue is a simple procedure that does not affect the sphincter musculature and is a possibly ideal treatment for perineal fistula<sup>5,6</sup>. Fibrin glue forms a fibrin clot approximately ten times stronger than a physiological clot. This clot advances the occlusion of the fistula tract by providing a firm provisional matrix and assisting the local proliferation of fibroblasts, collagen synthesis, and new blood vessel formation<sup>7,8</sup>.

In this case, we used Platelet-Rich Plasma (PRP) and fibrin glue as a new treatment method for the supralelevator anorectal fistula. We presented a non-healing fistula due to a supralelevator abscess that has an excellent response to PRP injection to its tract.

### CASE PRESENTATION

A 59-year-old man was admitted to the Emergency Department of Imam Reza Hospital, Mashhad, Iran in August 15, 2021, with hypogastric pain and transient fever three days ago. At admission, the body temperature was 37 °C, and respiratory rate, pulse rate, and blood pressures were in normal ranges. Physical examination revealed hypogastric

tenderness; a mass with fluctuation was also palpated in the midline below the umbilicus. Rectal examination defined a deep anorectal abscess. Blood tests determined leukocytosis (white blood cell count of 26000 cells/mm<sup>3</sup>), erythrocyte sedimentation rate of 84 mm/h, and C-reactive protein of 123 mg/L. He had a diagnosis of benign prostatic hypertrophy ten months ago and underwent a screening colonoscopy three weeks before admission, which was normal. Two weeks after the colonoscopy, the patient complained about progressive pelvic pain, discomfort, and transient fever (for only one day). Abdominopelvic sonography reported a perivesical abscess and collection of 6×10 cm around the bladder. An abdominopelvic CT scan showed increased bladder wall thickness, fat stranding, and multiple gas densities around the bladder and prostate in retropubic and perivesical regions with extension to the anterior abdominal wall and left inguinal canal. There was no evidence of contrast material leakage (Figure. 1, 2). Also, there were multiple air densities in soft tissue (Figure. 1A, 2A), which extended into the abdominal wall until adjacent to the umbilicus (Figure. 1B, 2B), perivesical space (Figure. 1C), and in retro-pubic and left inguinal canal (Figure. 2C). The patient received empirical antibiotics

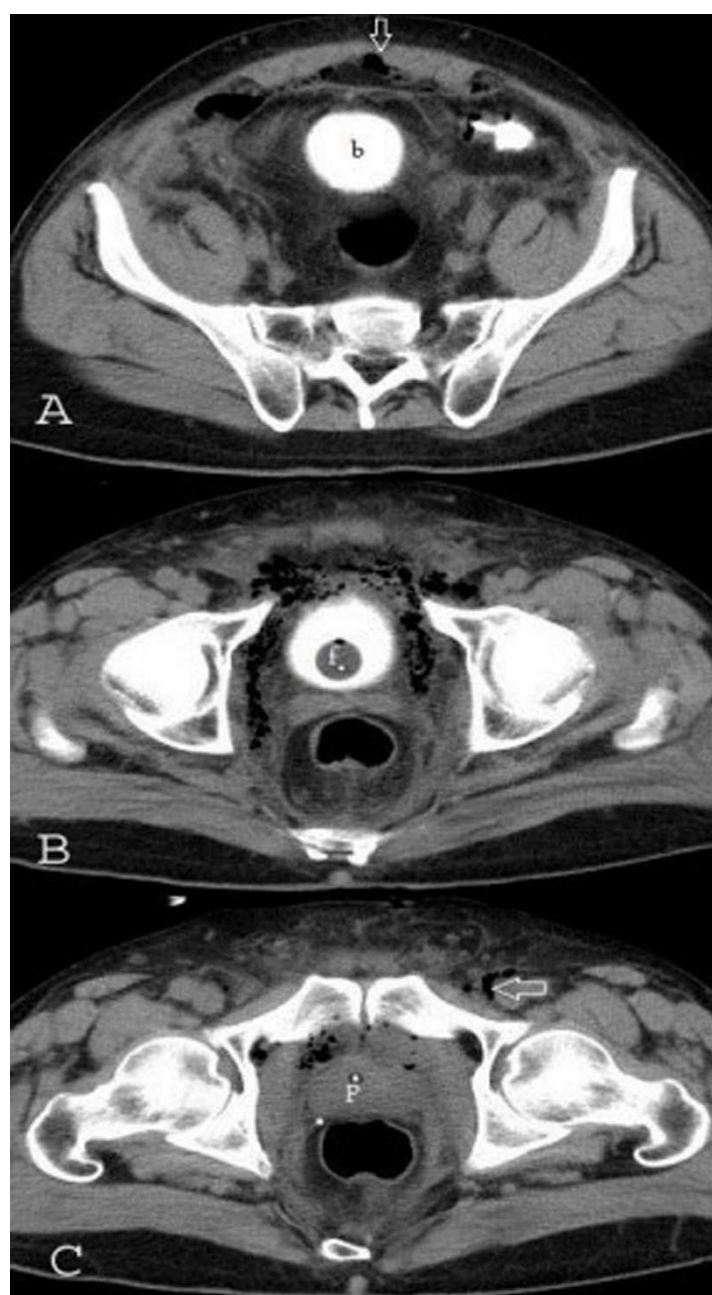


**Figure 1:** Multiple air densities in soft tissue (arrows). A) Scout view of abdominopelvic CT scan showed multiple gas densities above the pubis. B) In sagittal view, these gas densities extended to abdominal wall until adjacent to umbilicus. C) In coronal view, these air densities in perivesical space and left inguinal canal are obvious.

(Ceftriaxone and Metronidazole) intravenously one hour before the operation and underwent prompt radical surgical debridement. Due to the perivesical abscess spreading to the midline, the surgery was performed by a team consisting of urologists and general surgeons. Debridement of necrotic tissues and draining of the purulent discharges were done. Abscesses fluid culture determined *Klebsiella pneumoniae* as the responsible pathogen. Based on the antibiogram results, the antibiotics were changed

to imipenem and vancomycin. Debridement and draining of the purulent discharges were done several times under anesthesia. He was discharged after 30 days in good general condition.

Two weeks later, he was referred to the hospital with complaints about a fistula whose secretions did not stop. The retroperitoneal space around the bladder was dissected in the operation room without opening the abdominal cavity. Pus was spread in the pelvic floor, supraplevator, psoas, and retroperitoneal



**Figure 2:** transverse slices of abdominopelvic CT scan showed multiple air densities (arrows) of soft tissue in the abdominal wall (A), in perivesical space (B), and the retropubic and left inguinal canal (C).

muscles. About 300 cc of pus were removed from the abscess cavity. In the retroperitoneum, necrotic tissues were debrided. Then two drains were placed in the right and left lower quadrants. A pigtail drain was used to discharge the abscess. Discharge from the right drain continued for three months; when the release decreased, the drain was kept for five months. During outpatient follow-up, the right drain had an excessive discharge. Because of the high extension of necrotic tissue, using platelet-rich plasma (PRP) and platelet-rich fibrin glue (PRFG) to repair the destructed tissues was considered. Platelet-rich plasma and PRFG were obtained from the blood as standard, then PRP was injected around the fistula into the tissue, and PRFG was introduced to the fistula tract. No complications were observed during and after the injection.

Eleven months after the first admission, the patient had a good general condition with no urinary symptoms. According to the abdominopelvic US, there was no radiologic evidence of perivesical and supralelevator anorectal abscesses or fistula.

This study was confirmed by the Research Ethics Committees of Islamic Azad University- Mashhad Branch with an ID number of IR.IAU.MSHD.REC.1401.017 (<https://ethics.research.ac.ir/IR.IAU.MSHD.REC.1401.017>). The patient's written consent was obtained for the publication of this case report.

## DISCUSSION

The supralelevator abscess is the most complicated variant of deep anorectal abscesses. Its symptoms are not specific, resulting in delayed diagnosis and treatment <sup>4,9</sup>. NF is an uncommon soft-tissue infection. People with diabetes, immunosuppressed patients, and patients with peripheral vascular disease are more prone to develop NF. However, it has been reported in healthy individuals <sup>2, 10</sup>. The incidence of NF is 500–1500 cases per year, with a mortality rate of 24–34 % <sup>11</sup>. It presents as a generalized phlegmonous destructive inflammation of the perianal, perineal, genital, and gluteal soft tissues, the lower part of the anterior abdominal wall <sup>12</sup>. Progressive deterioration of the patient's general condition, with symptoms of sepsis, are typical manifestations <sup>10</sup>. Systemic toxicity is common and can be fatal if not diagnosed and aggressively treated <sup>13, 14</sup>. Treatment with broad-spectrum antibiotics to cover the extended range of potential pathogens and

early radical surgical excision of all affected tissue are the treatments of choice <sup>15</sup>. Zaveri et al. <sup>16</sup> reported a young male without any comorbid condition who presented with a retroperitoneal expansion of a perianal abscess after initial drainage. The drainage was performed through a lumbar incision based on the X-ray finding of gas in the retroperitoneum. Despite this, the patient did not survive. In contrast to the case presented by Zaveri et al. <sup>16</sup>, our patient survived and had no urinary or defecation problems after 11 months of follow-up. Several reasons contribute to the survival of our case, including the patient's age, absence of comorbidities, and, more importantly, urgent incision and drainage.

The safety and efficiency of using PRP and PRFG in the treatment of supralelevator fistula have been confirmed by Keshvari et al <sup>17</sup>. They reported entirely cured and marked improvement of supralevator fistula in 11 and 1 patient two months after a single injection, respectively. Moreno-Serrano et al. <sup>18</sup> used growth factor-rich fibrin (Vivostat PRF®) in monotherapy and achieved cure rates of 62%. As regards incontinence, their results revealed no incontinence and satisfactory quality of life in 80 %. Zmora et al. <sup>19</sup> suggested that despite the moderate success rate of fibrin glue application in the treatment of perineal fistulas, it should be considered an initial treatment step in all patients with complicated perineal fistulas. Our patient's NF extended from the perianal region into the pelvis and retroperitoneum spaces. Access to the internal pelvis from the perineum is difficult because of the risk of vascular injury and hemorrhage. In our case, the success in the closure of the supralelevator anorectal fistula was related to using PRP and PRFG.

## CONCLUSION

A combination of antibiotic therapy, surgical debridement, and PRP and PRFG is helpful in wound healing and eradicating infection and outcome of supralelevator anorectal fistula complicated by necrotizing fasciitis.

## ACKNOWLEDGMENTS

The authors would like to express appreciation toward the medical personnel involved in the treatment of this patient in Imam Reza Hospital, Mashhad, Iran.



## CONFLICT OF INTEREST

None

## FUNDING

None

## REFERENCES

1. Hadzhieva E, Chakarov D, Moshekov E, Hadzhiev D, Kalchev Y, Atliev K, Sakakushev B. Suprlevator Abscess Complicated by Necrotic Fasciitis of Peritoneum, Genitalia, Anterior Abdominal Wall and Retroperitoneum. *Albanian Journal of Trauma and Emergency Surgery* 2021 Jul 20; **5**(2):896-8.
2. Green RJ, Dafoe DC, Rajfin TA. Necrotizing fasciitis. *Chest* 1996 Jul 1; **110**(1):219-29.
3. Amaranathan A, Sahoo AK, Barathi D, Shankar G, Sistla SC. Retroperitoneal Necrotizing Fasciitis Masquerading as Perianal Abscess—Rare and Perilous. *Cureus* 2017 Jan 17; **9**(1): e982.
4. Oikonomou C, Alepas P, Gavriil S, Kalliouris D, Manesis K, Bouboulis P, Filippou D, Skandalakis P. A rare case of posterior horseshoe abscess extending to anterolateral extraperitoneal compartment: anatomical and technical considerations. *Annals of coloproctology*. 2019 Aug; **35**(4):216.
5. Hwang TL, Chen MF. Randomized trial of fibrin tissue glue for low output enterocutaneous fistula. *Br J Surg* 1996; **83**:112.
6. Cellier C, Landi B, Faye A, Wind P, Frileux P, Cugnenc PH, Barbier JP. Upper gastrointestinal tract fistulae: endoscopic obliteration with fibrin sealant. *Gastrointest Endosc* 1996 Dec 1; **44**(6):731-3.
7. Spotnitz WD. Commercial fibrin sealants in surgical care. *Am J Surg* 2001 Aug 1; **182**(2):S8-14.
8. Gorodetsky R, Vexler A, An J, Mou X, Marx G. Haptotactic and growth stimulatory effects of fibrin (ogen) and thrombin on cultured fibroblasts. *J Lab Clin Med* 1998 Mar 1; **131**(3):269-80.
9. Aparício DJ, Leichsenring C, Sobrinho C, Pignatelli N, Geraldés V, Nunes V. Suprlevator abscess: New treatment for an uncommon aetiology: Case report. *Int J Surg Case Rep* 2019 Jan 1; **59**:128-31.
10. Gadler T, Huey S, Hunt K. Recognizing Fournier's gangrene in the emergency department. *Adv Emerg Nurs J* 2019 Jan 1; **41**(1):33-8.
11. White NR, Fowler LL. Retroperitoneal and cutaneous necrotizing fasciitis secondary to necrotizing pancreatitis. *J Emerg Med* 2014 Aug 1; **47**(2):147-9.
12. Kuzaka B, Wróblewska MM, Borkowski T, Kawecki D, Kuzaka P, Młynarczyk G, Radziszewski P. Fournier's gangrene: clinical presentation of 13 cases. *Med Sci Monit* 2018; **24**:548.
13. Streptococcal necrotising fasciitis. *J Infect* 1992 Nov 1; **25**(3):299-302.
14. Donaldson PM, Naylor B, Lowe JW, Goulesbrough DR. Rapidly fatal necrotising fasciitis caused by *Streptococcus pyogenes*. *J Clin Pathol* 1993 Jul 1; **46**(7):617-20.
15. Woodburn MK, Ramsay G, Gillespie G, Miller DF. Retroperitoneal necrotizing fasciitis. *Br J Surg* 1992 Apr; **79**(4):342-4.
16. Zaveri JP, Nathani RR, Mathure AB. Ano-rectal abscess with retro-peritoneal spread (a case report). *J Postgrad Med* 1987 Apr 1; **33**(2):97.
17. Shirvan MK, Alamdari DH, Ghoreifi A. A novel method for iatrogenic vesicovaginal fistula treatment: autologous platelet rich plasma injection and platelet rich fibrin glue interposition. *J Urol* 2013 Jun 1; **189**(6):2125-9.
18. Moreno-Serrano A, García-Díaz JJ, Ferrer-Márquez M, Alarcón-Rodríguez R, Álvarez-García A, Reina-Duarte Á. Using autologous platelet-rich plasma for the treatment of complex fistulas. *Rev Esp Enferm Dig* 2016 Mar 1; **108**(3):123-8.
19. Zmora O, Mizrahi N, Rotholtz N, Pikarsky AJ, Weiss EG, Nogueras JJ, Wexner SD. Fibrin glue sealing in the treatment of perineal fistulas. *Dis Colon Rectum* 2003 May; **46**:584-9.