

Evaluation of Clinical Manifestations, Pattern of Involvement, and Surgical Outcomes in Patients with Post Covid-19 Head and Neck Mucormycosis Infection among Patients Admitted To Namazi Hospital, Shiraz, Iran (2021-2022)

Mehryar Nahaei¹, Gholamreza Motazedian², Ali-Akbar Mohammadi²,
 Mohammad Ali Davarpanah³, Parsa Yazdanpanahi⁴, Nazanin Ayareh^{4*},
 Fateme Salari⁵, Alireza Keshtkar⁴

1. Department of Plastic and Reconstructive Surgery, Shiraz University of Medical Sciences, Shiraz, Iran
2. Burn and Wound Healing Research Centre, Plastic and Reconstructive Surgery Ward, Shiraz University of Medical Sciences, Shiraz, Iran
3. Infectious Disease Department, Shiraz University of Medical Sciences, Shiraz, Iran
4. Student Research Committee, School of Medicine, Shiraz University of Medical Sciences, Shiraz, Iran
5. Trauma Research Center, Shahid Rajaei (Emtiaz) Trauma Hospital, Shiraz University of Medical Sciences, Shiraz, Iran

ABSTRACT

Background: COVID-19, caused by SARS-CoV-2, is a global pandemic that particularly affects immunocompromised individuals, leading to secondary bacterial and fungal infections. Mucormycosis, caused by Mucorales fungi, is a severe infection primarily affecting immunocompromised individuals. The COVID-19 pandemic has seen a surge in mucormycosis cases worldwide, with India experiencing a significant increase. Various factors, including diabetes mellitus, contribute to the risk of mucormycosis. This study investigated head and neck mucormycosis in patients with prior COVID-19 infection.

Methods: Data from 45 patients were analyzed, with diabetes being the most common risk factor. Visual symptoms, ethmoid bone involvement, and orbital bone involvement were also identified as significant factors.

Results: The COVID-19 pandemic has led to an increase in mucormycosis cases, particularly in the head and neck region, with high mortality. Successful management involves addressing underlying factors, surgical debridement, and antifungal therapy.

Conclusion: Timely debridement reduces morbidity and mortality.

KEYWORDS

COVID-19, Mucormycosis; Immunocompromised; Diabetes Mellitus

Please cite this paper as:

Nahaei M., Motazedian G., Mohammadi AA., Davarpanah MA., Yazdanpanahi P., Ayareh N., Salari F., Keshtkar A. Evaluation of Clinical Manifestations, Pattern of Involvement, and Surgical Outcomes in Patients with Post Covid-19 Head and Neck Mucormycosis Infection among Patients Admitted To Namazi Hospital, Shiraz, Iran (2021-2022). *World J Plast Surg.* 2023;12(3):64-72.
 doi: 10.61186/wjps.12.3.64

*Corresponding Author:

Nazanin Ayareh

Student Research Committee, School of Medicine, Shiraz University of Medical Sciences, Shiraz, Iran

Tel.: +98-9172600232

Email: nazanin.ayareh@gmail.com

Received: 2023.03.19

Accepted: 2023.10.17

INTRODUCTION

Coronavirus disease 2019 (COVID-19) is an infectious viral illness caused by a new strain of the severe acute respiratory syndrome coronavirus 2 (SARS-CoV-2). It was officially declared a global pandemic in March 2020^{1,2}. Immunocompromised individuals are particularly susceptible

to the exacerbation of COVID-19 due to secondary infections and co-infections. Bacterial secondary infections are the most common, followed by secondary fungal infections³.

Among COVID-19 patients admitted to intensive care units (ICUs) with acute respiratory failure, the most prevalent fungal pathogens are *Aspergillus*, *Candida*, and *Mucor*^{4, 5}. Mucormycosis is a common invasive fungal infection that primarily affects immunocompromised individuals, along with aspergillus⁶. Mucormycosis is caused by fungi belonging to the order Mucorales, which are ubiquitous in nature⁷. These infections are characterized by their severe and rapidly progressive nature, leading to significant morbidity and mortality⁸.

The COVID-19 pandemic has witnessed a sudden surge in the number of mucormycosis cases worldwide^{9, 10}. One of the countries hit hardest by the COVID-19 pandemic, India experienced a significant increase in mucormycosis cases. In May 2021, India reported thousands of mucormycosis cases, with estimates suggesting over 11,000 cases^{11, 12}.

Various factors contribute to compromised immune function and increase the risk of mucormycosis. Diabetes Mellitus is among these risk factors. It is worth noting that established risk factors such as diabetes, transplantation, or hematological malignancies may be absent in some mucormycosis cases¹³⁻¹⁵.

Understanding the factors that contribute to the development and severity of mucormycosis in COVID-19 patients can help healthcare professionals identify high-risk individuals and develop targeted prevention and treatment strategies.

We aimed to evaluate the association between various factors (such as age, sex, anemia, leukocytosis, diabetes mellitus, hypertension, renal failure, and malignancy) and the involvement of different anatomical sites (such as the ethmoid sinus, palate, and orbit) with the risk of recurrence or death in patients with mucormycosis. Analyzing such factors can provide valuable insights into the association between COVID-19 and mucormycosis.

METHODS

This cross-sectional study was conducted in a tertiary referral hospital located in the south of Iran,

Shiraz City, central Iran.

This study has been approved by the Shiraz University of medical science ethical committee with the ethical code of [IR.SUMS.MED.REC.1401.322](#).

We obtained the information by examining the data of patients who visited Namazi Hospital in Shiraz with head and neck mucormycosis infection that occurred during or after the course of Covid-19 infection from March 21, 2021, to March 20, 2022. We defined the conditions for inclusion in the study as patients must have been infected with covid-19 before developing mucormycosis, and their covid-19 was confirmed by at least one of the following methods: polymerase chain reaction (PCR) or rapid antigen test or Computed tomography (CT) of the chest which was diagnosed by infectious and radiology specialists. According to clinical evidence and radiological interventions such as magnetic resonance imaging (MRA) or CT, possible mucormycosis patients were found and finally confirmed by culture.

A checklist was designed that includes demographic information such as gender and age were included in the checklist. In addition, the clinical presentation of the cases like pain, paresthesia, facial swelling and visual symptoms was noted. Past medical history of patients such as diabetes mellitus status, hypertension status, Renal Failure and malignancy were gathered. Lab data such as anemia, and leukocytosis were added to the checklist. Also, with the cooperation of several specialists, the imaging data of various head and neck anatomical parts such as the nose, maxillary, palate, orbital, ethmoid, sphenoid, frontal, and scalp were analyzed and added to the above collection.

Statistical analysis

Statistical analysis was performed using SPSS software version 22 (IBM Corp., Armonk, NY, USA). Descriptive statistics were presented as number and frequency (%) for categorical variables. Quantitative variables are presented by means with standard deviation (mean \pm SD) or median with interquartile ratio (median, IQR). For data analysis, the Shapiro-Wilk test was used to assess the normal distribution of quantitative variables. Chi-square, exact fissure test, and independent sample T-test were used to investigate the correlation of each independent factor with the outcome and recurrence. Multivariate

logistic regression was used to correlate the chosen variables with the outcome. *P*-value of less than 0.05 was considered as significantly different.

RESULTS

Among all 45 patients included in the article, 28 (62.2) were men and 17 (37.8) were women, with a mean age of 54 years (80-5 Y/O) and a standard deviation (SD) of 13.4. A number of 24 people experienced disease recurrence, whose mean age was 50.9 ± 14.2 (*P*-value=0.077), and 21 people did not relapse, whose mean age was 58.0 ± 11.5 . Unfortunately, 17 patients died due to mucormycosis, with a mean age

of 59.0 ± 13.0 years (*P*-value=0.062), and those who survived had a mean age of 51.3 ± 13.0 years.

Table 1 shows the demographic characteristics of our patients. The mean age was not significantly different in the positive and negative recurrence group (*P*=0.07).

Table 2 demonstrates the correlation of the clinical symptoms with the recurrence of mucormycosis and the outcome of the cases. The results show statistically significant differences in the outcome of patients with positive visual symptoms and orbital bone involvement.

The logistic regression multivariable analysis were presented in Table 3.

Table 1: Demographic information and their correlation with recurrence and outcome

Variables	Number (%) Mean±SD	Recurrence N(%)		<i>P</i> -value	Outcome N(%)		<i>P</i> -value	
		Mean±SD			Mean±SD			
		Positive	Negative		Death	Alive		
Age	54±13.4	50.9 ± 14.2	58.0 ± 11.5	0.077	59.0 ± 13.0	51.3 ± 13.0	0.062	
Sex	Female	17(37.8)	12(70.6)	5(29.4)	.071	8(47.1)	9(52.9)	.317
	Male	28(62.2)	12(42.9)	16(57.1)		9(32.1)	19(67.9)	
Anemia	21(46.7)	13(61.9)	8 (38.1)	.281	8(38.1)	13(61.9)	.967	
Leukocytosis	21(46.7)	10(47.6)	11(52.4)	.472	8(38.1)	13(61.9)	.967	
Diabetes mellitus (DM)	35(77.8)	19(54.3)	16(45.7)	.546 ^f	15(42.9)	20(57.1)	.173 ^f	
Hypertension (HTN)	24(53.3)	14(58.3)	10(41.7)	.472	12(50.0)	12(50.0)	.071	
Renal Failure (RF)	7(15.6)	3(42.9)	4(57.1)	.422 ^f	4(57.1)	3(42.9)	.231 ^f	
Malignancy	4(8.9)	1 (25.0)	3(75.0)	.351	2(50.0)	2(50.0)	.339	

SD: standard deviation; f: Fisher's exact test

Table 2: Clinical presentation information and their correlation with recurrence and outcome

Variables	Number (%)	Recurrence		<i>P</i> -value	Death		<i>P</i> -value
		Positive	Negative		Positive	Negative	
Visual symptom	28(62.2)	16(66.6)	12(57.1)	.511	14(82.3)	14(50.0)	.030
Nasal bone involvement	16(35.6)	9(37.5)	7(33.3)	.771	8(47.0)	8(28.5)	.209
Ethmoid bone involvement	22(48.9)	11(45.8)	11(52.3)	.661	12(70.5)	10(35.7)	.023
Maxillary bone involvement	41(91.1)	23(95.8)	18(85.7)	.254 ^f	16(94.1)	25(89.2)	.511 ^f
Orbital bone involvement	23(51.1)	12(50.0)	11(52.3)	.873	12(70.5)	11(39.2)	.042
Frontal bone involvement	2(4.4)	0(0)	2(9.5)	.212 ^f	0(0)	2(7.1)	.382 ^f
Palatine bone involvement	13(28.9)	4(16.6)	9(42.8)	.053	6(35.2)	7(25.0)	.342 ^f
Sphenoid bone involvement	5(11.1)	2(8.3)	3(14.2)	.435 ^f	1(5.8)	4(14.0)	.365 ^f
Scalp involvement	1(2.2)	0(0)	1(4.7)	.467 ^f	0(0)	1(3.5)	.622 ^f

SD: Standard deviation; f: Fisher's exact test

Table 3: Multivariate logistic regression of selected variables and outcome (alive, death)

Variables	B	P-value	OR	95% CI
Age	.078	.032	1.081	1.007-1.161
Sex	-1.665	.063	.189	.033-1.092
Visual symptom	1.437	.117	4.207	.697-25.397
Ethmoid bone involvement	1.215	.124	3.370	.715-15.876
Orbital bone involvement	1.759	.050	5.808	1.001-33.702
constant	-6.473	.007	.002	

CI; confidence level; OR: Odds ratio

DISCUSSION

The research findings suggest that the COVID-19 pandemic has led to an increased prevalence of mucormycosis. This can be attributed to the convergence of various interconnected risk factors, including diabetes^{16, 17}. Furthermore, the pandemic has resulted in a rise in secondary illnesses, including mucormycosis, in multiple regions worldwide^{10, 18, 19}. A systematic analysis of published case reports and series of mucormycosis in individuals with COVID-19 has indicated a growing association between the infection and COVID-19, with a higher frequency of reports originating from India²⁰. The analysis also proposed a mechanistic explanation for the increasing association between mucormycosis and COVID-19. Uncontrolled diabetes has been identified as a key risk factor for mucormycosis¹⁶. In this study, the researchers investigated various clinical manifestations, complications and their association with disease recurrence and mortality in COVID-19 patients with mucormycosis.

Mucormycosis can invade different body systems including head and neck region. Rhino-orbito-cerebral mucormycosis (ROCM) refers to Mucorales infection of this region, which has a high mortality rate^{21, 22}. Some ocular signs and symptoms associated with ROCM include eye pain, ophthalmoplegia, impaired vision, orbital cellulitis, necrosis, and ptosis²³. Previous studies have demonstrated that mucormycosis can cause severe damage to the eyes, bones, and surrounding tissues, resulting in vision impairment or loss, bone deterioration, and inflammation^{10, 18, 19}. Among the mucormycosis patients in this study, 62% experienced visual symptoms, including vision problems, eye redness, epiphora, and eye pain. The maxillary bone was involved in the majority of patients (91%) (Fig. 1). The mortality rate of ROCM is 44% in diabetics, 35% in patients with no underlying conditions, and 66% in patients with other underlying conditions⁸. This investigation has established a correlation between mucormycosis and visual impairment, involvement of the ethmoidal bone, and orbital involvement,

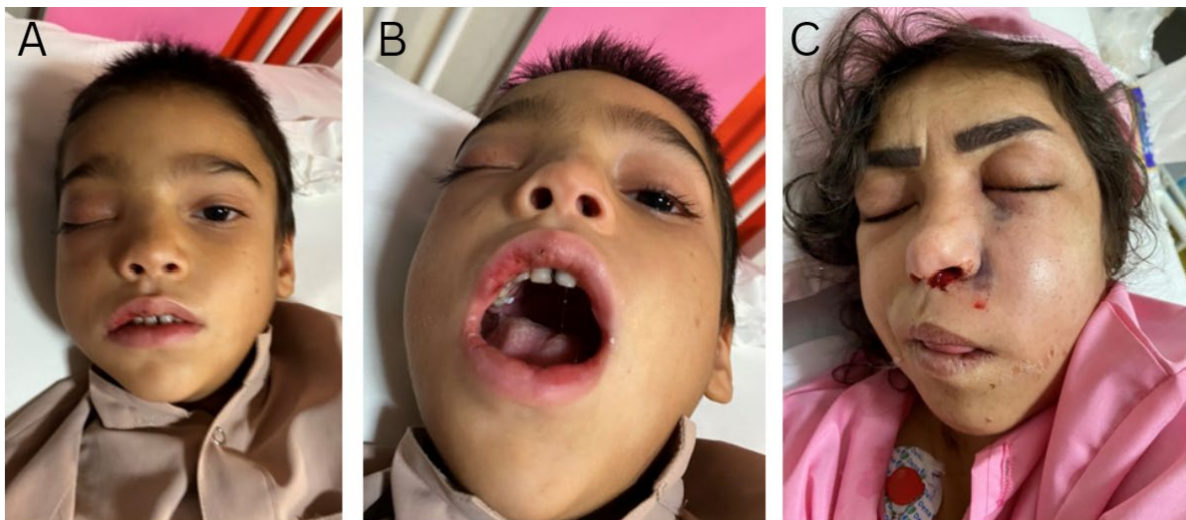

Figure 1: Two patients with COVID-19 and mucormycosis displaying signs of orbital cellulitis and palatal necrosis. This image highlights the severe damage caused by mucormycosis to the eyes, bones, and surrounding tissues

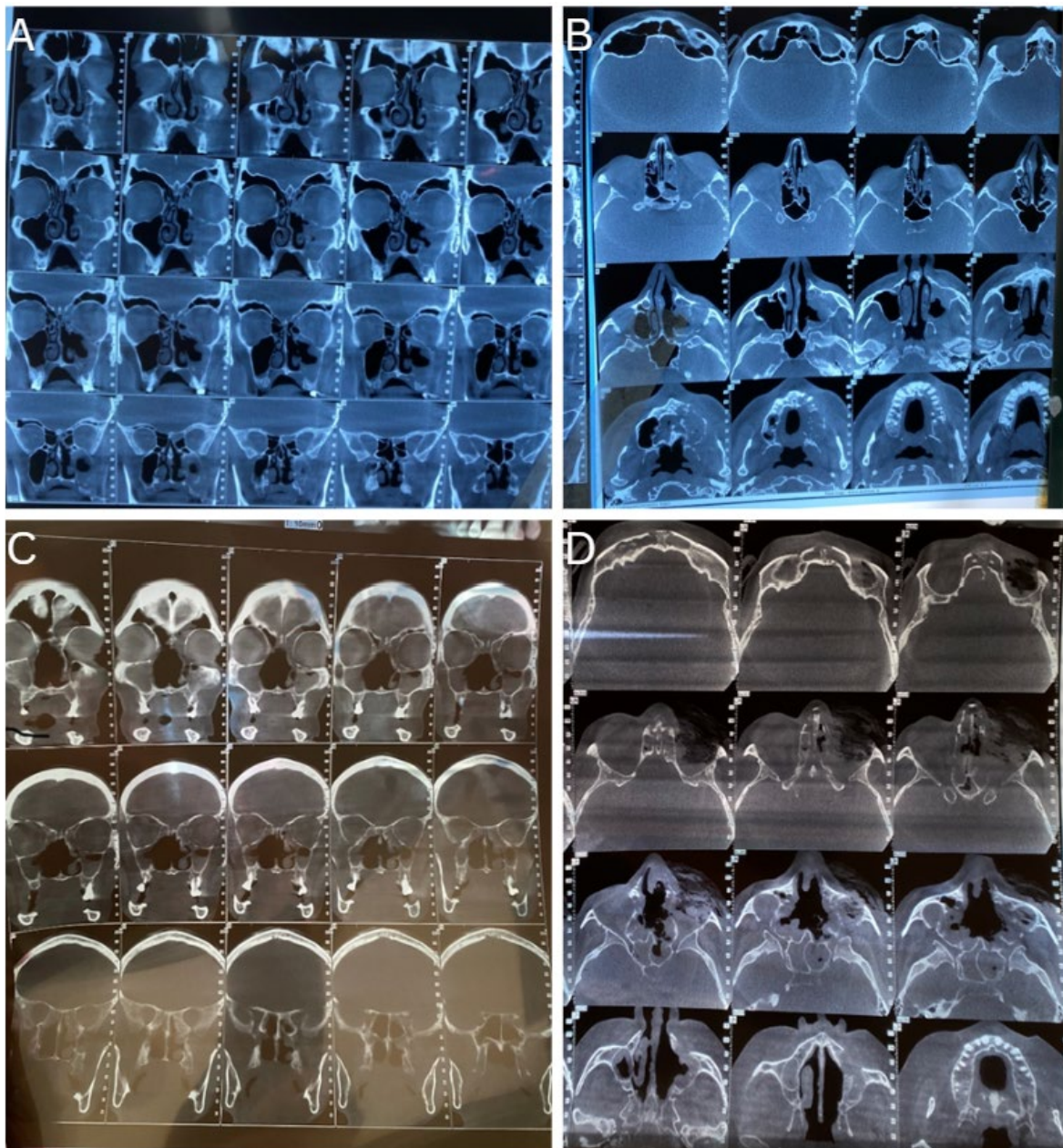


Figure 2: CT scan of two patients demonstrating typical findings of sinus opacification, mucosal thickening, and erosion of bony structures. These characteristic radiographic features are commonly observed in patients with Rhino cerebral mucormycosis (ROCM). The presence of these findings on CT scan warrants prompt evaluation and appropriate management to mitigate potential complications associated with ROCM and COVID-19 co-infection

which are associated with a higher mortality rate. Involvement of the frontal bone and scalp was less common, with only 2 cases and 1 case, respectively. All patients with such involvement exhibited a favorable outcome, as they were discharged from the hospital alive and did not experience any disease recurrence. This finding is consistent with some previous studies that have also reported a relatively low incidence of frontal bone and scalp involvement in mucormycosis cases^{24,25}. However, it

is important to note that further research is needed to fully understand the factors contributing to this favorable outcome and to determine if there are any specific characteristics or treatments that may have influenced the results.

Diagnosing mucormycosis in COVID-19 patients presents a significant challenge due to the lack of specific clinical features and reliable diagnostic tests. The clinical manifestations of mucormycosis can overlap with other fungal or bacterial infections,

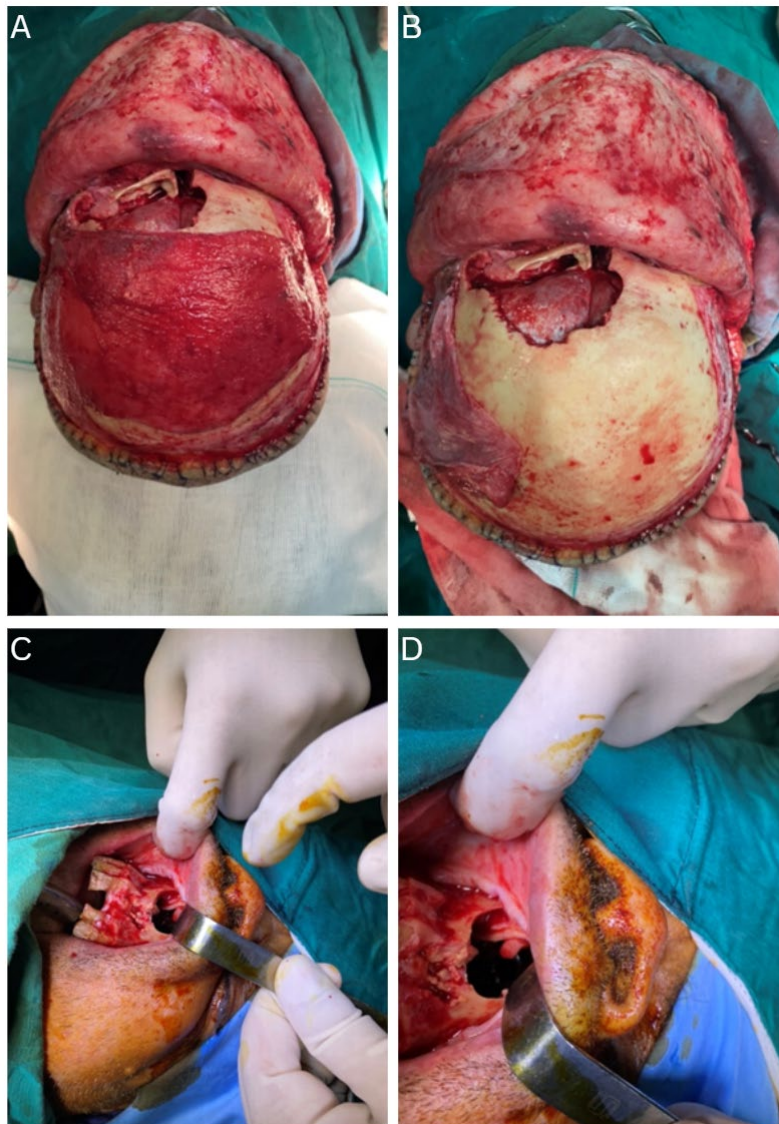


Figure 3: Surgical debridement in patients with mucormycosis and concurrent COVID-19 infection. This procedure involves removing infected and necrotic tissue to control the spread of the fungal infection. It is essential for successful management, along with appropriate antifungal therapy, in these patients

making it difficult to differentiate and diagnose accurately. However, a high index of suspicion is crucial in identifying potential cases. Imaging techniques such as computed tomography (CT) scans can aid in detecting characteristic findings.²⁶ Rapid and accurate diagnosis of mucormycosis in COVID-19 patients is crucial for timely initiation of appropriate antifungal therapy and improved patient outcomes. In our investigation CT scan was the modality of choice for diagnosis. CT scans typically revealed findings such as sinus opacification, mucosal thickening, and erosion of bony structures. (Fig. 2.) The involvement of the ethmoidal sinuses is commonly seen, with extension into the orbit

and adjacent structures. Orbital cellulitis, proptosis, and extraocular muscle involvement may also be evident²⁷. The orbital bones were involved in 51% of the cases while the ethmoid bones were involved in 48%. The odds ratio associated with ethmoid bone and Orbital bone shows that individuals with involvement of these bones had higher odds of developing mucormycosis. In severe cases, there can be intracranial extension with the presence of abscesses or cerebritis²⁸.

The lack of a reliable method for detection and treatment has posed challenges in managing this infection⁸. Successful management of mucormycosis requires a multimodal approach, involving the

reversal or discontinuation of underlying predisposing factors, surgical debridement, and antifungal therapy such as amphotericin B and Posaconazole, as well as the discontinuation of corticosteroids for mucormycosis treatment in COVID-19²⁹⁻³². In this hospital center, considering the pattern of bone involvement, the patients underwent surgical debridement and received antifungal and antibiotics before and after surgery (Fig. 3).

Various risk factors for mucormycosis recurrence or death in COVID-19 patients were also investigated in this study. In contrast to earlier studies suggesting a predominance of mucormycosis in men (78.9% of reported cases), our study indicates that being male was associated with a lower odds of developing mucormycosis compared to being female. However it is not statistically significant¹⁸.

Uncontrolled diabetes mellitus impairs immune system function, increasing the risk of developing mucormycosis. Data indicate that in countries such as India, Iran, and Mexico, over 75% of patients with diabetes are vulnerable to mucormycosis³³. Among all the risk factors examined in our study, the most common one was diabetes mellitus (DM), which was present in 77% of the individuals.

One study revealed that patients with malignancies such as lymphoma and acute leukemia, who developed neutropenia, became susceptible to mucormycosis³⁴. Only four participants reported having malignancies in our study, including aplastic anemia, myeloma, chronic lymphocytic leukemia (CLL), and colon cancer. The insignificant *P*-value can be due to small population of patients with malignancy.

Fifty percent of patients with HTN died, and the *P*-value of 0.071 indicates a potential trend towards a difference in mortality, but it is not statistically significant. The literature review found that the association between hypertension and mortality is heterogeneous^{35, 36}. More research is needed to determine the exact role of hypertension in COVID-19 disease severity and mortality.

The study revealed that there is no notable connection between the recurrence or mortality of mucormycosis and certain factors such as leukocytosis, blood group, frontal bone involvement, maxillary bone involvement, sphenoidal bone involvement, or scalp involvement.

CONCLUSION

The COVID-19 pandemic has caused an increase in the occurrence of mucormycosis, a fungal infection. This global health challenge has also led to a rise in secondary illnesses, including mucormycosis. Specifically, Rhino-orbito-cerebral mucormycosis (ROCM) in the head and neck area has been found to have a high mortality rate and can cause severe damage to the eyes, bones, and surrounding tissues. This investigation has established a clear connection between mucormycosis and visual impairment, involvement of the ethmoidal bone, and orbital involvement, all of which contribute to a higher mortality rate. Diagnosing mucormycosis in COVID-19 patients is challenging due to the absence of specific clinical features and reliable diagnostic tests. However, a high level of suspicion and the use of imaging techniques such as CT scans can assist in its detection. Successful management of mucormycosis requires a comprehensive approach that involves addressing underlying predisposing factors, performing surgical debridement, and administering antifungal therapy. It is important to note that timely debridement of necrotic regions can significantly reduce both the morbidity and mortality rates associated with this disease. Moving forward, it would be beneficial for future research to concentrate on methods for reconstructing bone structures in the head and neck of mucormycosis patients who have undergone debridement.

ACKNOWLEDGMENTS

We want to thank Shiraz University of Medical Science for supporting this study financially.

CONFLICT OF INTEREST

The authors declare that there is no conflict of interests. Ethical code: IR.SUMS.MED.REC.1401.322

REFERENCES

1. Cao H, Zhou Z, Wang L, et al. Screening of potential PFOS alternatives to decrease liver bioaccumulation: experimental and computational approaches. *Environ Sci Technol* 2019;**53**(5):2811-9.

2. World Health Organization. Who director-general's opening remarks at the media briefing on COVID-19-11 march 2020. 2020 [cited 2023; Available from: <https://www.who.int/director-general/speeches/detail/who-director-general-s-opening-remarks-at-the-media-briefing-on-covid-19e-11-march-2020>.
3. Ripa M, Galli L, Poli A, et al. Secondary infections in patients hospitalized with COVID-19: incidence and predictive factors. *Clin Microbiol Infect* 2021;**27**(3):451-7.
4. Song G, Liang G, Liu W. Fungal co-infections associated with global COVID-19 pandemic: a clinical and diagnostic perspective from China. *Mycopathologia* 2020;**185**(4):599-606.
5. Prattes J, Wauters J, Giacobbe DR, et al. Risk factors and outcome of pulmonary aspergillosis in critically ill coronavirus disease 2019 patients—a multinational observational study by the European Confederation of Medical Mycology. *Clin Microbiol Infect* 2022;**28**(4):580-7.
6. Camara-Lemarroy CR, González-Moreno EI, Rodríguez-Gutiérrez R, et al. Clinical features and outcome of mucormycosis. *Interdiscip Perspect Infect Dis* 2014;**2014**.
7. Spellberg B, Edwards Jr J, Ibrahim A. Novel perspectives on mucormycosis: pathophysiology, presentation, and management. *Clin Microbiol Rev* 2005;**18**(3):556-69.
8. Petrikos G, Skiada A, Lortholary O, Roilides E, Walsh TJ, Kontoyiannis DP. Epidemiology and clinical manifestations of mucormycosis. *Clin Infect Dis* 2012;**54**(suppl_1):S23-S34.
9. Hoenigl M, Seidel D, Carvalho A, et al. The emergence of COVID-19 associated mucormycosis: a review of cases from 18 countries. *The Lancet Microbe* 2022.
10. Al Balushi A, Al Ajmi A, Al Sinani Q, et al. COVID-19-associated mucormycosis: an opportunistic fungal infection. A case series and review. *Int J Infect Dis* 2022;**121**:203-10.
11. Ghazi BK, Rackimuthu S, Wara UU, et al. Rampant increase in cases of mucormycosis in India and Pakistan: a serious cause for concern during the ongoing COVID-19 pandemic. *The American Journal of Tropical Medicine and Hygiene* 2021;**105**(5):1144.
12. Pasquier G. COVID-19-associated mucormycosis in India: why such an outbreak? *Journal of Medical Mycology* 2023:101393.
13. Garg D, Muthu V, Sehgal IS, et al. Coronavirus disease (Covid-19) associated mucormycosis (CAM): case report and systematic review of literature. *Mycopathologia* 2021;**186**:289-98.
14. Mehta S, Pandey A. Rhino-orbital mucormycosis associated with COVID-19. *Cureus* 2020;**12**(9).
15. Venkatesh D, Dandagi S, Chandrappa PR, Hema K. Mucormycosis in immunocompetent patient resulting in extensive maxillary sequestration. *Journal of oral and maxillofacial pathology: JOMFP* 2018;**22**(Suppl 1):S112.
16. Sharma R, Kumar P, Rauf A, et al. Mucormycosis in the COVID-19 environment: a multifaceted complication. *Frontiers in cellular and infection microbiology* 2022;**12**:937481.
17. Arjmand P, Bahrami M, Mohammadie ZE, et al. Mucormycosis in pre-COVID-19 and COVID-19 era: A study of prevalence, risk factors and clinical features. *Laryngoscope Investigative Otolaryngology* 2022;**7**(5):1343-50.
18. Dogra S, Arora A, Aggarwal A, et al. Mucormycosis amid COVID-19 crisis: pathogenesis, diagnosis, and novel treatment strategies to combat the spread. *Frontiers in microbiology* 2022;**12**:794176.
19. Dam P, Cardoso MH, Mandal S, et al. Surge of mucormycosis during the COVID-19 pandemic. *Travel Med Infect Dis* 2023;**52**:102557.
20. Singh AK, Singh R, Joshi SR, Misra A. Mucormycosis in COVID-19: a systematic review of cases reported worldwide and in India. *Diabetes & Metabolic Syndrome: Clinical Research & Reviews* 2021;**15**(4):102146.
21. Talmi YP, Goldschmied-Reouven A, Bakon M, et al. Rhino-orbital and rhino-orbito-cerebral mucormycosis. *Otolaryngology—Head and Neck Surgery* 2002;**127**(1):22-31.
22. Veisi A, Bagheri A, Eshaghi M, Rikhtehgar MH, Rezaei Kanavi M, Farjad R. Rhino-orbital mucormycosis during steroid therapy in COVID-19 patients: A case report. *Eur J Ophthalmol* 2022;**32**(4):NP11-NP6.
23. Vaughan C, Bartolo A, Vallabh N, Leong SC. A meta-analysis of survival factors in rhino-orbital-cerebral mucormycosis—has anything changed in the past 20 years? *Clin Otolaryngol* 2018;**43**(6):1454-64.
24. Sahoo NK, Kulkarni V, Bhandari AK, Kumar A. Mucormycosis of the frontal sinus: A rare case report and review. *Annals of Maxillofacial Surgery* 2017;**7**(1):120.
25. Maliwan N, Reyes CV, Kippon JW. Osteomyelitis secondary to cutaneous mucormycosis: report of a case and a review of the literature. *The American journal of dermatopathology* 1984;**6**(5):479-82.
26. Prabhakar A, Prabhakar N, Garg M, Kumar A. The Integral Role of Radiology in the Diagnosis and Management of COVID-19-Associated Mucormycosis Infections. *The American Journal of Tropical Medicine and Hygiene* 2022;**106**(4):1022.
27. Agrawal A, Dixit Y, Yonati V, Nigam P, Khetai P. Imaging of COVID-19-associated rhino-orbital-cerebral mucormycosis: imaging analysis of 120 patients. *The*

- Egyptian Journal of Otolaryngology* 2022;**38**(1):1-8.
28. Joshi AR, Muthe MM, Patankar SH, Athawale A, Achhapalia Y. CT and MRI findings of invasive mucormycosis in the setting of COVID-19: experience from a single center in India. *American Journal of Roentgenology* 2021;**217**(6):1431-2.
 29. Skiada A, Lass-Floerl C, Klimko N, Ibrahim A, Roilides E, Petrlikos G. Challenges in the diagnosis and treatment of mucormycosis. *Med Mycol* 2018;**56**(suppl_1):S93-S101.
 30. Amanati A, Zekavat OR, Foroutan H, et al. Case reports of invasive mucormycosis associated neutropenic enterocolitis in leukemic children: diagnostic and treatment challenges and review of literature. *BMC Infect Dis* 2021;**21**:1-9.
 31. Sharma A, Goel A. Mucormycosis: risk factors, diagnosis, treatments, and challenges during COVID-19 pandemic. *Folia Microbiol (Praha)* 2022;**67**(3):363-87.
 32. Arbune M, Arbune A-A, Nechifor A, Chiscop I, Sapira V. Diagnostic and Treatment Challenges of Emergent COVID-Associated-Mucormycosis: A Case Report and Review of the Literature. *Antibiotics* 2022;**12**(1):31.
 33. Prakash H, Chakrabarti A. Global epidemiology of mucormycosis. *Journal of Fungi* 2019;**5**(1):26.
 34. Kara I, Tasova Y, Uguz A, Sahin B. Mucormycosis-associated fungal infections in patients with haematologic malignancies. *Int J Clin Pract* 2009;**63**(1):134-9.
 35. Mirza H, Noori MAM, Akbar H, et al. Hypertension as an independent risk factor for in-patient mortality in hospitalized COVID-19 patients: a multicenter study. *Cureus* 2022;**14**(7).
 36. Huang S, Wang J, Liu F, et al. COVID-19 patients with hypertension have more severe disease: a multicenter retrospective observational study. *Hypertens Res* 2020;**43**(8):824-31.