

A Case of Refractory Heel Ulcer Complicated by Moderate Osteomyelitis and Cellulitis Successfully Treated with Rheocarna

Makoto Shimabukuro^{1,2}, Naohiro Ishii^{1,2*}, Takanori Ko¹, Kyoichi Matsuzaki², Kazuo Kishi³

1. Department of Plastic and Reconstructive Surgery, International University of Health and Welfare Hospital, Tochigi, Japan
2. Department of Plastic and Reconstructive Surgery, International University of Health and Welfare, School of Medicine, Chiba, Japan
3. Department of Plastic and Reconstructive Surgery, Keio University, Tokyo, Japan

ABSTRACT

Revascularization surgery was first considered for the treatment of ulcers in patients with critical limb ischemia (CLI). However, it may not be indicated for patients with severe infections or peripheral vascular occlusions. Although blood purification therapy is adjuvant therapy for such patients, it is not yet widely used due to insurance coverage. We report a case of a refractory heel ulcer with moderate osteomyelitis and cellulitis that was not amenable to revascularization. Treatment with the adsorptive blood purifier rheocarna® (Kaneka Corporation; Osaka, Japan) resulted in complete epithelialization of the ulcer and control of inflammation. Although this case required careful follow-up, we believe rheocarna might be a promising treatment option for patients with CLI who do not respond to revascularization. Rheocarna could improve peripheral blood flow and control inflammation by improving antibiotic drug delivery.

KEYWORDS

Arteriosclerosis obliterans; Blood purification therapy; Critical limb ischemia; Osteomyelitis

Please cite this paper as:

Shimabukuro M., Ishii N., Ko T., Matsuzaki K., Kishi K. A Case of Refractory Heel Ulcer Complicated by Moderate Osteomyelitis and Cellulitis Successfully Treated with Rheocarna. *World J Plast Surg.* 2023;12(3):106-110. doi: 10.61186/wjps.12.3.106

INTRODUCTION

Improving lower-extremity blood flow is important for treating ulcers in patients with critical limb ischemia (CLI)¹. The treatment includes bypass surgery, endovascular therapy (EVT), and adjuvant therapies such as blood purification². Blood purification therapy improves peripheral circulation by removing toxic substances from the blood via extracorporeal circulation³. In Japan, the Liposorber® (Kaneka Corporation; Osaka, Japan) has been used for arteriosclerosis obliterans (ASO) patients^{4,5}; however, it is not widely used overseas. Rheocarna® (Kaneka Corporation; Osaka, Japan) is a new adsorptive blood purifier approved in Japan in 2020. It is indicated for patients with ASO and ulcers that are not amenable to revascularization and improves peripheral blood flow by removing low-density lipoprotein (LDL) cholesterol (LDL-C) and fibrinogen in the blood, contributing to wound healing⁶⁻⁸. However, it should be used cautiously in patients

*Corresponding Author:

Naohiro Ishii, M.D., Ph.D.

Department of Plastic and Reconstructive Surgery, International University of Health and Welfare Hospital, 537-3 Iguchi, Nasushiobara City, Tochigi 329-2763, Japan

Tel.: +81- 287-39-3060

E-mail: ishinao0916@gmail.com

Received: 2023.05.10

Accepted: 2023.11.19

with osteomyelitis because improved blood flow may spread the infection. Its effect on the treatment of patients with osteomyelitis has not been reported. Here, we report a case in which rheocarna was used to treat a patient with an intractable heel ulcer that did not respond to revascularization and was complicated by osteomyelitis and cellulitis. The rheocarna contributed to controlling inflammation and healing of the ulcer.

CASE PRESENTATION

A 62-year-old man undergoing dialysis for diabetic renal failure was referred to International University of Health And Welfare Hospital, Tochigi, Japan with an ulcer on the outer side of his left heel (Fig. 1a). He had a history of toe amputation for foot gangrene and bilateral diabetic retinal detachment. The

patient underwent debridement and conservative treatment with an ointment; however, the ulcer gradually worsened. We believe this result was due to inadequate blood flow. Computed tomographic angiography (CTA) revealed severe calcification and stenosis of the left below-knee arteries (Fig. 2a). Skin perfusion pressure (SPP) showed low values in the dorsal foot artery region of the left foot (28 mmHg) and its planter side (21 mmHg). The SPP around the ulcer was also low (Fig. 1a). Magnetic Resonance Imaging (MRI) showed high signals in the calcaneus and surrounding soft tissues on Short Tau Inversion Recovery (STIR); osteomyelitis and cellulitis were suspected. However, the patient refused hospitalization. The ulcer worsened, and the pain became so severe that the patient could no longer walk; therefore, he was admitted to the hospital three months after the initial visit.

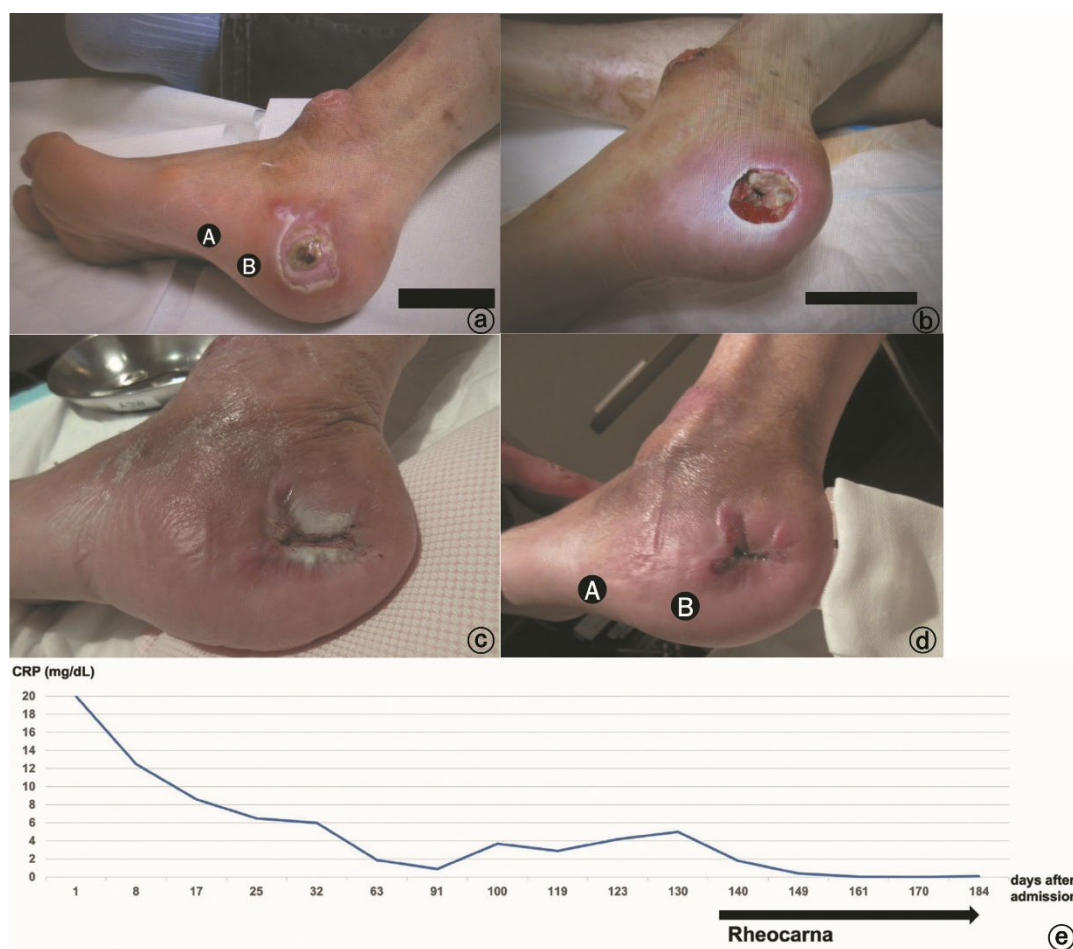


Figure 1: Photograph at initial examination. An ulcer is observed on the lateral side of the left heel. The SPP around the ulcer is low at 46 (A) and 16 (B) mmHg, respectively. (b) Photograph at admission. The ulcer is 3 cm in diameter and reaches the calcaneus. (c) Photograph taken after the split-thickness skin graft. The graft did not take well. (d) Photograph after Rheocarna treatment. The ulcer is completely epithelialized. The peri-ulcer SPP improves to 68 (A) and 43 (B) mmHg, respectively. (e) Chronological change of C-reactive protein in post-hospitalization course. CRP; C-reactive protein, SPP; skin perfusion pressure

On admission, the patient had high inflammation levels with a white blood cell count of 11800/ μ L; C-reactive protein (CRP) was 19.9 mg/dL. The ulcer was 3 cm in diameter and deep enough to reach the calcaneal bone (Fig. 1b), with surrounding pain, redness, and heat sensations. Bone scraping and curettage cultures revealed the presence of *Pseudomonas aeruginosa* and *Morganella morganii*. Because the patient refused to undergo lower extremity amputation, the debridement and reconstruction of the defect after revascularization was considered. However, the vascular surgeon decided against revascularization because of the high risk of a rapid spread of infection after

improved blood flow, and peripheral lesions which would have a limited therapeutic effect. Therefore, a conservative treatment was chosen.

Meropenem hydrate was administered, and daily washing, ointment treatment, and debridement were performed as needed until the inflammation improved. Antibiotics were de-escalated as needed, and vacuum-assisted closure (VAC) ULTA[®] (3M, Tokyo, Japan) was started one month after admission. Four weeks after starting VAC, granulation was somewhat raised and inflammation had improved; therefore, revascularization was reconsidered. However, anemia progressed, and close examination revealed multiple severe gastric ulcers. As a result,

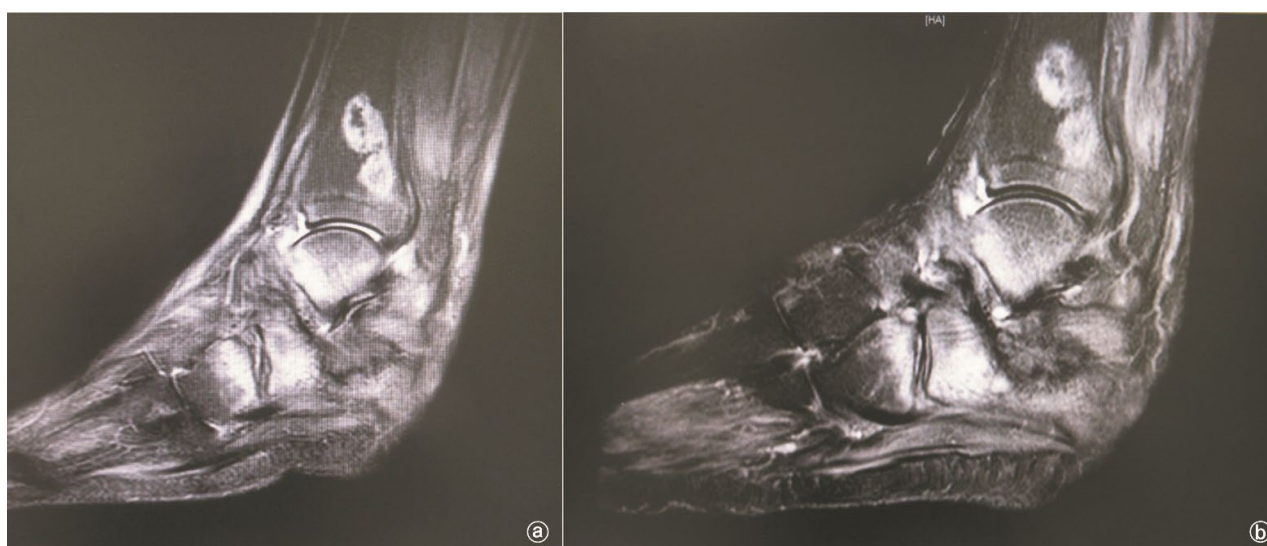

Figure 2: (a) Computed tomography angiography before Rheocarna treatment showing severe calcification and stenosis of the left below-knee arteries. (b) Computed tomography angiography after Rheocarna treatment showing improved blood flow

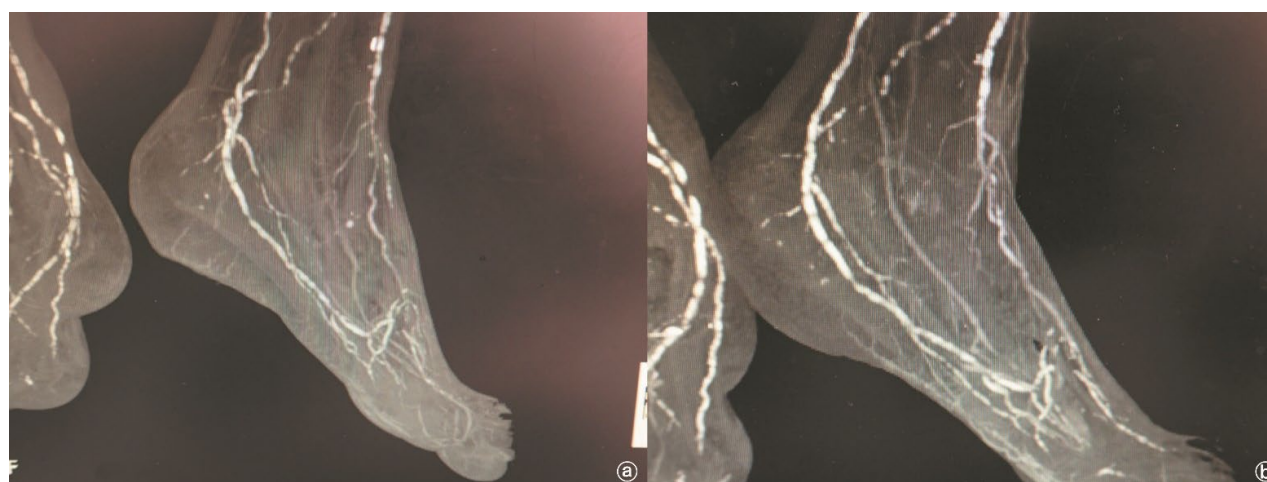


Figure 3: (a) MRI STIR before Rheocarna treatment shows osteomyelitis progressing to the distal end of the tibia and cuboid bone. (b) MRI STIR after Rheocarna treatment shows no exacerbation of osteomyelitis.

MRI; Magnetic Resonance Imaging

antiplatelet medication could not be administered, and revascularization was postponed. After three months of hospitalization, the granulation was sufficiently raised, and a split-thickness skin graft was performed. However, the grafted skin did not take well and was partially necrotic (Fig. 1c). A moderate increase in the inflammatory response was observed, and redness, heat sensation, and pain in the lower extremities began to flare. MRI showed osteomyelitis had progressed to the distal end of the tibia and cuboid bone (Fig. 3a), and wound healing and inflammation control were difficult. Therefore, four months after admission, we started rheocarna treatment to improve the peripheral circulation and delivery of antibiotic drugs to the infected sites.

About two weeks after the start of rheocarna treatment, CRP tested negative, ulcer epithelialization was observed, and redness, heat sensation, and pain in the lower extremities improved (Fig. 1d). One month after initiating treatment, CTA and SPP improved markedly (Fig. 1d, 2b), and MRI showed no exacerbation of the osteomyelitis (Fig. 3b). Chronological change of CRP after admission is shown in Fig. 1e. Inflammation remains under control, and the patient is continuing rehabilitation for walking.

Written informed consent was obtained from the patient.

DISCUSSION

In Japan, blood purification therapy is widely used, in addition to vascular bypass and EVT, in patients with ASO. This treatment is intended to improve peripheral blood flow by removing specific proteins from the blood via extracorporeal circulation. Plasma purifiers such as Selesorb® and Liposorber® are available for patients with ASO⁹. However, their sole purpose is to adsorb LDL-C in patients with refractory hypercholesterolemia. Therefore, hypercholesterolemia is a prerequisite for using these devices; specialized equipment, such as a plasma separator, is also necessary. Liposorber is used outside Japan; however, it is not widely used in the U.S. because it requires high lipoprotein (a) in addition to high LDL cholesterol¹⁰. In Europe, Liposorber is indicated only for familial hypercholesterolemia¹¹ but is not widely used due to the medical insurance system.

Rheocarna is a new blood purifier approved in 2020;

it was covered by insurance in 2021. The rheocarna uses dextran sulfate and tryptophan on internal cellulose beads to absorb LDL-C and fibrinogen, respectively, thereby improving peripheral vascular fluidity and contributing to wound healing⁶⁻⁸. It is indicated for ASO patients with ulcers that are not amenable to revascularization, with no limits to hypercholesterolemia or special equipment requirements. Clinical trials have shown healing effects in refractory ulcers⁶, and improved peripheral circulation has been reported in patients with occluded bypass grafts¹². However, clinical trials have not included patients with ulcers more proximal to the Lisfranc joint or osteomyelitis more proximal to the metatarsal bones. In the presence of osteomyelitis, the rheocarna should be used cautiously because improved blood flow may lead to the spread of infection. No reports are published on the use of the rheocarna in patients with osteomyelitis or cellulitis.

Improved blood flow after revascularization can exacerbate infection, especially if the CRP level is more than 4 mg/dL, easily leading to the spread of infection¹³. Therefore, controlling local infections using debridement is important before revascularization. With its ability to improve peripheral perfusion, rheocarna may be associated with an increased risk of infection exacerbation. The use of a rheocarna in a highly inflammatory state is likely to result in severe sepsis¹⁴. Therefore, we used the rheocarna after a moderate inflammatory response. In this case, we were able to improve peripheral blood flow and reduce inflammation without any exacerbation of infection after using the rheocarna. This result may be because, unlike revascularization, rheocarna treatment gradually improves peripheral blood flow, improving the delivery of antibiotic drugs without spreading infection.

In the present study, when we used rheocarna to treat a refractory heel ulcer that was not amenable to revascularization and was complicated by moderate osteomyelitis and cellulitis, the ulcer was completely epithelialized and inflammation was controlled. Rheocarna treatment may improve peripheral blood flow and control inflammation by improving the delivery of antibiotics. We hope that rheocarna will be widely used as a novel and effective treatment for patients with ASO unsuitable for revascularization.

Declaration of Conflicting Interests

The author(s) declared no potential conflicts of interest with respect to the research, authorship, and/or publication of this article.

Funding

The author(s) received no financial support for the research, authorship, and/or publication of this article.

REFERENCES

1. Michael SC, Andrew WB, Philippe K, et al. Global vascular guidelines on the management of chronic limb-threatening ischemia. *J Vasc Surg* 2019;**69**:3S-125S.e40.
2. Kobori M, Oiwa K, Yagi H, et al. A case in which CHDF was effective to reperfusion injury by the endovascular treatment to acute limb ischemia. *J Jpn Soc Blood Purif Crit Care* 2011;**2**:213-218.
3. Tsurumi-Ikeya Y, Tamura K, Azuma K, et al. Sustained Inhibition of Oxidized Low-Density Lipoprotein Is Involved in the Long-Term Therapeutic Effects of Apheresis in Dialysis Patients. *Arterioscler Thromb Vasc Biol* 2010;**30**:1058-1065.
4. Oda O, Nagaya T, Ogawa H. Analysis of protein absorbed by LDL column (Liposorber) with special reference to complement component factor D. *Clin Chim Acta* 2004;**342**:155-160.
5. Hara T, Kiyomoto H, Hitomi H, et al. Low-density lipoprotein apheresis for haemodialysis patients with peripheral arterial disease reduces reactive oxygen species production via suppression of NADPH oxidase gene expression in leucocytes. *Nephrol Dial Transplant* 2009;**24**:3818-3825.
6. Kobayashi S, Furukawa M, Ichioka S, et al. A novel low-density lipoprotein/fibrinogen apheresis method for chronic limb-threatening ischemia in patients with poor options for revascularization: a multicenter, single-arm clinical trial. *Ther Apher Dial* 2022;**27**:361-369.
7. Kojima S, Nakama T, Obunai K. Angiographic and clinical impact of novel low-density lipoprotein apheresis for no-option chronic limb-threatening ischemia. *Ther Apher Dial* 2022;**27**:186-187.
8. Nakamura Y, Kumada Y, Kawai N, et al. Rheocarna® therapy after distal bypass surgery. *SAGE Open Med* 2023;**11**:1-5.
9. Naganuma S, Agishi T, Miura A, et al. Hemorheological effect of LDL apheresis on atherosclerosis disease with hyperlipidemia. *Jpn J Artif Organs* 1992;**21**:1339-1343.
10. Waldmann E, Parhofer KG. Lipoprotein apheresis to treat elevated lipoprotein (a). *J. Lipid Res* 2016;**57**:1751-1757.
11. Taylan C, Weber LT. An update on lipid apheresis for familial hypercholesterolemia. *Pediatr Nephrol* 2023;**38**:371-382.
12. Satake A, Nakano Y, Amano T. Rheocarna® as an alternative therapeutic option for patients with chronic limb-threatening ischemia: A case report. *SAGE Open Med Case Rep* 2023;**11**:1-5.
13. Fujii M, Terashi H, Yokono K, et al. The Degree of Blood Supply and Infection Control Needed to Treat Diabetic Chronic Limb-Threatening Ischemia with Forefoot Osteomyelitis. *J Am Podiatr Med Assoc* 2021;**111**:18-185.
14. Krzysztof K, Krzysztof W, Tomasz K. Use of Negative Pressure Wound Therapy after Endovascular Revascularization in a Patient with Diabetic Foot Syndrome Complicated by Sepsis. *Negat. Press. Wound Ther J* 2015;**2**:8-12.