

# Two Cases of COVID-Related Osteonecrosis of the Jaws: A New and Worrying Entity Is Emerging

Ricardo Grillo <sup>1</sup>, Sahand Samieirad <sup>2\*</sup>, Omid Alizadeh <sup>3</sup>, Seyed Hossein Hosseini Zarch <sup>4</sup>,  
Rozita Khodashahi <sup>5</sup>, Navid Kazemian <sup>6</sup>, Maria da Graça Naclério-Homem <sup>1</sup>

1. 1 Department of Oral & Maxillofacial Surgery, Traumatology and Prosthesis – Faculty of Dentistry of the University of São Paulo, Brazil

2. Department of Oral & Maxillofacial Surgery, Mashhad Dental School, Mashhad University of Medical Sciences, Mashhad, Iran

3. Student Research Committee, Faculty of Dentistry, Mashhad University of Medical Sciences, Mashhad, Iran

4. Department of Oral and Maxillofacial Radiology, School of Dentistry, Mashhad University of Medical Sciences, Mashhad, Iran

5. Department of Infectious Diseases and Tropical Medicine, Faculty of Medicine, Mashhad University of Medical Sciences, Mashhad, Iran

6. Dental Research Center, Mashhad Dental School, Mashhad University of Medical Sciences, Mashhad, Iran

## ABSTRACT

Many people were affected by COVID-19 in its severe form. Some interurrences are still emerging. We here report two cases of COVID-related osteonecrosis of the jaws (CRONJ). Two retrospective cases were admitted into Imam Reza Hospital, Mashhad, Iran with suspected CRONJ. One patient escaped from hospital while the other showed a positive result after our proposed treatment. A new aftermath to COVID-19 infections is emerging. Maxillofacial and orthopedic surgeons should be aware of this situation. CRONJ should be on the suspect list in patients with COVID-19. Measures that are useful in the treatment carried out, as well as some measures recommended in the literature, were discussed. Surgical treatment of CRONJ appears to be an effective alternative, especially in the more aggressive cases.

## KEYWORDS

Osteonecrosis; Jaw; COVID-19; Platelet-Rich Fibrin; Platelet-Rich Plasma; Oral Pathology

## Please cite this paper as:

Grillo R, Samieirad S, Alizadeh O, Hosseini Zarch SH, Khodashahi R, Kazemian N, da Graça Naclério-Homem M. Two Cases of COVID-Related Osteonecrosis of the Jaws: A New and Worrying Entity Is Emerging. *World J Plast Surg.* 2024;13(1):96-102.

doi: 10.61186/wjps.13.1.96

## INTRODUCTION

The COVID-19 pandemic has changed the world as we know it. Social withdrawal, episodes of widespread stress and anxiety, in addition to multiple deaths from the viral or other opportunistic infection. Economic crisis affecting many countries around the world <sup>1</sup>. Even prosperous regions are suffering the catastrophic effects of this disease. It is still unclear why some countries have suffered more cases and more deaths than others. Brazil and Iran stood out negatively in this frequency <sup>2,3</sup>. Science has advanced at a speed never seen to develop vaccines that could control the situation. The COVID-19 pandemic was finally under control and the world was able to return to so-called normality.

However, there was no telling what COVID would have in store for us in the future. It was not known whether there could be any side effects or interactions in the meantime. But was not long after we left what was considered the zone of greatest risk that the side effects of COVID hit. Multiple cases of anosmia causing depression and suicidal thoughts, memory deficits causing a range of daily problems, macroglossia and

## \*Corresponding Author:

Sahand Samieirad

Department of Oral & Maxillofacial Surgery, Mashhad Dental School, Mashhad University of Medical Sciences, Mashhad, Iran.

Email: [samieirads@mums.ac.ir](mailto:samieirads@mums.ac.ir)

Received: 11/22/2023

Accepted: 3/21/2024

many others that we have to live with, at least for a while, while the answers do not come <sup>4</sup>. These consequences include musculoskeletal changes. There have been some reports of avascular necrosis and septic arthritis, primarily in the knee and hip <sup>5-7</sup>, and some maxillofacial episodes <sup>8</sup>.

Unfortunately, these are new situations. Researchers and surgeons are looking for answers to control these diseases with a minimal or no consequences for the patients. Therefore, the purpose of the present work is to report two cases of suspected CRONJ that occurred in the same Oral and Maxillofacial Surgery Department. One of the treatment alternatives with platelet-rich fibrin has been vigorously discussed.

## CASE REPORT

This is a retrospective case report according to the recommendations of the CARE guideline <sup>9</sup>. The authors studied two patients with suspected COVID-19 associated osteonecrosis of the jaws (CRONJ) at Imam Reza Hospital, Mashhad, Iran. Both were treated according to the guidelines of Good Clinical Practice and the principles of the Declaration of Helsinki.

### Case 1

A 46-year-old male patient was referred from Iraq for a maxillofacial consultation. The patient complained of severe pain in the maxillofacial are,

specifically in the middle third of the right face. In the medical story, he denied any kind of trauma or chronic comorbidities. He was not taking any long-term medication. The intraoral examination showed a loss of substance with exposed bone in the right maxillary premolar area of approximately 1,5 x 1 cm in length (Fig. 1).

It showed a necrotic aspect with irregular edges. There was no collection spontaneous drainage, but it had a putrid odor and was quite painful. The tomographic examination shows a change in the bone structure of the right upper jaw, which extends to the area of the palatal raphe, and veiling of the right maxillary sinus (Fig. 2).

The patient underwent local biopsy resulting in chronic osteomyelitis with focal abscess formation. The local bone tissue had a dense lymphoplasmatic and neutrophilic infiltrate. Suspecting an injury, the professionals decided to take a more vigorous approach and gathered more information about the patient's general health. During this second history, the patient called having had COVID-19 6 months prior to the onset of the lesion. He reported that he was hospitalized and received many medications, including hydroxychloroquine and high-dose dexamethasone for two months.

The first diagnostic hypothesis was CRONJ. Exploratory surgery with local surgical debridement to remove necrotic bone tissue and revascularize the region has been suggested. Disagreeing with the team's decision, the patient eventually escaped the hospital center without receiving any treatment.

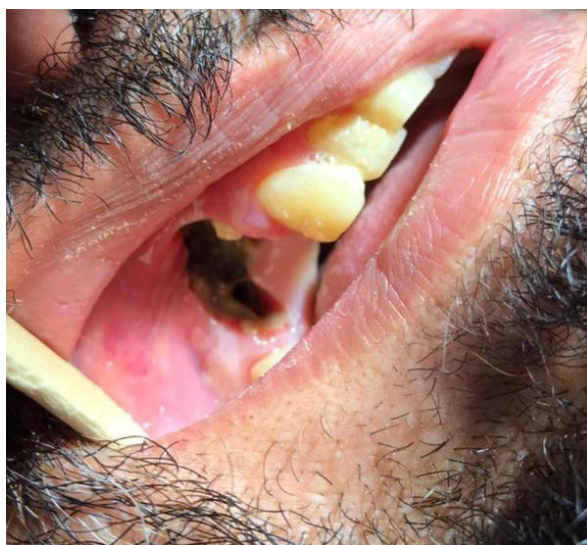

Figure 1: Clinical aspect of patient 1 CRONJ

### Case 2

A 40-year-old female patient from Iran was referred to Mashhad Hospital Center the same week as the previous patient. Complaints were the same, a severe pain in the right maxillofacial region, unrelated to previous trauma. Physical examination revealed bone exposure, approximately 0.5 cm in diameter, with no purulent collection, in the root area of the maxillary right premolars (Fig. 3).

Patient with excellent oral hygiene, with complete upper and lower teeth. The tomographic examination showed a veiling of the right maxillary sinus with a change in the skeleton in the maxillo-zygomatic region.

In the medical history, the patient denied any

comorbidity and was not taking any long-term medication. As with the other patient, the only reported health change reported was that she had contracted COVID-19 in the previous 6 months. The more enlightened patient reports that she was hospitalized for a period of 3 months and had taken high doses of corticosteroids during her stay. Additionally, due to aggressive pulmonary involvement of COVID-19, the patient was taking imipenem, colistin, and meropenem.

A local biopsy returned an osteomyelitis result with no fungal involvement. With this information, CRONJ was suspected. The case was discussed with the patient. She accepted the proposal of a sequestrectomy and revascularization under local anesthesia. Due to the significant loss of support, six

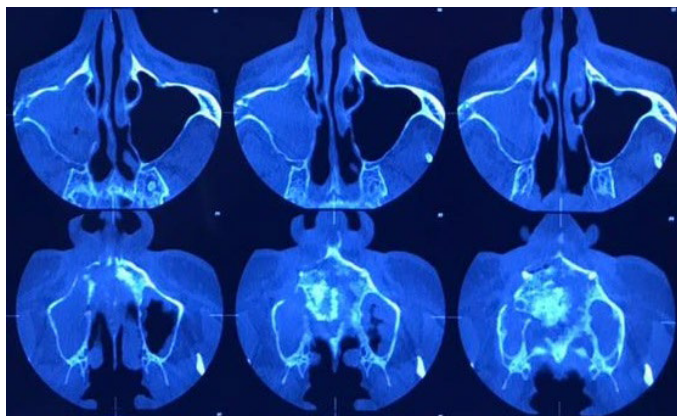


Figure 2: Tomographic aspect of patient 1 CRONJ

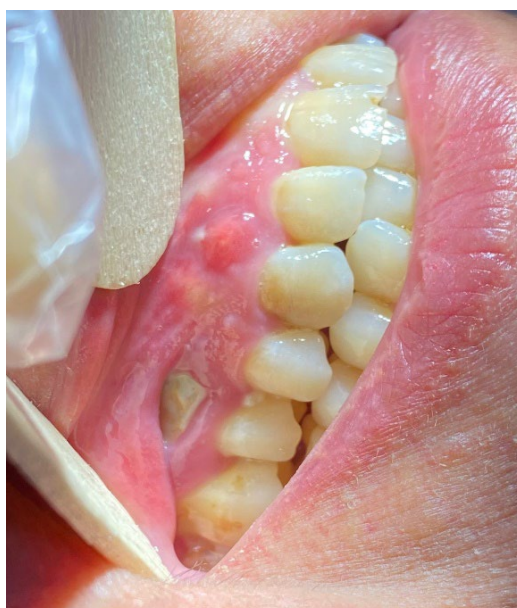

Figure 3: Clinical aspect of patient 2 CRONJ

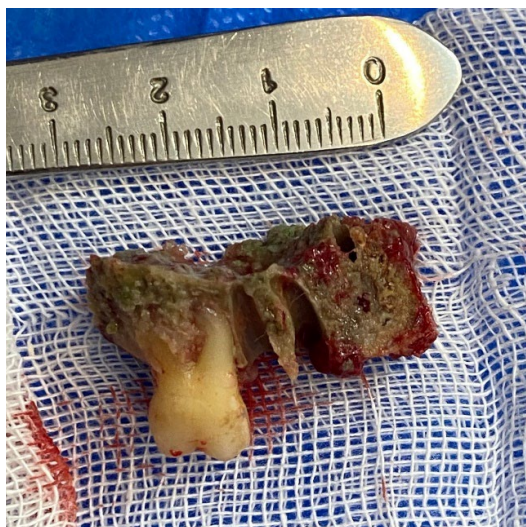


Figure 4: Sequestrectomy performed

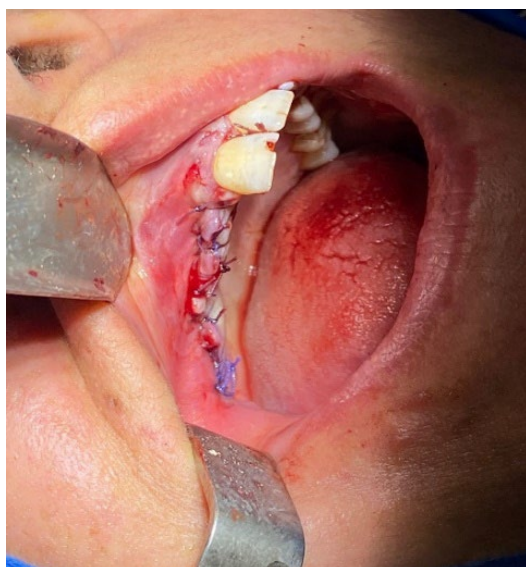

Figure 5: Immediate postsurgical aspect

teeth in the region had to be removed. A fragment as long as three teeth required no effort to remove (Fig. 4).

To speed up the local repair process, a platelet-rich fibrin (PRF) clot was added before the occlusive suture (Fig. 5). The patient has since been discharged and is symptom-free. Awaiting local recovery and probable prosthetic rehabilitation. The patient is followed weekly.

## DISCUSSION

Despite a high number of articles on osteonecrosis of the jaws, there are still few publications that

have described COVID-19 as an etiologic factor. One case was reported in Houston (USA) <sup>8</sup>, one in Sofia (Bulgaria) <sup>10</sup>, two cases in Sari (Iran) <sup>11</sup>, four cases in Tashkent (Uzbekistan) <sup>12</sup>, and a multicenter case series of 12 cases across Egypt <sup>13</sup>. All cases, including those reported here, had at least one comorbidity related to COVID-19. Twelve patients were hospitalized due to severe COVID-19 infection (63.15%). Only the Iranian patients showed an association between mucormycosis and CRONJ <sup>11</sup>. The majority of patients presenting CRONJ (89.47%), with the exception of one for whom information was unclear <sup>10</sup>, were taking corticosteroids. Those who were hospitalized, the

prescription was injectable and those who stayed at home the prescription was oral. The number of reports of CRONJ in other bones is slightly higher. Most notably knee<sup>6,7,14,15</sup>, hip<sup>14,16</sup>, femoral head<sup>16-20</sup>, and spine<sup>21</sup>. General musculoskeletal manifestations have also been reported<sup>22-24</sup>.

Prescribing corticoids is critical for pulmonary damage in severe COVID-19 cases. Unfortunately, however, their inappropriate and excessive use leads to an increase in cases of osteonecrosis<sup>25-27</sup>. There is clear evidence that prolonged use and cumulative doses of corticosteroids are associated with changes in bone homeostasis<sup>26, 28, 29</sup>. Glucocorticoids significantly alter the function of osteoblasts and osteoclasts in addition to mineral metabolism, drastically altering bone density and leading to changes such as osteonecrosis and osteoporosis<sup>10, 13, 26, 28</sup>. Some pre-COVID-19 comorbidities have an increased risk of CRONJ, most notably diabetes<sup>11-13, 27, 28</sup>. Vascular changes due to diabetes or other comorbidities considerably increase the risk of CRONJ<sup>8</sup>. The ambiguous outcomes observed in these cases may stem from a confluence of factors, including potential involvement of CRONJ, heightened corticosteroid utilization exceeding recommended thresholds, and a compromised immune system that collectively contribute to the intricate clinical picture.

Besides corticosteroids, other drugs commonly used in COVID-19 treatment such as tocilizumab and denozumab have been associated with medication-related osteonecrosis of the jaws (MRONJ)<sup>10, 12, 13</sup>. Even anticholesterol drugs are suspected to be involved<sup>30, 31</sup>. The role and mechanism of action of these drugs in MRONJ are still unclear. Differential diagnosis of CRONJ must be included in suspected MRONJ, osteoradionecrosis or osteomyelitis.

The recommendation available in the literature is to investigate all reports of discomfort, especially joint pain, as soon as possible<sup>26</sup>. Laboratory tests are mandatory and include blood calcium, phosphate, vitamin D, parathyroid hormone, blood count, and bone mineral density<sup>8, 26</sup>. An increased daily intake of calcium (1,000 mg) and vitamin D (600-800 IU). Although many of these recommendations relate to changes in long bone, the authors believe that they should be followed when dealing with maxillofacial disorders.

The maxilla showed a much higher incidence of CRONJ, in the literature and in this report. Some

authors suggest that sinusitis-induced osteomyelitis is the starting point for the development of CRONJ<sup>13</sup>. The use of the name “spontaneous” should be avoided as there is always a trigger for osteonecrosis<sup>13</sup>. In many cases, the original cause is difficult to detect, which does not make this pathology a spontaneous event.

The treatment option must be selected according to the CRONJ extension. Sequestrectomy is considered the treatment of choice for more aggressive cases<sup>8, 10</sup>. Spreading of osteonecrosis to other regions should be avoided, which makes treatment and subsequent rehabilitation even more difficult. Although considered aggressive by some authors, it is necessary damage control in many cases. Conservative alternatives such as local cleaning, antibiotics prescription and regular debridement may be helpful in milder cases<sup>10</sup>. Thromboprophylaxis may be helpful in more extensive situations<sup>8, 12</sup>. Close and constant monitoring is mandatory in all cases. Future randomized clinical trials are needed to evaluate the actual effectiveness of aggregates in bone repair in CRONJ. Another clear limitation of the present work is the number of cases. Further studies with larger casuistic are needed to assess whether the proposed treatment for CRONJ reported here can be considered the most efficient.

## CONCLUSION

If osteonecrosis of the jaws is suspected, a possible secondary disease of COVID-19 should be clarified quickly. The use of adjunctive therapies to sequestrectomy appears to positively affect the outcome.

## ACKNOWLEDGMENTS

The authors appreciate the continued support of the Research Counselor of Mashhad University of Medical Sciences.

## CONFLICTS OF INTEREST

None.

## FUNDING

None.

## REFERENCES

- Zandifar A, Badrfam R. Fighting COVID-19 in Iran; economic challenges ahead. *Arch Iran Med* 2020;**23**(4):284.
- Samadi AH, Owjimehr S, Halafi ZN. The cross-impact between financial markets, Covid-19 pandemic, and economic sanctions: The case of Iran. *Journal of policy modeling* 2021;**43**(1):34-55.
- Schall B, Gonçalves FR, Valente PA, et al. Gender and Food insecurity in the COVID-19 pandemic in Brazil: hunger through women's voices. *Ciência & Saúde Coletiva* 2022;**27**:4145-54.
- Mañón VA, Chubb D, Farach LS, et al. Massive macroglossia, a rare side effect of COVID-19: clinical, histologic, and genomic findings in COVID-19-positive versus COVID-19-negative patients. *Oral Maxillofac Surg* 2022;**26**(4):613-8.
- El Ashmawy A-AH, Dowson K, El-Bakoury A, Hosny HA, Yarlagadda R, Keenan J. Effectiveness, patient satisfaction, and cost reduction of virtual joint replacement clinic follow-up of hip and knee arthroplasty. *The Journal of Arthroplasty* 2021;**36**(3):816-22. e1.
- Agarwala SR, Vijayvargiya M, Sawant T. Secondary osteonecrosis of the knee as a part of long COVID-19 syndrome: a case series. *BMJ Case Reports CP* 2022;**15**(3):e248583.
- Malinowski K, Skowronek P, Hirschmann M, et al. Transient spontaneous osteonecrosis of the knee (SONK) shortly after SARS-CoV-2 infection: A report of 2 cases. *Advances in Clinical and Experimental Medicine* 2022;**31**(9):1035-41.
- Mañón VA, Balandran S, Young S, Wong M, Melville JC. COVID-Associated Avascular Necrosis of the Maxilla—A Rare, New Side Effect of COVID-19. *J Oral Maxillofac Surg* 2022;**80**(7):1254-9.
- Gagnier JJ, Kienle G, Altman DG, Moher D, Sox H, Riley D. The CARE guidelines: consensus-based clinical case reporting guideline development. *Global advances in health and medicine* 2013;**2**(5):38-43.
- Slavkova N, Nedevska M. Aseptic osteonecrosis of the maxilla after severe COVID-19 infection and its treatment. *Radiology Case Reports* 2022;**17**(9):3228-32.
- Fakhar M, Zakariaei Z, Sharifpour A, et al. Post-COVID-19 maxillary osteonecrosis and floating maxillary teeth due to mucormycosis in two uncontrolled diabetic patients. *Clinical Case Reports* 2022;**10**(3):e05502.
- Boymuradov SA, Rustamova DA, Bobamuratova DT, et al. Complications of COVID-19 in the maxillo-facial region: Clinical case and review of the literature. *Advances in Oral and Maxillofacial Surgery* 2021;**3**:100091.
- Al-Mahalawy H, El-Mahallawy Y, Dessoky NY, et al. Post-COVID-19 related osteonecrosis of the jaw (PC-RONJ): an alarming morbidity in COVID-19 surviving patients. *BMC Infect Dis* 2022;**22**(1):544.
- Jain S, Sawant T. Osteonecrosis with Concomitant Bacterial Osteomyelitis of Both Hips and a Knee in a Post-COVID-19 Patient: A Case Report. *JBS Case Connector* 2022;**12**(1):e21.
- Angulo-Ardoy M, Ureña-Aguilera Á. Knee osteonecrosis after COVID-19. *Fam Pract* 2021;**38**(Supplement\_1):i45-i7.
- Ardakani MV, Parviz S, Ghadimi E, et al. Concomitant septic arthritis of the hip joint and femoral head avascular necrosis in patients with recent COVID-19 infection: a cautionary report. *J Orthop Surg Res* 2022;**17**(1):302.
- Dhanasekararaja P, Soundararajan D, Kumar KS, Pushpa B, Rajkumar N, Rajasekaran S. Aggressive presentation and rapid progression of osteonecrosis of the femoral head after COVID-19. *Indian J Orthop* 2022;**56**(7):1259-67.
- Thannheimer A, von Rüden C. Aseptic osteonecrosis of the medial femoral condyle in a patient with acute SARS-CoV-2 infection. *Unfallchirurgie (Heidelberg, Germany)* 2021;**125**(8):664-6.
- Zhang S, Wang C, Shi L, Xue Q. Beware of steroid-induced avascular necrosis of the femoral head in the treatment of COVID-19—Experience and lessons from the SARS epidemic. *Drug Des Devel Ther* 2021:983-95.
- Huang Z, Fu F, Ye H, et al. Chinese herbal Huo-Gu formula for the treatment of steroid-associated osteonecrosis of femoral head: a 14-year follow-up of convalescent SARS patients. *Journal of orthopaedic translation* 2020;**23**:122-31.
- Sulewski A, Sieroń D, Szyluk K, et al. Avascular necrosis bone complication after active COVID-19 infection: preliminary results. *Medicina* 2021;**57**(12):1311.
- Jeyaraman M, Selvaraj P, Jeyaraman N, Shivashankar PG, Muthu S. Assessment of risk factors in post-COVID-19 patients and its associated musculoskeletal manifestations: a cross-sectional study in India. *Journal of Orthopaedics* 2022;**33**:131-6.
- Bagaria V. Usual and unusual musculoskeletal sequelae of COVID 19! *Indian J Orthop* 2021;**55**(Suppl 2):518-9.
- Disser NP, De Micheli AJ, Schonk MM, et al. Musculoskeletal consequences of COVID-19. *The Journal of bone and joint surgery American volume* 2020;**102**(14):1197.
- Tang C, Wang Y, Lv H, Guan Z, Gu J. Caution against corticosteroid-based COVID-19 treatment. *The Lancet* 2020;**395**(10239):1759-60.
- Tang J. What can we learn about corticosteroid

- therapy as a treatment for COVID-19? *Osteoporos Int* 2020;**31**(8):1595-.
27. Asim MA. Risk of invasive fungal infections and osteonecrosis of jaw in patients exposed to current therapeutic drugs for COVID-19. *J Coll Physicians Surg Pak: JCPSP* 2021;**31**(7):150-1.
  28. Shetty GM. Double Trouble—COVID-19 and the Widespread Use of Corticosteroids: Are We Staring at an Osteonecrosis Epidemic? *Indian J Orthop* 2021:1-11.
  29. Zhang B, Zhang S. Corticosteroid-induced osteonecrosis in COVID-19: a call for caution. *J Bone Miner Res* 2020;**35**(9):1828-9.
  30. Samieirad S, Labafchi A, Famili K, Hashemzadeh H. Medication-Related Osteonecrosis of the Jaw (MRONJ) due to simvastatin: an unusual case report. *World Journal of Plastic Surgery* 2021;**10**(1):132.
  31. Giladi HZ, Gabay E, Machtei EE. Medication-Related Osteonecrosis of the Jaw in Patients Taking High-Dose Simvastatin. *J Oral Maxillofac Surg* 2020;**78**(6):862-3.