

Pharyngoesophageal Reconstruction with A Tubed Radial Forearm Free Flap: A Case Report

Lugo Beltran Ignacio, Guitian González Marisol, Ornelas-Flores María Cristina, Uribe Briceño David Armando, Delcid Morazán Allan Fernando*

1. Plastic and Reconstructive Surgery
Department at Centro Medico Nacional
20 de Noviembre, Mexico City, Mexico

ABSTRACT

Hypopharyngeal carcinoma is one of the most aggressive primary head and neck cancers, often managed through partial or total laryngopharyngectomy. Reconstruction after such surgeries remains a challenging procedure that often requires the use of free flaps. A 63-year-old male patient with in-situ squamous cell carcinoma of the left vocal cord treated with total pharyngolaryngectomy and primary reconstruction with a left radial forearm free flap, complicated by flap necrosis, which ended up in dismantling and gastrostomy. He was referred to the Plastic and Reconstructive Surgery Department at Centro Medico Nacional 20 de Noviembre, Mexico in 2023 to assess the reconstructive options for the hypopharynx and cervical esophagus defect. A tubular right radial forearm free flap was designed forming the anterior wall of the hypopharynx and cervical esophagus and a posterior wall for the external defect. Twelve months after his surgery, he continues tolerating oral intake without signs of stenosis or tumor recurrence. The objective in this case was based on restoring the continuity of the digestive tract and swallowing function, as well as providing skin coverage of the defects, and preventing serious complications. The radial forearm free flap has versatility in the tubular construction and a low leak rate, as well as an adequate skin island size. Conclusion: The pharyngoesophageal reconstruction with a tubed forearm free flap has favorable outcomes for restoring the gastrointestinal tract without further complications.

KEYWORDS

Total laryngopharyngectomy; Pharyngoesophageal reconstruction; Radial forearm free flap

Please cite this paper as:

Ignacio LB, Marisol GG, Cristina OFM, Armando UBD, Fernando DMA. Pharyngoesophageal Reconstruction with A Tubed Radial Forearm Free Flap: A Case Report. *World J Plast Surg.* 2024;13(2):77-81.
doi: 10.61186/wjps.13.2.77

*Corresponding Author:

Allan Fernando Delcid Morazán

Department: Plastic and Reconstructive Surgery at Centro Medico Nacional 20 de Noviembre

Address: Felix Cuevas 540, Col del Valle Sur, Benito Juarez, 03104, México City

Tel.: +52 55 5200 5003
(Ext. 14649)

Email: allanferdelcid@gmail.com

Received: 1/22/2024
Accepted: 5/27/2024

INTRODUCTION

Hypopharyngeal carcinoma is one of the most aggressive primary head and neck cancers, characterized by a 5-year overall survival rate ranging from 25% to 40%. Surgical resection continues to be the therapeutic gold standard, including partial or total hypopharyngectomy with or without laryngectomy, accompanied by radiotherapy¹. Reconstruction after laryngectomy secondary to hypopharyngeal carcinoma remains a challenge.

The ideal reconstructive technique for such defects which often involve

the cervical esophagus, should be the one that ensures the lowest morbidity, especially in terms of fistula, stricture, and mortality rates, as well as the most rapid and efficient rehabilitation². Several flap options, including free (anterolateral thigh, radial forearm, jejunum) and pedicled flaps (pectoralis major, supraclavicular), have been used for reconstruction of hypopharyngeal defects. Radical surgery for advanced disease, cancer recurrence, or prior chemoradiotherapy introduces additional complexity, often resulting in extensive defects. Excessive scarring and hypovascularization of the tissues compromise the quality of the soft tissues surrounding the neck. In this scenario, additional vascularized tissue is required for coverage of the anterior neck region and to restore continuity of the digestive system³.

There is no universal agreement as to the optimal reconstruction method as different options have well known advantages and disadvantages⁴. The fabricated radial flap helps restore the swallowing process, allowing a relatively smooth passage of food. Initially, stricture of the esophageal anastomosis may be experienced due to scar contracture at the skin-mucosa interface, but this problem is resolved by crimping the esophageal suture line of the flap. The large vessel caliber of the flap facilitates the selection of suitable recipient vessels and ensures microvascular anastomosis, unlike other skin flaps. The recipient vessels are relatively large vessels, such as the facial, lingual, superior thyroid, and superficial cervical arteries, and the external jugular, facial, and superficial cervical veins⁵.

We present the case of a male 60 yr patient with laryngopharyngectomy sequelae reconstructed using a tubed radial forearm free flap.

CASE PRESENTATION

In the year of 2018, a 63-year-old male patient with a personal history of colon cancer, began 5 years prior to his evaluation with dysphonia and progression to low-pitched aphonia, for which he was evaluated by otorhinolaryngology. The laryngoscopy showed hypertrophic ventricular bands, exophytic, verrucose, pink and digitiform lesions, glottic lumen at 40% and the left vocal cord with an irregular edge. A biopsy was performed which reported in situ squamous cell carcinoma of the left vocal cord. First line of treatment was CO2 laser

laryngeal microsurgery. Three years later, recurrent mass growth was evident. A biopsy reported well-differentiated, keratinizing, invasive carcinoma. Treatment involved 15 cycles of radiotherapy followed by total pharyngolaryngectomy with free margins in addition to primary reconstruction with a left radial forearm free flap, complicated by flap necrosis which ended up in dismantling and gastrostomy. He was referred to the Plastic and Reconstructive Surgery department at Centro Medico Nacional 20 de Noviembre to assess the reconstructive options for the hypopharynx and cervical esophagus defect.

In the year of 2023 upon admission, the physical examination revealed a 20.3 BMI, permeable tracheostomy, a skin defect of 10 x 8 cm, a hypopharynx defect of 3 x 3 cm and an esophageal defect of 3 x 3 cm, with perilesional maceration and significant fibrosis (Figure 1). Right thoracic limb with adequate radial pulse, positive Allen test. A Doppler ultrasound was performed revealing a patent right radial artery, with antegrade flow and preserved spectrum. The reconstructive choice was a right radial forearm free flap. The patient signed informed consent for the surgical procedure and photoshooting of the clinical case.

During the procedure, the absence of the left internal jugular vein was found, the left superior thyroid artery and lingual artery were dissected, as well as the external jugular vein and the posterior edges of the hypopharynx were dissected (Figure 2A), ischemia of the right thoracic limb began and a 10 x 10 cm radial forearm flap was designed, the radial artery was dissected distally and subsequently between the brachioradialis and the flexor carpi radialis. The radial vessels were proximally referred, proximal and distal vessels were ligated (Figure 2B). A tubular flap was designed with an anterior and posterior wall, forming the anterior wall of the hypopharynx and cervical esophagus and a posterior wall for the external defect. End-to-end anastomosis of the radial artery and vein to the facial artery and vein respectively was performed with 9-0 nylon suture, adequate patency and integrity of anastomosis was confirmed (Figure 2C). Subsequently, the previously designed flap was placed and fixed with 4-0 monocryl for the posterior wall, and 3-0 nylon for the anterior wall to offer skin coverage (Figure 3A). A partial thickness skin graft was harvested and applied to the donor site on the right forearm and

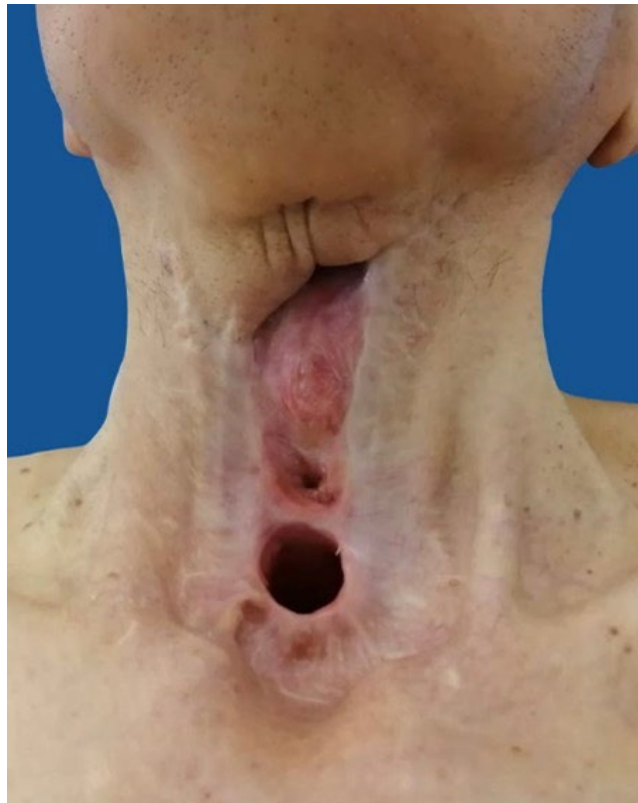


Figure 1: Hypopharyngeal defect with an esophageal stoma and permeable tracheostomy

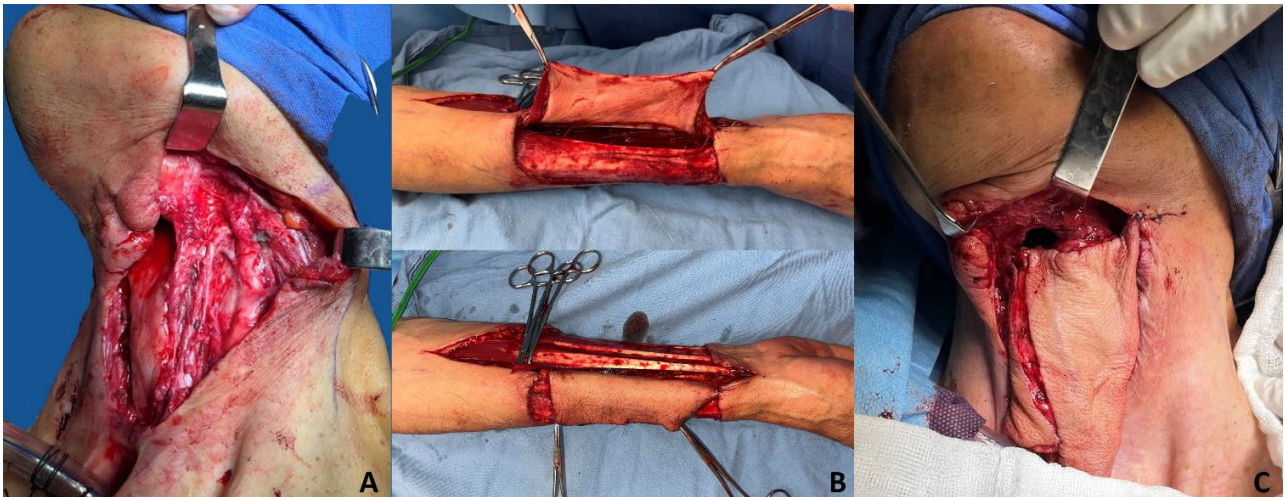


Figure 2: Surgical sequence (A) left cervical dissection at recipient site, (B) tubed right radial forearm free flap design (C) tubed free flap placement

then covered with cotton as a tie-over, a tension-free neck bandage was placed.

The patient was strictly monitored during the first week of hospitalization, maintaining adequate capillary refill, turgor, and coloration. He was discharged from the hospital with outpatient follow up two weeks later. A liquid test was performed

without evidence of leakage. The patient progressed to semi-solids and solid food at home, gaining 20 kg with subsequent removal of the gastrostomy tube (Figure 3B). Eighteen months after his surgery, he continues tolerating oral intake without signs of stenosis or tumor recurrence, however, he continues multidisciplinary follow-up (Figure 3C).

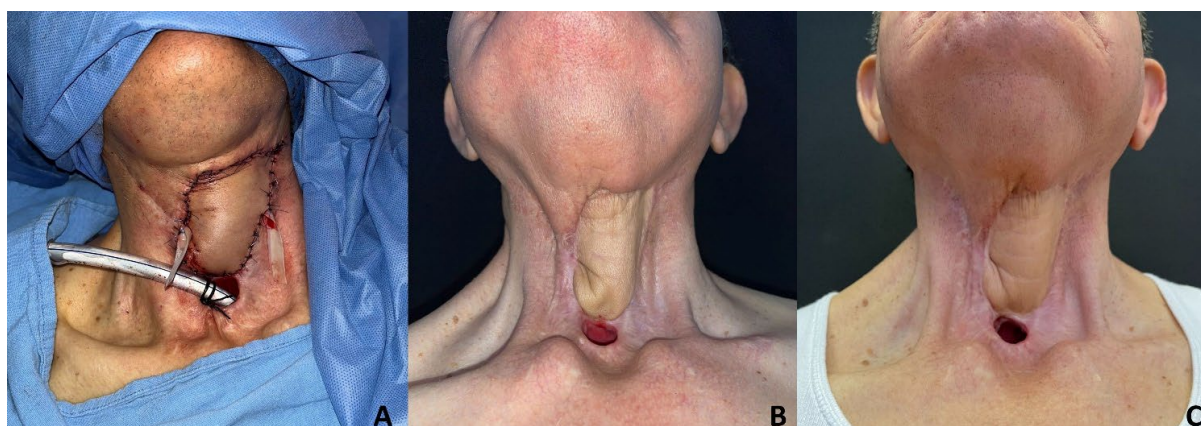


Figure 3: (A) Immediate post op, (B) 3 months post op, (C) 12 months post op

DISCUSSION

The reconstruction of large defects in the head and neck after oncologic resection is challenging. Different reconstruction methods are used depending on the location, size of the defect, and the judgment of the reconstruction team in charge. For reconstruction of hypopharyngeal and cervical esophageal defects pedicled pectoralis muscle flaps are the preferred reconstructive option. Another choice are free flaps with donor sites such as the radial forearm flap, anterolateral thigh flap, or vascularized jejunum. Vascularized jejunal and radial forearm free flaps are an excellent reconstructive option for partial and total defects of the hypopharynx⁶. However, a fasciocutaneous flap has a better recover of phonation compared to a jejunal flap⁷.

The radial forearm free flap is a fundamental piece in reconstruction of the hypopharynx and laryngopharynx due to its anatomical reliability, versatility in the tubular construction and a low leak rate, as well as an adequate skin island size^{8,9}. The selection of the flap should be based on the size of the defect, the characteristics of the patient, the experience and skill of the surgeon, as well as the capacity of the institution in the management of free flaps before, during and after the surgery. In this case the abdominal flap options were ruled out due to the patient's surgical-oncological history. The final objective in this case was based on restoring the continuity of the digestive tract and swallowing function, as well as providing skin coverage of the defects, and preventing serious complications. Therefore, an area with limited morbidity was taken as the donor site that would allow the creation of a

thin tubular flap that would adapt to the dimensions of the anterior cervical region¹⁰.

The reported incidence of postoperative complications in the international literature is 37.4%, including necrosis, pharyngeal fistulas, incisional infections (both at the recipient and donor sites), wound dehiscence, and tubular stenosis. This incidence was reported in patients reconstructed with gastric lift, pedicled pectoralis flap, anterolateral thigh free flap and radial forearm free flap. The incidence of complications reported for radial forearm free flap is 20% to 50% of cases, the most common being fistulas and constriction during swallowing¹¹⁻¹³. The choice of reconstruction is multifactorial, however some literatures report slightly lower incidences of complications with the use of radial forearm free flaps, compared to other free and pedicled flap options¹⁴. In our patient, none of the complications described above occurred, with an adequate evolution of the flap up to eighteen months after the intervention.

CONCLUSION

The pharyngoesophageal oncological defects represent a complex scenario for the plastic surgeon. The circumferential free forearm radial flap is a useful and viable technique for the reconstruction of these defects following laryngopharyngectomy. The patient we presented had a favorable outcome without complications such as fistulae or stenosis of the digestive tract.

CONFLICT OF INTEREST

Authors have no conflicts of interest to declare.

REFERENCES

- Heng Y, Zhang D, Zhu X, et al. Hypopharynx reconstruction for primary hypopharyngeal carcinoma: a retrospective study and literature review. *Transl Cancer Res* 2021;**10**(7):3236-3247. doi:10.21037/tcr-20-2910
- Piazza C, Bon FD, Paderno A, Grammatica A, Montalto N, Taglietti V, et al. Fasciocutaneous free flaps for reconstruction of hypopharyngeal defects. *The Laryngoscope* 2017;**127**(12):2731-7. doi:10.1002/lary.26705
- Sharaf B, Xue A, Solari MG, et al. Optimizing Outcomes in Pharyngoesophageal Reconstruction and Neck Resurfacing: 10-Year Experience of 294 Cases. *Plast Reconstr Surg* 2017;**139**(1):105e-119e. doi:10.1097/PRS.0000000000002915
- Disa JJ, Pusic AL, Hidalgo DA, Cordeiro PG. Microvascular reconstruction of the hypopharynx: defect classification, treatment algorithm, and functional outcome based on 165 consecutive cases. *Plast Reconstr Surg* 2003;**111**(2):652-663. doi:10.1097/01.PRS.0000041987.53831.23
- Harii K, Ebihara S, Ono I, Saito H, Terui S, Takato T. Pharyngoesophageal reconstruction using a fabricated forearm free flap. *Plast Reconstr Surg* 1985;**75**(4):463-476. doi:10.1097/00006534-198504000-00001
- Somuk BT, Çiftçi O, Aygenç E. Evaluation of Cases Who Underwent Reconstruction Through Pectoralis Major Myocutaneous Flap after Laryngopharyngectomy. *Turk Arch Otorhinolaryngol* 2016;**54**(2):58-62. doi:10.5152/tao.2016.1603
- Richmon JD, Brumund KT. Reconstruction of the hypopharynx: current trends. *Curr Opin Otolaryngol Head Neck Surg* 2007;**15**(4):208-212. doi:10.1097/MOO.0b013e32825b0852
- Selber JC, Xue A, Liu J, et al. Pharyngoesophageal reconstruction outcomes following 349 cases. *J Reconstr Microsurg* 2014;**30**(9):641-654. doi:10.1055/s-0034-1376887
- Scharpf J, Esclamado RM. Reconstruction with radial forearm flaps after ablative surgery for hypopharyngeal cancer. *Head Neck* 2003;**25**(4):261-266. doi:10.1002/hed.10197
- Lasso JM, Castellano M, Pinilla C, González-Pozega C, Pérez-Cano R. Circumferential pharyngoesophageal reconstruction and total larynx preservation with extra-anatomical free flaps. *Plast Reconstr Surg Glob Open* 2018;**6**(11):e2008. doi:10.1097/gox.0000000000002008
- Marzouki H, Addas MA, Nujoom M, Zawawi F, Almarzouki HZ, Merdad M. Hypopharyngeal reconstruction: Possibilities, outcomes, and updates for improving the human health for quality of life. *Comput Intell Neurosci* 2022;**2022**:1-10. doi:10.1155/2022/6132481
- Welkoborsky H-J, Deichmüller C, Bauer L, Hinni ML. Reconstruction of large pharyngeal defects with microvascular free flaps and myocutaneous pedicled flaps. *Curr Opin Otolaryngol Head Neck Surg* 2013;**21**(4):318-327. doi:10.1097/moo.0b013e3283631ea2
- Van der Putten L, Spasiano R, de Bree R, et al. Flap reconstruction of the hypopharynx: a defect oriented approach. *Acta Otorhinolaryngol Ital* 2012;**32**(5):288-296. PMID: 23326007; PMCID: PMC3546404.
- Hong JW, Jeong HS, Lew DH, Roh TS, Tark KC, Choi EC, et al. Hypopharyngeal reconstruction using remnant narrow pharyngeal wall as omega-shaped radial forearm free flap. *J Craniofac Surg* 2009;**20**(5):1334-1340. doi:10.1097/scs.0b013e3181ae66a9