

Efficacy of Surgery-First Approach in the Management of Severe Skeletal Class III Malocclusion: A Case Report

Seyyed Hamidreza Aboutorabzadeh ¹, Mahboobe Dehghani ², Amirmohammad Moradpour ³, Iman Shiezadeh ³, Ashkan Golabkesh Afshar ¹, Sahand Samieirad ^{1*}

1. Department of Oral & Maxillofacial Surgery, Mashhad Dental School, Mashhad University of Medical Sciences, Mashhad, Iran
2. Department of Orthodontics, Mashhad Dental School, Dental Research Center, Mashhad University of Medical Sciences, Mashhad, Iran
3. Student Research Committee, Faculty of Dentistry, Mashhad University of Medical Sciences, Mashhad, Iran

ABSTRACT

The surgery-first approach (SFA) is gaining popularity in orthognathic surgery because it makes treatment duration shorter and more satisfying for patients. However, its effectiveness in complex cases isn't fully understood. Here, we describe a rare case where SFA was used to fix problems caused by missing posterior teeth and a deep bite, which made traditional pre-surgery orthodontic treatment impractical. A 34-year-old woman had facial asymmetry, bite issues, and trouble chewing due to a misaligned jaw. X-rays showed the problem, confirming that orthognathic surgery was needed. Planning for the surgery involved moving the upper jaw forward and the lower jaw backward, using specific bone-cutting techniques. The surgery, done with the patient under general anesthesia, went well. Orthodontic brackets were added during surgery which was aided by an orthodontist to make follow-up orthodontic treatment easier. The patient recovered uneventfully and saw improvements in how her face looked, how her teeth fit together, and how well she could chew. Later, more orthodontic work fine-tuned her bite, making sure the changes lasted and kept her satisfied. This case shows how combining orthodontics with the surgery-first method can be successful in orthognathic surgery. It brings benefits like shorter treatment times and immediate improvements in appearance. Our results match other recent studies that also found good outcomes with the surgery-first approach and quicker recovery times. While more research is needed, our case adds to the evidence that SFA can lead to successful orthognathic surgery results..

KEYWORDS

Orthognathic surgery; Surgery-first approach; Skeletal class III malocclusion

Please cite this paper as:

Aboutorabzadeh SH, Dehghani M, Moradpour A, Shiezadeh I, Golabkesh Afshar A, Samieirad S. Efficacy of Surgery-First Approach in the Management of Severe Skeletal Class III Malocclusion: A Case Report. *World J Plast Surg.* 2024;13(3):96-103.
doi: 10.61186/wjps.13.3.96

*Corresponding Author:

Sahand Samieirad

Department of Oral & Maxillofacial Surgery, Mashhad Dental School, Mashhad University of Medical Sciences, Mashhad, Iran

Email: samieerads@mums.ac.ir

Received: 10/5/2024

Accepted: 14/11/2024

INTRODUCTION

Orthodontic intervention preceding surgery was infrequent in the 1960s. Surgeons often performed orthognathic procedures either before orthodontic treatment or after removing orthodontic appliances ^{1, 2}. Consequently, the "surgery-first" approach was prevalent during this time. Building upon this, Worms et al. expanded the "orthodontics-first" principle to encompass all orthognathic cases, such as mandibular prognathism, mandibular retrognathism, and vertical skeletal

discrepancies involving anterior open bite or deep bite³. They emphasized the importance of eliminating all dental compensations before surgery for optimal jaw repositioning⁴. The orthodontics-first approach became the gold standard for orthognathic surgical treatment after the 1970s⁵. Dentofacial deformities, characterized by malocclusion, masticatory, phonetic, and respiratory challenges, typically undergo treatment in three phases: pre-operative orthodontics, orthognathic surgery, and post-operative orthodontics^{6,7}. While presurgical orthodontic procedures can yield satisfactory results, they are inherently slow and may induce masticatory discomfort and psychosocial issues due to delayed responses to patient concerns and exacerbation of facial profile discrepancies. This delay can lead to significant dissatisfaction and even patient dropout^{8,9}. Furthermore, the visibility of unattractive fixed appliances and the potential worsening of existing deformities at the dental and soft-tissue levels during the pretreatment phase, caused by decompensatory tooth movements, can amplify patient dissatisfaction and contribute to patients quitting therapy^{8,10,11}.

Recently, there has been a growing preference for the surgery-first approach (SFA) in orthognathic surgery, wherein orthognathic surgery precedes postsurgical orthodontics, bypassing presurgical orthodontic treatment¹². This innovative concept, introduced by Nagasaka et al., represents a novel paradigm in the integrated orthodontic-orthognathic management of jaw deformities¹³, SFA protocols have shown reduced treatment duration¹². This reduction significantly enhances patients' overall satisfaction with the treatment process¹⁴. The remarkable orthodontic efficiency observed in SFA cases can be attributed to a combination of factors. Firstly, initiating treatment with the correction of skeletal bases minimizes the complexity of subsequent orthodontic interventions and potential soft tissue imbalances that could obstacle orthodontic movements are addressed from the outset. Secondly, the metabolic turnover post-surgery is heightened, leading to accelerated tooth movement, thereby expediting the orthodontic process¹⁴. However, SFA may increase the risk of skeletal recurrence due to initial postsurgical occlusion inadequacies¹⁵.

In this work, we investigated a rare case in the field of orthognathic surgery. The surgery-first strategy for Class I procedures and less severe patients was

the main focus of earlier research. This case report investigated the surgery-first approach for a patient with posterior tooth loss and a deep bite, where typical pre-operative orthodontic treatment plans were impractical. As such, we chose to treat the patient's complaints by surgery first process.

CASE PRESENTATION

This process was with the personal consent and approval of the patient and was approved by the Research and Ethics Committee of Mashhad University of Medical Sciences (IR. MUMS. DENTISTRY.REC.1402.052). The authors attest that they have all necessary patient permission form in their possession. The patient has agreed on the form that her pictures and other clinical data may be published in the publication. The patient is aware that while every attempt would be made to hide identification and that name and initials will not be disclosed, anonymity cannot be ensured.

A 34-year-old female patient presented to the Dental Clinic of Mashhad University of Medical Science, Mashhad, Iran with complaints of facial asymmetry, malocclusion, and difficulty in chewing. Clinical examination revealed a Class III skeletal malocclusion with mandibular prognathism and maxillary retrusion. Cephalometric analysis (Figure 1) confirmed the presence of a skeletal discrepancy with an ANB angle of -8.8, indicating a significant anteroposterior skeletal discrepancy (Figure 2,3). Preoperative records, including study models, cephalometric radiographs, and photographs, were obtained to assess the severity of the malocclusion and plan the surgical correction. Orthognathic surgical planning was performed using computerized cephalometric analysis to determine the extent of maxillary and mandibular repositioning required to achieve ideal facial aesthetics and occlusion (Figure 1).

The patient's acute problems had caused her deep overbite to be 8 mm and her reverse overjet to be -12 mm. Her SNA angle was 79.8 degrees, SNB angle was 88.6 degrees, ANB angle was -8.8, and the patient's Facial angle (FH/NP_g) was 99.5 degrees. Additionally, the A/NP_g Distance, indicating convexity in the patient, was -9.4 mm, and the P_g-NP distance was measured as 14.7 mm. In the skeletal vertical view, the Y-axis (FH/Y) of the patient measured 48.0 degrees, and the Facial axis

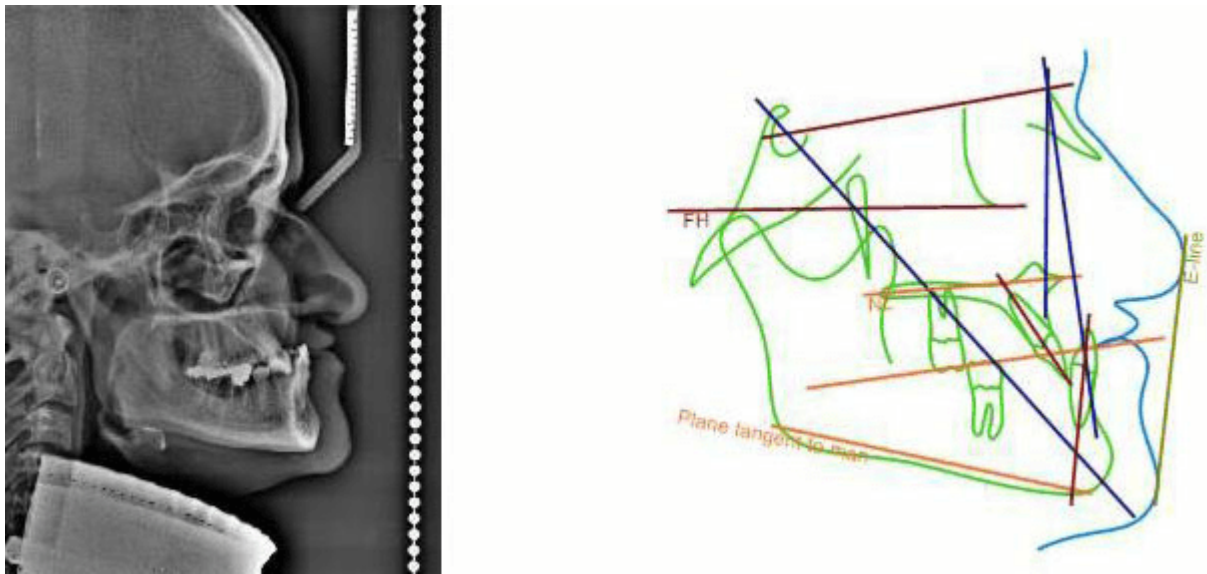


Figure 1: Cephalometric analysis & Radiographic image of the lateral view

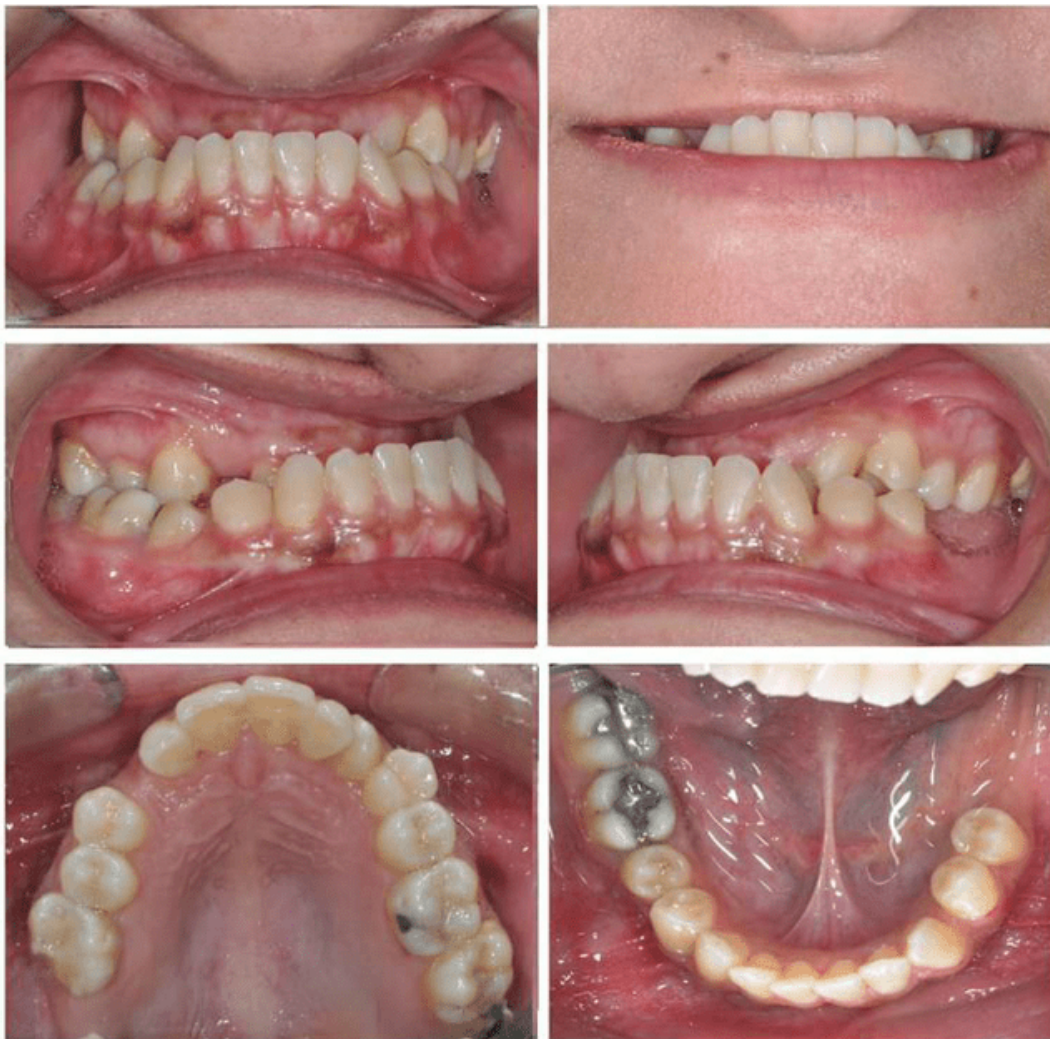

Figure 2: Preoperative occlusion of the patient

was 102.9 degrees. Jarabak's ratio (PFH/AFH) was calculated to be 73%.

A multidisciplinary treatment approach involving orthodontics and maxillofacial surgery was adopted. The treatment plan consisted of a surgery-first approach; wherein orthognathic surgery would be performed before initiating any orthodontic treatment. The surgery would involve moving the upper jaw forward with Le Fort I osteotomy and moving the lower jaw back with bilateral sagittal split osteotomy (BSSO). In this procedure, we used a splint to guide the movement of the jaws. In this

surgery intermediate and final splints were applied to maintain the desired position accurately, thus improving the precision of the surgery. We made sure the patient understood the plan, including the benefits and possible risks of starting with the surgery-first approach.

Under general anesthesia, the planned orthognathic surgery was performed following a standardized surgical protocol. Initially, a Le Fort I osteotomy and down-fracture of the maxilla were performed to advance the maxilla and rectify any transverse and vertical discrepancies. Complete mobilization of the

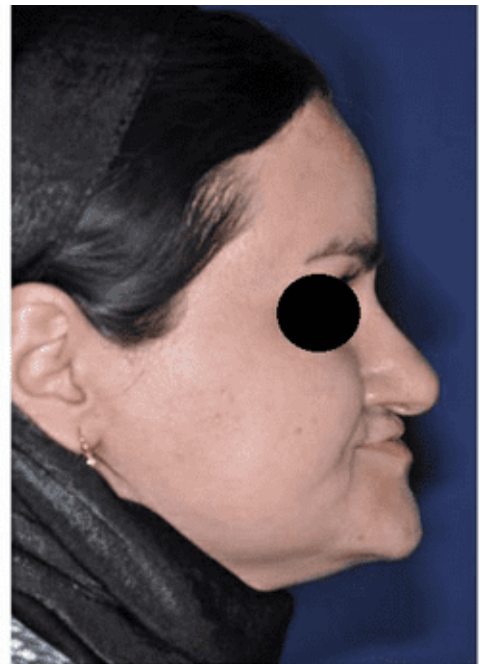


Figure 3: Appearance of the patient's face before surgery

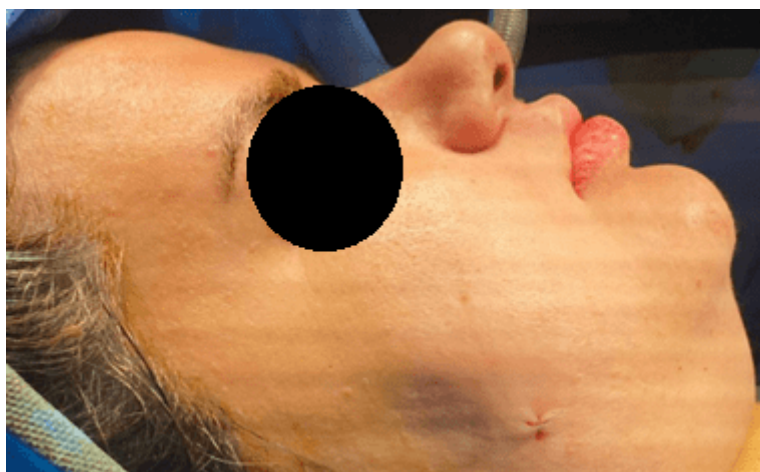


Figure 4: Lateral view of the patient's face after surgery

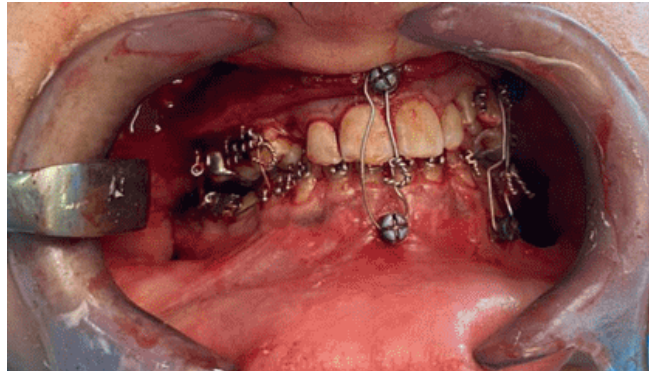


Figure 5: Orthodontic brackets and intraoperative fixations

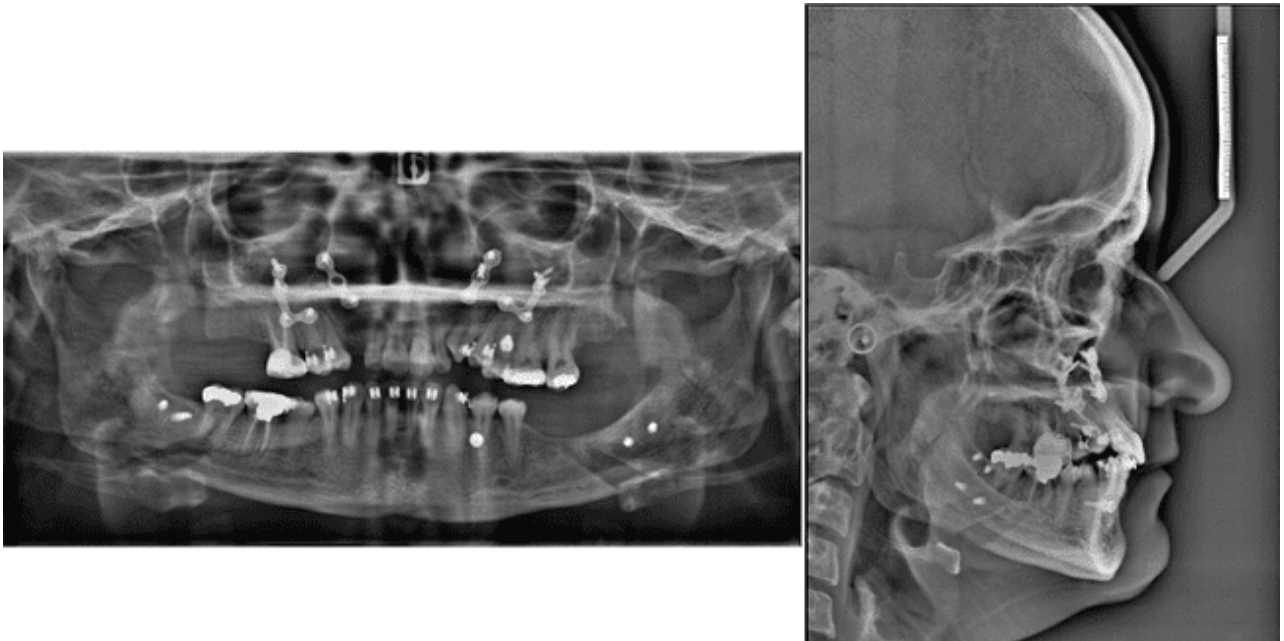


Figure 6: Postoperative lateral radiographic & OPG images

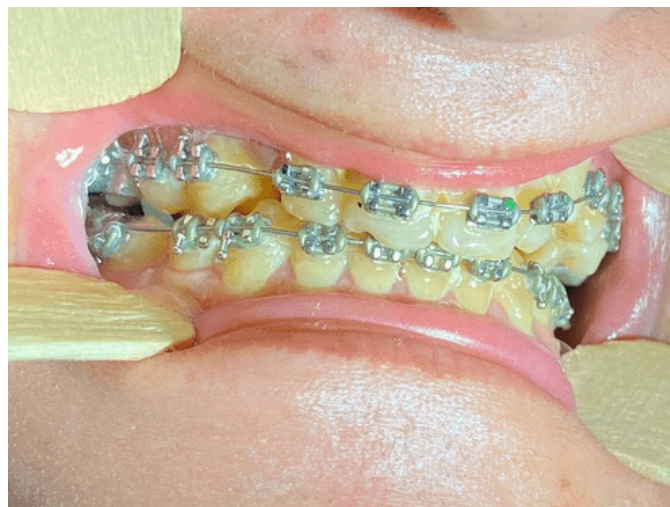

Figure 7: 1-year follow-up occlusion situation of the patient

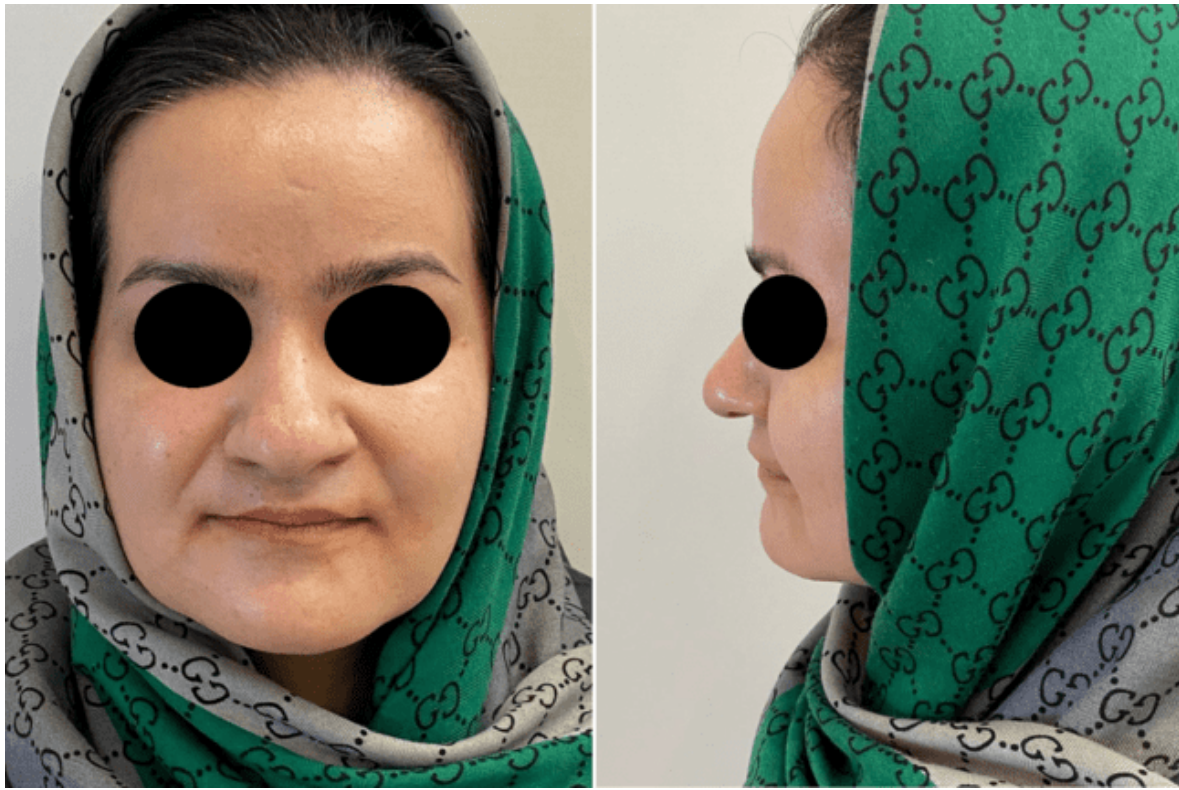

Figure 8: 1-year follow-up images

upper jaw, the placement of an intermediate splint, and maxillary fixation were done. Subsequently, bilateral sagittal split osteotomy was conducted to reposition the mandible in a retrusive position, and finally, the final splint was placed to fix the position of the jaws. Intraoperative monitoring ensured the precise execution of the surgical plan, and postoperative stability was confirmed using rigid internal fixation (Figure 4, 5). During the surgical procedure, in collaboration with an orthodontic specialist, orthodontic brackets were concurrently placed to ensure seamless continuation of orthodontic treatment post-operation (Figure 5). Because of the severe reverse overjet and overbite, placing brackets before the operation wasn't feasible. Hence, orthognathic surgery was conducted initially, followed by the installation of orthodontic brackets during the surgical procedure. To enhance the flexibility and stability of the treatment plan, IMF (Intermaxillary Fixation) screws were utilized combined with hooks attached to orthodontic brackets to optimize both dental and skeletal stability, resulting in better treatment outcomes. Immediate postoperative care included pain management (Novafen prn), antibiotic therapy

(amoxicillin 500 mg q8h), and dietary instructions to facilitate healing and minimize postoperative complications. The patient was closely monitored for any signs of infection, neurosensory deficits, or occlusal discrepancies. Regular follow-up appointments were scheduled to assess postoperative healing, monitor occlusal changes, and initiate orthodontic treatment.

The postoperative course was uneventful, with satisfactory healing and minimal postoperative discomfort. Follow-up evaluation revealed significant improvement in facial aesthetics, occlusion, and functional outcomes. The patient reported enhanced chewing ability and expressed high satisfaction with the treatment outcomes. Also, she was amazed by the shortened time of face aesthesia. As a consequence of this treatment process, the reverse overjet increased to 3.8 mm, exceeding the normal value by 0.3 mm. In comparison, the deep overbite decreased to 2.0 mm, aligning with the normal range (Figure 6). Orthodontic treatment was initiated postoperatively to fine-tune occlusion and achieve optimal dental alignment. Long-term stability and patient satisfaction were maintained during the follow-up period, confirming the efficacy

of the surgery-first approach in achieving successful outcomes in orthognathic surgery (Figure 7 & 8).

DISCUSSION

The presented case demonstrates the successful application of the surgery-first approach in orthognathic surgery for the correction of dentofacial deformity. The reason for choosing this treatment process was the impossibility of placement of brackets before the procedure due to the reverse overjet and severe deep overbite. Thus, orthognathic surgery was performed first, and then orthodontic brackets were applied while the operation was performed.

This treatment, done with both the oral and maxillofacial surgeon and orthodontist working together during surgery, was particularly special because the patient had no posterior teeth and a serious deep bite. Without those posterior teeth, it was hard to distinguish the natural stopping point for jaw positioning. However, with help from the orthodontist, jaw positioning & vertical dimension for easier access were determined and this made the post-operative orthodontic treatment phase easier. This treatment plan solved a big problem with the surgery-first method - not being able to easily adjust the orthodontics brackets to teeth after surgery - and It made the patient more satisfied and more comfortable.

The SFA offers numerous advantages, including reduced treatment duration, immediate improvement in facial aesthetics, and enhanced patient satisfaction^{12,14}. This approach reduces treatment time while improving face appearance right away by starting with an instant surgical correction and then moving on to orthodontic alignment¹². As a result, patients can achieve optimal functioning and aesthetics sooner and without the need for preoperative treatment¹⁴. Further the SFA has its drawbacks. For instance, it might increase the risk of jaw alignment issues initially, leading to a chance of jaw problems recurrence¹⁵. Additionally, there is the challenge of orthodontic treatment after surgery, which keeps the traditional method of starting with orthodontics as the gold standard treatment option, however, the mentioned advantages of SFA make it more beneficial than OFA in rare cases like this one.

With these advantages and disadvantages, careful

patient selection, comprehensive treatment planning, and interdisciplinary collaboration are essential to ensure favorable outcomes with the surgery-first approach. Further research and long-term follow-up studies are warranted to evaluate the stability and predictability of the SFA compared to traditional orthognathic surgery approaches.

In recent articles it was confirmed that the SFA became able to gain comparable medical consequences to CSA (conventional surgery approach) but in a shorter remedy time¹⁶. We observed that the convalescence period was significantly reduced in this case as Ying Zhai et al showed that surgical-orthodontic remedy using SFA could be a possible choice of remedy for dentofacial deformities primarily based on the equal impact on TMD (Temporomandibular disorders) and shorter standard remedy period as compared to standard surgeons' treatment the usage of OFA (orthodontics-first approach)¹⁷.

Most beneficial esthetic and functional outcomes were executed in 10 weeks after the surgical treatment, with the cooperation of two specialties and using the surgical operation first method similar to what Aylin Gallegos Salazar et al. observed in a case report article¹⁸.

It could be said that the success of the surgery-first approach mostly depends on case selection as its importance was discussed in many articles. Another thing that highlights the surgery-first approach is predictability and more satisfactory results for the patient.

CONCLUSION

The surgery-first approach represents a viable treatment option in orthognathic surgery for selected patients with dentofacial deformities. This case is handled distinctly from other surgery-first approach surgeries because orthodontic brackets are set concurrently with the surgical procedure, which is made feasible by collaborating with the orthodontic specialist. This method diminishes the patient's follow-up and treatment duration while improving patient satisfaction. This case report highlights the successful application of the SFA in achieving optimal outcomes in terms of facial aesthetics, occlusion, and patient satisfaction. The SFA offers several advantages over the traditional orthodontics-first approach and may serve as a

valuable treatment alternative in appropriately selected cases.

ACKNOWLEDGMENT

The authors gratefully acknowledge the assistance and financial support of Mashhad University of Medical Sciences and the Student Research Committee of Mashhad University of Medical Sciences. No financial support was received.

CONFLICTS OF INTEREST

The authors declare no conflict of interest.

REFERENCES

- Huang CS, Hsu SS, Chen YR. Systematic review of the surgery-first approach in orthognathic surgery. *Biomed J* 2014 Jul-Aug;**37**(4):184-90. doi: 10.4103/2319-4170.126863.
- Choovait P, Puranitee V, Nisalak P. Correction of mandibular prognathism using a surgery-first approach or early surgery: Two case reports. *M Dent J* 2021;**41**(2):97-112.
- Worms FW, Isaacson RJ, Speidel TM. Surgical orthodontic treatment planning: profile analysis and mandibular surgery. *Angle Orthod* 1976 Jan;**46**(1):1-25. doi: 10.1043/0003-3219(1976)046<0001:SOTPPA>2.0.CO;2.
- Behrman SJ, Behrman DA. Oral surgeons' considerations in surgical orthodontic treatment. *Dent Clin North Am* 1988 Jul;**32**(3):481-507.
- Graber TM, Vanarsdall Jr RL, Vig KWL, Bister D. Orthodontics. Current principles & techniques, 4th edition. *The European Journal of Orthodontics* 2005;**28**(2). doi: 10.1093/ejo/cji127
- Borges TM, Sol I, de Castro Rodrigues CM, Peres Lima FGG, Silva CJ, Furtado LM. Surgery First Approach in Orthognathic Surgery - Considerations and Clinical Case Report. *Ann Maxillofac Surg* 2021 Jul-Dec;**11**(2):349-351. doi: 10.4103/ams.ams_8_21.
- Hernández-Alfaro F, Guijarro-Martínez R, Molina-Coral A, Badía-Escriche C. "Surgery first" in bimaxillary orthognathic surgery. *J Oral Maxillofac Surg* 2011 Jun;**69**(6):e201-7. doi: 10.1016/j.joms.2011.01.010.
- Gandedkar NH, Chng CK, Tan W. Surgery-first orthognathic approach case series: Salient features and guidelines. *J Orthod Sci* 2016 Jan-Mar;**5**(1):35-42. doi: 10.4103/2278-0203.176657.
- Hernández-Alfaro F, Guijarro-Martínez R, Peiró-Guijarro MA. Surgery first in orthognathic surgery: what have we learned? A comprehensive workflow based on 45 consecutive cases. *J Oral Maxillofac Surg* 2014 Feb;**72**(2):376-90. doi: 10.1016/j.joms.2013.08.013.
- Liao YF, Chiu YT, Huang CS, Ko EW, Chen YR. Presurgical orthodontics versus no presurgical orthodontics: treatment outcome of surgical-orthodontic correction for skeletal class III open bite. *Plast Reconstr Surg* 2010 Dec;**126**(6):2074-2083. doi: 10.1097/PRS.0b013e3181f52710.
- Baek SH, Ahn HW, Kwon YH, Choi JY. Surgery-first approach in skeletal class III malocclusion treated with 2-jaw surgery: evaluation of surgical movement and postoperative orthodontic treatment. *J Craniofac Surg* 2010 Mar;**21**(2):332-8. doi: 10.1097/SCS.0b013e3181cf5fd4.
- Yu HB, Mao LX, Wang XD, Fang B, Shen SG. The surgery-first approach in orthognathic surgery: a retrospective study of 50 cases. *Int J Oral Maxillofac Surg* 2015 Dec;**44**(12):1463-7. doi: 10.1016/j.ijom.2015.05.024.
- Nagasaka H, Sugawara J, Kawamura H, Nanda R. "Surgery first" skeletal Class III correction using the Skeletal Anchorage System. *J Clin Orthod* 2009 Feb;**43**(2):97-105.
- Peiró-Guijarro MA, Guijarro-Martínez R, Hernández-Alfaro F. Surgery first in orthognathic surgery: A systematic review of the literature. *Am J Orthod Dentofacial Orthop* 2016 Apr;**149**(4):448-62. doi: 10.1016/j.ajodo.2015.09.022.
- Saghafi H, Benington P, Ju X, Ayoub A. The surgery-first approach for orthognathic correction of maxillary deficiency-is it stable? Three-dimensional assessment of CBCT scans and digital dental models. *Int J Oral Maxillofac Surg* 2024 Sep;**53**(9):763-770. doi: 10.1016/j.ijom.2024.02.006.
- Hoang TA, Lee KC, Chuang SK. The Surgery-first Approach to Orthognathic Surgery. *J Craniofac Surg* 2021 Mar-Apr **01**;**32**(2):e153-e156. doi: 10.1097/SCS.0000000000006942.
- Zhai Y, Han JJ, Jung S, Kook MS, Park HJ, Oh HK. Changes in the temporomandibular joint clicking and pain disorders after orthognathic surgery: Comparison of orthodontics-first approach and surgery-first approach. *PLoS One* 2020 Sep **4**;**15**(9):e0238494. doi: 10.1371/journal.pone
- Salazar AG, Waite PD, Kau CH. Enhancing the Orthognathic Surgery Experience: Treatment in 10 Weeks "Surgery First" Approach. *Ann Maxillofac Surg* 2020 Jan-Jun;**10**(1):227-231. doi: 10.4103/ams.ams_203_19.