

# Medial Breast Reconstruction after Breast Conserving Surgery with Local Flap: A Single Center Experience

Abolfazl Afsharfard<sup>1</sup>, Hamed Ebrahimibagha<sup>1</sup>, Armin Mohammadi<sup>2</sup>, Adel Zeinalpour<sup>1\*</sup>

1. Department of General Surgery, School of Medicine, Shahid Beheshti University of Medical Sciences, Tehran, Iran

2. Department of Surgery, School of Medicine, Ahvaz Jundishapur University of Medical Sciences, Ahvaz, Iran

## ABSTRACT

**Background:** Breast-conserving surgery (BCS) and post-surgical radiotherapy are the treatment of choice in early-stage breast cancers. Surgeons use different techniques for the reconstruction of the breast after BCS. We aimed to present our novel reconstruction technique for medial breast defects and report the follow-up results of patients who underwent breast reconstruction using this method in the short and long term.

**Methods:** Forty patients with medially located breast tumors under BCS referred to Shahid Modares Hospital in Tehran, Iran from 2018 to 2022 were enrolled in the study. The patients underwent breast reconstruction post-lumpectomy using the local transposition flap technique. We followed the patients for one year, and the satisfaction and complication results were assessed and reported post-operation, after radio-chemotherapy, and after one year.

**Results:** The patients' mean age was 48.4 ( $\pm 12.3$ ) years, and the mean BMI was 30.9 ( $\pm 3.1$ ). There were no cases of complication, including infection, seroma formation, hematoma, flap ischemia, or necrosis post-operation, one week and one month after discharge. The surgeon and patient satisfaction surveys conducted post-op, after the radio-chemotherapy course, and one year after BCS using the Breast-Q satisfaction domain showed that the excellent and good satisfaction rates are 88%, 92%, and 92%, respectively.

**Conclusion:** Local transposition flap has remarkable cosmetic results with the least complication rate in the reconstruction of medial breast defects after breast-conserving surgery and is an excellent choice for surgeons.

## KEYWORDS

Breast reconstruction; Breast Conserving Surgery; Medial Transposition Flap; Medial Breast defects

## Please cite this paper as:

Afsharfard A, Ebrahimibagha H, Mohammadi A, Zeinalpour A. Medial Breast Reconstruction after Breast Conserving Surgery with Local Flap: A Single Center Experience. *World J Plast Surg.* 2024;13(3):79-86. doi: 10.61186/wjps.13.3.79

## \*Corresponding Author:

Dr. Adel Zeinalpour,

Assistant Professor of Surgery, Shahid Modarres Hospital, Shahid Beheshti University of Medical Sciences, Velenjak Street, Tehran, Iran

Email: [adel.zeinalpour@gmail.com](mailto:adel.zeinalpour@gmail.com)

Received: 17/07/2024

Accepted: 19/10/2024

## INTRODUCTION

Breast-conserving surgery (BCS) and post-surgical radiotherapy are the treatment of choice in early-stage breast cancers since there are no differences in survival rates compared to total mastectomy<sup>1-4</sup>. Using BCS methods with resecting enough margin and immediate defect reconstruction leads to appropriate oncological and cosmetic results and lower costs. Eventually, it improves patients' psychological condition and quality of life<sup>5-8</sup>.

Choosing the appropriate method for breast reconstruction after BCS depends on various factors. Tumor size, location, defect size, and size of the breast are among the most important ones<sup>9, 10</sup>.

In large-sized breasts, we can employ Oncoplastic surgical methods, including mammoplasty and advanced flaps from the breast tissue to reconstruct the defect site. There are limitations in using these methods in the case of small and sometimes medium-sized breasts<sup>11</sup>.

In most cases, the breast tumors are located in the upper outer quadrant of the breast due to its dense texture, and the prevalence of medially located tumors is much lower. Accordingly, it is always challenging to reconstruct the medial side of the breast after tumor resection<sup>12, 13</sup>.

After the BCS for medial breast tumors, reconstruction of remaining defect is challenging, and if done incorrectly, it will cause obvious deformity<sup>14</sup>. Especially the upper inner quadrant of the breast, which is the so-called “no man’s land” due to the complexity of the reconstruction of this portion<sup>15, 16</sup>.

For medial breast reconstruction using oncoplastic technique after BCS, especially in large-sized breasts, in lower inner quadrant of the breast, the inferior sub-mammary fold is usually cut, and the breast tissue is rotated from the lower to the medial portion, and the NAC recentralized by de-epithelialization of the supro-lateral pedicle<sup>17</sup>. The tumor prevalence is low in the upper inner quadrant of the breast, and there is no standard Oncoplastic reconstruction method in this area<sup>18-21</sup>. Silverstein et al. presented Batwing’s method for reconstruction of this area, which has its disadvantages and requires more research<sup>22</sup>.

Using the local transposition flap is another method we can use for reconstructing both lateral and medial breast defects, especially in cases where the tumor’s skin should be excised<sup>23</sup>. The perforating arteries of the chest and abdominal wall (intercostal, internal mammary, and epigastric artery) and their enriched subdermal networks made them an appropriate area for making the local flaps<sup>24, 25</sup>.

In this study, we aimed to present our experience using the local transposition flap to reconstruct the breast’s medial portion after BCS.

## PATIENTS AND METHODS

### *Study design and participants*

Forty patients with medially located breast tumors under BCS referred to Shahid Modares Hospital in Tehran, Iran from 2018 to 2022 were enrolled. Inclusion criteria include tumors in the medial portion of the breast (superior, median, inferior) with small to medium-sized breasts.

The exclusion criteria were: patients with advanced tumors, large breast size, non-medially located tumors, comorbidities such as diabetes, corticosteroid givers, and immunodeficiency from the study. We excluded large breasts because the oncoplastic methods have better proven cosmetic results in these cases. In addition to that, mentioned comorbidities may interfere with wound healing and may affect the cosmetic results. The whole procedure was explained to the patients, and after obtaining informed consent, patients were entered into the study. Two experienced surgeons perform all of the surgery stages and perform the flap in a referral hospital affiliated with Shahid Beheshti University of Medical Sciences, Tehran, Iran. All surgery parts, including lumpectomy and reconstruction, were done by a fixed surgeon.

The research adhered to the fundamentals of the Declaration of Helsinki. The Ethical Committee of the Shahid Beheshti University of Medical Sciences approved the protocol for this study (IR.SBMU.MSP.REC.1399.446).

### *Surgical technique*

After performing a classic lumpectomy with an adequate margin and sentinel lymph node biopsy (SLNB), all the margins and sentinel lymph nodes were sent for the frozen section study. In the case of marginal involvement or positive SLN in the frozen section, the involved margins were re-excised, or axillary lymph node dissection (ALND) was performed, respectively. After being sure about free margins, we designed the local transposition flap for reconstruction of the created defect.

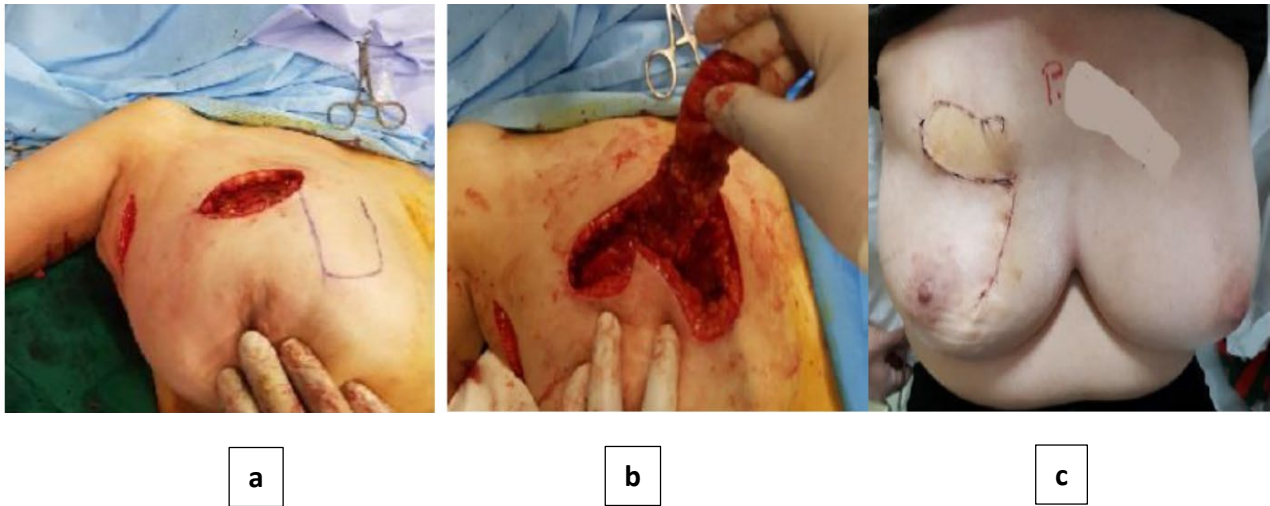
In this study, we divided the medial breast side into three parts: the upper, middle, and lower using a

clock position. Accordingly, the upper part was from 12:00 to 2:00 in the right breast and 10:00 to 12:00 on the left. The middle section is from 2:00 to 4:00 on the right and 8:00 to 10:00 on the left (above the end of the sub-mammary fold), finally, the lower section is from 4:00 to 6:00 on the right and from 6:00 to 8:00 on the left (below the end of the sub-mammary fold). We present three different methods for reconstructing each part using a specific local transposition flap.

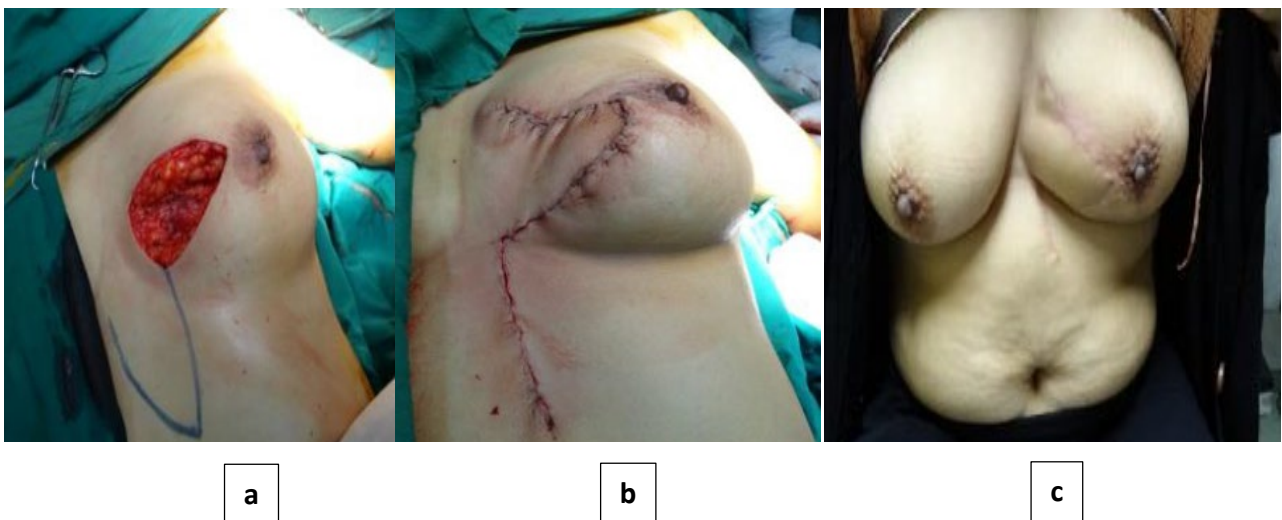
### *Reconstruction of the upper-medial defects*

We used the dermo-glandular local transposition flap, including the dermis and the breast tissue,

for reconstructing the upper-medial lumpectomy defects. We designed the flap's length and width according to the defect size in the adjacent tissue. Then, the flap, including the dermis, sub-dermis, breast tissue, and pectoral fascia, is removed from the Pectoralis major muscle and rotated to the defect site (Figure 1). The deep fascia of the flap is sutured to its dermis layer in each 2cm by Vicryl (Johnson and Johnson) 3/0 to avoid the blood supply disturbance of the flap. After transposing the flap to the defect site, we suture the sub-dermis and dermis with Vicryl 2/0 and Monocryl (Ethicon) 3/0, respectively, in subcuticular form. If necessary, a closed suction drain is placed under the flap.



**Figure 1:** Reconstruction of the upper-medial defect. Flap design in the adjacent tissue (a) transposition the flap to the defect site (b) one month after the surgery(c)



**Figure 2:** Reconstruction of the lower-medial defect. Flap design (a) transposition flap(b) one year after the operation(c)

### Reconstruction of the lower-medial defects

We use the local transposition thoraco-epigastric flap for the reconstruction of lower-medial defects. The epigastric region has a tremendous sub-dermal blood supply from the origin of the sixth perforating branch of the medial mammary artery. Hence, we can perform appropriate flaps on this site with a good blood supply. We design the flap according to the defect size in the epigastric region under the breast. This flap consists of the dermis, sub-dermis, and adipose tissue to the depth of the abdominal muscle wall fascia. After transposing the flap and covering the defect site, the sub-dermis and dermis are sutured subcutaneously by Vicryl and Monocryl, respectively. It is not necessary to place a closed suction drain, but complete homeostasis must be created. We can design and do this flap obliquely and under the breast so that the scar will be hidden in the sub-mammary fold (Figure 2).

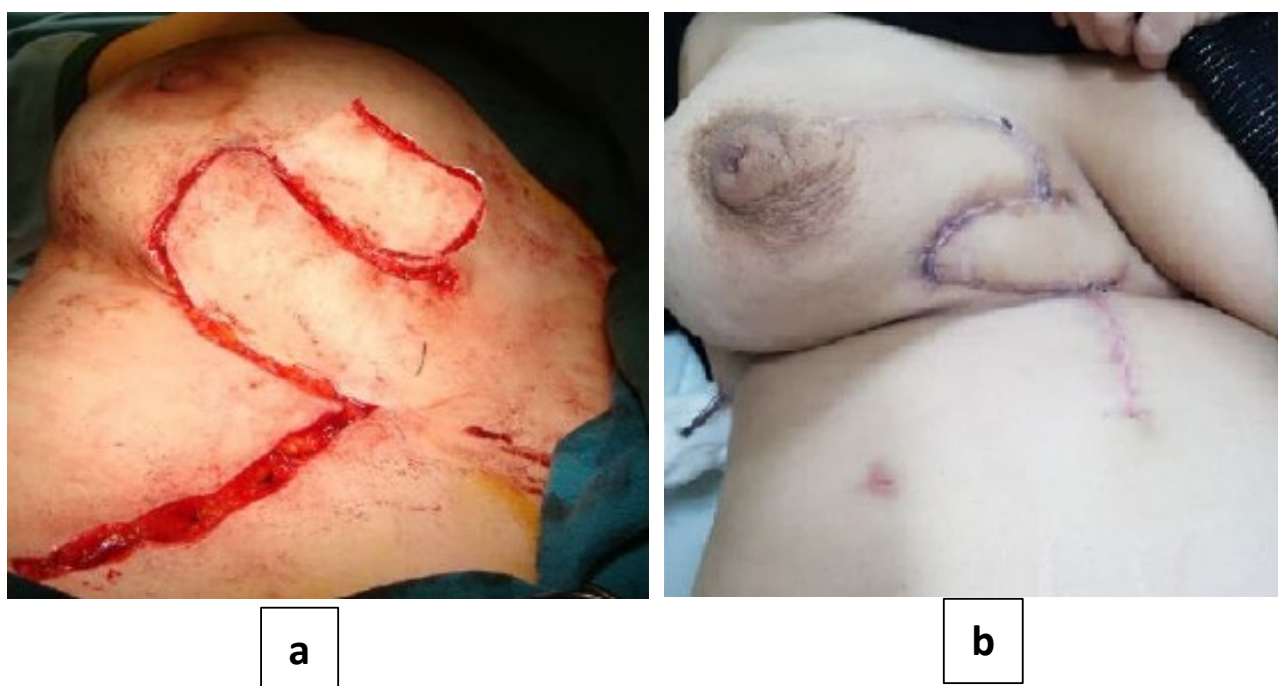### Reconstruction of the middle-medial defects

We use two adjacent transposition flaps for the reconstruction of middle-medial defects. First, we design the flap according to the defect size on the adjacent inferior part, consisting of the dermis, sub-

dermis, breast tissue, and pectoralis muscle fascia. Then, we rotate the flap from the lower breast part to the defect site on the middle breast part. After that, the second local transposition, the thoraco-epigastric flap, like the lower-middle flap, is designed and performed on the epigastric and sub-mammary regions. If necessary, a closed suction drain is placed under the flap site (Figure 3).

### Postoperative follow-up

After the surgery, we assessed the possible complications, such as infection in the surgery site, flap ischemia or necrosis, seroma, and hematoma. We discharged the patient with a drain one day after the operation. Before discharging the patients, we instructed the patients concerning how to dress the wound, evacuate, and chart the drain secretion. We used regular traditional Gauze dressing in all cases. A week after discharging the patients, we remove the drain if there is no secretion. Then we referred the patients to the oncologist with their tumor pathology report. All the patients are visited a month later, after finishing the radiotherapy course, and one year after the operation. We examined and evaluated the operation site and the flap in terms of aesthetics, possible side effects, local recurrence,



**Figure 3:** Reconstruction of the middle-medial defect. two adjacent(bi-lobbed) transposition flaps(a) one month after the operation(b)

**Table 1:** Basic demographics and pathological staging of tumors

Variables	Results	
Age (yr)	48.4 ( $\pm 12.3$ )	
Location	Upper-medial	19
	Middle-medial	8
	Lower-medial	13
Tumors' size	3.4 $\times$ 2.6 $\times$ 1.21 cm ( $\pm 1.56 \times 1.01 \times 0.7$ )	
Defect size	8.24 $\times$ 4.52 $\times$ 3.11 ( $\pm 6.15 \times 1.22 \times 1.55$ )	
Pathological staging	T <sub>1</sub>	25
	T <sub>2</sub>	13
	T <sub>3</sub>	2
	N <sub>0</sub>	24
	N <sub>1</sub>	11
	N <sub>2</sub>	5
	M <sub>0</sub>	40

**Table 2:** Patient satisfaction survey results

Time of survey	Cosmetic Result (%)		
	Excellent / good	Fair	Poor
A Month After The Operation	88	11	1
After Radio-Chemotherapy Course	92	7	1
After One Year	92	7%	1

and the patient's satisfaction rate using the Breast-Q survey, a questionnaire for assessing the patients' satisfaction<sup>26</sup>. In each visit. We used the Breast-Q reconstruction module, satisfaction domain, to assess the patient's satisfaction with our novel flap. We reported the obtained results qualitatively for a better and more concrete report. For this purpose, we have reported average numbers less than 33 as poor, 33 to 66 as fair, and above 66 as good/excellent. We assess the satisfaction rate three times; post-operation, after the radiotherapy, and one year after the surgery, and report the results.

## RESULTS

We included 40 patients with a mean age of 48.4 ( $\pm 12.3$ ) years. The mean BMI of the patients was 30.9 ( $\pm 3.1$ ). All patients had early-stage tumors in the medial part of the breast, of which 19 were in the upper medial, eight in the middle medial, and 13 in the lower-medial part of the breast.

The tumors' size ranged from 1.2 $\times$ 1 $\times$ 1 cm to 6.5 $\times$ 5 $\times$ 3.5 cm with an average size of 3.4 $\times$ 2.6 $\times$ 1.21 cm ( $\pm 1.56 \times 1.01 \times 0.7$ ). The defects sized from 4.5 $\times$ 3 $\times$ 1 cm to 12 $\times$ 7 $\times$ 4.5 cm with the mean defect size of 8.24 $\times$ 4.52 $\times$ 3.11 ( $\pm 6.15 \times 1.22 \times 1.55$ ). All of the excised tumors were reported as invasive ductal

carcinoma. Basic demographics and pathological staging of tumors according to TNM are shown in Table 1. According to the frozen section results, three patients needed re-excision of margins, and 16 needed axillary lymph node dissection due to positive SLNB.

No complications included infection, seroma formation, hematoma, flap ischemia, or necrosis post-operation, one week and one month after discharge. There was no local recurrence in the one-year follow-up. No skin changes, fibrosis, or flap deformity were observed after radiotherapy. Patient satisfaction surveys conducted post-operation, after the radio-chemotherapy course, and one year after BCS shows that the excellent/good satisfaction rate was 88%, 92%, and 92%, respectively (Table 2). Cosmetic results and patient satisfaction have increased over time.

## DISCUSSION

BCS and following radio-chemotherapy is an accepted rule in managing early-stage breast cancers, except in the cases where there is a contraindication for breast conservation<sup>1</sup>. The proper breast appearance after breast surgery significantly impacts the patient's mental health and

quality of life. Therefore, finding a proper method to reconstruct breast defects, especially large ones, after breast-conserving surgery is challenging for surgeons. Although the prevalence of breast tumors on the medial breast side is much lower than on the lateral side, all surgeons will meet some of these cases. Another issue is that the reconstruction of this part is complicated, and there is the risk of deformity with current methods.

Choosing a proper reconstruction method after BCS is a crucial issue, especially in cases with large tumor sizes or tumor invasion to the skin in which the resulting defect is significant after tumor and margin excision. The primary closure of the lumpectomy site causes degrees of deformity when the excised volume is more than 20% of the breast, and it is much more frequent in medial side lumpectomy<sup>27</sup>. There are many studies concerning breast reconstruction after BCS, and they all aim to better flap shape, higher patient satisfaction rate in terms of beauty, and more excellent oncological results. A standard medial breast reconstruction method used chiefly for cases with large-sized breasts is oncoplastic breast surgery<sup>22</sup>. Despite the significant advantages of these methods, some critical disadvantages include limitations of applying to small and medium-sized breasts, complex technique, and breast asymmetry at the end of the operation, which needs another aesthetic surgery on the opposite side breast for symmetry<sup>28, 29</sup>. Another reconstruction method applicable in larger medial breast defects is the Latissimus dorsi flap which is an invasive method that may cause morbidity in the donor site and muscular distinction<sup>30</sup>. The other method uses the superior epigastric artery flap (SEAP flap). Hamdi et al. reviewed the different studies on the efficacy of this kind of flap for the reconstruction of medial breast defects and showed that the SEAP flap is an appropriate method for reconstruction of this site; however, complex techniques need to use Doppler or CT angiography to identify the perforating branches, the dependence of the flap displacement on the length and location of the perforating branch, significant scar in the donor site, and finally necrosis the distal portion of the flap are the limitations of this kind of flap<sup>31</sup>. Using the local transposition flap is another method for breast reconstruction after BCS. Afsharfard et al., presented and used this method for the reconstruction of lateral breast

defects, which had great cosmetic results and very low complications<sup>23</sup>. Here in this study, we also used the local transposition flap to reconstruct the medial breast defects.

Our presented technique is associated with excellent aesthetic results, outstanding patient satisfaction, and shallow complication rates. The technique is easy to perform, and most surgeons can do it, and following the basic principles, the rate of necrosis, seroma, and infection will be very low. This flap enables us to start the chemo-radiotherapy just after the wound healing without worrying about radiotherapy's destructive effects on the flap. Our results showed no cases of post-radiotherapy flap complications such as deformation, fibrosis, and infection. Another advantage of this method is outstanding cosmetic results and patient satisfaction rate as time goes on. After one year of surgery, the patient's satisfaction with the shape of the breast was excellent. This flap has the lowest neural, vascular, and muscular morbidity and scar in the donor site. There are no changes in NAC location, and the breasts are symmetric after the surgery, which resolves the need for secondary aesthetic surgery, which is necessary for Oncoplastic techniques.

Regarding the complication, we do not have any cases of infection, seroma, hematoma, flap ischemia, or necrosis post-operation. Limited local Lymphedema was seen in some cases, which resolved after some days. One of the disadvantages of the presented flap is that in the case of lower and middle medial reconstruction, we may have a vertical scar. We can solve this by designing the flap obliquely so that the scar will be hidden in the sub-mammary fold.

## CONCLUSION

Our experience in reconstructing medial breast defects with a local transposition flap signifies that the flap is practical, non-invasive, with a low complication rate, great cosmetic results, and high patient satisfaction, and can be an excellent choice for surgeons.

## ACKNOWLEDGEMENTS

This research received no specific grant from any funding agency in the public, commercial, or not-for-profit sectors. The authors of the present study would like to thank the Shohadaye Tajrish

Educational Hospital staff who helped us with the execution of this report.

## CONFLICTS OF INTEREST

There are no conflicts of interests.

## REFERENCES

- Veronesi U, Cascinelli N, Mariani L, et al. Twenty-year follow-up of a randomized study comparing breast-conserving surgery with radical mastectomy for early breast cancer. *N Engl J Med* 2002;**347**(16):1227-32.
- Veronesi U, Saccozzi R, Del Vecchio M, et al. Comparing radical mastectomy with quadrantectomy, axillary dissection, and radiotherapy in patients with small cancers of the breast. *N Engl J Med* 1981;**305**(1):6-11.
- Veronesi U, Banfi A, Saccozzi R, et al. Conservative treatment of breast cancer: a trial in progress at the Cancer Institute of Milan. *Cancer* 1977;**39**(6):2822-6.
- Christiansen P, Mele M, Bodilsen A, Rocco N, Zachariae R. Breast-conserving surgery or mastectomy?: impact on survival. *Ann Surg* 2022;**3**(4):e205.
- Schover LR, Yetman RJ, Tuason LJ, et al. Partial mastectomy and breast reconstruction. A comparison of their effects on psychosocial adjustment, body image, and sexuality. *Cancer* 1995;**75**(1):54-64.
- Kurtz J. Impact of radiotherapy on breast cosmesis. *The Breast* 1995;**4**(3):163-9.
- Kroll SS, Singletary SE. Repair of partial mastectomy defects. *Clin Plast Surg* 1998;**25**(2):303-10.
- Dean C, Chetty U, Forrest A. Effects of immediate breast reconstruction on psychosocial morbidity after mastectomy. *The Lancet* 1983;**321**(8322):459-62.
- Clough KB, Kroll SS, Audretsch W. An approach to the repair of partial mastectomy defects. *Plast Reconstr Surg* 1999;**104**(2):409-20.
- Brierley J, Paterson I, Lallemand R, Rostom A. The influence of breast size on late radiation reaction following excision and radiotherapy for early breast cancer. *J Clin Oncol* 1991;**3**(1):6-9.
- Yang JD, Kim MC, Lee JW, et al. Usefulness of Oncoplastic Volume Replacement Techniques after Breast Conserving Surgery in Small to Moderate-sized Breasts. *Arch Plast Surg* 2012 Sep;**39**(5):489-96.
- Bright CJ, Rea DW, Francis A, Feltbower RG. Comparison of quadrant-specific breast cancer incidence trends in the United States and England between 1975 and 2013. *Cancer Epidemiol* 2016 Oct;**44**:186-94.
- André C, Holsti C, Svenner A, et al. Recurrence and survival after standard versus oncoplastic breast-conserving surgery for breast cancer. *BJS Open* 2021;**5**(1):zraa013.
- Lin J, Chen D-R, Wang Y-F, Lai H-W. Oncoplastic surgery for upper/upper inner quadrant breast cancer. *PLoS One* 2016;**11**(12):e0168434.
- Grisotti A, Calabrese C. Conservation treatment of breast cancer: reconstructive problems. *Surgery of the Breast: Principles and Art 2nd ed Philadelphia: Lippincott Williams & Wilkins* 2006:147-78.
- Krämer S, Kuemmel S, Camara O, Grosse R, Friedrich M, Blohmer J-U. Partial mastectomy reconstruction with local and distant tissue flaps. *Breast Care* 2007;**2**(5):299-306.
- Clough KB, Kaufman GJ, Nos C, Buccimazza I, Sarfati IM. Improving breast cancer surgery: a classification and quadrant per quadrant atlas for oncoplastic surgery. *Ann Surg Oncol* 2010 May;**17**(5):1375-91.
- Audretsch WP, Rezai M, Kolotas C, Zamboglou N, Schnabel T, Bojar H. Tumor-specific immediate reconstruction in breast cancer patients. *Perspectives in Plastic Surgery* 1998;**11**(01):71-100.
- Rezai M, Nestle-Kramling C. Onkoplastische Operationstechniken bei der brusterhaltenden Therapie des Mammakarzinoms. *Der Gynäkologe* 1999;**32**(2):83-90.
- Krämer S, Jäger W, Lang N, Beckmann M. Operative Therapie des Mammakarzinoms. *J Menopause* 2004;**11**:9-15.
- Dieterich H, Heyl V, Scheler P, Blazek J, Hoffmann G, Nestle-Krämling C. Rekonstruktion der Brust mit Eigengewebe. *Der Gynäkologe* 2005;**38**(3):236-42.
- Anderson BO, Masetti R, Silverstein MJ. Oncoplastic approaches to partial mastectomy: an overview of volume-displacement techniques. *Lancet Oncol* 2005;**6**(3):145-57.
- Afsharfard A, Ebrahimibagha H, Zeinalpour A. A Novel Local Transposition Flap for Lateral Breast Reconstruction After Breast Conserving Surgery. *Clin Breast Cancer* 2021 Jan 23.
- Nebril BA, Ramírez SB, Novoa AG, Lamas CV. Rotational flaps in oncologic breast surgery. Anatomical and technical considerations. *Cirugía Española (English Edition)* 2016;**94**(7):372-8.
- Audretsch W. Reconstrucción para defectos de mastectomía parcial: clasificación y método. *Cirugía de la mama Principios y arte Filadelfia: AMOLCA* 2008:179-216.
- Pusic AL, Klassen AF, Scott AM, Klok JA, Cordeiro PG, Cano SJ. Development of a new patient-reported outcome measure for breast surgery: the BREAST-Q. *Plast Reconstr Surg* 2009 Aug;**124**(2):345-53.
- Bulstrode NW, Shrotria S. Prediction of cosmetic

- outcome following conservative breast surgery using breast volume measurements. *Breast* 2001 Apr;**10**(2):124-6.
28. Bertozzi N, Pesce M, Santi PL, Raposio E. Oncoplastic breast surgery: comprehensive review. *Eur Rev Med Pharmacol Sci* 2017 Jun;**21**(11):2572-85.
29. Kijima Y, Shinden Y, Hirata M, Natsugoe S. [ONCOPLASTIC BREAST SURGERY AND BREAST RECONSTRUCTION]. *Nihon Geka Gakkai Zasshi* 2016 Nov;**117**(6):503-8.
30. Adams Jr WP, Lipschitz AH, Ansari M, Kenkel JM, Rohrich RJ. Functional donor site morbidity following latissimus dorsi muscle flap transfer. *Ann Plast Surg* 2004;**53**(1):6-11.
31. Hamdi M, Craggs B, Stoel A-M, Hendrickx B, Zeltzer A. Superior epigastric artery perforator flap: anatomy, clinical applications, and review of literature. *J Reconstr Microsurg* 2014;**30**(07):475-82.