

The Effect of Extensor Digiti Minimi Tendon (EDM) Transfer on Ulnar Deviation of the Little Finger

Hossein Akbari^{1*}, Ali Saadati¹, Peyman Akbari¹

1. Department of Plastic and Reconstructive Surgery, School of Medicine, Iran University of Medical Sciences, Tehran, Iran.

ABSTRACT

Background: The little finger permanent abduction is an annoying deformity usually along with Wartenberg's sign (a consequence of ulnar nerve palsy), but there are several ways to correct this condition in rheumatoid arthritis as well. We aimed to investigate the effect of surgical intervention on patients.

Methods: The current study was a clinical trial which was done at Hazrat Fatima Hospital of Tehran, Iran from 2020-2022, where 15 patients with an age range of 21-48 years were investigated. All these patients had complications of ulna nerve damage. After the intervention (tendon transfer), the angle change of the fifth finger was compared with before the surgery.

Results: A significant improvement in reducing the angle of the fifth finger after surgery was observed in patients ($P < 0.05$)

Conclusion: Tendon transfer is one of the best techniques for the treatment of ulnar injuries.

KEYWORDS

Ulnar palsy; Little finger; Wartenberg's sign; Digiti minimi tendon

Please cite this paper as:

Akbari H, Saadati A, Akbari P. The Effect of Extensor Digiti Minimi Tendon (EDM) Transfer on Ulnar Deviation of the Little Finger. *World J Plast Surg*. 2024;13(3):75-78.

doi: 10.61186/wjps.13.3.75

INTRODUCTION

Lesions and injuries of peripheral nerves in the upper limbs are one of the most frequent problems and diseases which can be observed in the group of patients referred to the specialized rehabilitation and rehabilitation treatment center. Chronic pains in the upper limb are closely related to repetitive movements in the arm, which can affect the upper limb peripheral nerves¹.

Ulnar nerve involvement is the second common cause of local mononeuropathy. This nerve includes the sensory and motor nerves that originate from the roots of C8-T1 and passes through the lower trunk and internal cord of the brachial network².

One of the rare features of lower ulnar nerve palsy is persistent abduction of the little finger, which is annoying³. Involuntary and persistent abduction of the little finger is a pathognomonic symptom of ulnar nerve lesions described by Wartenberg in 1939⁴. The weakness of muscle and dysesthesia in the affected hand is one of the consequences of ulnar nerve damage⁵.

*Corresponding Author:

Hossein Akbari

Hazrate Fatemeh Hospital,
Department of Plastic and
Reconstructive Surgery, School
of Medicine, Iran University of
Medical Sciences, Tehran, Iran

Email: hakbari1339@gmail.com

Received: 10/6/2024

Accepted: 13/10/2024

Manifestations of involvement of this nerve vary from pain in the elbow area and intermittent paresthesia of the hand to a distinct sensory disorder, emaciation and weakness of the hand muscles and the development of forked hands⁶⁻⁸.

Wartenberg's symptom (the little finger abduction deformity) occurs at the ulnar neuropathy site, wherein the extrinsic extensors of radially innervated do unopposed to the hand intrinsics⁶.

In 1966, Mannerfelt discussed the Wartenberg phenomenon. Wartenberg and Mannerfelt stated that there is a direct correlation between the abducted position of the little finger palsy of the palm third interosseous muscle³.

The little finger inaccurate abduction leads to the unrivaled operation of the extensor digiti minimi (EDM). It has been shown that EDM tendon can be prevented by performing tenodesis on the radial side of the little finger or EDM of the EDM tendon if Wartenberg's finding is not accompanied by deformity of the claw hand. The ulnar side of the EDM tendon is separated from the surface of the retina if Wartenberg's sign is accompanied by a deformity of the paw hand. Then it passes between the 4th and 5th metacarpals and is transferred from the palm to the A2 pulley. This leads to both little finger adduction and MP flexion⁹.

There are various surgical techniques to treat ulnar deviation of the little finger⁶.

The first technique to do this was described by Brooks et al. In this technique, the EDM is moved below the DTML and reconnected to the radial side of the digital sheath¹⁰.

We aimed to investigate the effectiveness of fifth finger extensor tendon transfer in improving the correction of fifth finger ulnar deviation.

MATERIALS AND METHODS

Study Design

This Clinical trial study was conducted in 2023 with IRCT20230430058028N1 registry code.

Sample and Sampling Method.

The study population consisted of 15 patients with ulnar nerve cut who had abduction deviation of the fifth finger from Hazrat Fatima Hospital, Tehran, Iran between 2020 -2022.

The inclusion criteria included evidence of ulnar deviation in patients, lack of nerve regeneration, informed consent and willingness to participate in the study. Exclusion criteria were the presence of other nerve lesions, unwillingness of the patient and age less than 10 years.

Procedure

Firstly, the extensor digiti minimi tendon was identified and released with an incision in the fifth metacarpophalangeal joint in the affected hand.

Then, the wrist was incised immediately proximal to the extensor retinaculum in the dorsal aspect of the hand. The extensor digiti minimi tendon was then released from the fifth extensor retinaculum compartment and entered the fourth compartment, and was placed on the radial side of the EDC 5 tendon. The transferred tendon was fixed in the distal part to the interosseous muscle in the radial side of the fifth finger.

This surgery was performed under local or general anesthesia. To ensure proper tension, the distal part of the transferred tendon was fixed on the surface, allowing the fifth finger to move out of the ulnar deviation and be in the neutral position. A wrist and metacarpophalangeal extensor orthosis was used for three weeks, and rehabilitation was performed between the fourth and sixth weeks after surgery.

The patients were evaluated before and three months after surgery to measure the angles of the fingers and assess the changes caused by the surgery.

Data Analysis

Data analysis was done using SPSS (version23) software (IBM Corp., Armonk, NY, USA).

In order to evaluate the difference between the angle before and after the surgery, as well as to evaluate the relationship between age and injury in the dominant hand with the amount of correction of the angle after the surgery, the Related-Samples Wilcoxon Signed Rank Test and Pearson correlation tests were used, respectively. *P* value less than 0.05 was considered statistically significant.

RESULTS

Fifteen patients with a mean age of 37.3 years were studied. Among the participants, there was only

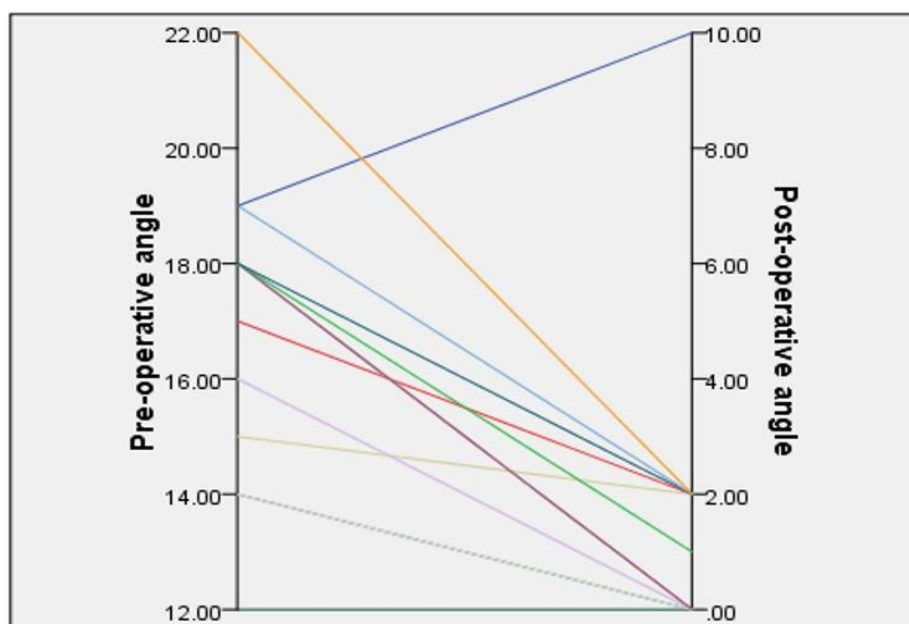


Figure 1: Fifth finger angle of patients before and after surgery (P -Value<0.001)

one female. Ulnar nerve damage occurred between 2 and 5 years ago. The angle between the fifth and fourth finger varied from 14 to 22 degrees (Mean: 16.9) (Figure 1).

There was no disease with complications at the wound site. Also, there was no anatomical variation in the number and presence of EDM and EDC 5 tendons. Thirteen patients were right-handed and the affected hand was on the dominant side in 10 cases.

All patients showed significant degrees of improvement and reduction of the fifth angle. The angle of the fifth finger in the patients increased from an average of 16.9 degrees to an average of 1.4 degrees (P value <0.001). The least recovery belonged to the oldest patient (48 years old) which went from 19 to 10 degrees and other patients recovered and the angle decreased by about 2 degrees.

The surgery used in this study was more effective in younger patients. Also, there was no significant relationship between age and gender with the effectiveness of surgery.

DISCUSSION

In order to investigate the deformation of the little finger extensor apparatus in ulnar nerve palsy, several techniques have been proposed¹¹.

Treatment of the sequelae of ulnar nerve palsy has attracted considerable attention since the

beginning of the 19th century, as reflected by the wide range of tendon transfers currently available. Nevertheless, the technique of tendon transfers to correct permanent abduction of the little finger was first published by Brooks in 1975. The extensor digitorum minor tendon is transferred dorsally to the palmar aspect below the intermetacarpal ligament and then sutured to the radial aspect of the flexor sheath. Brooks stated that this technique leads to correction of the metacarpophalangeal joint of the little finger and abduction¹².

In this technique, the end tendon of the EDM is transferred from its separate compartment in the wrist with the tendons of the extensor digitorum communis, in the extensor retinaculum. Also, in order to check the effect of tendon transfer during the operation, local anesthesia and two short cuts on the back skin are performed. In the center of the metacarpophalangeal joint of the little finger, the first incision of 2 cm length is made. And in the next step, on the base of the first phalanx, the little finger extensor tendon is cut¹².

This study shows the effectiveness of EDM transfer on ulnar deviation of the little finger. In line with the results of our study, other studies showed the effectiveness of the mentioned surgery. The results of a study have shown that in 34 patients with injury below or above the elbow of the ulnar nerve, complete paralysis of adduction and abduction was observed in their little finger⁴.

But contrary to the previous assumptions^{13, 14} the patient's finger claw was not able to abduct their little finger. In Dalon's study, this procedure was performed on ten patients. One of them had mild paralysis and the other patients had severe paralysis. Before the operation, these patients faced problems such as wearing gloves and getting their fingers stuck in pants pockets. With surgery, these problems were solved and the appearance of their hands improved¹⁵.

CONCLUSION

The ulnar nerve is mainly made from the roots of the cervical nerves C8 and T1 and extends to the hand. The ulnar nerve is the most important nerve of the hand and when this nerve is damaged due to the weakness of the major muscles of the hand, many delicate activities and even the strength of the hand are disturbed. This nerve passes through the inner side of the elbow and is very prone to damage in this area. Nerve damage is called neuropathy. Most of the symptoms of this disease occur in the hands and fingers. Many symptoms usually occur when bending the elbow. Correct diagnosis of entrapment is essential to prevent loss of function and sensation in the affected hand and finger. Tendon transfer has been the first technique to correct permanent abduction of the little finger. In this method, the little finger extensor tendon is transferred from the back to the palm, under the intermetacarpal ligament, and then it is sutured to the radial side of the flexor sheath. According to the results of this study, it can be said that tendon transfer is one of the appropriate treatment techniques for ulnar nerve injury.

ACKNOWLEDGMENTS

This research received no specific grant from any funding agency.

CONFLICT OF INTEREST

The authors declare that there is no conflict of interest.

REFERENCES

1. M A. Investigating the causes of ulnar nerve lesions *Journal of the Medical Organization of the Islamic Republic of Iran* 2012;**26**(3).
2. Merlevede K, Theys P, van Hees J. Diagnosis of ulnar neuropathy: a new approach. *Muscle Nerve Suppl* 2000;**23**(4):478-81.
3. Burge P. Abducted little finger in low ulnar nerve palsy. *J Hand Surg Eur Vol* 1986;**11**(2):234-6.
4. Bertelli J, Tavares K. Little finger abduction and adduction testing in ulnar nerve lesions. *Hand Surg Rehabil* 2018;**37**(6):368-71.
5. Woo A, Bakri K, Moran SL. Management of ulnar nerve injuries. *J Hand Surg Am* 2015;**40**(1):173-81.
6. Akinleye SD, Culbertson MD, Cappelletti G, Garofolo G, Choueka J. The relative contribution to small finger abduction of the ulnar versus radial slip of the EDM: Implications for tendon transfers. *HAND* 2018;**13**(6):678-81.
7. Sarla GS. Musculoskeletal Disorders: History Taking, Physical Examination, Investigations and Diagnosis. *Journal of Nursing Science & Practice*; **9**(2):19-27.
8. Edited by Pedro K. Beredjikian M, David J. Bozentka, and Gregory Gallant, MD, MBA. 5 Nerve Anatomy and Physiology, Compression Neuropathies, and Nerve Injuries. 2nd Edition ed: Elsevier; 2021.
9. Karaman S, Ekrem S, Ertem K. The Clinical Results of Tendon Transfers in Patients with Ulnar Palsy. *J Med Case Rep Rev* 2022;**5**(6):1144-52.
10. Bauer B, Chaise F. Correction of ulnar claw hand and Wartenberg's sign. *Hand Surg Rehabil* 2022;**41**:S118-S27.
11. van Aaken J, Zhu J, Fasel JH, Beaulieu J-Y. Investigation of radialization and rerouting of the extensor digiti minimi (EDM) in the abduction deformity of the little finger: a cadaver study. *Hand* 2011;**6**(2):202-5.
12. Bellan N, Belkhiria F, Touam C, Asfazadourian H, Oberlin C. Extensor digiti minimi tendon «rerouting transfer in permanent abduction of the little finger. *Chir Main* 1998;**17**(4):325-33.
13. Kaplan E. Functional and surgical anatomy of the hand, ed 2. Philadelphia, 1965. JB Lippincott co.
14. Tsujino A, Macnicol M. Finger flexion sign for ulnar neuropathy. *J Hand Surg Eur Vol* 1998;**23**(2):240-1.
15. Dellon AL. Extensor digiti minimi tendon transfer to correct abducted small finger in ulnar dysfunction. *J Hand Surg Am* 1991;**16**(5):819-23.