

Cleft Lip Techniques and Surgical Outcome in Patients Referred To Abuzar Children's Hospital in Ahvaz, Southern Iran

Mehran Peyvasteh¹, Vahid Ayati^{1*}, Mahmoud Khosh khabar¹, Shahnam Askarpour¹,
Hoda Ilkhani Pak¹

1. Department of General Surgery, School of Medicine, Abouzar Hospital, Ahvaz Jundishapur University of Medical Sciences, Ahvaz, Iran

ABSTRACT

Background: Cleft lip in infants is associated with severe morphological and functional disorders. Cleft lip is particularly important, which can lead to psychological changes in the patient if the treatment result is not satisfactory. Different surgical methods have been developed in the past decades. We aimed to investigating cleft lip techniques and surgical outcome in patients.

Methods: In this cross-sectional analytical study, 32 patients undergoing cleft lip surgery referred to Abuzar Children's Hospital in Ahvaz, southern Iran between 2022 and 2023 were enrolled. According to the surgeon's opinion, the patients underwent cleft lip surgery using the Sommerlad technique. (n=18 or Millard technique (n=14). Surgical Outcomes were compared between the two groups.

Results: The mean age was 33.58 ± 59.14 months. 65.6% of patients were boys (n=21). The need for rhinoplasty in the Sommerlad and Millard groups was 100% and 84.6%, respectively, and no significant difference was observed between the two groups ($P=0.17$). The cupid's bow was estimated to be good in 28.6% and 38.9% of patients in the Millard and Sommerlad groups, respectively, while this difference between the two groups was not significant ($P=0.51$). There was no significant difference between the two groups in the vermilion border ($P=0.31$). No significant difference was observed between the two groups in terms of white roll match, lip length and Scar appearance ($P>0.05$).

Conclusion: No significant difference was observed in the results of lip surgery between the Sommerlad and Millard techniques. Further multicenter studies with larger sample sizes are recommended to validate these results.

KEYWORDS

Cleft lip; Millard; Sommerlad; Outcome

*Corresponding Author:

Dr. Vahid Ayati

Department of General Surgery,
School of Medicine, Abouzar
Hospital, Ahvaz Jundishapur
University of Medical Sciences,
Ahvaz, Iran

Email: ayativahid8@gmail.com

Received: ***

Accepted: ***

Please cite this paper as:

Peyvasteh M, Ayati V, Khosh khabar M, Askarpour S, Ilkhani Pak H. Cleft Lip Techniques and Surgical Outcome in Patients Referred To Abuzar Children's Hospital in Ahvaz, Southern Iran. World J Plast Surg. 2025;14(2):1-6.
doi: 10.61186/wjps.14.2.**

INTRODUCTION

Congenital anomalies are changes in structure, function, and metabolism present at birth, and there may be one or more anomalies

that lead to physical and mental disorders¹. Cleft lip and palate are one of the most common birth defects with a global prevalence of 1 in 700 live births. Most of these oral clefts are non-syndromic²⁻⁴.

In addition to facial manifestations, functional disorders such as speaking, hearing, chewing, swallowing, and breathing problems result from these disorders. The aim of repair is to restore symmetry and alignment of anatomical landmarks and restore the child's smile⁵. Clefts may be classified as unilateral or bilateral, as well as complete or incomplete⁶.

Complete clefts affect the entire lip and extend into the nose. Incomplete clefts involve a portion of the lip, where there is a bridge connecting the medial and lateral lip elements. Unilateral clefts are usually accompanied by abnormalities of the lip and nose. Bilateral clefts involve clefts on both sides of the lip and nose and the middle part of the lip^{7,8}.

With recent advances in the cleft repair, the procedures for cleft lip and cleft palate, although complex, have become simpler to allow for improvisation and better refinement of the surgical outcome. The procedural complexities and the quest for near-perfect aesthetics and function make this anomaly the recipient of multiple procedures^{9,10}.

A basic technique used for unilateral cleft lip repair is the Millard rotation-advancement technique, which is a geometric flap technique. This technique recognizes the importance of moving the orbicularis oris muscle into the correct anatomical orientation to achieve both cosmetic and functional improvement, and is one of the most widely used techniques¹¹.

In the ideal practice for cleft lip repair, there should be no peaking in the Cupid's bow on the cleft or vermillion side. In addition, the Cupid's bow should have adequate proportions^{12,13}.

It is important to assess the outcomes of cleft lip and palate repair and to improve their quality. Efforts to reduce the incidence of these complications have

been the focus of studies in various reconstructive surgery centers around the world. Due to differences in techniques, as well as the skills and experience of surgeons, the range of outcomes for cleft lip and palate treatment can be significant. Therefore, evaluation of treatment outcomes is essential to identify and implement the highest possible standards of care¹⁴.

Given the limited global studies and the lack of studies on cleft lip surgery outcomes in Iran, we aimed to investigate cleft lip techniques and surgical outcomes.

MATERIAL AND METHODS

In this cross-sectional analytical study, using a census sampling method, 32 patients undergoing cleft lip surgery referred to Abozar Children's Hospital in Ahvaz, southern Iran between 2022 and 2023 were enrolled. Sampling was by census method. Patients with cleft lip who underwent Millard and Sommerlad cleft palate surgery were included. Patients with very wide cleft lip and protruding or rotated premaxilla, patients with other associated congenital anomalies, and patients with a history of previous cleft lip repair surgery at another center were excluded. The surgical repairs were performed by 1 pediatric surgeons highly proficient in cleft surgery, and the surgical method used for each patient was determined by their judgment.

Before the operation, a general assessment of the medical status of all patients was performed. Routine preoperative examinations were performed including hemoglobin levels, prothrombin time, thromboplastin time, etc. Frontal and lateral radiographs were taken of all patients. Measurements of upper lip height, cutaneous upper lip height, and vermillion mucosal height were performed.

Figure 1 and **2** show the patients before the operation and the Sommerlad and Millard technique.

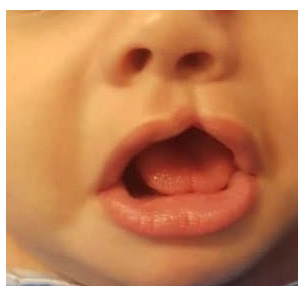


Figure 1: A. Before surgery

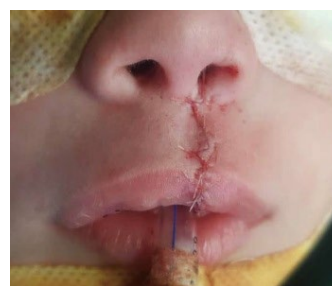


Figure 1: B. After surgery (Millard)

This study was approved by the Golestan Hospital Research Ethics Committee (Ethics code: IR.AJUMS.HGOLESTAN.REC.1403.028).

Moreover, written informed consent has been obtained from parents of patients, or legal guardians.

Statistical analysis

The obtained data were analyzed using IBM SPSS ver. 26 software (IBM Corp., Armonk, NY, USA). Descriptive data, presented as mean and standard deviation were used in quantitative variables and frequency and percentage were used in qualitative variables. T-test (Mann-Whitney) and chi-square test were used for univariate data analysis. A *P*-value of < 0.05 was considered for statistical significance.

RESULTS

The mean age was 33.58 ± 59.14 months. 65.6% of patients were boys ($n=21$). In 43.58% of patients ($n=14$), the parents were consanguine. Cleft lip was observed in 21.9% and 28.1% of patients in the first- and second degree family, respectively. The mean

duration of surgery was 147.74 ± 32.42 minutes. The mean length of hospital stay and stay in the ward was 5.54 ± 1.91 and 4.48 ± 1.45 days, respectively. 43.8% ($n=14$) and 56.2% ($n=18$) were in the Millard and Sommerlad group, respectively (**Table 1**).

Table 2 shows the cleft lip surgery outcomes in the two study groups. The need for rhinoplasty in the Sommerlad and Millard groups was 100% and 84.6%, respectively, and no significant difference was observed between the two groups ($P=0.17$). The cupid's bow was estimated to be good in 28.6% and 38.9% of patients in the Millard and Sommerlad groups, respectively, while this difference between the two groups was not significant ($P=0.51$). The Nostril Symmetry was estimated to be good in 42.9% and 57.1% of patients in the Millard and Sommerlad groups, respectively, while this difference between the two groups was not significant ($P=0.42$).

In the millard group, vermilion border was good and moderate in 50% and 28.6% of patients respectively, while, in the sommerlad group, vermilion border was good and moderate in 77.2% and 22.2% of patients respectively. In terms of vermilion border, no remarkable difference was observed between the

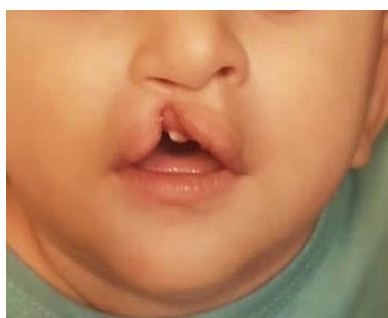

Figure 2: A. Before surgery

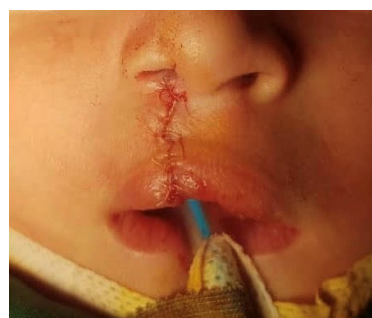

Figure 2: B. After surgery (Sommerlad)

Table 1: Baseline and clinical characteristics of participants

Variable	Results
Age (Month), mean \pm SD	33.58 \pm 59.14
Sex (Boy), n (%)	21 (65.6)
Consanguinity, n (%)	14 (43.58)
Presence of cleft lip in the first-degree family, n (%)	7 (21.9)
Presence of cleft palate in the 2nd degree family, n (%)	9 (28.1)
Duration of surgery (minutes) , mean \pm SD	147.74 \pm 32.42
Length of hospital stay, (Day), mean \pm SD	5.54 \pm 1.91
Length of stay in the ward, (Day), mean \pm SD	4.48 \pm 1.45
Length of stay in the ICU, (Day), mean \pm SD	1.26 \pm 0.27
Type of technique, n (%)	Millard Sommerlad
	14 (43.8) 18 (56.2)

Table 2: Cleft lip surgery outcomes in the two study groups

Variable		Millard technique	Sommerlad technique	P-value
Need for rhinoplasty, n (%)	Yes	11 (100)	11 (84.6)	0.17
	No	0	2 (15.4)	
Alar dome, n (%)	Good	4 (28.6)	4 (22.2)	0.68
	Poor	10 (71.4)	14 (77.8)	
Cupids bow, n (%)	Good	4 (28.6)	7 (38.9)	0.51
	Average	10 (71.4)	10 (55.6)	
	Poor	0	1 (5.6)	
Lip length, n (%)	Good	8 (57.1)	14 (77.8)	0.31
	Average	5 (35.7)	4 (22.2)	
	Poor	1 (7.1)	0	
Scar appearance, n (%)	Good	8 (57.1)	9 (50)	0.89
	Average	5 (35.7)	7 (38.9)	
	Poor	1 (7.1)	2 (11.1)	
Vermilion border, n (%)	Good	7 (50)	13 (72.2)	0.31
	Average	4 (28.6)	4 (22.2)	
	Poor	3 (21.4)	1 (5.6)	
White roll match, n (%)	Good	11 (78.6)	9 (50)	0.11
	Average	1 (7.1)	7 (38.9)	
	Poor	2 (14.3)	2 (11.1)	
Vermilion border, n (%)	Perfect	7 (31.8)	15 (68.2)	0.12
	Disparity <1	4 (66.7)	2 (33.3)	
	Disparity >1	3 (75)	1 (25)	
Alar base, n (%)	Good	4 (44.4)	5 (55.6)	0.99
	Average	7 (43.8)	9 (56.3)	
	Poor	3 (42.9)	4 (57.1)	
Nostril Symmetry, n (%)y	Good	3 (42.9)	4 (57.1)	0.42
	Average	9 (52.9)	8 (47.1)	
	Poor	2 (25)	6 (75)	

two groups ($P=0.31$). No significant difference was observed between the two groups in terms of white roll match, lip length and Scar appearance ($P>0.05$). More details are provided in **Table 2**.

DISCUSSION

Cleft lip and palate is one of the most common congenital malformations of the skull and face (craniofacial)^{15,16}. The anomaly is characterized by a loss of integrity of the lip muscles, alveolar bone, and hard and soft palate. The severity of the anomaly can range from a small hole in the lip to a large fissure extending into the roof of the mouth and nose^{15,17}. Studies have been conducted to investigate the outcomes of different cleft lip techniques, but to our current knowledge, this is the first study to investigate the outcomes of the Sommerlad and Millard surgical technique in patients with cleft lip. According to our results, the two Sommerlad and Millard surgical technique did not differ in terms of outcome. In the study by Adetayo et al., the Millard rotation

advancement group had a more flattened nose than the Tennison-Randall (TR) group. Essentially, there was no major difference in overall results between the advancements of the two techniques. Both the Millard and Tennison-Randall techniques required significant improvements in the appearance of the scar on the upper and lower lip¹⁸. The overall results of this study were consistent with the results of the present study. The difference between our study and the study by Adetayo et al. was the difference in the techniques used for comparison.

In the study by Adetayo et al., 21% of parents of patients in the Millard group and 7% in the TR group were not satisfied with Cupid's bow. The Millard technique has been criticized by various authors. In contrast, the TR technique produces a nearly normal Cupid's bow. No significant superiority of the two techniques was observed for the Cupid's bow¹⁸. This may be related to the ability of the Millard surgeon in their study to produce a normal-appearing Cupid's bow. The results of this study in terms of Cupid's bow were similar to the findings of the current study.

There is a consensus that Millard cleft lip repair produces better nasal symmetry than TR repair. However, a study by Adetayo et al. found more symmetrical noses in TR than in Millard repair subjects¹⁸. In our study, nasal symmetry did not differ significantly between the Sommerlad and Millard techniques. This may be due to other factors, such as the width of the cleft and the skill of the surgeon, which were not investigated. The outcome of nasal reconstruction worsens with increasing width of the cleft deformity, but an experienced and skilled surgeon can achieve good nasal appearance even in wide cleft deformities. However, researchers have suggested the use of a preoperative orthopedic technique to deform a wide cleft.

In the study by Kuaffmann et al., the development of vertical symmetry of the philtrum and vermillion lip on the cleft side compared to the healthy side differed depending on the Pfeifer and Millard techniques. The height of the cleft lip was shorter than on the healthy side in both methods, but the difference was significantly greater in the Pfeifer group. The height of the vermillion lip on the cleft side was slightly shorter in the Millard group. It was concluded that both methods could achieve good symmetry results for the vertical dimension of the lip, and the Millard technique showed better results regarding the symmetry of the philtrum and vermillion lip during growth in the first 6 years¹⁹. The findings of this study are inconsistent with the results of the current study. Differences in sample size, different study designs, and surgeon expertise may be the reason for these discrepancies.

In the study by Kuaffmann et al., vermillion length was found to be inconsistent between the Millard and Pfeifer groups, with results differing between the two groups¹⁹.

While in our study, no statistically significant difference was observed between the two groups in terms of Vermilion border. The difference in sample size and individual characteristics of the surgeon may be the reason for the difference in results. Similar to the findings of our study, in the study of Kuaffmann et al., the total lip height was not significantly different in both groups¹⁹.

CONCLUSION

No significant differences in outcomes were observed between the Sommerlad and Millard techniques.

Surgeon expertise and/or individual preferences are important factors to consider when choosing a procedure for unilateral cleft lip repair. One of the limitations of the present study is the small sample size and single-center study. It is recommended that further multicenter studies with larger sample sizes be conducted to compare the outcomes of the Sommerlad and Millard surgical techniques in patients with cleft lip.

ACKNOWLEDGMENTS

No financial support was received.

CONFLICT OF INTERESTS

There is no conflict of interests.

REFERENCES

1. Hosseini SN, Kalantar-Hormozi A, Vakili M, Yariqoli F, Hosseini N. Epidemiology of lip and palate clefts in northwest of Iran: Prevalence, surgery complications and unrepaired patients younger than 18 years old. *Clin Epidemiol Global Health* 2019;7(1):6-10.
2. Raghavan U, Vijayadev V, Rao D, Ullas G. Postoperative management of cleft lip and palate surgery. *Facial Plast Surg* 2018;34(06):605-11.
3. Peyvasteh M, Askarpour S, Moradi N, Mansouri A. Comparison of the Outcomes of Surgical Repair of Cleft Palate Performed by Modified Von Langenbeck and Bardach (Two-Flap Palatoplasty) Methods. *World J Plast Surg* 2023;12(3):94.
4. Zajac DJ, Vallino-Napoli LD. Evaluation and management of cleft lip and palate: A developmental perspective: Plural Publishing; 2024.
5. Paranaíba LMR, Miranda RTd, Ribeiro LA, Barros LMD, Martelli-Júnior H. Frequency of congenital craniofacial malformations in a Brazilian Reference Center. *Revista Brasileira de Epidemiologia* 2011;14:151-60.
6. Samuel S, Prasad BR, Kumari S, Tejaswi SS, Sanal T. A clinical study of incidence and distribution and co-relating factors of cleft lip and cleft palate among karnataka & kerala population. *J Health Allied Sci NU* 2014;4(03):066-9.
7. Monson LA, Khechoyan DY, Buchanan EP, Hollier LH. Secondary lip and palate surgery. *Clin Plast Surg* 2014;41(2):301-9.
8. Pradnyandari NKPD. Aesthetic outcome comparison between Millard and Fisher technique for cleft lip surgery: a literature review. *Indonesia J Biomed Sci* 2023;17(2):153-9.

9. Aycart MA, Caterson EJ. Advances in Cleft Lip and Palate Surgery. *Medicina (Kaunas)* 2023 Nov 1;**59**(11).
10. Oh TS, Kim YC. A comprehensive review of surgical techniques in unilateral cleft lip repair. *Arch Craniofac Surg* 2023 Jun;**24**(3):91-104.
11. Narayanan PV. Millard's rotation advancement technique for unilateral cleft lip repair. *Journal of Cleft Lip Palate and Craniofacial Anomalies* 2021;**8**(2):157-62.
12. Christofides E, Potgieter A, Chait L. A long term subjective and objective assessment of the scar in unilateral cleft lip repairs using the Millard technique without revisional surgery. *J Plast Reconstr Aesthet Surg* 2006;**59**(4):380-6.
13. Adetayo AM, Adetayo MO, Adeyemo WL, James OO, Adeyemi MO. Unilateral cleft lip: evaluation and comparison of treatment outcome with two surgical techniques based on qualitative (subject/guardian and professional) assessment. *J Korean Assoc Oral Maxillofac Surg* 2019 Jun;**45**(3):141-51.
14. Peyvasteh M, Askarpour S, Moradi N, Mansouri A. Comparison of the Outcomes of Surgical Repair of Cleft Palate Performed by Modified Von Langenbeck and Bardach (Two-Flap Palatoplasty) Methods. *World J Plast Surg* 2023;**12**(3):94-9.
15. Vyas T, Gupta P, Kumar S, Gupta R, Gupta T, Singh HP. Cleft of lip and palate: A review. *J Family Med Prim Care* 2020 Jun;**9**(6):2621-5.
16. Vyas T, Gupta P, Kumar S, Gupta R, Gupta T, Singh HP. Cleft of lip and palate: A review. *J Family Med Primary Care* 2020;**9**(6):2621-5.
17. Candotto V, Oberti L, Gabrione F, et al. Current concepts on cleft lip and palate etiology. *J Biol Regul Homeost Agents* 2019;**33**(3 Suppl. 1):145-51. DENTAL SUPPLEMENT.
18. Adetayo AM, Adetayo MO, Adeyemo WL, James OO, Adeyemi MO. Unilateral cleft lip: evaluation and comparison of treatment outcome with two surgical techniques based on qualitative (subject/guardian and professional) assessment. *J Korean Assoc Oral Maxillofac Surg* 2019;**45**(3):141.
19. Kauffmann P, Cordesmeier R, Fouellefack GA, Schminke B, Wiese K-G. Postoperative long-term results for the comparison of the symmetry of the upper lip during lip closure according to Millard and Pfeifer. *Maxillofac Plast Reconstr Surg* 2018;**40**:1-6.