

# Spontaneous Bone Regeneration followed by Segmental Resection of Mandibular Unicystic Ameloblastoma with Primary Reconstruction in 12-Year-Old Girl: A Case Report

Sara Pilehvar <sup>1</sup>, Ashkan Golabkesh Afshar <sup>1</sup>, Saleh Dadmehr <sup>1</sup>, Alireza Shirzadeh <sup>1</sup>,  
Shayan Yousefi <sup>2</sup>, Sahand Samieirad <sup>1\*</sup>

1. Department of Oral & Maxillofacial Surgery, faculty of Dentistry, Mashhad University of Medical Sciences, Mashhad, Iran

2. Student Research Committee, Faculty of Dentistry, Mashhad University of Medical Sciences, Iran

## ABSTRACT

The rare odontogenic tumor known as ameloblastoma presents serious problems for kids because of its aggressive nature and capacity to hinder development and function. In order to maximize results, the mural subtype of unicystic ameloblastoma necessitates precision surgical intervention and creative restorative techniques. A 12-year-old girl who presented with discomfort, swelling, and tenderness in her left mandible is described in this report. The patient was admitted to Velayat Hospital in Mashhad, Iran, in 2024 and received the necessary medical treatment there. Histopathological and radiographic analysis verified mural ameloblastoma. A segmental resection of the mandible was part of the treatment, with an emphasis on protecting vital anatomical features including the inferior alveolar nerve and periosteum. Allograft and xenograft materials were applied after a prefabricated plate was used to accomplish reconstruction. Frequent radiography follow-ups showed excellent mandibular continuity restoration and spontaneous bone regeneration. Occlusal modifications boosted functional outcomes, guaranteeing both functional and aesthetic rehabilitation. This example emphasizes the value of a customized strategy in the treatment of pediatric ameloblastoma, stressing the need to strike a balance between growth preservation and efficient tumor eradication. The treatment addressed the aggressive character of the tumor while reducing the chance of recurrence by combining precise surgical procedures with cutting-edge reconstructive strategies. Results were further improved by the use of adaptive dental measures and the preservation of important components. Managing pediatric ameloblastoma requires a customized, multidisciplinary treatment plan. This case demonstrates the efficacy of combining radical and conservative procedures to provide long-term growth, functional restoration, and minimal recurrence risk. Early diagnosis, meticulous surgical planning, and continuous postoperative monitoring enabled the positive results..

## KEYWORDS

Ameloblastoma, Segmental Resection, Mandibular Reconstruction, Bone Regeneration, Case report

## \*Corresponding Author:

Sahand Samieirad

Department of Oral & Maxillofacial Surgery, faculty of Dentistry, Mashhad University of Medical Sciences, Mashhad, Iran

Tel.: +98 912 813 7859

Email: [Samieerads@mums.ac.ir](mailto:Samieerads@mums.ac.ir)

Received: \*\*\*

Accepted: \*\*\*

## Please cite this paper as:

Pilehvar S, Golabkesh Afshar A, Dadmehr S, Shirzadeh A, Yousefi S, Samieirad S. Spontaneous Bone Regeneration followed by Segmental Resection of Mandibular Unicystic Ameloblastoma with Primary Reconstruction in 12-Year-Old Girl: A Case Report. World J Plast Surg. 2025;14(2):1-10. doi: 10.61186/wjps.14.2.\*\*

## INTRODUCTION

Ameloblastoma is a benign odontogenic tumor that mainly affects the jawbone but can be aggressive locally. If treatment is not received, it can cause significant local invasion and has a high recurrence rate. It begins in the tooth germ's epithelial remnants<sup>1-6</sup>. Only 20% of ameloblastoma are discovered in the upper jaw, with the rest (approximately 80%) occurring in the mandible, especially in the area of the third molar. Extragnathic occurrences, such as in the sinonasal tract, are extremely rare<sup>5,7</sup>. Numerous genetic pathways, such as the WNT/ $\beta$ -catenin signaling pathway, sonic hedgehog, and mitogen-activated protein kinase, are dysregulated in ameloblastoma, and their formation and recurrence is associated with these pathways. These molecular factors are crucial in understanding the pathogenesis and potential therapeutic targets for ameloblastoma<sup>1</sup>.

The extent of ameloblastomatous epithelial proliferation dictates the luminal, intraluminal, and mural histological classifications<sup>8</sup>. Mural ameloblastoma is a subtype of unicystic ameloblastoma, which is a variant of ameloblastoma characterized by its cystic nature. In contrast to other unicystic ameloblastoma subtypes, it is renowned for acting aggressively. In contrast to other kinds such as luminal and intraluminal ameloblastoma, this one involves the proliferation of ameloblastoma cells into the fibrous wall of the cyst, which may result in more aggressive behavior and a higher chance of recurrence<sup>9-11</sup>. Mural ameloblastoma exhibit a high proliferative index, increased angiogenesis, and strong protease activity, indicating a more aggressive phenotype<sup>10</sup>. Patients with mural ameloblastoma have a higher risk of recurrence compared to those with luminal or intraluminal subtypes<sup>9,12</sup>. Mural ameloblastoma often exhibit a heterogeneous histology, including follicular, acanthomatous, and desmoplastic regions. By identifying these characteristics by biopsy and histological examination, mural ameloblastoma can be diagnosed<sup>11</sup>.

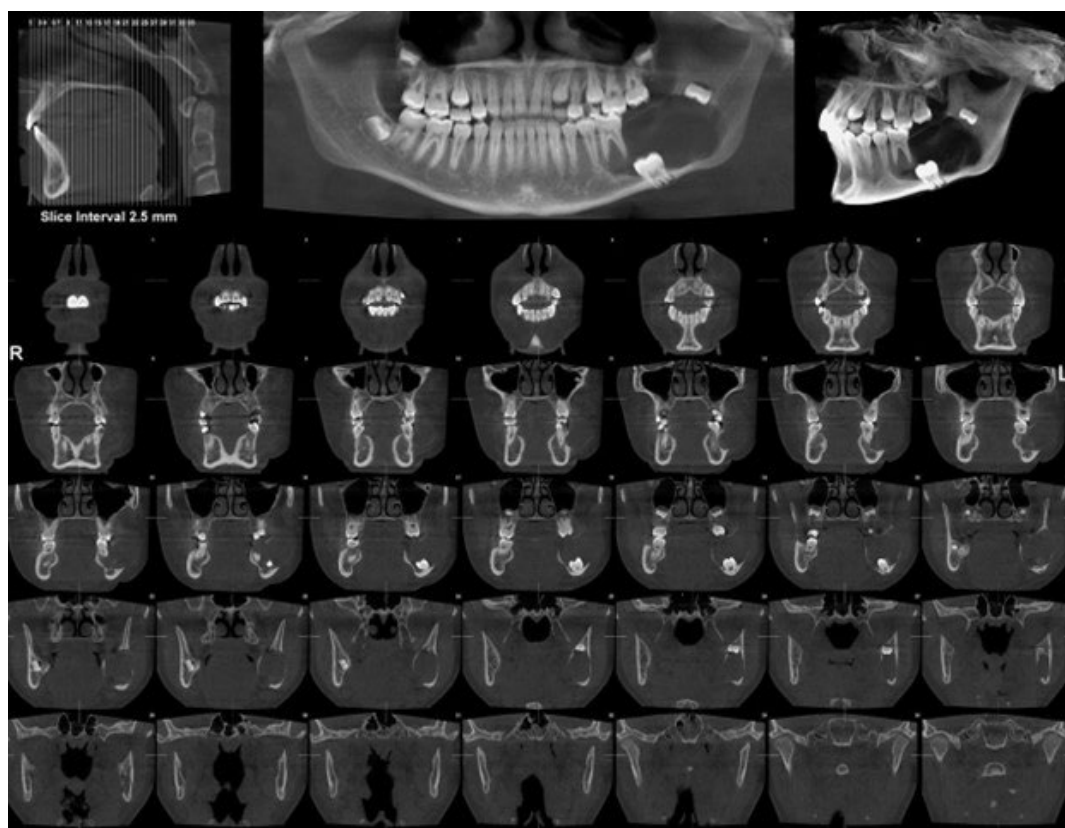
The treatment of mural ameloblastoma is complex due to its potential for recurrence and the need to balance effective management with minimizing patient morbidity. Marsupialization, enucleation with Carnoy's solution, and radical surgery are key surgical treatment approaches for managing unicystic

ameloblastoma, including the mural subtype. Marsupialization has proven effective in reducing the size of cystic lesions; however, the mural subtype poses a higher recurrence risk, often requiring additional surgical interventions<sup>9</sup>. Enucleation, combined with the application of Carnoy's solution, shows a promising reduction in recurrence rates, reported at 10% even when 93% of cases involve mural invasion, highlighting the solution's efficacy in controlling disease progression<sup>12,13</sup>. For aggressive or recurrent cases, radical surgery involving resection with wide margins is recommended, demonstrating significantly lower recurrence rates compared to conservative approaches, making it a preferred option in such contexts<sup>14,15</sup>. The utilization of adjuvant therapies, such as Carnoy's solution post-enucleation, has been documented to substantially reduce recurrence rates, indicating its advantage in the treatment protocol for mural ameloblastoma<sup>13</sup>. This case report describes a 12-year-old girl with a mural ameloblastoma in the left mandible, identified with CBCT imaging and histopathological analysis. Thorough care encompassed segmental excision and rebuilding to facilitate functional rehabilitation and reduce recurrence.

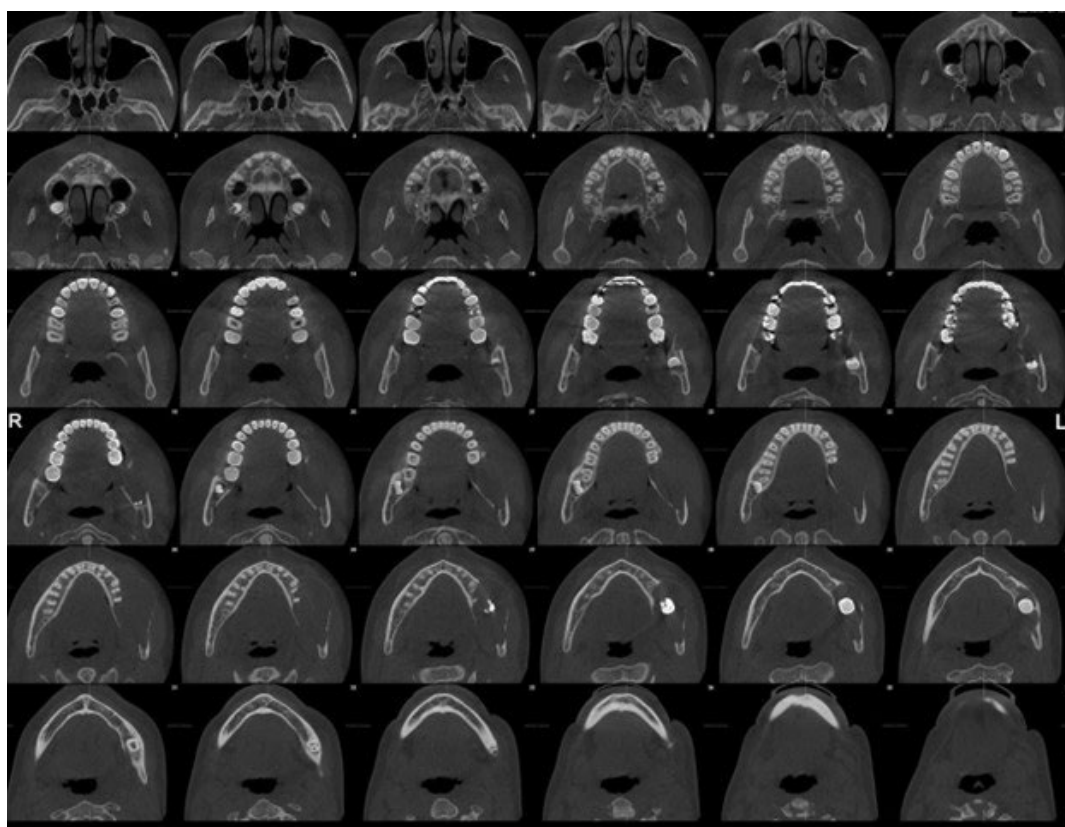
## CASE PRESENTATION

A 12-year-old girl complained of increasing pain, swelling, soreness, and movement in the area surrounding her left mandibular first molar. The patient was admitted to Velayat Hospital in Mashhad, Iran, in 2024 and received the necessary medical treatment there. Significant intraoral edema, especially in the posterior mandible, and impaired occlusal function were found during the clinical assessment. Cone-beam computed tomography (CBCT) and other radiographic evaluations showed an impacted second molar connected to a distinct, unilocular radiolucent lesion in the left jaw. Based on the clinical symptoms and radiological appearance, unicystic ameloblastoma was strongly suspected. Figures 1 and 2 illustrate the pre-biopsy CBCT images, delineating the lesion's relationship to the adjacent structures and highlighting the severity of the impacted molar within the mandible. These findings formed the basis for initial treatment planning.

The histological analysis verified the diagnosis of mural ameloblastoma, an aggressive variant of



**Figure 1:** The radiolucent lesion and impacted second molar are visible on the preoperative CBCT scan



**Figure 2:** An additional CBCT picture of the lesion, showing how large it is in the left mandible.

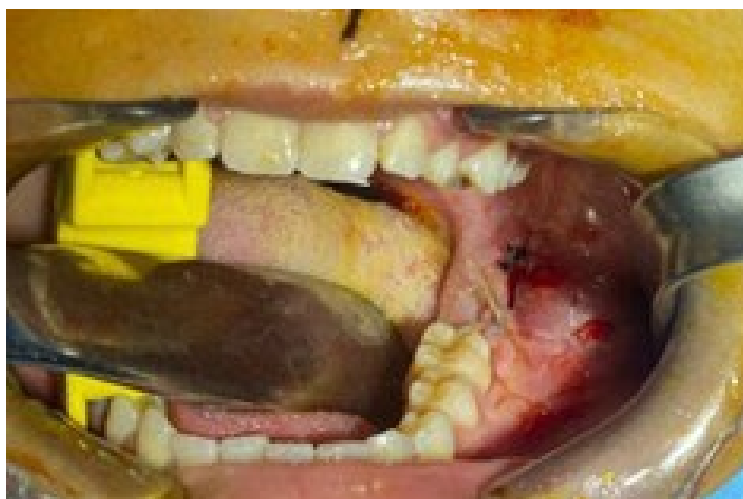unicystic ameloblastoma, following an incisional biopsy carried out under local anesthetic. During the biopsy procedure, the developing bud of the third molar was intentionally removed to mitigate future complications associated with its eruption in a pathological environment. Figure 3 shows the biopsy site before definitive surgery, emphasizing the extensive exposure required for accurate diagnosis. Because of the type of lesion, surgery was considered required. The surgical team used general anesthesia to do a segmental excision of the left mandible. By preserving the periosteum, the procedure was performed intraorally to promote future bone growth. The impacted second molar, erupted first molar, and the second premolar were surgically removed alongside the pathological lesion. Finally,

the excised tumor and teeth were analyzed, documenting the extent and successful removal of all pathological tissues.

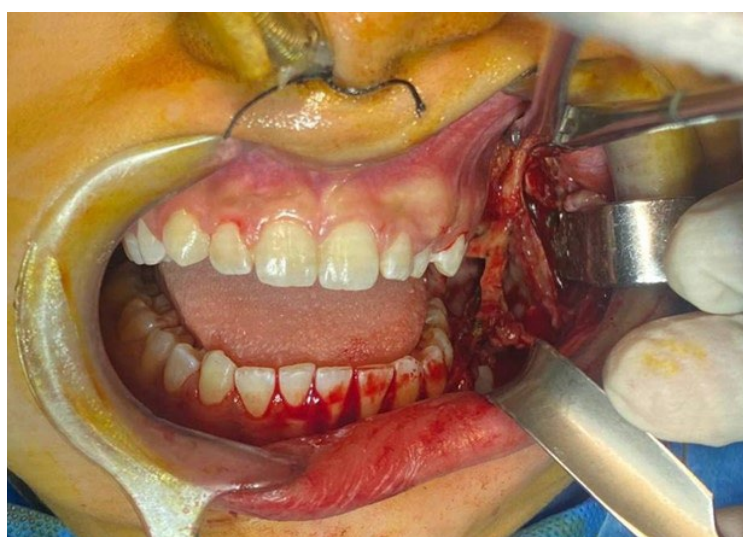Figure 4 highlights the meticulous preservation of the inferior alveolar nerve during resection, which is a critical consideration in maintaining sensory function in the mandible.

Figure 5 highlights the macroscopic view of the resected tumor and the removed teeth, underscoring the scope of the surgical intervention. Careful attention was given to preserving the continuity of the mandible and the inferior alveolar nerve during tumor excision.

Mandibular continuity was maintained by placing a pre-fabricated reconstruction plate. The plate, contoured extraorally to fit the patient's mandibular



**Figure 3:** The biopsy site's intraoral image prior to resectional surgery



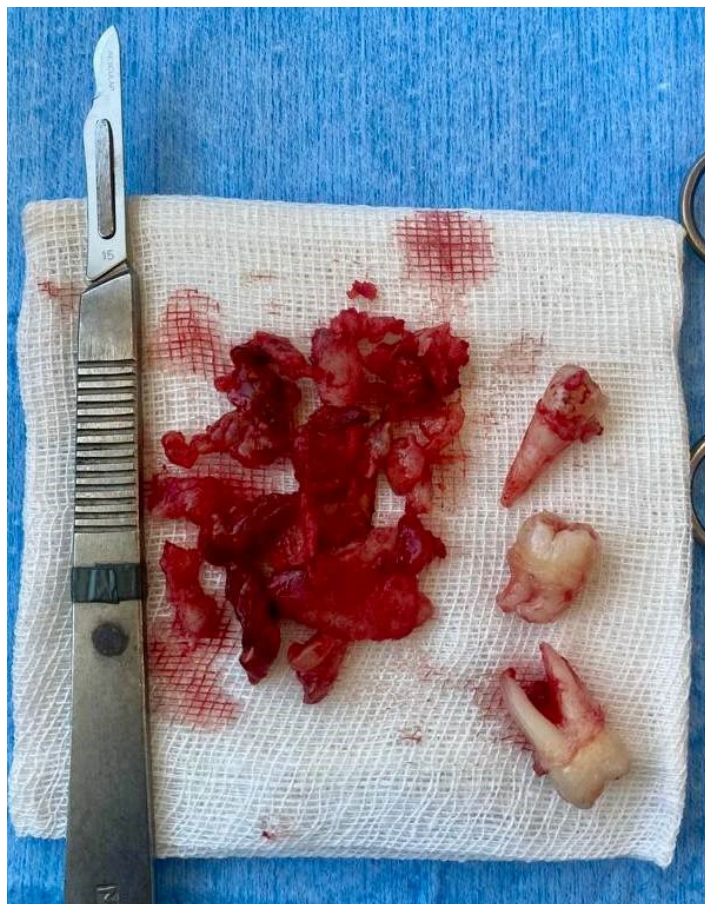**Figure 4:** Removing the tumor surgically while protecting the inferior alveolar nerve



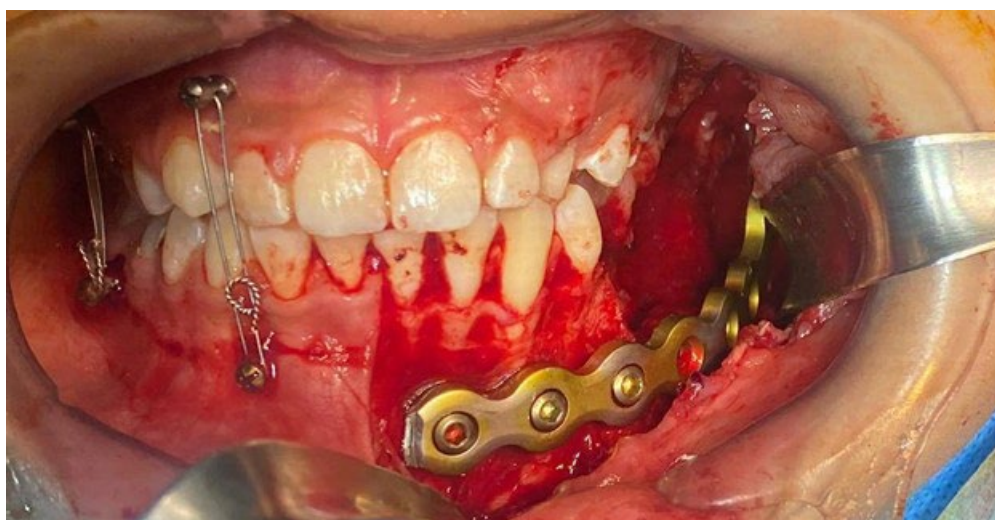
anatomy, extended from the left incisor region to the ascending ramus and was secured with four screws. To further stabilize the occlusion during the immediate postoperative period, intermaxillary fixation (IMF) screws were utilized. The superior border of the reconstruction plate was secured via

a trocar incision to optimize stabilization. Figures 6 and 7 depict the reconstruction plate in position, demonstrating the maintenance of mandibular continuity and appropriate occlusal alignment achieved with IMF screws.

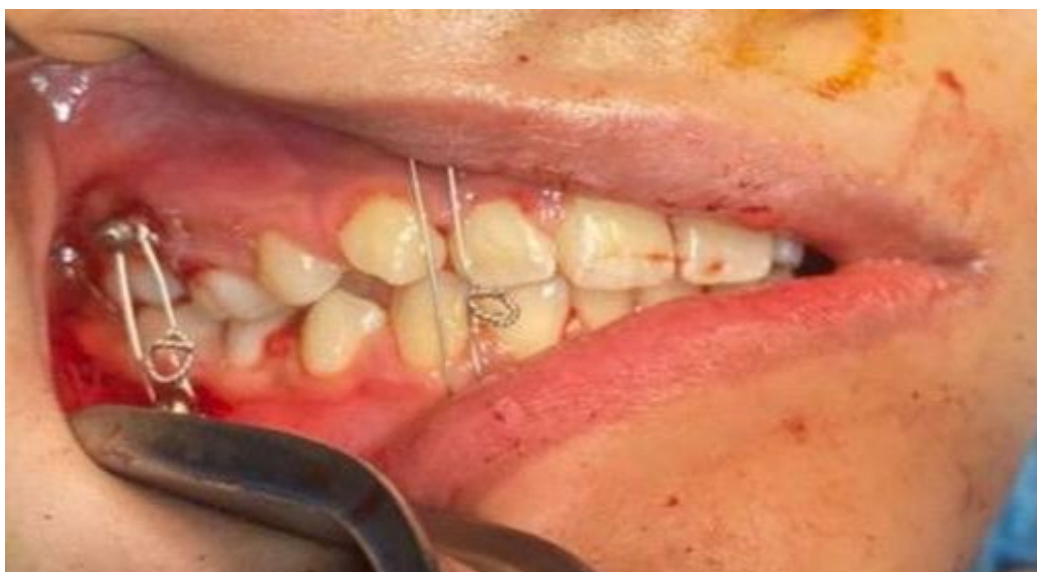Postoperatively, the patient showed an excellent



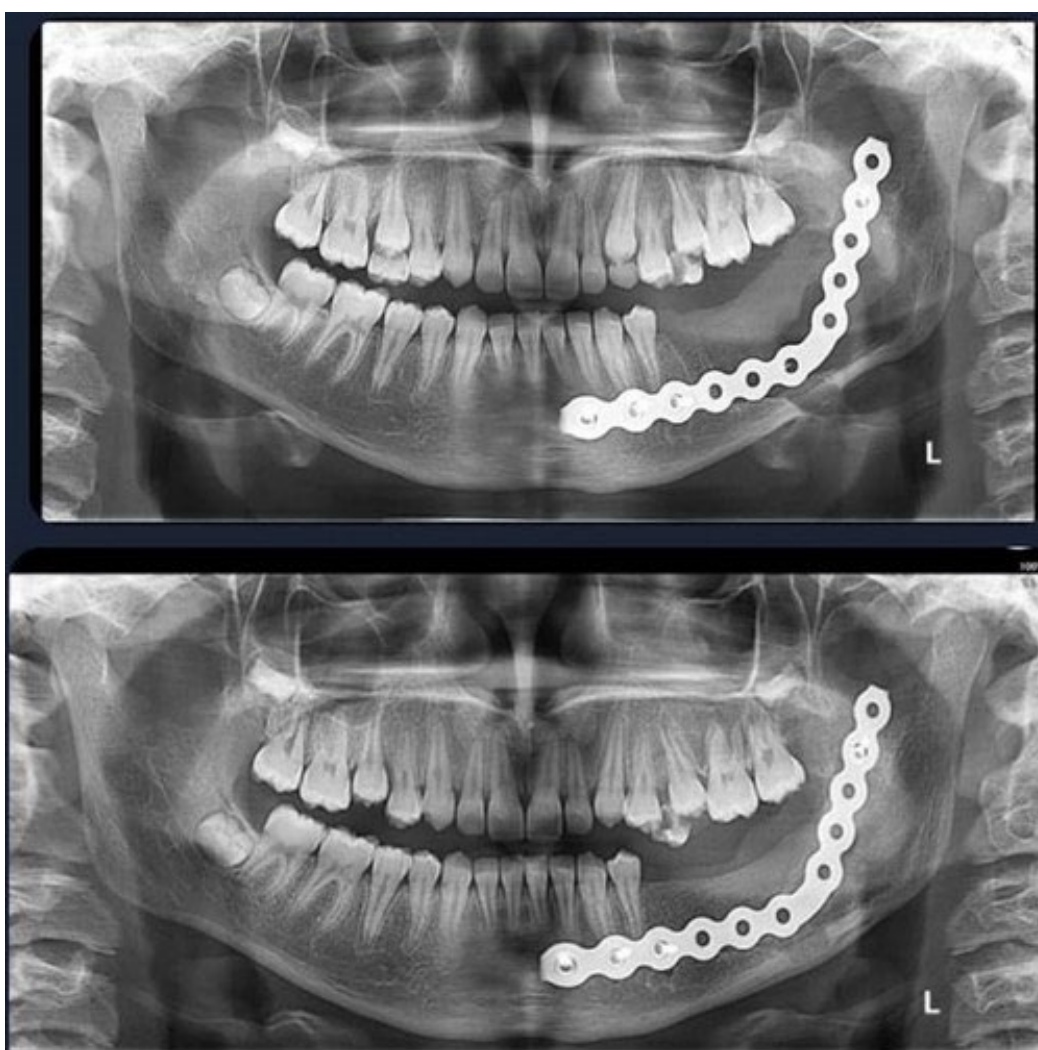**Figure 5:** Macroscopic image of the removed teeth and the excised tumor



**Figure 6:** At the surgical site, a reconstruction plate is positioned to guarantee occlusal stability and mandibular continuity

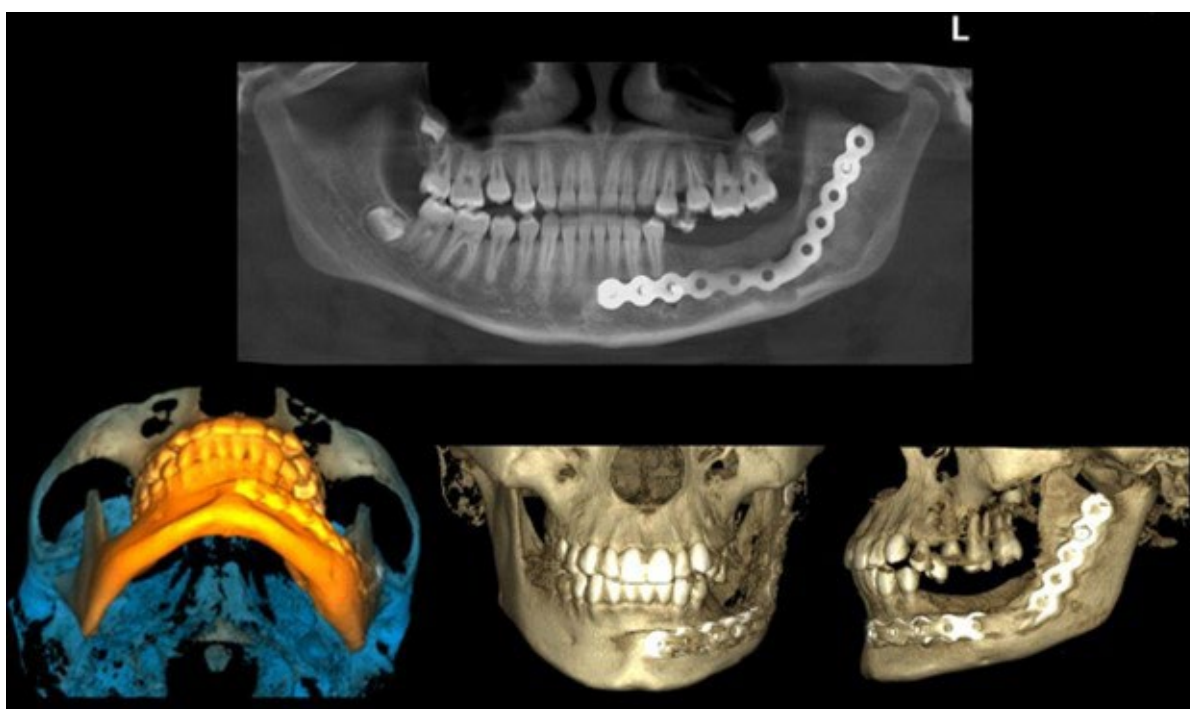


**Figure 7:** During surgery, IMF screws are used to establish the right occlusal alignment

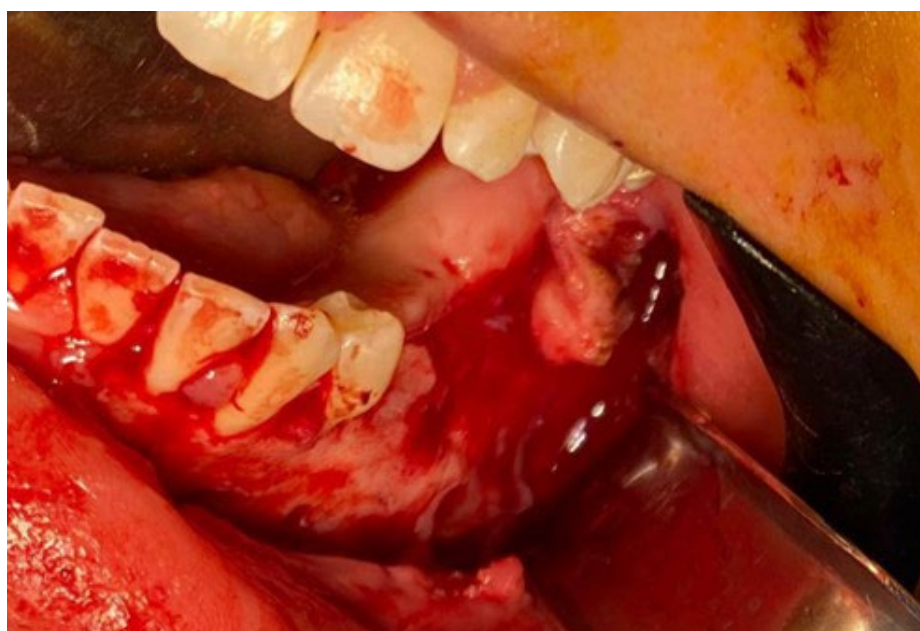

**Figure 8:** Radiographs taken two and four months after surgery that demonstrate increasing bone regeneration





**Figure 9:** After five months, a radiograph



**Figure 10:** An intraoral image showing bone healing following the removal of the restoration plate

recovery. Monthly radiographic follow-ups indicated spontaneous osteogenesis in the resected site. Radiographs taken at two and four months postoperatively exhibited progressive bone regeneration in the resected area. Figure 8 illustrates these radiographic images, providing evidence of early-stage bone healing.

Follow-up imaging confirmed newly formed bone, ensuring adequate osseous continuity. Figure 9 presents a radiograph taken five months postoperatively. Following the acquisition of informed consent and in accordance with the Mashhad University of Medical Sciences' ethical code (IR.MUMS.REC.1404.048), the patient informed



**Figure 11:** Following surgery, the reconstructive plate was removed, and the site showed signs of bone consolidation

of the surgical plan and the type of lesion. At five months, significant mandibular growth necessitated the removal of the reconstruction plate. Upon removal, residual gaps in the bone were filled with a combination of xenograft and autograft materials to enhance osseous continuity and promote further regeneration.

Figure 10 shows the intraoral condition after the removal of the reconstruction plate, emphasizing bone consolidation.

Figure 11 provides a macroscopic view of the reconstruction plate post-removal and demonstrates the formation of stable new bone at the resection site.

This case emphasizes how important careful surgical planning and execution are when treating a child with ameloblastoma. The treatment program guaranteed both functional rehabilitation and the possibility of future dental implants following skeletal maturity by placing a high priority on the preservation of anatomical elements like the periosteum and inferior alveolar nerve, encouraging spontaneous osteogenesis, and using a rebuilding technique adapted to patient growth.

## DISCUSSION

The rare, benign, but locally aggressive tumor known as ameloblastoma in children mainly affects the jaw. Management of ameloblastoma presents

a challenge amplified in children due to the high local morbidity and recurrence rate<sup>16</sup>. Treatment strategies vary, with a focus on balancing effective tumor removal and minimizing impact on facial growth and function. The nature and aggressiveness of the tumor determine the treatment strategy for ameloblastoma; conservative, radical, and targeted therapies all have different functions. Conservative Treatment includes enucleation and curettage, often used for unicystic ameloblastoma. However, this approach has a higher recurrence rate, especially for solid/multicystic types, with recurrence rates reported as high as 40% in some studies<sup>12, 15, 17</sup>. This treatment is more suitable for less aggressive types like the luminal unicystic ameloblastoma<sup>12, 18</sup>.

**Radical Treatment:** Involves resection with clear margins and is recommended for solid/multicystic ameloblastoma due to their higher recurrence rates when treated conservatively<sup>14, 15, 19</sup>. Radical surgery is often necessary for cases with mural invasion or when the tumor is of the solid type<sup>9, 17</sup>.

In children, considerations for ameloblastoma treatment include histological variants, recurrence risks, and geographical variations. The plexiform type is more common in pediatric cases and is generally less aggressive than the follicular type, which can influence treatment strategies<sup>18</sup>. Long-term follow-up is essential, particularly for conservatively treated cases, due to the potential for late recurrences<sup>9, 19</sup>. Additionally, geographical and demographic



variations impact presentation and outcomes, with unicystic types being more prevalent in Western populations compared to higher occurrences of other forms in African populations, underscoring the need for region-specific approaches to diagnosis and management<sup>17, 20</sup>.

In this instance, a 12-year-old girl complained of mandibular pain and swelling when she arrived at the dental clinic. A reconstruction plate was inserted after mandibular excision was carried out after histological confirmation of mural ameloblastoma. Due to the high recurrence rate of the tumor, the patient underwent bi-monthly follow-ups with orthopantomography, which revealed spontaneous bone regeneration. Consequently, five months post-operation, the reconstruction plate was removed, and the residual defect was filled with allograft and xenograft materials. To minimize the risk of tumor recurrence, the involved teeth were extracted. However, if impacted teeth demonstrated the potential for eruption, preservation was considered. For cases requiring tooth extraction, restoration of function and occlusion is prioritized, particularly in growing children, where jaw development is critical.

## CONCLUSION

In this case report, a comprehensive approach to managing mural ameloblastoma in a pediatric patient demonstrated favorable outcomes. Early intervention with segmental resection, strategic preservation of anatomical structures, and postoperative reconstruction facilitated spontaneous bone regeneration and functional rehabilitation. The utilization of allograft and xenograft materials in defect repair, coupled with close monitoring, underscores the importance of a tailored treatment strategy in mitigating recurrence risk while ensuring long-term growth and occlusion in growing children. This multidisciplinary approach highlights the delicate balance required in treating aggressive odontogenic tumors in pediatric populations.

## CONFLICT OF INTEREST

The authors declare that there is no conflict of interests.

## REFERENCES

1. Effiom OA, Ogundana OM, Akinshipo AO, Akintoye

- SO. Ameloblastoma: current etiopathological concepts and management. *Oral Dis* 2018 Apr;**24**(3):307-16.
2. McClary AC, West RB, McClary AC, et al. Ameloblastoma: a clinical review and trends in management. *Eur Arch Otorhinolaryngol* 2016 Jul;**273**(7):1649-61.
3. Fuchigami T, Ono Y, Kishida S, Nakamura N. Molecular biological findings of ameloblastoma. *Jpn Dent Sci Rev* 2021 Nov;**57**:27-32.
4. Kreppel M, Zöller J. Ameloblastoma-Clinical, radiological, and therapeutic findings. *Oral Dis* 2018 Mar;**24**(1-2):63-6.
5. Masthan KM, Anitha N, Krupaa J, Manikkam S. Ameloblastoma. *J Pharm Bioallied Sci* 2015 Apr;**7**(Suppl 1):S167-70.
6. Pandiar D, Anand R, Kamboj M, Narwal A, Shameena PM, Devi A. Metastasizing Ameloblastoma: A 10 Year Clinicopathological Review with an Insight Into Pathogenesis. *Head Neck Pathol* 2021 Sep;**15**(3):967-74.
7. Schafer DR, Thompson LD, Smith BC, Wenig BM. Primary ameloblastoma of the sinonasal tract: a clinicopathologic study of 24 cases. *Cancer* 1998 Feb 15;**82**(4):667-74.
8. Garcia NG, Oliveira DT, Rodrigues MT. Unicystic Ameloblastoma with Mural Proliferation Managed by Conservative Treatment. *Case Rep Pathol* 2016;**2016**:3089540.
9. Zheng CY, Cao R, Hong WS, Sheng MC, Hu YJ. Marsupialisation for the treatment of unicystic ameloblastoma of the mandible: a long-term follow up of 116 cases. *Br J Oral Maxillofac Surg* 2019 Sep;**57**(7):655-62.
10. Sah P, Menon A, Kamath A, Chandrashekar C, Carnelio S, Radhakrishnan R. Role of immunomarkers in the clinicopathological analysis of unicystic ameloblastoma. *Dis Markers* 2013;**35**(5):481-8.
11. Mahadesh J, Rayapati DK, Maligi PM, Ramachandra P. Unicystic ameloblastoma with diverse mural proliferation - a hybrid lesion. *Imaging Sci Dent* 2011 Mar;**41**(1):29-33.
12. Seintou A, Martinelli-Kläy CP, Lombardi T. Unicystic ameloblastoma in children: systematic review of clinicopathological features and treatment outcomes. *Int J Oral Maxillofac Surg* 2014 Apr;**43**(4):405-12.
13. Lee PK, Samman N, Ng IO. Unicystic ameloblastoma-use of Carnoy's solution after enucleation. *Int J Oral Maxillofac Surg* 2004 Apr;**33**(3):263-7.
14. Neagu D, Escuder-de la Torre O, Vázquez-Mahía I, et al. Surgical management of ameloblastoma. Review of literature. *J Clin Exp Dent* 2019 Jan;**11**(1):e70-e5.
15. Hendra FN, Natsir Kalla DS, Van Cann EM, de Vet HCW, Helder MN, Forouzanfar T. Radical vs conservative treatment of intraosseous

- ameloblastoma: Systematic review and meta-analysis. *Oral Dis* 2019 Oct;**25**(7):1683-96.
16. Cadavid AMH, Araujo JP, Coutinho-Camillo CM, Bologna S, Junior CAL, Lourenço SV. Ameloblastoma: current aspects of the new WHO classification in an analysis of 136 cases. *Surgical and Experimental Pathology* 2019 2019/06/14;**2**(1):17.
  17. Ord RA, Blanchaert RH, Jr., Nikitakis NG, Sauk JJ. Ameloblastoma in children. *J Oral Maxillofac Surg* 2002 Jul;**60**(7):762-70; discussion, 70-1.
  18. Takahashi K, Miyauchi K, Sato K. Treatment of ameloblastoma in children. *Br J Oral Maxillofac Surg* 1998 Dec;**36**(6):453-6.
  19. Pogrel MA, Montes DM. Is there a role for enucleation in the management of ameloblastoma? *Int J Oral Maxillofac Surg* 2009 Aug;**38**(8):807-12.
  20. Arotiba GT, Ladeinde AL, Arotiba JT, Ajike SO, Ugboko VI, Ajayi OF. Ameloblastoma in Nigerian children and adolescents: a review of 79 cases. *J Oral Maxillofac Surg* 2005 Jun;**63**(6):747-51.