Case Report

Benign Pleomorphic Adenoma of the Buccal Space: A Rare Case with Intraoral Surgical Approach

Fereshteh Naderi[1], Shayan Yousefi[2], Haleh Hashemzadeh[3], Sara Pilehvar[1], Ricardo Grillo[4], Sahand Samieirad[5*]

1. Department of Oral & Maxillofacial Surgery, Faculty of Dentistry, Mashhad University of Medical Sciences, Mashhad, Iran
2. Student Research Committee, Faculty of Dentistry, Mashhad University of Medical Sciences, Iran
3. Department of Orthodontics, Tehran University of Medical Science, Tehran, Iran
4. Department of Oral and Maxillofacial Surgery, University of São Paulo, São Paulo, Brazil
5. Oral & maxillofacial diseases research center, Mashhad University of Medical sciences, Mashhad, Iran

***Corresponding Author:**

Sahand Samieirad

Oral & maxillofacial diseases research center, Mashhad University of Medical sciences, Mashhad, Iran.

Tel.: +98 912 813 7859
Email: Samieerads@mums.ac.ir

Received: ***
Accepted: ***

ABSTRACT

Pleomorphic adenoma (PA) is the most common benign salivary gland tumor, mainly affecting the parotid gland. Involvement of the buccal minor salivary glands is uncommon and frequently misdiagnosed due to its unusual location and nonspecific clinical presentation. In March 2025, a 45-year-old male patient was referred to the Department of Oral and Maxillofacial Surgery, Faculty of Dentistry, Mashhad University of Medical Sciences, Mashhad, Iran. The patient presented with a painless, gradually enlarging swelling of the right cheek that had been present for approximately one year. Clinical examination revealed a firm, well-defined, non-tender mass in the right buccal mucosa. Contrast-enhanced computed tomography (CT) and CT angiography demonstrated a well-circumscribed, non-vascular soft-tissue mass that was distinct from the parotid gland. The lesion was completely removed through an intraoral approach, and histopathological examination confirmed the diagnosis of PA. The patient's postoperative recovery was uneventful, with no clinical evidence of recurrence during the one-year follow-up. Although rare, PA should be included in the differential diagnosis of painless, slowly enlarging buccal masses. Timely diagnosis, appropriate imaging, and complete surgical excision are essential for achieving a favorable outcome. This case highlights the complexity of diagnosing and treating a rare minor salivary gland tumor.

KEYWORDS
Case report; Salivary gland; Neoplasms; Pleomorphic adenoma

Please cite this paper as:
Naderi F, Yousefi Sh, Hashemzadeh H, Pilehvar S, Grillo R, Samieirad S. Benign Pleomorphic Adenoma of the Buccal Space: A Rare Case with Intraoral Surgical Approach. World J Plast Surg. 2026;15(3):1-10.
doi: 10.61186/wjps.15.3.**

INTRODUCTION

Salivary gland tumors are relatively rare, representing 1%-3% of cancers located in the head and neck[1]. Pleomorphic adenoma (PA), or benign mixed tumor, is the predominant benign neoplasm of the salivary glands [1-5]. They originate from the major salivary glands, as well as the minor salivary glands. They may infrequently originate from the palate, oral cavity, neck, and nasal cavity as well [2, 6]. PA is characterized by three components: an epithelial component, a myoepithelial cell component, and a mesenchymal component. A fibrous capsule functions to isolate these cells from the surrounding tissues [2]. PAs typically present as

[Downloaded from wjps.ir on 2026-10-15]

painless, slow-growing masses, usually discovered in middle-aged adults (4th–6th decades) with a slight female predominance [1, 2]. These tumors predominantly affect the major salivary glands, particularly the parotid gland, which constitutes around 70%–80% of all PAs [1, 7]. Minor salivary gland PAs are infrequent generally. The hard and soft palate is the predominant site among small glands, accounting for over half of instances, followed by the upper lip and additional places. In contrast, PA originating in the buccal mucosa or cheek (buccal space) is exceedingly rare. Palate involvement is predominant among minor glands, with buccal locations representing only a modest proportion of minor salivary cancers [7, 8].

Clinically, buccal-space periapical abscesses manifest similarly to those in other locations: generally, as hard, well-defined, slowly growing, painless masses beneath intact mucosa. The overlying mucosa is often unremarkable, with no evidence of skin ulceration or fixation. Lesions are frequently mobile across neighboring planes and not attached to the underlying bone. The lack of discomfort, facial nerve paralysis, or systemic signs is indicative of benign behavior. In minor glands, PAs may grow to several centimeters before detection; sizes of 1–7 cm have been reported, with occasional very large lesions in the cheek [2, 9].

Given the rarity of PA in the buccal space, a broad differential diagnosis should be considered. This includes benign soft-tissue lesions such as fibroma, lipoma, neurofibroma, epidermoid or dermoid cysts, and vascular anomalies, particularly hemangioma. Other diagnostic considerations include benign and malignant minor salivary gland tumors and lesions arising from accessory parotid tissue [9]. Although a long-standing, asymptomatic swelling with a firm, non-pulsatile consistency may suggest a benign lesion, clinical findings alone are generally insufficient to establish the diagnosis. Imaging is therefore important for evaluating the lesion's extent, anatomical relationships, and vascularity and for guiding surgical planning. On cross-sectional imaging, PAs typically appear as well-circumscribed, smoothly marginated soft-tissue masses. Cross-sectional imaging (CT or MRI) may help confirm the lesion's location, assess possible extension into adjacent structures, and distinguish it from cystic or vascular lesions [2].

Definitive diagnosis requires histopathological examination, while complete surgical excision is the treatment of choice. This report describes a PA arising in the right buccal space of a 45-year-old man, with emphasis on its clinical presentation, imaging characteristics, histopathological findings, and successful management through an intraoral surgical approach.

CASE PRESENTATION

A 45-year-old male presented in March 2025 to the Department of Oral and Maxillofacial Surgery, Faculty of Dentistry, Mashhad University of Medical Sciences, Mashhad, Iran, with a gradually enlarging swelling in the right cheek that had developed progressively over approximately one year. Initially, the swelling was small and asymptomatic, but it gradually increased in size, causing cosmetic concerns and mild discomfort. There was no history of trauma, infection, or similar swellings. The patient reported no systemic symptoms such as pain, fever, weight loss, or functional impairment in chewing or speaking. The study was approved by the Ethics Committee of Mashhad University of Medical Sciences under the ethics code IR.MUMS.REC.1404.230.

During the clinical examination, a firm, non-tender, well-defined mass measuring approximately 3 cm in diameter was palpated in the right buccal mucosa (Figure 1). The overlying mucosa was intact and unremarkable, exhibiting no signs of ulceration or inflammation. The lesion appeared fixed to the underlying tissues but was mobile over the skin and not adherent to adjacent anatomical structures. There was no evidence of cervical lymphadenopathy. Given the mass's anatomical position and clinical manifestation, an initial differential diagnosis encompassed fibroma, lipoma, and small salivary gland tumor. A contrast-enhanced CT scan of the face was conducted to further describe the lesion (Figure 2). The lesion was observed to be distinct from the parotid gland and exhibited no indications of osseous involvement or dental extension. A CT angiography was performed to exclude any vascular pathology (Figure 3).

Based on the clinical and radiologic findings, complete surgical excision was selected as the treatment of choice. An intraoral vestibular technique was employed to access the buccal area under general anesthesia. The tumor was

[Downloaded from wjps.ir on 2026-10-15]

Figure 1. Preoperative clinical view showing swelling in the right buccal region

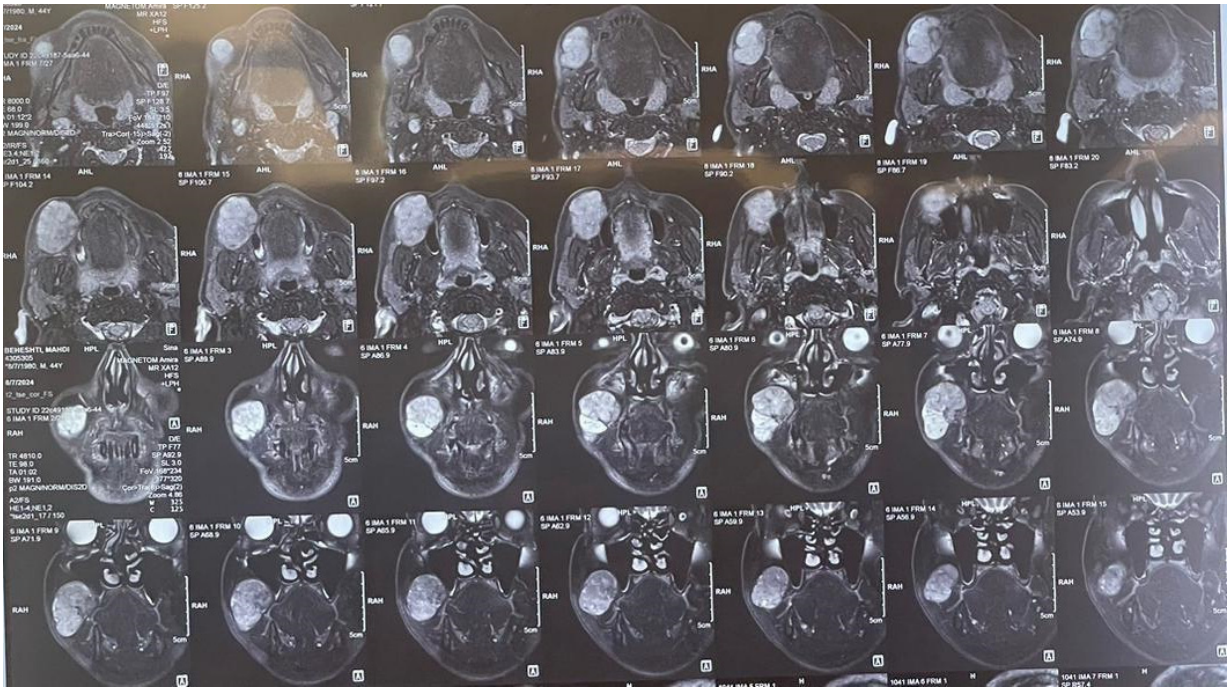

Figure 2. Axial CT scan demonstrating a well-defined, homogeneous soft tissue mass in the right buccal space, measuring approximately 2.8 × 2.5 × 2.2 cm

meticulously dissected and removed en bloc, ensuring the careful preservation of surrounding anatomical tissues (Figures 4–8).

The excised specimen was sent for histopathological examination. Macroscopic examination revealed a well-encapsulated, firm, elastic, white-tan mass measuring 6 × 5 × 2.5 cm, with a solid cut surface. Microscopic examination showed the proliferation of epithelial and myoepithelial cells organized in duct-like formations and trabeculae within a myxochondroid matrix, confirming the diagnosis of PA. No histopathological features of malignancy were identified (Figure 9).

The postoperative course was uneventful, and the patient was discharged on the second postoperative day. At the one-month follow-up, the surgical

[Downloaded from wjps.ir on 2026-10-15]

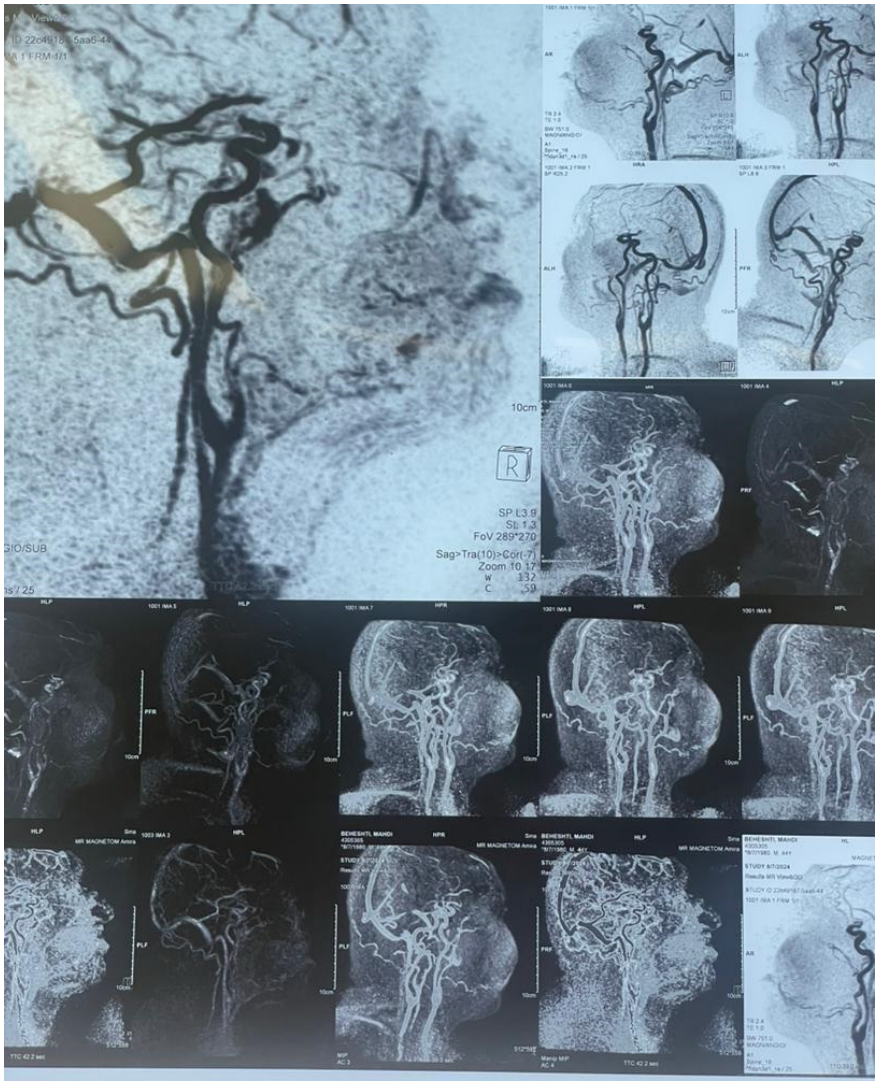

Figure 3. CT angiography of the face excluding vascular malformations or hemangiomas

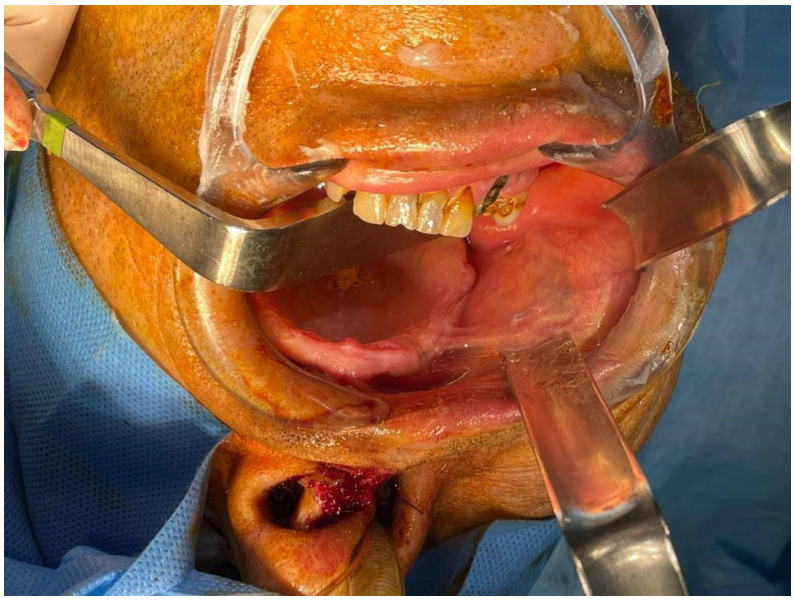

Figure 4. Vestibular incision and exposure of the lesion

[Downloaded from wjps.ir on 2026-10-15]

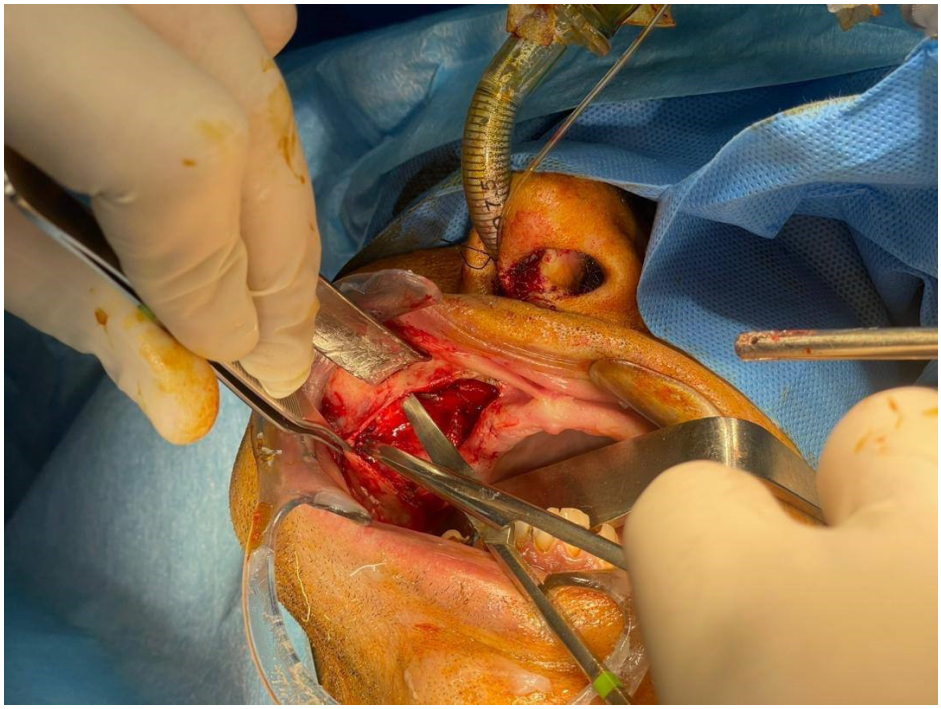

Figure 5. Blunt dissection of surrounding tissue

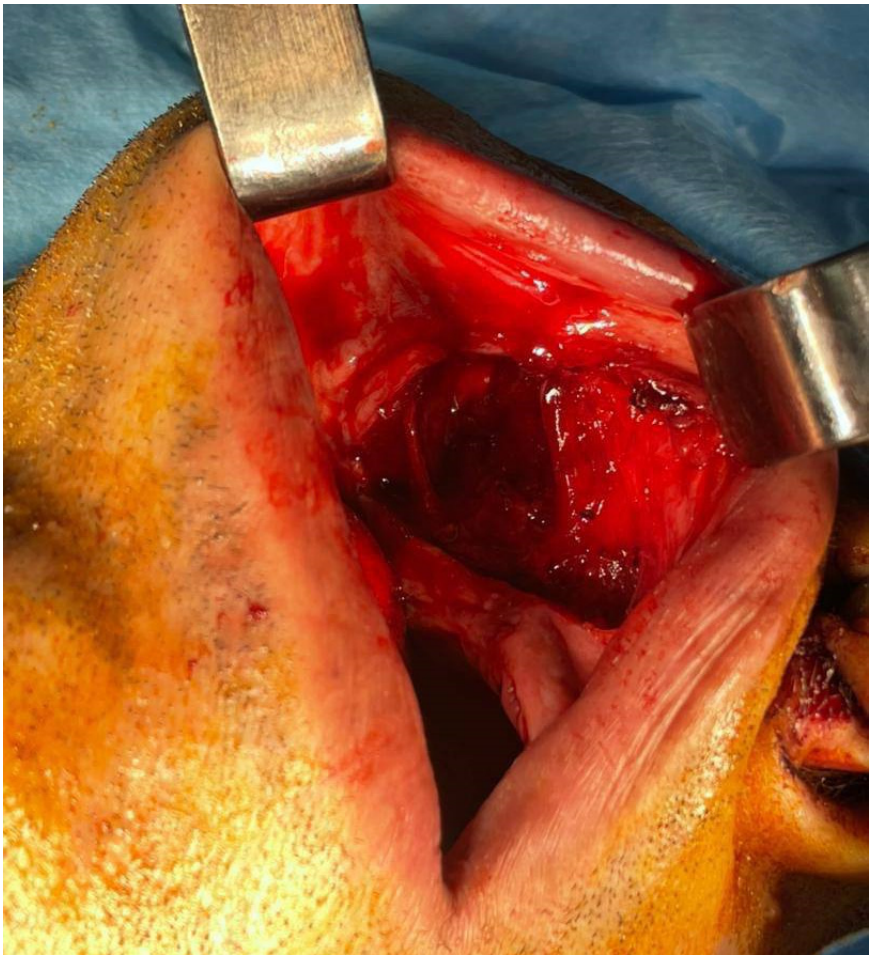

Figure 6. En bloc removal of the mass

[Downloaded from wjps.ir on 2026-10-15]

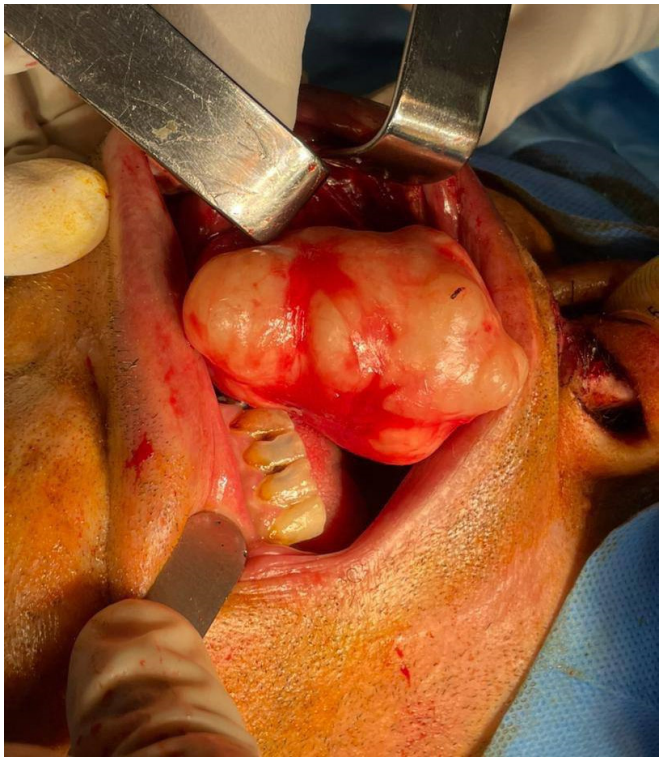

Figure 7. Examination of the excised tumor

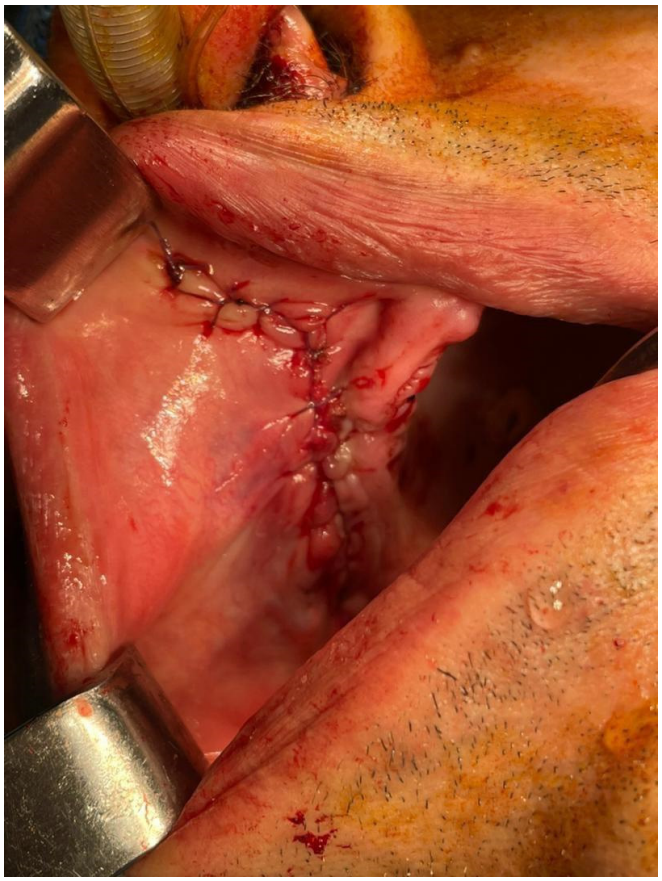

Figure 8. Primary closure of the surgical site

[Downloaded from wjps.ir on 2026-10-15]

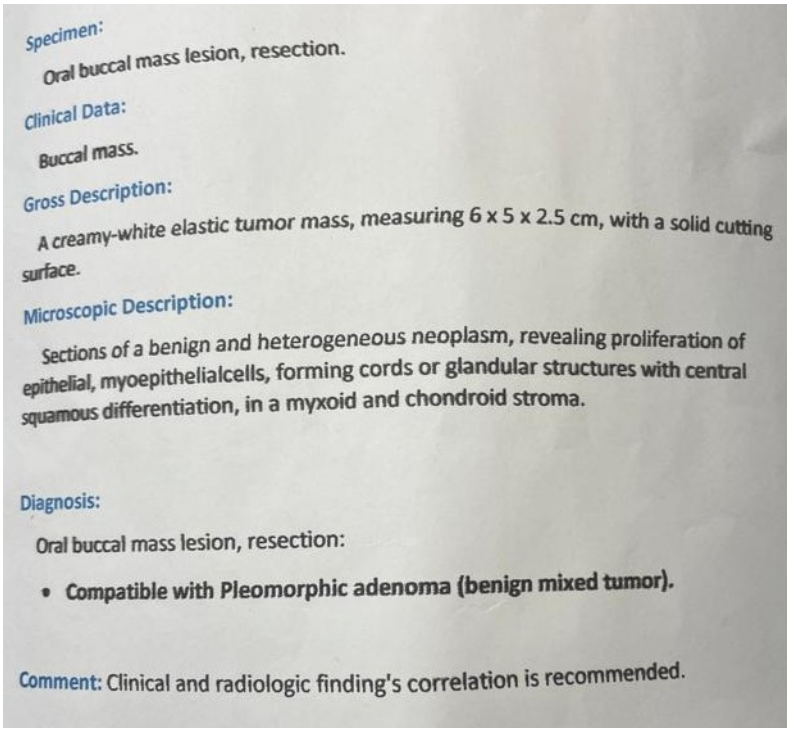

Specimen:

Oral buccal mass lesion, resection.

Clinical Data:

Buccal mass.

Gross Description:

A creamy-white elastic tumor mass, measuring 6 x 5 x 2.5 cm, with a solid cutting surface.

Microscopic Description:

Sections of a benign and heterogeneous neoplasm, revealing proliferation of epithelial, myoepithelialcells, forming cords or glandular structures with central squamous differentiation, in a myxoid and chondroid stroma.

Diagnosis:

Oral buccal mass lesion, resection:

- Compatible with Pleomorphic adenoma (benign mixed tumor).

Comment: Clinical and radiologic finding's correlation is recommended.

Figure 9. Histopathological findings: benign mixed tumor (PA) showing epithelial and myoepithelial components in a myxoid and chondroid stroma

Figure 10. Postoperative clinical view at one-month follow-up showing satisfactory healing and no signs of recurrence

[Downloaded from wjps.ir on 2026-10-15]

site had healed satisfactorily, with a favorable cosmetic outcome (Figure 10). Subsequent clinical examinations at six months and one year showed that the patient remained asymptomatic, with no evidence of recurrence.

DISCUSSION

This case of PA in the buccal minor salivary glands is an uncommon presentation. By definition, PAs can occur in both major and minor glands but over two-thirds involve the parotid gland [1, 5, 10]. The remaining cases involve submandibular and, much less frequently, sublingual or minor glands [7]. Among minor glands, the hard/soft palate is the most common site, and cheek/vestibular lesions comprise a small minority [7, 8]. Case reports likewise describe buccal PA as a rare entity [8, 9]. The patient's age (45 yr) and gender (male) fit the typical age range (30–50 yr) and minor predilection of middle-aged adults for PAs, although many series report a slight female predominance overall [2, 11].

Clinically, this case demonstrated the common features of PA. The lesion manifested as a firm, non-tender, well-circumscribed mass in the buccal mucosa, with intact overlying mucosa and no ulceration – classic descriptors for PA. The slow, painless growth over one year without facial nerve involvement or systemic symptoms is typical for benign salivary tumors. The mass was mobile relative to the skin but fixed relative to deeper tissues; similar mobility is often noted in cheek lesions, where the tumor is tethered by surrounding muscles or fascia. Literature on buccal PAs similarly describes asymptomatic, slow enlarging cheek swellings that can be misdiagnosed initially as lipomas or other benign lesions [2, 9]. In our patient, the absence of pain and rapid growth suggested against inflammatory or malignant processes.

As with other buccal masses, the differential diagnosis was broad. Benign soft-tissue lesions such as fibroma (reactive hyperplasia), lipoma, neural tumors (neurofibroma, schwannoma), and epidermoid/dermoid cysts had to be considered. Vascular lesions like hemangioma or arteriovenous malformation were also possible, though the lesion's firm consistency and lack of bruits/pulsations argued against those. Minor salivary gland tumors (e.g., canalicular adenoma) and accessory parotid gland lesions (cysts or neoplasms) were additional possibilities. The differential also includes inflammatory processes (benign lymphadenopathy, abscess) or benign muscle/duct anomalies as noted in prior reviews of buccal space tumors. In our case, the mobility of the tumor and its normal overlying mucosa led us to favor a benign mesenchymal or glandular etiology (e.g., fibroma, lipoma, PA). Indeed, other authors have reported cases where PAs in the cheek were initially thought to be fibromas or lipomas on clinical exam. Ultimately, imaging and histopathology are required to distinguish among these entities [9].

In salivary gland tumors, imaging (ultrasound, CT, MRI) is helpful for localization and surgical planning. Contrast-enhanced CT of the face was ordered, which showed a well-demarcated, homogeneous soft-tissue mass in the right buccal space, measuring about 2.8×2.5×2.2 cm. It was clearly separate from the parotid gland and did not invade adjacent bone. These findings are consistent with typical imaging characteristics of PA. On CT, PAs are usually smoothly marginated, often lobulated, homogeneous soft-tissue lesions [2].

Smaller PAs generally appear uniformly dense on imaging, whereas very large lesions can develop cystic or necrotic areas. A CT angiogram was ordered additionally to exclude any vascular malformation given the cheek location; this is not routine for all salivary tumors, but it confirmed the lesion was not a hemangioma or AVM. In many cases, MRI is the preferred modality; it would likely have shown a well-circumscribed mass with homogeneous T2 hyperintensity and uniform post-contrast enhancement. The choice of imaging depends on availability and the need to assess vascular supply or deep extension. In any case, our imaging confirmed a benign-appearing tumor, consistent with a PA, and helped plan an intraoral surgical approach [2].

Based on the clinical and radiologic findings, complete surgical excision was selected as the treatment of choice. Histopathology of the excised specimen confirmed PA of minor salivary gland origin, with the classic admixture of epithelial ductal structures and myoepithelial (mixed) cells in a myxoid–chondroid stroma. No malignant features (mitoses or necrosis) were present. These findings correspond well with known histopathology of PA: a benign, encapsulated tumor containing both glandular (epithelial) and mesenchymal (myoepithelial matrix) components. Minor-gland

[Downloaded from wjps.ir on 2026-10-15]

PAs may exhibit a more cellular (less myxoid) appearance than major-gland tumors, but our case fell within the expected spectrum [2, 9].

PA was excised en bloc via an intraoral approach, avoiding external scarring. The firm, encapsulated mass was easily dissected, with care taken to prevent capsule rupture, which raises recurrence risk. A margin of normal tissue was included due to possible microscopic extensions. The specimen measured approximately 6.0 × 5.0 × 2.5 cm. No adjuvant therapy was needed, as PAs are not radiosensitive. Postoperative care involved routine wound management and follow-up.

Postoperative course was uneventful, and the patient was discharged on the second postoperative day. At the one-month follow-up, the surgical site had healed satisfactorily, with a favorable cosmetic outcome. Clinical evaluations at six and 12 months revealed no evidence of local recurrence. This outcome is consistent with the generally favorable prognosis of PA following complete surgical excision. Many studies report recurrence rates well under 10% when tumors are removed with clear margins. Spiro et al. found a recurrence of about 7% in benign parotid tumors and 6% in benign minor-gland tumors after adequate surgery [5, 9]. Nevertheless, recurrence may occur several years after treatment, particularly in cases involving incomplete excision, capsular rupture, or microscopic tumor extensions. Continued long-term follow-up is therefore necessary. Although malignant transformation into carcinoma ex PA is uncommon, it has been associated primarily with long-standing or recurrent tumors, further supporting the need for appropriate treatment and long term follow-up.

The clinical and histopathological findings in this case are consistent with previously reported PAs of the buccal minor salivary glands. The lesion presented as a painless, firm, slowly enlarging cheek mass, while histopathological examination demonstrated the characteristic epithelial and myoepithelial components within a myxochondroid stroma. Despite its rarity at this site, PA should be included in the differential diagnosis of a persistent, slow-growing buccal mass. Careful radiographic assessment and surgical planning facilitated complete intraoral excision without perioperative complications or external scarring. The absence of clinical recurrence at one year is encouraging; however, longer follow-up is required to establish sustained disease control [9].

CONCLUSION

PA of the buccal minor salivary glands is rare and may be clinically mistaken for other benign soft-tissue lesions. It should therefore be considered in the differential diagnosis of a painless, slowly enlarging, well-circumscribed buccal mass. Cross-sectional imaging is valuable for determining the lesion's extent, anatomical relationships, and vascularity, whereas definitive diagnosis relies on histopathological examination. Complete surgical excision with preservation of capsular integrity is the treatment of choice and is generally associated with a favorable prognosis. In the present case, an intraoral approach enabled complete tumor removal without complications or external scarring, and no clinical evidence of recurrence was observed during the one-year follow-up. Nevertheless, long-term follow-up is necessary as late recurrence and, rarely, malignant transformation may occur.

CONFLICT OF INTEREST

The authors declare no conflicts of interest.

REFERENCES

1. Samia M, Amin K, Rihab O, Afifa C. Case Series: Pleomorphic adenoma in minor salivary gland. *F1000Res* 2024;**13**:243.
2. Kalwaniya DS, Meena R, Kumar D, Tolat A, Arya SV. A Review of the Current Literature on Pleomorphic Adenoma. *Cureus* 2023;**15**(7):e42311.
3. Sheereen S, Manva MZ, Sheereen S, Patil NN, Abdelrahim RK, Afroz MM. "Pleomorphic adenoma in salivary glands: Insights from a 100-patient analysis". *J Oral Maxillofac Pathol* 2024;**28**(1):42-8.
4. Moonis G, Patel P, Koshkareva Y, Newman J, Loevner LA. Imaging characteristics of recurrent pleomorphic adenoma of the parotid gland. *AJNR Am J Neuroradiol* 2007;**28**(8):1532-6.
5. Spiro RH. Salivary neoplasms: overview of a 35-year experience with 2,807 patients. *Head Neck Surg* 1986 ;**8**(3):177-84.
6. Thoeny HC. Imaging of salivary gland tumours. *Cancer Imaging* 2007;7(1):52-62.
7. Alsanie I, Rajab S, Cottom H, et al. Distribution and Frequency of Salivary Gland Tumours: An International Multicenter Study. *Head Neck Pathol* 2022;**16**(4):1043-54.

[Downloaded from wjps.ir on 2026-10-15]

8. Periasamy S, Manoharan A, Garg H, Kumar SP. Pleomorphic Adenoma of the Cheek: A Case Report. *Cureus* 2019;**11**(8):e5312.
9. Bahbah S, Chbicheb S. Pleomorphic adenoma of the cheek. Case report with review. *Int J Odontostomat* 2020;**14**(4):653-7.
10. Hmidi M, Aatifi H, Boukhari A, Zalagh M, Messary A. Pleomorphic adenoma of the soft palate: major tumor in a minor gland. *Pan Afr Med J* 2015;**22**:281.
11. Singh K, Kumar Mishra A, Kour A, Gupta A. Novel Approach for Management of Extremely Rare Pleomorphic Adenoma of Soft Palate (Minor Salivary Glands). *Indian J Otolaryngol Head Neck Surg* 2022;**74**(Suppl 2):1989-91.

[Downloaded from wjps.ir on 2026-10-15]