Case Report

Sialorrhea Following Rhytidectomy: A Case Report and Literature Review

Malihe Kadkhodaei[1], Ali-Mohammad Fallah Tafti[2*], Mohammad Mehdi Mehrabi[3], Seyyed Mohammad Hosseini Marvast[1]

1. Student Research Committee, Shahid Sadoughi University of Medical Sciences, Yazd, Iran
2. Department of Surgery, Shahid Sadoughi University of Medical Sciences and Health Services, Yazd, Iran
3. Department of Surgery, Shiraz University of Medical Sciences, Fars, Iran

***Corresponding Author:**

Ali-Mohammad Fallah Tafti

Department of Surgery, Shahid Sadoughi University of Medical Sciences and Health Services, Yazd, Iran.

Email: fallah.ali.m@gmail.com

Received: ***
Accepted: ***

ABSTRACT

Rhytidectomy (facelift) is a commonly performed procedure aimed at restoring facial youthfulness, utilizing either supra-SMAS or sub-SMAS techniques. The sub-SMAS approach carries an elevated risk of complications, including facial nerve injury, hematoma, and prolonged swelling. We present a case of a 64-year-old woman from Shiraz, Iran who developed right-sided facial swelling on postoperative day 7 following a short-scar sub-SMAS rhytidectomy, subsequently diagnosed as a sialocele. Conservative management, consisting of repeated aspirations and application of compression dressings, was successfully undertaken. Sialography on day 15 confirmed a well-defined operative site collection. Targeted doxycycline injection combined with supportive care resulted in complete resolution of swelling, restoration of facial symmetry, and absence of postoperative complications. This case underscores the importance of early recognition and appropriately tailored conservative management in effectively treating post-facelift sialocele, optimizing both functional and aesthetic outcomes.

KEYWORDS
Facelift; Rhytidectomy; Parotid sialocele; Postoperative complication; Conservative management

Please cite this paper as:
Kadkhodaei M, Fallah Tafti AM, Mehrabi M, Hosseini Marvast SM. Sialorrhea Following Rhytidectomy: A Case Report and Literature Review. World J Plast Surg. 2026;15(3):1-7.
doi: 10.61186/wjps.15.3.**

INTRODUCTION

Rhytidectomy remains a cornerstone in facial rejuvenation widely regarded as the most effective and durable method for addressing age-related facial changes, whether performed using the supra-SMAS or sub-SMAS approach. Over the past five decades, the procedure has undergone significant refinements, with manipulation of the superficial musculoaponeurotic system (SMAS) playing a pivotal role in achieving durable and predictable results. Techniques commonly involve either superficial plication or SMAS elevation with secure reanchoring [1]. The SMAS, a fibromuscular layer responsible for facial expression, resides within the superficial fascia of the parotid and cheek regions, requiring meticulous intraoperative handling to ensure optimal outcomes [2].
Contemporary facelift trends favor deeper tissue dissection, often involving SMAS manipulation. While this technique enhances rejuvenation outcomes, it also increases the risk of inadvertent injury to adjacent structures, particularly the parotid gland [3-6]. Facial aging is

[Downloaded from wjps.ir on 2026-11-26]

a progressive process affecting all anatomical layers, including skin, subcutaneous fat, retaining ligaments, and the facial skeleton. Loss of skeletal support and soft tissue volume, along with attenuation of retaining ligaments, contribute to soft tissue ptosis and altered facial contours [7-12]. Addressing these deficits through precise repositioning of the underlying tissues and meticulous redraping of the overlying soft tissues is essential for achieving natural and harmonious rejuvenation outcomes [7-10].

A comprehensive understanding of parotid gland anatomy is crucial for safe surgical practice [13]. The parotid gland, the largest salivary gland, is situated anteroinferior to the external ear, is traversed by the facial nerve, and drains via Stensen's duct [14]. Parotid injury during facelift can lead to complications such as sialocele or salivary fistula, which may compromise flap healing, cause prolonged edema, and result in suboptimal aesthetic outcomes [3-6, 15, 16]. Although uncommon, complications such as parotid duct injuries and salivary fistulas have been reported not only after facelift procedures but also following other surgical interventions, including mastoidectomy, mandibular procedures, and parotidectomy [6, 17-21].

The overlapping pathophysiology between post-rhytidectomy and post-parotidectomy fistulas [14] supports adopting similar prevention and treatment strategies. A summary of previously reported cases of iatrogenic parotid injury highlights variability in presentation and management, providing valuable context for the current case (Table 1).

The shared pathophysiological mechanisms between fistulas following rhytidectomy and those arising after parotidectomy [14] justify the application of comparable preventive and therapeutic approaches in both settings. Table 1 summarizes previously documented instances of iatrogenic parotid gland injury, outlining the number of reported cases, contributing factors, clinical features, diagnostic tools, management strategies, and outcomes.

This overview underscores the heterogeneity in presentation and treatment of this rare complication and provides essential context for the current case report.

CASE PRESENTATION

A 64-year-old healthy woman, from Shiraz, Iran in 2024 underwent a short-scar facelift with sub-SMAS dissection and plication for facial rejuvenation. A classic surgical procedure was performed, and the patient recovered normally during the initial postoperative period.

On postoperative day 7, the patient developed right-sided facial swelling accompanied by localized tenderness. Clinical examination revealed no erythema, warmth, or other signs of infection, and there was no evidence of hematoma. A focused neurovascular assessment demonstrated preserved motor and sensory function.

Based on the clinical findings and imaging, a sialocele was suspected. Analysis of the aspirated fluid showed amylase levels more than twice the upper limit of normal, consistent with salivary gland involvement (Figure 1).



Figure 1. (a): Preoperative view of the patient prior to short-scar sub-SMAS facelift (b): Right-sided facial swelling developing after short-scar sub-SMAS facelift. (c): Sialocele suspected based on clinical and imaging findings; aspirated fluid showed amylase levels above the normal range

[Downloaded from wjps.ir on 2026-11-26]

Initial management consisted of repeated aspirations and compression dressings to reduce salivary secretion. Despite one week of conservative therapy, the swelling persisted without improvement. On postoperative day 15, sialography demonstrated a well-circumscribed collection of contrast on the operative side, raising concern for parotid gland or ductal injury.

Definitive treatment included repeated aspirations, Injection of 100 mg doxycycline into the cavity followed by compression dressings.

The lesion resolved within one month, with complete resolution of swelling and restoration of facial symmetry. No recurrence, infection, facial nerve dysfunction, or additional postoperative complications were observed during follow-up (Figure 2).

DISCUSSION AND REVIEW OF MANAGEMENT STRATEGIES

Foundational anatomical studies by Mitz and Peyronie, through cadaveric dissection, radiographic analysis, and histologic evaluation, highlighted the structural and functional significance of the SMAS and provided the foundation for modern rhytidectomy techniques [2].

The supra-SMAS approach involves elevating the skin flap in a more superficial plane above the SMAS, preserving the retaining ligaments, mimetic muscles, and deeper fascial structures. This method allows controlled access to the SMAS for modification; such as plication or imbrication, while maintaining deeper anatomical support. Mendelson and colleagues emphasized that a precise understanding of layered midcheek anatomy is critical for safe dissection within this plane [22].

By contrast, the sub-SMAS or deep-plane approach involves elevating the SMAS either independently or with the overlying skin, providing access to a deeper plane beneath the SMAS. This facilitates mobilization and repositioning of the malar fat pad and deeper tissues, yielding enhanced midface suspension. Hamra described this technique as particularly effective for patients with advanced soft tissue descent, offering durable and anatomically based rejuvenation [23].

The supra-SMAS method provides moderate repositioning with minimal risk, while the sub-SMAS technique enables broader tissue mobilization but requires advanced anatomical expertise and carries a greater risk of facial nerve injury. As Baker noted in his description of lateral SMASectomy, the choice of approach should be individualized



Figure 2. (a): Sialography on postoperative day 15 showing a well-defined contrast collection at the operative site. (b): Repeated aspirations performed on postoperative day 21.
(c): Repeated aspirations and injection of 100 mg doxycycline into the cavity, followed by compression dressings
(d): Complete resolution of the lesion and restoration of facial symmetry within one month

[Downloaded from wjps.ir on 2026-11-26]

according to patient anatomy, degree of laxity, and the surgeon's technical expertise (Table 2) [24].

Parotid fistulas are uncommon and usually result from injury to the gland or ductal system [25]. Although parotid injury following rhytidectomy is rare, early recognition and timely management are essential to minimize morbidity and optimize aesthetic outcomes. Increasing awareness of this complication has led to a range of conservative and surgical treatment strategies tailored to severity and persistence [13]. Clinically, parotid injury often presents with localized edema [3-6, 15, 16, 26,27], clear serous drainage from incision sites [6, 15], erythema [15], or patient-reported pain [5, 16], findings that warrant prompt evaluation.

A parotid fistula is defined as an abnormal tract between the parotid gland or duct and the skin, producing salivary efflux that typically increases with mastication [28-30]. Clinically, the patient exhibited intermittent postoperative swelling with clear fluid discharge from the incision site, with the swelling often fluctuating in intensity following food intake [31], while some fistulas resolve spontaneously due to scar formation that blocks salivary outflow [32]. However, persistent leakage can impair wound healing and cause contour irregularities or facial asymmetry. No standardized treatment protocol exists, and both conservative and surgical options have been used [33]. Initial management include needle aspiration, compression dressings, and

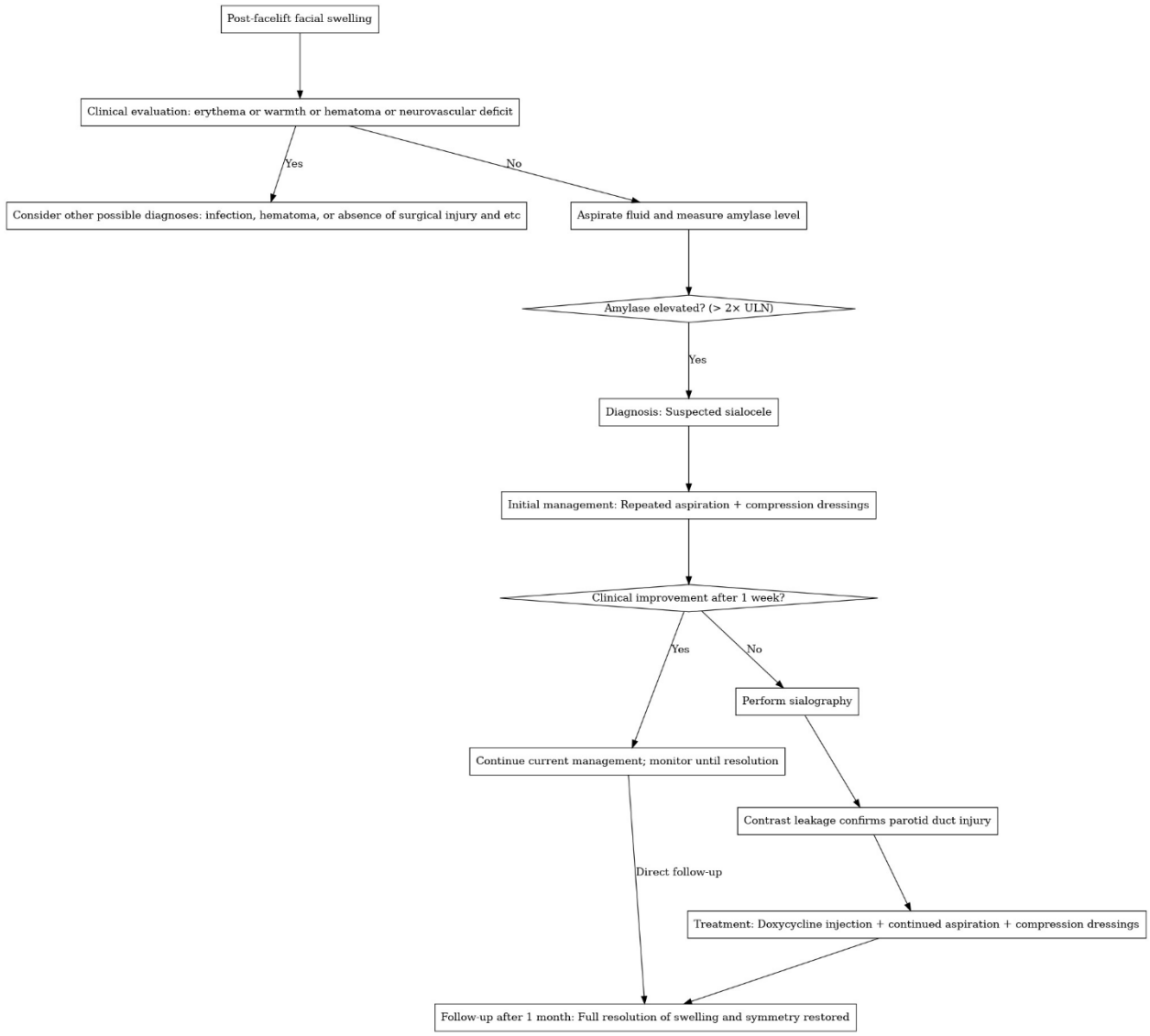

Figure 3. Algorithm for evaluation and management of post-facelift facial swelling and suspected sialocele. Clinical assessment guides further diagnostic and therapeutic decisions. ULN, upper limit of normal

[Downloaded from wjps.ir on 2026-11-26]

pharmacologic suppression of salivary flow with anticholinergic agents [34, 35]. However, long-term use of these medications carries risks such as cognitive impairment, urinary dysfunction, and even paralytic ileus [5, 28].

Although uncommon, postoperative salivary fistulas can complicate rhytidectomy. Prompt recognition and timely initiation of conservative therapies, particularly transdermal scopolamine and Botulinum toxin type A (BoNT/A), are essential to optimize outcomes and minimize patient morbidity [25].

Among pharmacological agents, BoNT/A has emerged as an effective minimally invasive therapy, reducing salivation by inhibiting acetylcholine release [16]. In post-rhytidectomy patients, it represents a reliable treatment option [13].

Successful management of a post-rhytidectomy fistula was achieved using transdermal scopolamine combined with BoNT/A [25], while another case achieved complete healing within six days with scopolamine alone [5]. Gallo et al. [25] highlighted transdermal scopolamine as a safe, cost-effective, and minimally invasive alternative to BoNT/A in post-parotidectomy cases, effectively reducing salivary secretion, promoting healing, and potentially decreasing the need for surgical intervention.

A multimodal conservative regimen, incorporating BoNT/A injections, compressive dressings, scopolamine patch application, and temporomandibular joint restriction, is widely favored as a first-line treatment before considering surgical intervention [33].

Alongside established conservative strategies, our patient was successfully managed with intralesional doxycycline, which facilitated closure of the fistulous tract and complete resolution. Although infrequently reported in the literature, this approach proved effective for a persistent case unresponsive to conventional therapies. The favorable outcome underscores doxycycline as a safe, minimally invasive, and cost-effective adjunct in the management of post-rhytidectomy salivary leaks, warranting further clinical investigation.

Despite encouraging outcomes, no universal standard of care exists, and management should be individualized. More invasive techniques such as tympanic neurectomy or marsupialization [26, 36] have been reserved for refractory cases, though their application is limited due to higher surgical risk and potential cosmetic compromise [33]. Diagnostic accuracy is equally important, as sialoceles may mimic hematomas or infection [28], whereas traumatic parotid injuries are more readily identified due to visible wounds [13].

Parotid gland trauma can lead to diverse complications including hemorrhage, infection, facial nerve injury, sialocele, and salivary fistula. In persistent cases, pharmacologic options should be exhausted before surgical procedures such as tympanic neurectomy or partial parotidectomy are considered [32].

Management of parotid sialoceles and fistulae generally begins with observation, drainage, with intraparotid botulinum toxin reserved for cases that do not improve spontaneously. Lawson et al. [13] proposed a structured approach for addressing salivary leakage following rhytidectomy, highlighting the importance of evaluating suspected Stensen's duct injuries. When intraoperative findings indicate potential ductal involvement, surgical re-exploration is recommended to assess ductal integrity. Patency can be confirmed by gently introducing a lacrimal probe into the ductal papilla and instilling saline or dye. If a proximal transection is identified and considered amenable to repair, anastomosis over a stent should be performed and maintained for approximately two weeks. When primary repair is not feasible, such as in distal injuries or when the ductal ends are not identifiable, proximal duct ligation or creation of a controlled intraoral fistula represents an appropriate management strategy [13].

Our proposed algorithm (Figure 3) provides a clear, evidence-based framework for the evaluation and management of salivary leaks after facelift surgery, emphasizing timely diagnosis and minimally invasive therapy. This stepwise strategy offers clinicians a practical guide to optimizing patient outcomes while minimizing complications.

CONCLUSION

Parotid sialocele is an uncommon but important complication following rhytidectomy that may mimic more common postoperative conditions such as hematoma or infection. Early recognition through clinical evaluation, fluid analysis, and imaging allows timely initiation of conservative management. In this case, repeated aspiration, compression therapy, and intralesional doxycycline injection resulted in complete resolution without

[Downloaded from wjps.ir on 2026-11-26]

surgical intervention. This experience highlights the effectiveness of minimally invasive management strategies in preserving both functional recovery and aesthetic outcomes after facelift surgery.

ACKNOWLEDGEMENT

The authors thank the patient for her cooperation and for providing written informed consent for publication of this case report.

CONFLICT OF INTEREST

The authors declare no conflicts of interest.

PATIENT CONSENT

Written informed consent was obtained from the patient for publication of this case report and accompanying images in accordance with journal guidelines.

REFERENCES

1. Charafeddine AH, Drake R, McBride J, Zins JE. Facelift: History and Anatomy. *Clin Plast Surg* 2019 Oct;**46**(4):505-13. https://doi.org/10.1016/j.cps.2019.05.001
2. Mitz V, Peyronie M. The superficial musculo-aponeurotic system (SMAS) in the parotid and cheek area. *PRS* 1976 Jul;**58**(1):80-8. https://doi.org/10.1097/00006534-197607000-00013
3. Bansberg SF, Krugman ME. Parotid salivary fistula following rhytidectomy. *Ann Plast Surg* 1990;**24**(1):61-2. https://doi.org/10.1097/00000637-199001000-00011
4. Barron R, Margulis A, Icekson M, Zeltser R, Eldad A, Nahlieli O. Iatrogenic parotid sialocele following rhytidectomy: diagnosis and treatment. *Plast Reconstr Surg* 2001;**108**(6):1782-4. https://doi.org/10.1097/00006534-200111000-00055
5. Lapid O, Kreiger Y, Sagi A. Transdermal scopolamine use for postrhytidectomtomy sialocele. *Anesthetic Plast Surg* 2004;**28**:24-8. https://doi.org/10.1007/s00266-004-3115-5
6. Wolf K, Bostwick J, Dinner M, Jackson IT. Parotid salivary fistula following rhytidectomy. *Plast Reconstr Surg* 1996;**97**(3):641-2. https://doi.org/10.1097/00006534-199603000-00025
7. Rosen HM, Rosen HM. Treatment Planning: Aesthetics Goals. *Aesthetic Perspectives In Jaw Surgery* 1999:3-23. https://doi.org/10.1007/978-1-4612-2142-5_1
8. Terino EO, Edwards MC. Alloplastic contouring for suborbital, maxillary, zygomatic deficiencies. *Facial Plast Surg Clin North Am* 2008;**16**(1):33-67. https://doi.org/10.1016/j.fsc.2007.09.006
9. Terino EO, Edward M. The magic of mid-face three-dimensional contour alterations combining alloplastic and soft tissue suspension technologies. *Clin Plast Surg* 2008;**35**(3):419-50. https://doi.org/10.1016/j.cps.2008.02.011
10. Whitaker LA, Bartlett SP. Skeletal alterations as a basis for facial rejuvenation. *Clin Plast Surg* 1991;**18**(1):197-203. https://doi.org/10.1016/S0094-1298(20)30682-9
11. Lambros V. Observations on periorbital and midface aging. *Plast Reconstr Surg* 2007 Oct;**120**(5):1367-76. https://doi.org/10.1097/01.prs.0000279348.09156.c3
12. Mendelson B, Wong C-H. Changes in the facial skeleton with aging: implications and clinical applications in facial rejuvenation. *Anesthetic Plast Surg* 2012;**36**:753-60. https://doi.org/10.1007/s00266-012-9904-3
13. Lawson III GA, Kreyerman P, Nahai F. An unusual complication following rhytidectomy: iatrogenic parotid injury resulting in parotid fistula/sialocele. *Anesthetic Surg J* 2012;**32**(7):814-21. https://doi.org/10.1177/1090820x12455798
14. S S. Gray's Anatomy: The Anatomical Basis of Clinical Practice. London: Elsevier; 2020.
15. Dessy L, Mazzocchi M, Monarca C, Onesti MG, Scuderi N. Combined transdermal scopolamine and botulinum toxin A to treat a parotid fistula after a facelift in a patient with siliconomas. *Int J Oral Maxillofac Surg* 2007;**36**(10):949-52. https://doi.org/10.1016/j.ijom.2007.05.021
16. McKinney P, Zuckerbraun BS, Smith JW, Kawamoto HK, Griffith HB. Management of parotid leakage following rhytidectomy. *Plast Reconstr Surg* 1996;**98**(5):795-7. https://doi.org/10.1097/00006534-199610000-00006
17. Bushara K. Sialorrhea in amyotrophic lateral sclerosis: a hypothesis of a new treatment-botulinum toxin A injections of the parotid glands. *Med Hypotheses* 1997;**48**(4):337-9. https://doi.org/10.1016/s0306-9877(97)90103-1
18. Winkler E, Goldan O, Regev E, Mendes D, Orenstein A, Haik J. Stensen duct rupture (sialocele) and other complications of the Aptos thread technique. *Plast Reconstr Surg* 2006;**118**(6):1468-71. https://doi.org/10.1097/01.prs.0000239604.69415.e6
19. Baurmash HD. Obstructive parotitis after rhytidectomy. *J Oral Maxillofac Surg* 2004;**62**(11):1439. https://doi.org/10.1016/j.joms.2003.11.012
20. Bailey B. A persistent parotid fistula following the extraction of mandibular teeth. *J Laryngol*

[Downloaded from wjps.ir on 2026-11-26]

Otol 1984;**98**(10):1051-4. https://doi.org/10.1017/s0022215100147991
21. Hutchison I, Ryan D. A parotid fistula and sialocele complicating temporomandibular joint surgery. *Br J Oral Maxillofac Surg* 1989;**27**(3):203-8. https://doi.org/10.1016/0266-4356(89)90145-9
22. Mendelson BC, Muzaffar AR, Adams WP, Jr. Surgical anatomy of the midcheek and malar mounds. *Plast Reconstr Surg* 2002 Sep 1;**110**(3):885-96; discussion 97-911. https://doi.org/10.1097/00006534-200209010-00026
23. Hamra ST. The deep-plane rhytidectomy. *Plast Reconstr Surg* 1990 Jul;**86**(1):53-61; discussion 2-3. https://pubmed.ncbi.nlm.nih.gov/2359803/
24. Baker DC. Lateral SMASectomy. *Plast Reconstr Surg* 1997 Aug;**100**(2):509-13. https://doi.org/10.1097/00006534-199708000-00039
25. Gallo A, Manciocco V, Pagliuca G, Martellucci S, de Vincentiis M. Transdermal scopolamine in the management of postparotidectomy salivary fistula. *Ear, Nose Throat J* 2013;**92**(10-11):516-9. https://pubmed.ncbi.nlm.nih.gov/24170466/
26. HABAL MB. Parotid retention cysts as a complication of rhytidectomy: Case report. *Plast Reconstr Surg* 1978;**61**(6):920-1. https://pubmed.ncbi.nlm.nih.gov/662954/
27. Choi JS, Kim YM, Lim JY. Parotid ductal stenosis after facial cosmetic surgery (2 case reports). *Medicine (Baltimore)* 2019 Apr;98(15):e15015. doi: 10.1097/MD.0000000000015015. PMID: 30985650; PMCID: PMC6485784.
28. Parekh D, Glezerson G, Stewart M, Esser J, Lawson H. Post-traumatic parotid fistulae and sialoceles. A prospective study of conservative management in 51 cases. *Ann Surg* 1989;**209**(1):105. https://doi.org/10.1097/00000658-198901000-00015
29. Ananthakrishnan N, Parkash S. Parotid fistulas: a review. *J Br Surg* 1982;**69**(11):641-3. https://doi.org/10.1002/bjs.1800691104
30. Arulpragasam A. On the treatment of parotid fistulae. *J Laryngol Otol* 1967;**81**(3):329-37. https://doi.org/10.1017/s002221510006713x
31. Gordin EA, Daniero JJ, Krein H, Boon MS. Parotid gland trauma. *Facial Plas Surg* 2010;**26**(06):504-10. https://doi.org/10.1055/s-0030-1267725
32. Witt RL. The incidence and management of siaolocele after parotidectomy. *Otolaryngol Head Neck Surg* 2009;**140**(6):871-4. https://doi.org/10.1016/j.otohns.2009.01.021
33. Jung MS, Lee BH, Kim JH, et al. Treatment of Botulinum Toxin Type A in Parotid Fistula after Face Lifting. *Arch Anesthetic Plast Surg* 2014;**20**(2):120-3. https://doi.org/10.14730/aaps.2014.20.2.120
34. Chow TL KS. Use of botulinum toxin type A in a case of persistent parotid sialocele. *Hong Kong Med J* 2003;**9**(4):293-4. http://pubmed.ncbi.nlm.nih.gov/12904619/
35. Bhidayasiri R, Truong DD. Expanding use of botulinum toxin. *J Neurol Sci* 2005;**235**(1-2):1-9. https://doi.org/10.1016/j.jns.2005.04.017
36. Westreich M, Binns JH. Posttraumatic parotid pseudocyst with hyperamylasemia. *Plast Reconstr Surg* 1982;**69**(6):1002-5. https://doi.org/10.1097/00006534-198206000-00018

[Downloaded from wjps.ir on 2026-11-26]