

Long Term Follow up and Patient Satisfaction after Reduction Mammoplasty: Superomedial versus Inferior Pedicle

Mohamed Makboul^{1*}, Mahmoud Abdelhamid², Ghada Al-Attar³

1. Plastic Surgery Department, Faculty of Medicine, Assiut University, Egypt
2. Plastic Surgery Department, Faculty of Medicine, Aswan University, Egypt
3. Public Health and Community Medicine Department, Faculty of Medicine, Assiut University, Egypt

ABSTRACT

BACKGROUND

Surgery for hypertrophied breast represents a challenge for plastic surgeons. The search for a good cosmetic breast has led to the development of many techniques. Objectives for reduction mammoplasty are to achieve elevated, symmetrical breasts, with round shape, good projection, small cicatrices that are not very perceptible, and a lasting result.

METHODS

This study was carried out on 60 cases who had done reduction mammoplasty from January 2009 to December 2014. All patients were examined and asked for late post-operative results and overall patients' satisfaction.

RESULTS

Long term projection and contour of the breast were more satisfactory among patients who had superomedial pedicle with a statistical significant difference. No statistical significant difference was observed between patients undergone either types of operations concerning breast symmetry, nipple symmetry and sensation. The mean score of satisfaction was higher among patients undergone superomedial pedicle than inferior pedicle.

CONCLUSION

The superomedial pedicle shows better long term cosmetic result in reduction mammoplasty.

KEYWORDS

Patients' satisfaction; Reduction mammoplasty; Inferior pedicle; Superomedial pedicle

Please cite this paper as:

Makboul M, Abdelhamid M, Al-Attar G. Long Term Follow up and Patient Satisfaction after Reduction Mammoplasty: Superomedial versus Inferior Pedicle. *World J Plast Surg* 2017;6(1):82-87.

INTRODUCTION

The female breast is the strongest feminine character. For many women, breast reduction offers a solution for the functional and aesthetic problems associated with large breasts.¹ Surgery for hypertrophied breast represents a challenge for plastic surgeons. The search for a good cosmetic breast has led to the development of many techniques. The objective of a reduction procedure is

*Corresponding Author:

Mohamed Makboul, MD;
Plastic Surgery Department,
Faculty of Medicine,
Assiut University,
Egypt

E-mail: plasticconsult@gmail.com

Received: November 4, 2015

Revised: June 7, 2016

Accepted: November 9, 2016

primarily to reduce the size of the hypertrophic breast with appropriate redraping of the skin envelope while maintaining a viable nipple-areola complex (NAC). Secondary objectives are to achieve elevated, symmetrical breasts, with round shape, good projection, small cicatrices that are not very perceptible, and a lasting result.²

Breast reduction procedures have been modified over time, with different methods employed for skin and glandular resection. The 'inverted-T scar' described by Wise in 1956 is based on a key-hole technique, with peri-areolar, vertical and infra-mammary fold scars.³ This technique has been widely used ever since with a variety of associated Nipple-Areola Complex (NAC) pedicles. The 'vertical scar' was originally designed and used before aimed to reduce the amount of scarring and the complication of T-junction skin necrosis.³⁻⁷

Reduction Mammoplasty techniques differ in the way the NAC is transposed to its new higher position. During the past two decades the trend was towards using a combination of dermal and glandular pedicles.⁸ The inferior pedicle technique, originally described in the mid 1970s in separate publications, has perhaps become the most popular technique of reduction mammoplasty in North America. This technique gives consistent, reproducible results, with excellent survival of the NAC.⁹⁻¹²

However it has the major disadvantage of late loss of conical projection due to sagging of lower breast tissue.^{13,14} The superomedial pedicle technique, described previously in 1975, was able to produce a long lasting projection of the breast with good reliability regarding NAC viability and sensibility.^{15,16} It was developed to include more breast parenchyma beneath the pedicle, aimed to preserve both the vascularity and innervation to the NAC.^{17,18} The aim of this study is to evaluate the long term follow up outcome for reduction mammoplasty cases comparing both the inferior pedicle and the superomedial pedicle techniques as regards breast aesthetics, nipple sensation, scar acceptance and patient satisfaction.

MATERIALS AND METHODS

This study included 60 cases who had done reduction mammoplasty in the period from January 2009 to December 2014. All the surgeries were done by one surgeon. The operative records for every patient were checked for the type of

pedicle that was used either inferior pedicle or superomedial pedicle reduction mammoplasty, with the same "inverted-T" skin incision type. All patients were examined and asked for late post-operative results at least 1 year post-operatively regarding (i) Long-term breast projection and contour, (ii) Breast symmetry, (iii) Recurrence of breast ptosis, (iv) Nipple position and sensation, (v) Scar acceptance, and (vi) Over all patient's satisfaction score. The satisfaction scale ranged from excellent=5 to very poor=1 (Excellent=5, Good=4, Fair=3, Poor=2, Very poor=1).

RESULTS

This study was done on female patients who had done reduction mammoplasty operation in our institution in the period from January 2009 to December 2014. The total number of patients was 60 patients with a mean age of 29.2 ± 5.9 years (Table 1).

Records showed that reduction mammoplasty was done via superomedial or inferior pedicle in 33.3% (20 Patients) and 66.7% (40 patients) respectively. Studied patients who had superomedial pedicle were younger in age than those who had inferior pedicle, nearly one fourth of the patients who had reduction mammoplasty via inferior pedicle were above 35 years of age with a statistical significant difference. However, no statistical significant difference was observed among the 2 groups concerning the marital status (Table 1).

Long term post-operative assessment results of the patients' satisfaction concerning breast symmetry, long term breast projection, recurrence of ptosis, nipple position and sensation, scar acceptance and overall satisfaction were as follows: concerning the breast symmetry; records showed that breast symmetry was recorded in 58.3% of cases. Long term projection and contour were satisfactory in 55.0% of cases, while recurrence of breast ptosis was recorded in nearly one fourth of the cases (26.7%, n=16). As for the nipple position, it was symmetrical in 58.3% of cases. Nipple sensation was decreased in 16 cases (26.7%) and lost in 3 cases (5.0%), while normal nipple sensation was recorded in 68.3% of cases (Table 2).

Post operative scar was accepted by the majority of the patients (86.6%, n=52) while none acceptability of the scar was reported in 13.4% (n=8). Moreover, the overall satisfaction

Table 1: Age and marital status according to the type of procedure

Variable	Inferior pedicle (n=40)		Superomedial pedicle (n=20)	
	Frequency	%	Frequency	%
Age*				
▪ <25 years	8	20.0	6	30.0
▪ 25–	21	52.5	14	70.0
▪ 35+	11	27.5	0	0.0
Marital status				
▪ Married	34	85.0	13	65.0
▪ Divorced	1	2.5	1	5.0
▪ Single	5	12.5	6	30.0

*P=0.034

Table 2: Post operative characteristics of the reduction mamoplasty

Post operative characteristics	Frequency (n=60)	%
Breast symmetry		
▪ Symmetrical	35	58.3
▪ Asymmetrical	25	41.7
Long term projection and contour		
▪ Satisfactory	33	55.0
▪ Unsatisfactory	27	45.0
Recurrence of breast ptosis		
▪ No	44	73.3
▪ Yes	16	26.7
Nipple position		
▪ Symmetrical	35	58.3
▪ Asymmetrical	25	41.7
Nipple sensation		
▪ Normal	41	68.3
▪ Decreased	16	26.7
▪ Lost	3	5.0

was reported in nearly three fourth of the cases (73.3%, n=44) (Table 3). Comparing the two groups of patients according to the pedicle type; we found that patients' satisfaction about the long term projection and contour of the breast was higher among patients who had superomedial pedicle with a statistical significant difference ($p<0.01$) (Figure 1). In addition, lesser percentage of recurrence of breast ptosis was recorded among those who had superomedial pedicle compared to those who had inferior pedicle with a statistical significant difference ($p=0.007$) (Figure 2).

As for scar acceptance, higher acceptance was reported by patients who had reduction mammoplasty via superomedial pedicle compared to inferior pedicle with a statistical significant difference ($p<0.001$). The overall satisfaction about the operation was higher

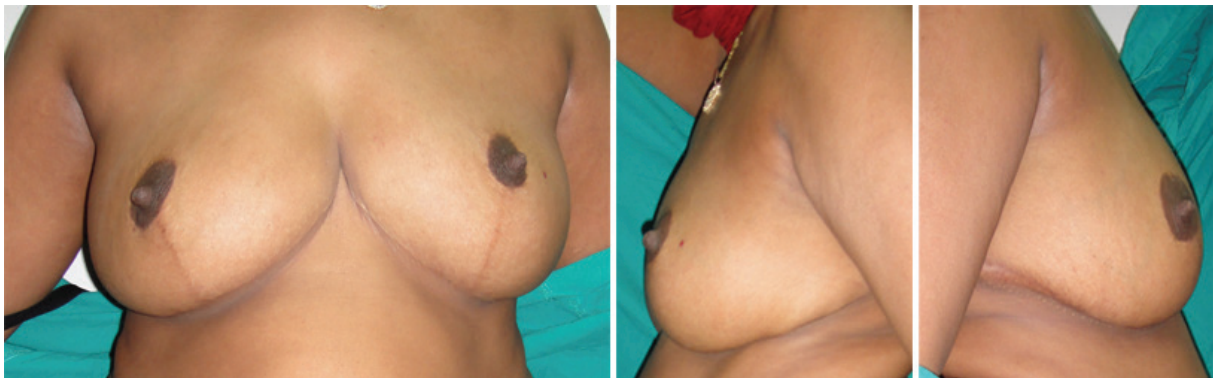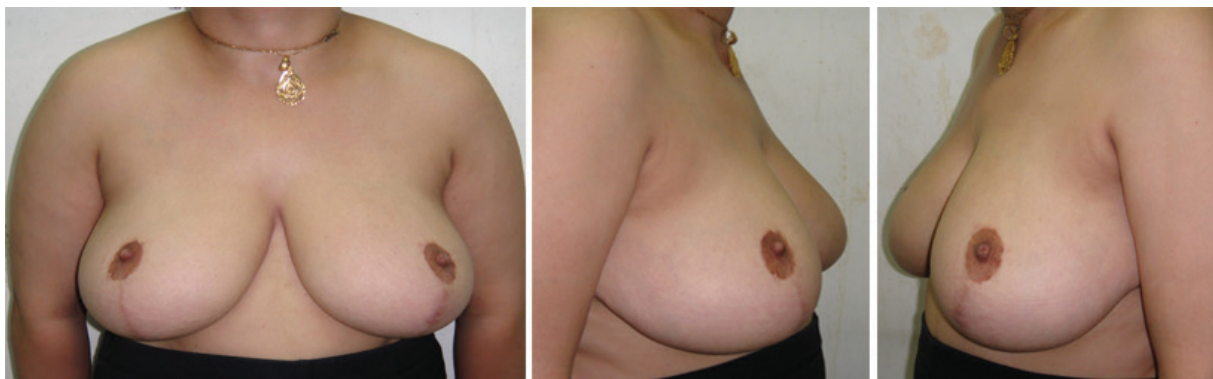
among patients who had superomedial pedicle compared to those who had inferior pedicle with a statistical significant difference ($p=0.007$). The mean score of satisfaction was higher among patients who had superomedial pedicle than inferior pedicle (Table 4). On the other hand, no statistical significant difference was observed between patients who had either types of operations concerning breast symmetry, nipple symmetry and sensation.

DISCUSSION

The search for the ideal technique to reduce the size of large breasts has continued for decades. The objective of a reduction procedure is primarily to reduce the size of the hypertrophic breast with appropriate redraping of the skin envelope while maintaining a viable NAC.²

Table 3: Post operative patient satisfaction

Patient satisfaction	Frequency (n=60)	%
Scar acceptance		
▪ Highly acceptable	26	43.3
▪ Moderately acceptable	26	43.3
▪ Not acceptable	8	13.4
Overall satisfaction		
▪ Satisfied	44	73.3
▪ Unsatisfied	16	26.7

**Fig. 1:** Late post operative patient who had superomedial pedicle reduction mammoplasty showing good projection and contour of the breasts.**Fig. 2:** Late post operative patient who had inferior pedicle reduction mammoplasty showing recurrence of glandular breast ptosis (bottoming out).

Criticisms of procedures always include the loss of long term projection, quality and length of scars, development of bottoming out. Several techniques have appeared over the years and modifications of the basic principles also were published, but yet until now, there is no single technique that appears to fulfill all the criteria of excellence.¹⁹

In this study comparing the long term follow up of the inferior pedicle and superomedial pedicle reduction mammoplasty, we found that patients' satisfaction about the long term projection and contour of the breast was higher among patients who had superomedial pedicle. This result was in accordance with Nahabedian et al., 2000 as they mentioned that the medial

and superiomedial techniques give enhancement of the central breast projection.¹⁹

We also found that lesser percentage of recurrence of breast ptosis was recorded among those who had superomedial pedicle compared to those who had inferior pedicle technique. Bericout, 1996 stated that, in inferior pedicle reduction mammoplasty, cleavage between the superior skin envelope and the dermo-glandular pedicle makes the pedicle more exposed to the effects of gravity and this increases the risk of secondary ptosis compared to other techniques.²⁰

Inferior pedicle reduction mammoplasty is one of the most popular techniques, especially in North America. This technique is safe and can be applied equally to minimally, moderate,

Table 4: Post operative characteristics and patient satisfaction according to the type of pedicle

Variable	Inferior pedicle (n=40)		Superomedial pedicle (n=20)	
	Frequency	%	Frequency	%
Long term projection and contour*				
▪ Satisfactory	14	35.0	19	95.0
▪ Unsatisfactory	26	65.0	1	5.0
Recurrence of breast ptosis*				
▪ No	25	62.5	19	95.0
▪ Yes	15	37.5	1	5.0
Scar acceptance*				
▪ Highly acceptable	10	25.0	16	80.0
▪ Moderately acceptable	23	57.5	3	15.0
▪ Not acceptable	7	17.5	1	5.0
Overall satisfaction*				
▪ Satisfied	25	62.5	19	95.0
▪ Unsatisfied	15	37.5	1	5.0
Mean score of satisfaction±SD	3.18 ±1.1		4.5 ±0.6	

and massively enlarged breasts. The vascular basis of this pedicle is the musculo-cutaneous perforating branches of the internal mammary artery through the pectoralis major muscle and intercostal perforating branches through the muscle. It is very reliable and safe technique. However, the need to preserve and maintain central and lower breast tissue may lead to postoperative bottoming out.²¹

Later bottoming out of the breast or pseudoptosis was considered an inevitable sequel of the inferior pedicle technique.²²⁻²⁴ On the other hand, no statistical significant difference was observed between patients undergone either types of operations concerning breast symmetry, nipple symmetry and sensation. Inferior pedicle technique is able to achieve good cosmetic result with a reliable vascular and nerve supply to the NAC.^{13,14}

Superomedial technique was able to produce a good aesthetic result as regard conical breast projection with normal NAC sensation. This is explained by the fact that incorporating a medial component to the superior pedicle preserves the anterior cutaneous branches of the 2nd-5th intercostal nerves.² We found that, the overall satisfaction about the operation was higher among patients who undergone superomedial pedicle compared to those who had inferior pedicle.

Studies have shown that the choice of reduction mammoplasty technique has a considerable influence on the durability of the aesthetic result. This was attributed to the

gradual increase in length of the vertical infra-areolar scar (bottoming out effect) which was maximum in the inferior pedicle and minimum in the superior pedicle. Thus the superomedial pedicle shows better long term cosmetic result.²⁵ From this study comparing the long term follow up of the inferior pedicle and superomedial pedicle reduction mammoplasty, we concluded that the superomedial pedicle shows better long term aesthetics, projection and contour of the breast in addition to the less incidence of glandular ptosis.

CONFLICT OF INTEREST

The authors declare no conflict of interest.

REFERENCES

- 1 Guyuron B. Plastic Surgery. Indications, Operations and Outcomes. Mosby, 2000; p. 2709.
- 2 Finger RE, Vasquez B, Drew S, Given KS. Superomedial pedicle technique of reduction mammoplasty. *Plast Reconstr Surg* 1989;**83**:471-8.
- 3 Lassus C. A technique for breast reduction. *Int J Surg* 1970;**53**: 69e72.
- 4 Lassus C. Breast reduction: evolution of a techniquee a single vertical scar. *Aesthetic Plast Surg* 1987;**11**:107e12.
- 5 Lassus C. A 30-year experience with vertical mammoplasty. *Plast Reconstr Surg* 1996;**97**:373e80.

- 6 Lejour M. Vertical mammaplasty and liposuction of the breast. *Plast Reconstr Surg* 1994;**94**:100e14.
- 7 Lejour M, Abboud M, Declety A, Kertesz P. Reduction of mammaplasty scars: from a short inframammary scar to a vertical scar. *Ann Chir Plast Esthet* 1990;**35**:369e79.
- 8 Mckissock PK. Reduction mammaplasty. With a vertical dermal flap. *Plast Reconstr Surg* 1972;**49**:245-52.
- 9 Robbins TH. A reduction mammaplasty with the areola-nipple based on an inferior dermal pedicle. *Plast Reconstr Surg* 1977;**59**:64.
- 10 Courtiss EH, Goldwyn RJ. Reduction mammaplasty by the inferior pedicle technique. *Plast Reconstr Surg* 1977;**59**:500.
- 11 Ribeiro L. A new technique for reduction mammaplasty. *Plast Reconstr Surg* 1975;**55**:330.
- 12 Hidalgo DA, Elliot LF, Palumbo S, Casas L, Hammond D. Current trends in breast reduction. *Plast Reconstr Surg* 1999;**104**:806.
- 13 Mizgala CL, MacKenize KM. Breast reduction outcome study. *Ann Plast Surg* 2000;**44**:125-33.
- 14 Bohmert H, Gabka CJ. Plastic and Reconstructive Surgery of the Breast. A Surgical Atlas. Thieme. Stuttgart. New York, 1997; p. 37.
- 15 Orlando JC, Gutherie Jr RH. The superomedial dermal pedicle for nipple transposition. *Br J Plast Surg* 1975;**28**:42-5.
- 16 Abramo AC. A superior vertical dermal pedicle for the nipple-areola: an alternative for severe breast hypertrophy and ptosis. *Aesthetic Plast Surg* 2012;**36**:134-9.
- 17 Hauben DJ. Experience and refinements with the superomedial dermal pedicle for nipple-areola transposition in reduction mammoplasty. *Aesthetic Plast Surg* 1984;**8**:189e94.
- 18 Hugo NE, McClellan RM. Reduction mammaplasty with a single superiorly-based pedicle. *Plast Reconstr Surg* 1979;**63**:230e4.
- 19 Nahabedian M, McGibbon B, Manson P. Medial pedicle Reduction Mammaplasty For severe Mammary Hypertrophy. *Plast Reconstr Surg* 2000;**105**:896-904.
- 20 Bricout N. Breast Surgery. Springer-Verlag, Paris. 1996.
- 21 Nahai F. Clinical Decision-Making in Breast surgery. The art of aesthetic surgery: Quality Medical publishing, Inc. 2005. pp. 1817-58.
- 22 Hall-Findlay EJ. Pedicles in vertical reduction and mastopexy. *Clin Plastic Surg* 2002;**29**:379.
- 23 Reus WF, Mathes SJ. Preservation of projection after reduction mammaplasty: Long-term follow-up of the inferior pedicle technique. *Plast Reconstr Surg* 1987;**82**:644.
- 24 Karp NS. Medial pedicle/vertical breast reduction made easy, the importance of complete inferior glandular resection. *Ann Plast Surg* 2004;**52**:458.
- 25 White DJ, Maxwell GP. Reduction Mammoplasty. In: Plastic Surgery Indications, Operations, and Outcomes. Eds: Bruce MA, Eriksson E, Bahman G., et al., Louis, 2000; P. 2705-43.