

# Evaluation of Complications and Effectiveness of Snodgraft Method on the Treatment of Distal Hypospadias or Midshaft

Mehran Peyvasteh<sup>1</sup>, Shahnam Askarpour<sup>1</sup>, Armin Mohamadi<sup>1</sup>, Hoda Ilkhani Pak<sup>1\*</sup>

1. Department of Surgery, Ahvaz Jundishapur, University of Medical Sciences, Ahvaz, Iran

## ABSTRACT

**Objective:** Hypospadias is one of the most common diseases of the male reproductive system. Considering the different treatment techniques for this anomaly and important complications such as fistula, meatal/neourethral stenosis, an attempt is made to use a method that has the best result and the least complication for treatment. The aim of this study was to evaluate the snodgraft method in repairing distal or midshaft hypospadias in terms of complications, beauty and effectiveness.

**Methods:** In this retrospective study, conducted Oct 2018 to Oct 2020, 60 boys with distal hypospadias or midshaft who underwent the methods of Snodgraft in Imam Khomeini and Abuzar Hospitals of Ahvaz, southern Iran were enrolled. All patients were followed up and examined for postoperative complications after surgery with intervals of 1 week, 2 weeks, monthly to 6 months and then annually.

**Results:** The mean age of patients was 30.1±11.3 months. No surgical diverticulitis or meatal stenosis was seen after surgery. Urethrocutaneous fistula was seen in 4 patients at initial follow-up, of these 4 patients, 1 spontaneous improvement was seen after 6 months. Urinary status was normal in all patients. Bleeding, hematoma and meatus stenosis were not observed in patients. In all patients, the appearance of meatus was very good and similar to normal people.

**Conclusion:** The snodgraft surgery method in repairing hypospadias is a very simple, appropriate method and with a good appearance of Glans and Meatus, and the complications of this technique are few and acceptable. To confirm our findings, prospective studies with larger sample size of patients are needed.

**Keywords:** Hypospadias, Snodgraft, Complications

## Please cite this paper as:

Peyvasteh M, Askarpour S, Mohamadi A, Ilkhani Pak H. Evaluation of Complications and Effectiveness of Snodgraft Method on the Treatment of Distal Hypospadias or Midshaft. *World J Plast Surg.* 2022;11(1):38-43. doi: 10.52547/wjps.11.1.38

## \*Corresponding Author:

Dr. Hoda Ilkhani Pak

Department of Surgery, Ahvaz Jundishapur, University of Medical Sciences, Ahvaz, Iran

**Email:** ilkhanipakhoda@gmail.com

**Received:** 21 Jun 2021

**Accepted:** 15 Jan 2022

## INTRODUCTION

Hypospadias, a nomination of medical term, was derived from the Greek terms: hypo meaning under and spadon meaning rent or fissure<sup>1</sup>. Hypospadias is one of the most prevalent congenital anomalies of the external genitalia of boys<sup>2</sup> determined by three anomalies of the penis as follows: a ventrally located meatus anywhere between the glans and the perineum, the dorsal prepuce hood in association with a ventral deficit of the prepuce, and chordee<sup>3</sup>.

The rate of hypospadias is reported 1/300 male births<sup>4</sup>. Hypospadias categorized into: anterior (50%) including glanular, coronal and subcoronal regions. Middle (30%) which includes the distal penile, mid-shaft and proximal penile regions, and the posterior type is 20% of cases including penoscrotal, scrotal and perineal.<sup>5,6</sup>

Tubularized incised plate urethroplasty (TIP) is the predominant method for repairing distal and midshaft hypospadias for at least two decades<sup>7</sup>. This technique is associated with good results in terms of cosmetic and function, where the urethral plate is narrow or shallow, these results may be compromised<sup>8</sup>. In TIP method, several complications have been reported, the most common of which is meatal / neourethral stenosis, for which several causes have been suggested<sup>9</sup>. In addition, urethrocutaneous fistula formation is the most common complication of hypospadias treatment with an incidence of between 4-25%<sup>10</sup>. Dorsal inlay graft urethroplasty (snodgraft), which uses a free graft on the posterior plate of the urethra, has been introduced as an effective method in treatment the distal hypospadias and mid-shaft, which has significant results in reducing the risk of meatal / neourethral stenosis due to the creation of appropriate depth and lack of scarring<sup>11</sup>.

Since the introduction of this method in 2000, few studies have been done on this technique and more studies are needed to confirm the applicability and safety of this method<sup>7, 12, 13</sup>. Hence, we aimed to evaluate the snodgraft method in repairing distal or midshaft hypospadias in terms of complications, cosmetic and effectiveness.

## MATERIAL AND METHODS

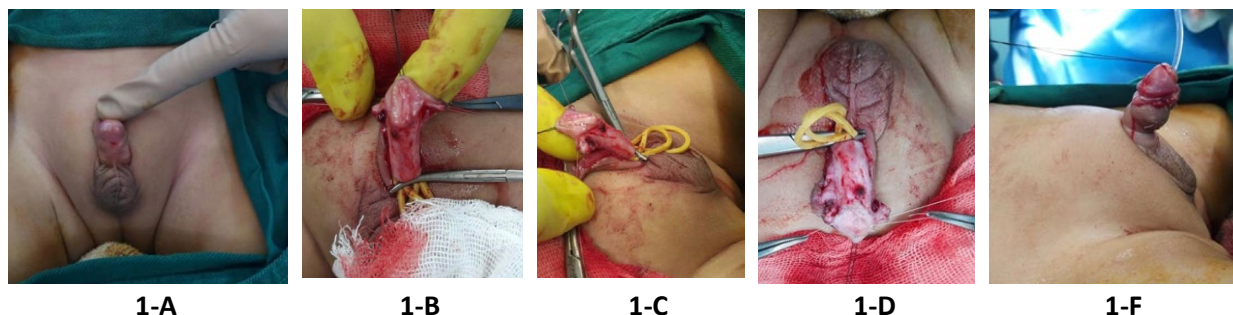
In this retrospective study, sixty children with distal hypospadias or midshaft referred to Abuzar and Imam Khomeini hospitals in Ahvaz, southern Iran

from October 2018 to October 2020 underwent Snodgraft surgery were enrolled. Children with proximal hypospadias, severe chordee, circumcised penis, and micropenis were excluded.

Distal hypospadias was defined as meatallocation distal to the mid penile shaft. The presence of chordee was checked with an artificial erection intraoperatively after degloving the penis when necessary. Micropenis was defined as stretched penile length less than 2.5 SD below mean normal for age.

In this study, optical magnification was used in all surgeries. The surgical procedure was as follows: After circumferential incision and degloving of the penis, diluted adrenaline was injected into the glans to prevent bleeding. Bilateral incisions were made along the urethral plate to prepare the glans wings. The urethral plate was cut longitudinally in the midline. The width and length of the incised urethral plate were measured, and depending on each patient, an inner prepuse was taken with a width of about 0.5-0.8 cm, and a length of 0.5-1.5 cm as a free graft from the dorsal preputial hood. Excess fat was removed. This was laid as a free graft in the diamond-shaped defect and sutured in place around its edges. In addition, a quilting stich was placed in the center of this graft to secure it in the depth of the neourethral groove. The urethral plate is then tabularized around an 8-Fr feeding tube. Using a continuous subcuticular absorbable suture in two layers. In all of the cases, a vascularized tunica vaginalis flap was used to cover the graft, and then, the glans wings were closed, followed by the skin cover. The bandage and catheter were kept for one week. **Figure 1** shows the steps of the snodgraft method for hypospadias treatment.

Patients were followed up in the hospital daily and after discharge at intervals of one week, two weeks, monthly for up to 6 months, and then annually (for 18 months). During repeated visits based on history



**Figure 1:** Snodgraft technique for hypospadias repairing

and physical examination, the appearance of glans, penis cover, chordee, deviation of urine flow were examined and the presence on meatal/neourethral stenosis was assessed by checking the calibration of the neourethra with approximately 1 cm insertion of a feeding tube that was the same size as the intraoperative catheter. Patient's characteristics, including age, postoperative bleeding, hematoma, meatal stenosis, fistula, urethral stricture, wound infection, detachment of the wound edge, recorded daily until hospitalization, were recorded in a questionnaire. Those patients who had incomplete records were excluded from the study.

The written informed consent was obtained from all parents of patients or legal guardians. The approval was obtained from the ethics committee of Ahvaz Jundishapur University of Medical Sciences before the study (IR.AJUMS.HGOLESTAN.REC.1399.114).

### Statistical Analysis

Data were analyzed using IBM SPSS software package version 22. Kolmogorov–Smirnov test was used to determine the normal or abnormal distribution of quantitative data. Descriptive statistics were presented as mean  $\pm$  standard deviation (SD) for quantity values and frequency (percentage) for qualitative values.

## RESULTS

Sixty patients referred to Ahvaz hospitals for the treatment of distal hypospadias or midshaft were examined. The mean age of patients was  $30.1 \pm 11.3$  months. The age of two patients was less than 10 months, and the highest frequency (13 patients) were related to children aged 35 to 40 months. In terms of birth weight, 18.30% of patients were less than 2500 grams. Gestational age at birth in 25.30% of patients were less than 37 weeks. Family history of hypospadias was positive in 10% of patients. The most common type of distal hypospadias was coronal (30%). The mean number of hospitalization days in the studied samples was  $3.95 \pm 1.86$  days. The duration of hospitalization was three days with the highest frequency (29 people). Regarding the duration of surgery, the mean surgery time of the samples was  $103.90 \pm 25.54$  with a minimum of 60 and a maximum of 140 minutes. Detailed demographic and clinical features of the studied patients are shown in Table 1.

All patients were followed up after surgery with intervals of 1 week, 2 weeks, monthly to 6 months and then annually (18 months in total). In this study, no diverticulitis or meatal stenosis were seen after surgery. Moreover, hematoma and bleeding were not observed in any of the patients.

**Table 1:** Demographic and clinical characteristics of patients

Characteristics	Results	
Age (Month) (Mean $\pm$ SD)	30.2 $\pm$ 11.3	
Birth weight (Gram) (n, %)	<2500	11 (18.30)
	>2500	49 (71.70)
Gestational age (week) (n, %)	<37	15 (25.00)
	$\geq$ 37	45 (75.00)
Family history (n, %)	Yes	6 (10)
	No	54 (90)
Types of distal hypospadias	Mid penile	11 (18.34)
	Glanular	5 (8.33)
	Coronal	18 (30)
Duration of hospitalization (day) (Mean $\pm$ SD)	Subcoronal	26 (43.33)
		3.95 $\pm$ 1.86
Operation time (minute) (Mean $\pm$ SD)	103.90 $\pm$ 25.54	

**Table 2:** Postoperative complications of snodgraft procedure in hypospadias repair

Complications	Frequency	Percentage	Group	Visit
Fistula	4	6.66	Mid penile	The first and second week and follow-up for 6 months
Meatal stenosis	0	0	-	-
Wound infection and glans rupture	1	1.66	Subcoronal	The first and second week
Bleeding	0	0	-	-
Hematoma	0	0	-	-



Figure 2: Follow-up of two patients after 6 months

There was a case of wound infection (1.66%) followed by complete opening of the operation site due to the use of ashes by the parents on the wound based on the indigenous belief in wound disinfection. Urethrocutaneous fistula was seen in 4 patients (6.66%) in the initial follow-up and out of these 4 patients, 1 patient spontaneous improvement was seen after 6 months. In the other 3 patients, reconstructive surgery was performed, which was successful in all 3 cases, and no case of urethral meatal stenosis was seen on the calibration of the neourethra. In all patients, the appearance of meatus was very suitable and similar to normal people. The shape of the meatus was longitudinal and slit. Urinary status was normal in all patients and no urinary retention was observed in any case. The frequency of postoperative complications of snodgraft procedure are provided in Table 2. Figure 2 shows the follow-up of two patients after 6 months.

## DISCUSSION

Hypospadias is a common disease with unknown causes in terms of variety and severity. The purpose of hypospadias repair is to normalize function and appearance. The optimal age for surgical intervention is still under discussion and is affected by the risks of anesthesia, tissue dimensions at different ages, postoperative complications, and the impact of psychological and social dimensions. Functional and visual outcomes in the long run are generally acceptable, but still lower than in men without hypospadias<sup>14,15</sup>.

The aim of this study was to evaluate the snodgraft method in the repair of distal or midshaft

hypospadias in terms of complications, cosmetic and effectiveness in 60 patients referred to Ahvaz hospitals.

So far, no agreement has been reached on an ideal technique for repairing hypospadias. The Snodgrass technique was revolutionary in this way and became one of the most widely used techniques for repairing distal hypospadias. It has many benefits, such as better beauty of the meatus at the tip of the penis and a flat phallus<sup>16</sup>. On the other hand, some common complications associated with snodgrass urethroplasty include fistula, meatus stenosis, and urethral stricture. Many changes have been described to reduce these complications, including vertical hole configuration, back cut changes, and inlay graft<sup>17</sup>. Narrow urethral plate and even plate incision were considered as the most common causes of Snodgrass complications. The snodgraft technique was first described by Kolon and Gonzales, which partially eliminated the disadvantages of Snodgrass. Snodgraft filled out the traditional hypospadias repair criteria and was a successful addition to the armamentarium of the hypospadiologist<sup>13</sup>.

In a study to investigate the snodgraft method in the treatment of distal hypospadias, the results showed that on average 2.4 years of follow-up, there was no meatal stenosis or diverticulum at the graft site<sup>7</sup>. In addition, urinary fistula was observed in 10 patients (9.8%), slit-like appearance of neomeatus was observed in all patients. None of the patients who underwent Snodgraft surgery had meatal/neourethral stenosis<sup>7</sup>, which is consistent with the results of the current study. In the present study, fistula was observed in 4 patients (6.66%) and meatal stenosis was not observed in any of the

patients. Urinary status was normal in all patients and no patients developed obstructive urinary flow. Similar to our result, in another study, no obstructive urinary flow pattern was detected during follow-up of patients<sup>7</sup>.

In another study to evaluate the snodgraft method in patients with distal hypospadias, none of the 14 patients had meatal stenosis with a mean follow-up of 18 months<sup>12</sup>, which was in line with our results. Fistula was observed in one patient<sup>12</sup>, while in the present study, fistula was observed in 4 patients (6.66%).

According to the study of Eldeeb et al., the snodgraft method was not superior to the snodgrass operation in the narrow plate of a healthy urethra<sup>11</sup>. Moreover in the study of Eldeeb, there were no differences between both groups regarding the outcomes such as fistula, meatal stenosis and dehiscence<sup>11</sup>. Although the snodgrass method is a common method with excellent results and few complications, the snodgraft method is quite suitable for creating a deep and wide urethral plate. In addition, snodgraft has clearly reduced the two-step procedure performed due to the shallow depth of the urethral or small penis. Furthermore, the snodgraft technique partially eliminated the disadvantages of other methods such as fistula and stenosis<sup>11</sup>. One of the limitations of this study is the small sample size.

## CONCLUSION

The snodgraft surgery method in repairing hypospadias is a very simple, appropriate method with a good appearance of glans and meatus, and the complications of this technique are few and acceptable. The functional and cosmetic results in the short-term follow up were excellent, however, the permanence of the surgical results requires that these patients be followed up for longer. It is suggested that in a multicenter study with higher sample size, hypospadias surgery be evaluated by snodgraft method, and in addition to determining short-term complications, cosmetic results, sexual function and satisfaction after puberty and sexual life be followed for a long time.

## ACKNOWLEDGEMENTS

The authors are thankful of Clinical Research Development units, Imam Khomeini and Abuzar Hospitals for their assistance.

## CONFLICT OF INTERESTS

None declared.

## REFERENCES

1. Almusafer M, Mezban SG, Faisal M. The outcome of double dartos versus single layer flap in snodgrass urethroplasty for distal hypospadias repair in basra training center of urology. *Basrah Journal of Surgery* 2021;**27**(2):2.
2. Van der Zanden L, Van Rooij I, Feitz W, Franke B, Knoers N, Roeleveld N. Aetiology of hypospadias: a systematic review of genes and environment. *Hum Reprod Update* 2012;**18**(3):260-83.
3. Pramod S, Anukethan J. Short term outcomes of snodgrass urethroplasty in distal and mid penile hypospadias. *Int Surg J* 2018;**5**(5):1878-81.
4. Sheikh MA, Latif T, Ahmad JAM. Hypospadias repair in children: 10-years experience at shaikh zayed hospital lahore. *The Professional Medical Journal* 2019;**26**(07):1020-6.
5. Zain AZ. Snodgrass urethroplasty for mid and distal penile hypospadias. *Iraqi J Med Sci* 2017;**15**(3).
6. Askarpour S, Peyvasteh M, Mohamadi A, Khoshkhabar M. Comparative Study of Modifying Meatal Advancement Glandular with Release Chordi versus Snodgrass Surgical Methods Regarding the Repair of Distal Hypospadias. *World J Plastic Surg* 2021;**10**(3):73.
7. SilayMS, SirinH, Tepeler A, et al. "Snodgraft" technique for the treatment of primary distal hypospadias: pushing the envelope. *J Urol* 2012;**188**(3):938-42.
8. Holland A, Smith G. Effect of the depth and width of the urethral plate on tubularized incised plate urethroplasty. *J Urol* 2000;**164**(2):489-91.
9. Wilkinson DJ, Farrelly P, Kenny SE. Outcomes in distal hypospadias: a systematic review of the Mathieu and tubularized incised plate repairs. *J Pediatr Urol* 2012;**8**(3):307-12.
10. Bakan V, Yildiz A. Dorsal double-layer dartos flap for preventing fistulae formation in the Snodgrass technique. *Urol Int* 2007;**78**(3):241-4.
11. Eldeeb M, Nagla S, Abou-Farha M, Hassan A. Snodgrass vs Snodgraft operation to repair the distal hypospadias in the narrow urethral plate. *J Pediatr Urol* 2020;**16**(2):165. e1-. e8.
12. Gundeti M, Queteishat A, Desai D, Cuckow P. Use of an inner preputial free graft to extend the indications of Snodgrass hypospadias repair (Snodgraft). *J Pediatr Urol* 2005;**1**(6):395-6.
13. Kolon Tf, Gonzales Et. The dorsal inlay graft for hypospadias repair. *J Urol* 2000;**163**(6):1941-3.
14. Leunbach TL, Springer A, Williamson PR, Ahmed SF.

- A systematic review of core outcomes for hypospadias surgery. *Sex Dev* 2019;**13**(4):165-70.
15. Yu X, Nassar N, Mastroiacovo P, et al. Hypospadias prevalence and trends in international birth defect surveillance systems, 1980–2010. *Eur Urol* 2019;**76**(4):482-90.
16. Snodgrass WT, Nguyen MT. Current technique of tubularized incised plate hypospadias repair. *Urology* 2002;**60**(1):157-62.
17. Silay MS, Armagan A, Erdem MR, Akcay M, Kilincaslan H. Tubularized incised plate urethroplasty with dorsal inlay graft prevents meatal/neourethral stenosis: a single surgeon's experience. *J Pediatr Surg* 2012;**47**(7):1480.