

Use of FACIAL ARTERY MUSCULOMUCOSAL and Turbinate Flaps for Rapp Hodgkin Syndrome

Mahdy Saboury ^{1*}, Noor Ahmad Latifi ¹, Shahriar Saboury ², Moosa Saboury ³

1. Department of Plastic and Reconstructive Surgery, School of Medicine, Iran University of Medical Sciences, Tehran, Iran.

2. Department of General Surgery, School of Medicine, Iran University of Medical Sciences, Tehran, Iran.

3. Department of Hematology-Oncology, School of Medicine, Tehran University of Medical Sciences, Tehran, Iran.

ABSTRACT

Rapp Hodgkin Syndrome (RHS), is a subtype of Ectodermal Dysplasias (EDs), which has various manifestation. Here, we report a case on repair of the palatal cleft in an 18 year old girl, having RHS, with combination of facial artery musculomucosal (FAMM) flap and inferior turbinate flaps (ITF), at Hazrat Fatima Hospital, Tehran, Iran in 2021.

KEYWORDS

Rapp Hodgkin Syndrome; FAMM flap; Inferior turbinate Flap; Ectodermal Dysplasias

Please cite this paper as:

Saboury M, Latifi NA, Saboury S, Saboury M. Use of FACIAL ARTERY MUSCULOMUCOSAL and Turbinate Flaps for Rapp Hodgkin Syndrome. *World J Plast Surg.* 2022;11(2):153-156.
doi: 10.52547/wjps.11.2.153

INTRODUCTION

Ectodermal Dysplasias (EDs) is defined by rare mendelian mode genetic disorder that affect many areas such as skin, teeth, nails, hair, sweat glands, ear, eye, fingers, nipples, oral and nasal and rectal mucosa ¹⁻⁴.

There are 150 different subtypes of EDs classified into 4 groups based on absence or presence of its defects:

EDs 1: Trichodysplasia

EDs 2: Dental dysplasia

EDs 3: Onychodysplasia

EDs 4: Dyshydrosis ³.

The most commonly EDs syndromes that affect midfacial structures are:

- (1) Ectodermal dysplasia, Ectrodactyly, and Clefting (EEC) syndrome
- (2) Hay-Wells syndrome or Ankyloblepharon, Ectodermal dysplasia, and Cleft lip/palate (AEC) syndrome;
- (3) Rapp-Hodgkin syndrome (RHS).

All of which are caused by mutations in the *TP63* gene.

RHS was described earlier ⁵, characterized by anhidrotic Eds, cleft lip, cleft palate, narrow nose, anodontia, wiry hairs, conical teeth, anonychia, lacrimal duct stenosis, ear canal abnormalities and genitourinary abnormalities ⁵⁻⁷.

As our knowledge, this is the first report of combination of FAMM and inferior turbinate flaps (ITF) for treatment of the palatal cleft in RHS patient.

*Corresponding Author:

Mahdy Saboury MD,

Assistant Professor of Plastic and Reconstructive Surgery Department of Plastic and Reconstructive Surgery, School of Medicine, Iran University of Medical Sciences, Tehran, Iran

Tel.: +989021120064

Email: dr.mahdysaboury@yahoo.com

Received: 2022/04/21

Accepted: 2022/07/19



This work is licensed under a Creative Commons Attribution-NonCommercial 4.0 International license. (<https://creativecommons.org/licenses/by-nc/4.0/>). Non-commercial uses of the work are permitted, provided the original work is properly cited.

Case presentation

An 18 year old girl presented with complaint of unsuccessful prior cleft palate surgeries at Hazrat Fatima hospital, Tehran, Iran, in 2021 (Figure 1).

She did not have hair and eyelashes at birth. There was no history of similar issue in the family, parents were not related. Lack of hair and eyelashes and eyebrows, microsomia, anodontia, cleft lip and nose and wide cleft palate and severe old scars was obvious. She had normal fingers and genitourinary system.

She had multiple surgeries for lip and nose and palate but as shown in Figure 2, they were unsuccessful.

We admitted her with primary diagnosis of Eds, after precise searches, we found out that she had one of rare syndrome, one subtype of Eds: RHS. At last, after 18 years she was diagnosed with RHS.

Multidisciplinary consultations were done with ENT surgeon for hearing loss and orthodontics for anodontia and skin specialties. We decided to do inferior turbinate bipedicle flaps for nasal surface closure and FAMM flap for repairing the oral side of wide palatal cleft. Because of severe scars that remain from previous surgeries, local flaps were not suitable.

After adequate infiltration of 1/100000 epinephrin

solution in the inferior turbinate mucosa, one perpendicular incision was made at the middle point of the turbinate and with meticulous bilateral horizontal dissection, two open book flaps were made, therefore we closed the nasal side of the palate.

For oral side of the palatal cleft, we used FAMM flap, which is robust pediculate flap that can use for large palatal defects. This flap consists of mucosa, sub mucosa, a small amount of buccinator muscle, the deeper plane of the orbicularis oris muscle and the facial artery and venous plexus. After precise marking with great care, antegrade flow flap was raised and reach to the oral side of the palatal cleft and complete closure of the cleft was achieved (Figure 3).

Declaration of patient consent

The authors certify that they have obtained all appropriate patient consent forms. The patient has given her consent for her images and other clinical information to be reported in the journal. The patient understands that her name and initial will not be published and due efforts will be made to conceal her identity, but anonymity cannot be guaranteed.

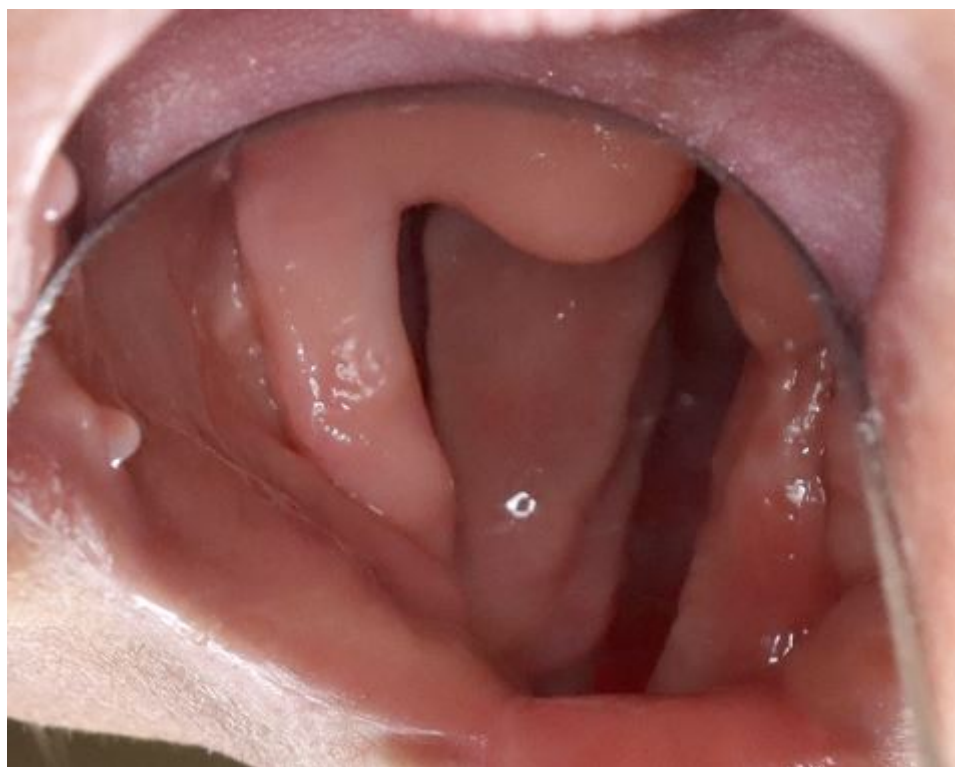

Fig. 1: Wide palatal cleft in patient with RHS. Note: large inferior turbinate was obvious.

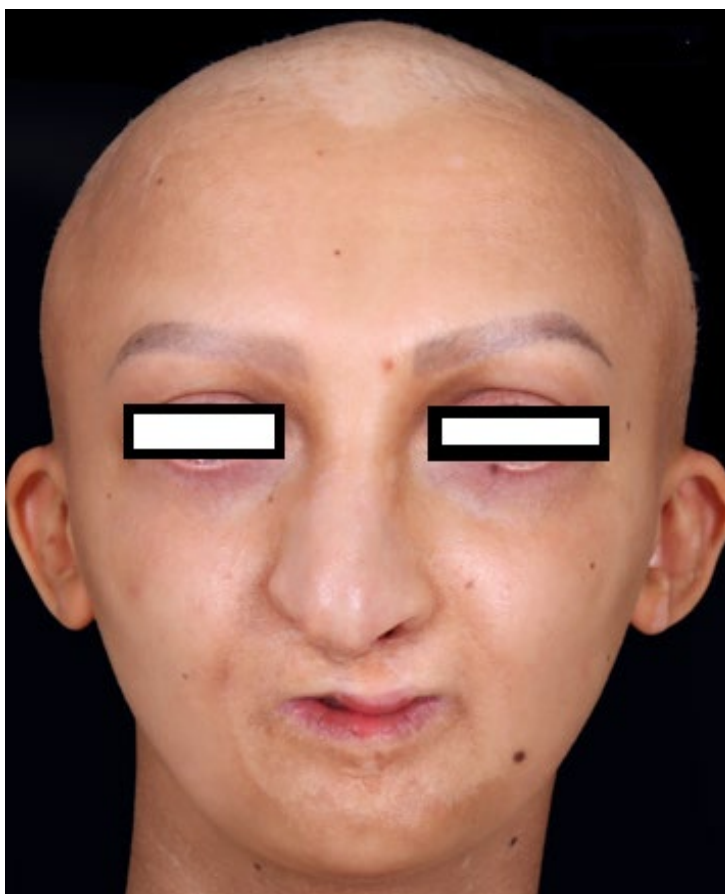


Fig. 2: Lack of hair, eyebrows and eyelashes, cleft lip and nose, surgical scars in the case of RHS.

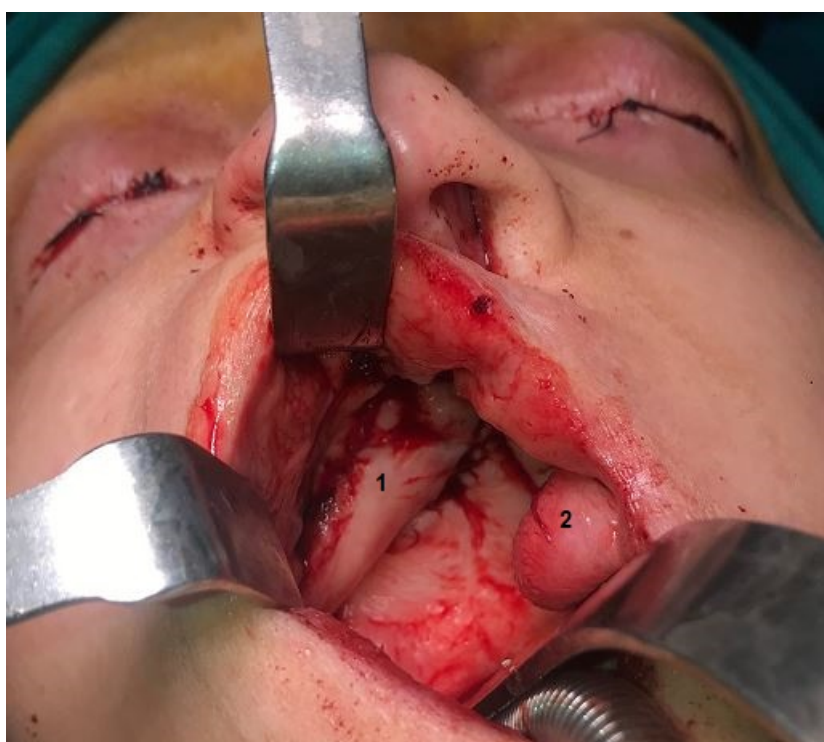

Fig. 3: Repair of palatal cleft with FAMM (1) +ITF. Number (2) shows the tongue.

This study was approved by Ethical Committee of Iran University of Medical Sciences and Baqiyatallah University of Medical Sciences: IR.BMSU.BAQ.REC.1398.046.

DISCUSSION

Congenital defect in 2 or more of ectodermal structures inherited by genetic disorders identified as Eds. 3 subtypes of Eds are associated with mid facial hypoplasia and clefts:

Ectrodactyly-Ectodermal Dysplasia-Cleft lip-palate syndrome (EEC), Ankyloblepharon filiforme adenatum-Ectodermal Dysplasia-Cleft palate syndrome (AEC), and Rapp Hodgkin syndrome. These disorders are generally inherited in an autosomally dominant fashion but sporadic mutations do occur.

Rapp Hodgkin syndrome consists of lack of hair and eyelashes, eyebrows, lacrimal ducts obstruction, midfacial hypoplasia, cleft lip and palate, narrow nose and upper lip, oligodontia, anodontia, microsomia, hearing loss, and inability to sweat⁸⁻¹¹.

Our case did not have lacrimal ducts abnormalities and sweating disability. She had not diagnosed until 18 years old.

Awareness of this syndrome and its defects is essential for plastic and ENT surgeons, also for orthodontics.

CONCLUSION

Although, it is rare but, RHS patients are difficult for clinicians to treat cause multiorgan defects demand multidisciplinary approaches. For plastic surgeons, palatal / lip cleft repair in this type of patients, is challenging. We recommend use of combination of FAMM and ITF for repair of wide cleft in this scenario.

FUNDING

NONE.

CONFLICT OF INTEREST

NONE.

REFERENCES

- 1- Silengo MC, Davi GE, Bianco R, Costa M, DeMarco A, Verona R, et al. Distinctive hair changes (pili torti) in Rapp-Hodgkin ectodermal dysplasia syndrome. *Clin Genet* 1982; **21**:297-300.
- 2- Salinas CF, Montes-G GM. Rapp-Hodgkin syndrome: Observations on ten cases and characteristic hair changes (pili canaliculi). *Birth Defects Orig Art Ser* 1988;**24**:149-68.
- 3- Cambiaghi S, Tadini G, Barbareschi M, Menni S, Caputo R. Rapp-Hodgkin syndrome and AEC syndrome: Are they the same entity? *Br J Dermatol* 1994; **130**:97-101.
- 4- Celli JI, Duijf P, Hamel BC, Bamshad M, Kramer B, Smits AP, et al. Heterozygous germline mutations in the p53 homolog p63 are the cause of EEC syndrome. *Cell* 1999; **99**:143-53.
- 5- Bougeard G, Hadj-Rabia S, Faivre L, Sarafan-Vasseur N, Frébourg T. The Rapp-Hodgkin syndrome results from mutations of the TP63 gene. *Eur J Hum Genet* 2003; **11**:700-4.
- 6- Atila F, Visinoni, Toni Lisboa-Costa. Ectodermal dysplasias: clinical and Molecular Review. *Am J Med Genet Part A* 2009; **149**: 1980-2002.
- 7- Mikkola ML. Molecular aspects of hypohidrotic ectodermal dysplasia. *Am J Med Genet Part A* 2009; **149**: 2031-6.
- 8- Hoffmann A, Waśkiel-Burnat A, Żółkiewicz J, Blicharz L, Rakowska A, Goldust M, Olszewska M, Rudnicka L. Pili Torti: A Feature of Numerous Congenital and Acquired Conditions. *J Clin Med* 2021 Aug 30;**10**(17):3901. doi: 10.3390/jcm10173901. PMID: 34501349; PMCID: PMC8432236.
- 9- Koul M, Dwivedi R, Upadhyay V. Ectrodactyly-ectodermal dysplasia clefting syndrome (EEC syndrome). *J Oral Biol Craniofac Res* 2014;**4**:135-139.
- 10- Sutton VR, Plunkett K, Dang DX, Lewis RA, Bree AF, Bacino CA. Craniofacial and anthropometric phenotype in ankyloblepharon-ectodermal defects-cleft lip/palate syndrome (Hay-Wells syndrome) in a cohort of 17 patients. *Am J Med Genet A* 2009 Sep;**149** (9):1916-21. doi: 10.1002/ajmg.a.32791. PMID: 19676059.
- 11- Tosun G, Elbay U. Rapp-Hodgkin syndrome: clinical and dental findings. *J Clin Pediatr Dent* 2009 Fall;**34**(1):71-5. doi: 10.17796/jcpd.34.1.kr015833p1qg6873. PMID: 19953814.