Original Article

The Clinical and Radiographic Changes of Temporomandibular Joint (TMJ) Following Mandibular Set Back Surgery by Bilateral Sagittal Split Osteotomy (BSSO)

Mozhgan Kazemian[1], Nafiseh Ghadiri Moghaddam [2*], Najmeh Anbiaee[1], Hamed Kermani[1], Sahand Samiee Rad [3]

1. Oral and Maxillofacial Diseases Research Center, Mashhad University of Medical Sciences, Mashhad, Iran.
2. Department of Oral and Maxillofacial Surgery, Student Research Committee, Faculty of Dentistry, Mashhad University of Medical Sciences, Mashhad, Iran.
3. Dental Research Center, Mashhad University of Medical Sciences, Mashhad, Iran

***Corresponding Author:**

Ghadiri Moghaddam N

School of Dentistry, Mashhad University of Medical Sciences, Vakilabad Boulevard, Mashhad, Iran

Tel.: +989388251605
Email: ghadirim89@yahoo.com

Received: 2022/03/02
Accepted: 2022/05/29

ABSTRACT

Background
Bilateral Sagittal Split Osteotomy (BSSO) is one of the treatment options for Class III maxillary deficiency which may affect the condylar position and the patient's occlusion. We aimed to evaluate the clinical and radiographic changes of temporomandibular joint (TMJ) following mandibular set back surgery by BSSO.

Methods
In this retrospective study, All Class III patients, aged between 18-30 years old who underwent bimaxillary orthognathic surgery in the Oral and Maxillofacial Surgery Ward of Ghaem Hospital, Mashhad, Iran from January 2018- January 2020 were enrolled. Radiographic changes of joint space, condylar position and clinical changes for maximal mouth opening and joint sound were examined before and 6 months after surgery. Data were analyzed by SPSS16 software and the significance level of the data was set at P-value < 0.05.

Results
Twenty-five patients were recruited. The axial angle of the left and right condyle and condylar inclination on both sides reduced but this reduction was not statistically significant. While the anterior joint space was reduced and posterior joint space was increased in both sides, the changes on the right side were only significant (P = 0.039). In clinical examinations maximum mouth opening, lateral and protrusive movements were also decreased but this reduction was not statistically significant.

Conclusion
The mandibular set back with BSSO surgery in class III skeletal patients had no significant effect on the position of the condyle in the glenoid fossa as well as clinical symptoms.

Key words
Temporomandibular joint; Orthognathic surgery; Sagittal split osteotomy; Cone beam computed tomography

Please cite this paper as:
Kazemian M, Ghadiri Moghaddam N, Anbiaee N, Kermani H, Samiee Rad S. The Clinical and Radiographic Changes of Temporomandibular Joint (TMJ) Following Mandibular Set Back Surgery by Bilateral Sagittal Split Osteotomy (BSSO). World J Plast Surg. 2022;11(2):110-116.
doi: 10.52547/wjps.11.2.110

INTRODUCTION

Class III malocclusion is a result of either excessive mandibular growth or deficient maxillary growth, or a combination of both discrepancies. This type of dentofacial disorders affects the occlusion and the temporomandibular joint (TMJ) and its related structures [1-2]. At present, due to the advances in orthodontic therapy and corrective surgery, appropriate dentoskelatal relationship, function and esthetics

This work is licensed under a Creative Commons Attribution-NonCommercial 4.0 International license (https://creativecommons.org/licenses/by-nc/4.0/). Non-commercial uses of the work are permitted, provided the original work is properly cited.

[Downloaded from wjps.ir on 2024-10-12]

[DOI: 10.52547/wjps.11.2.110]

can be achieved in patients with this type of malocclusion[3-4-5]. This surgery can alter the position of the condyle and occlusion and these changes are capable of attenuating TMD (Temporomandibular disease) related symptoms or in some cases, even aggravating them [6-7].

The TMJ is the most complicated joint in the body and connects the mandible to the cranium, and includes the mandibular condyle, the glenoid fossa of the temporal bone, associated ligaments, and the articular disc that divides the cavity into upper and lower compartments[8-9].

CBCT (cone beam computed tomography) provides accurate images of the target area using a cone beam and a two-dimensional detector. Advantages include high-speed CT-level scanning, high resolution, lower exposure dose than CT, and the ability to accurately view and assess the TMJ[10-11]. CBCT has proven to be a highly cost-effective method for radiographic evaluation of the TMJ[12].

The fact that BSSO surgery is able to induce TMD symptoms or not still remains a subject of controversy[6-7]. Hence, we aimed to investigate the effect of BSSO surgery on the condylar position and TMD signs and symptoms in skeletal class III patients.

METHODS

In order to address the research objective a retrospective cross sectional study was designed and implemented.

All Class III patients, aged between 18-30 years old who underwent bimaxillary orthognathic surgery in the Oral and Maxillofacial Surgery Ward of Ghaem Hospital, Mashhad, Iran from January 2018- January 2020 were enrolled. Patients' files and medical documents were retrieved from the hospital archive. Patients with severe skeletal asymmetry, craniofacial syndromes as well as those with underlying systematic diseases which could possibly complicate the surgical procedure; were all excluded from the study. In order to be included in the study, having a preoperative CBCT image of the TMJ was mandatory

All operations were performed by the same surgical team. Mandibular setback surgery was performed using bilateral sagittal split osteotomy (BSSO) (Epker modification) and maxillary advancement through Lefort I osteotomy. Patients were clinically and radiographicaly evaluated one day prior to and six months after orthognathic surgery.

The results of clinical TMJ examinations were recorded in the patient's file both pre and postoperatively. Subjective variables as in maximum mouth opening (MMO), protrusive and lateral movements were measured and recorded. The presence or absence of pathologic TMJ noises as well as reporting pain on palpation was also evaluated.

One day before surgery and six months postoperatively, CBCT was obtained from the TMJ area of both sides for radiographic evaluation of the joint. CBCT images with the mouth closed and in the up-right position and while the FH plane was parallel to the ground, the CBCT device with the following specifications was used in 8.5 seconds of radiation. KVP: mA 12MAX MA, Mm 2 / 0slice thickness).

The condyles and articular space were examined in sagittal, coronal and axial plans according to the 25 reference points displayed in Tables 1 and 2. These reference points were determined [6]. In addition to

Table 1: Radiographic reference points

Plan	measurement	definition
sagittal	Po'Rt.-DRt./Po'Lt.-DLt	Distance between Po'&D
sagittal	FRt.-CoRt./FLt.-CoLt	Distance between F&Co
sagittal	AmRt.-LRt./AmLt.-LLt	Distance between Am&L
sagittal	Po'Rt.-AmRt./Po'Lt.-AmLt	Distance between Po'&Am
sagittal	Sagittal condylar angle Rt./Lt	Distance between Co-Lline&Po'-Amline
sagittal	Axial axis between left and right condyle	Distance between MDP-DDP and sagittal reference plane
sagittal	Intercondylar dystance	Distance between left and right condyle
sagittal	Coronal axis between left and right condyle	Axis between CoN-Co and HRP
Horizontal Reference Plan		The plane constructed by PoRt. - OrRt. - PoLt (Frankfort plane)
Sagittal Reference Plane (SRP)		The plane perpendicular to FH plane & passing through Na – Ba line (Midsagittal plane)
Coronal Reference Plane (CRP)		The plane perpendicular to FH plane and Midsagittal plane passing through Na (Na - perpendicular plane)

[Downloaded from wjps.ir on 2024-10-12]

[DOI: 10.52547/wjps.11.2.110]

Table 2: Radiographic Reference points

REFERENCE POINTS	DEFENITION
Na	THE MOST ANTERIOR POINT OF NASOFRONTAL SUTURE ON SAGITTAL PLANE
S	MIDPOINT OF THE FOSSA HYPOPHYSEALIS
Ba	THE MIDPOINT ON THE ANTERIOR BORDER OF THE FORAMEN MAGNUM
FRt./FLt	THE MOST SUPERIOR POINT OF THE (RIGHT/LEFT) GLENOID FOSSA
CoRt./CoLt.	THE MOST SUPERIOR POINT OF THE (RIGHT/LEFT) CONDYLE
LRt./LLt.	THE MOST POSTERIOR POINT ON ANTERIOR SURFACE OF (RIGHT/LEFT) CONDYLE
PoRt./PoLt	THE MOST SUPERIOR POINT OF THE (RIGHT/LEFT) EXTERNAL AUDITORY MEATUS
Po'Rt./Po'Lt	THE MOST INFERIOR POINT OF THE (RIGHT/LEFT) EXTERNAL AUDITORY MEATUS
AmRt./AmLt.	THE MOST INFERIOR POINT OF (RIGHT/LEFT) ARTICULAR EMINENCE
MDPRt./MDPLt	THE MOST MEDIAL POINT OF (RIGHT/LEFT) DISC POLE
DDPRt./DDPLt.	THE MOST DISTAL POINT OF (RIGHT/LEFT) DISC POLE
CoNRt./CoNLt	THE MID-POINT OF (RIGHT/LEFT) CONDYLAR NECK ON CORONAL VIEW
OrRt./OrLt	THE MOST INFERIOR POINT OF THE (RIGHT/LEFT) INFRAORBITAL MARGIN
DRt./DLt.	THE INTERSECTING POINT ON POSTERIOR SURFACE OF CONDYLE AND PO - AM LINE (RIGHT/LEFT)

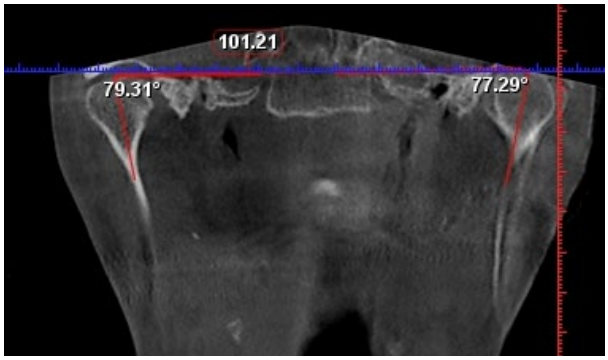

Figure 1: Coronal measurements

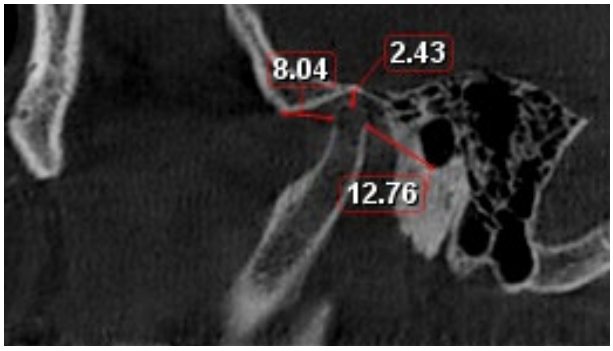

Figure 2: Measurements of the articular spaces

these variables, condylar inclination was evaluated which the angle of the longitudinal axis of the condyle with the line passing through the anterior and posterior articular ridges was measured (Figures 1, 2). All variables were measured by the same radiologist twice at two-week intervals. The evaluator was blind to all surgeries.

All data were subjected to statistical analysis using SPSS version 16 (SPSS Inc. Chicago, Illinois). *P*-value<0.05 was considered statistically significant.

Ethical Approval

All procedures performed in this study involving the human participant were in accordance with the ethical standards of our institutional research committee and with the 1964 Helsinki declaration. The patient's ethical consent form was signed and approved by the patient. All procedures used in this research were approved by the Ethical Committee of Mashhad University of Medical Sciences (Ethical code: IR.mums.sd.REC.1395.143).

[Downloaded from wjps.ir on 2024-10-12]

[DOI: 10.52547/wjps.11.2.110]

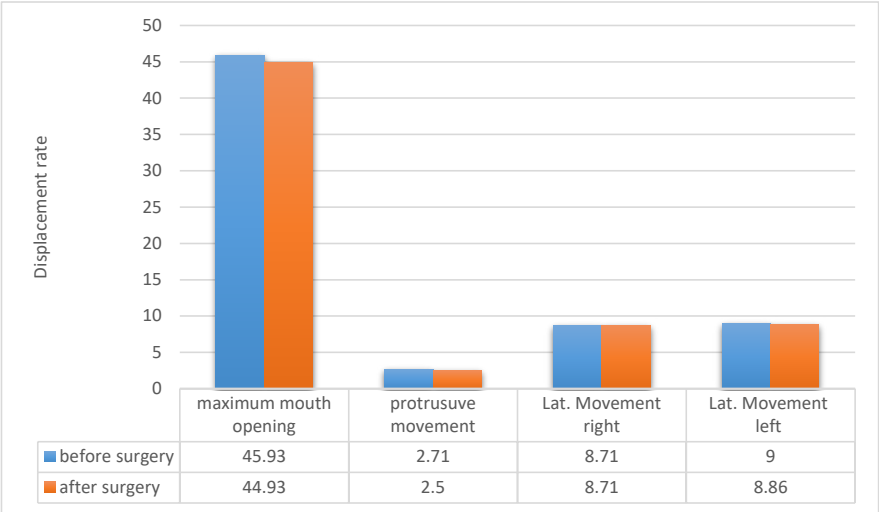

Figure 3: All clinical examination values changes after surgery

RESULTS

A total of 25 consecutive patients with a mean age of 23.2 ±2.7 years, were enrolled.

We noticed a bilateral decrease in the condyle axial angle and the condyle inclination after orthognathic surgery; however this reduction was not statistically significant. The coronal angle and the distance between the condyles increased on both sides, but this change was again statistically insignificant (P =0.021).

Although radiographic evaluation revealed that both anterior and posterior joint spaces on both sides had decreased following orthognathic surgery; only changes in the right posterior joint space were statistically significant. The upper joint space and sagittal angle of the right and left condyle did not demonstrate any statistically significant changes.

As illustrated in Figure 3, all postoperative MMO, protrusive movement and lateral extrusion values were less compared to the recorded preoperative values; however this reduction was not statistically significant.

TMD symptoms as in joint sounds and TMJ pain were identified in nineteen patients (76%) before undergoing surgery. In nine patients symptoms persisted for at least six months after surgery.

DISCUSSION

Despite its advantages in obtaining occlusion, esthetic and function, orthognathic surgery has been associated with some undesirable effects on the position of mandibular condyle relative to the temporal bone and also the position of the articular disc[3].

Bilateral Sagittal Split Osteotomy is one of the most frequently used methods for correcting mandibular prognathism. Many studies have investigated the potential impact of this surgery on the position of the condyle in the glenoid fossa and its effect on TMD symptoms[13-14].

The aim of this study was to evaluate the condylar angle changes in coronal, sagittal and axial plans six months after BSSO surgery in skeletal class III patients.

Owing to the lower exposure dose, CBCT is favored over CT scans for evaluating the TMJ structures. In contrast to lateral cephalometric radiography, CBCT yields it is possible to examine the condyle at all angles[15-16-17].

Our results revealed that condylar axial angle showed reduction after surgery, although it was not statistically significant but this might indicate that the condyle was slightly inward, which is in accordance with the findings of other studies[15-18]. In a study by Kim et al. patients were also examined radiographically with CBCT preoperatively and six months afterwards, stating that during this interval the condyle had slightly rotated inward. Nerveless, when another CBCT image was obtained 12 months postoperatively, they realized that the rotated condyle returned to its previous position[19].

A slight increase in the condylar coronal angle was observed in both left and right sides, but this change was not statistically significant, which is similar to

[Downloaded from wjps.ir on 2024-10-12]
[DOI: 10.52547/wjps.11.2.110]

the results of Choi et al. and Kim et al. studies. The coronal angle in initially slightly increased, but after 12 months this angle decreased significantly and the condyles rotated towards the midline[19].

The intercondylar distance increased slightly, but this amount was not statistically significant. In Kim et al. study, after three months, the distance between the two condyles had slightly decreased, but after 6 months, the condyles returned to their initial position[19].

In measurement of sagittal angle, the right condyle increased slightly and the left decreased slightly, but these changes were not statistically significant. In other studies, the sagittal angle of the condyle also decreased as a result to BSSO surgery[18-19-20-21].

We also measured condylar inclination, which is defined as the angle between the connection of the anterior and posterior point of the glenoid cavity and the longitudinal axis of the condyle. This angle confirms the results of previous studies on reducing the sagittal angle[20-22].

In a study, the sagittal angle of the condyle did not significantly change [23]. In that study, 28 skeletal class III patients who underwent BSSO and Lefort I surgery were evaluated, the condylar changes were examined using Torenes and Sund methods. Lateral cephalometry with open and closed mouth was used before surgery and six months after [23-24].

In the examination of joint spaces, the anterior joint space is reduced, which indicates the forward displacement of the disc and condyle. The results of other studies also suggest that the condyle moves forward in the joint space[6-19]. The results of Kim et al. study showed that the condyle remains in an anterior position 6 months after surgery and then returns to its previous position. The cause of this forward movement may be attributable to postoperative edema or hemarthrosis [19].

Chen et al. also assessed class II patients and showed that 43% of the condyles tended to move forward. In this study, Kamelchuk method and Pullinger - Hollender method were used to measure the articular spaces and anterior-posterior condyle relationship, respectively[25]. In Kamelchuk method, which is used to measure anterior, posterior and upper joint space, the most superior point of the glenoid fossa was drawn parallel to the FH plane, and from this point tangent lines were drawn to the most prominent condyle point on the anterior and posterior sides, and the vertical distance of these lines with the glenoid fossa was considered as posterior and anterior space. It includes the distance from the highest point of the condyle to the top of the glenoid fossa.

In the Pullinger-Hollender method, the ratio of posterior to anterior space is measured to determine the relationship between the condyle and the glenoid cavity. If this ratio is more than 0.25, the condyle in the anterior position is less than -0.25 in the posterior position and all values between the two are considered as the concentric position[25]. There was no statistically significant difference before and after surgery in the study of the upper joint space. Other studies also corroborate this finding[20-26].

In Yoon et al. study, the upper joint space on both sides significantly reduced immediately after the operation due to the use of an interocclusal splint to prevent relapse[7]. In Chen et al. study on class II patients, the condyle moved in a posterior and inferior direction immediately after surgery, followed by a superior and inferior movement after a 12-months postoperatively [25].

The position of the condyle depends on the thickness of the disc and the overlying soft tissue [20]. In Class III patients, the condyle is often anteriorly inclined and the glenoid cavity is wider and shallower, and the condyle is in a more superior position. In fact, there is a direct relationship between the shape of the condyle and its position in the cavity [20].

In clinical examinations; maximal mouth opening, lateral and protrusive movements reduced, but none of these reductions were statistically significant. Nineteen patients (76%) had TMD symptoms before surgery including joint sounds and pain. Nine patients continued to experience these symptoms after surgery.

In the Chen et al. study, similar to ours, the most common finding after orthognathic surgery was clicking[25]. In Ghang et al. study, 60% of patients also had these postoperative symptoms[26]. Long-term changes in TMJ sounds are due to improved occlusal, skeletal, and neuromuscular balance [23-26-27]. These observations indicate that a thorough preoperative TM examination is imperative. Moore et al. reported five cases of condylar resorption in patients undergoing orthognathic surgery, three of whom presented symptoms of TMJ dysfunction before surgery [28]. Ten cases of postoperative condylar resorption following orthognathic surgery were reported, all of which had preoperative dysfunction and in 6 of them this postoperative resorption continued [29]. The female gender, preoperative

[Downloaded from wjps.ir on 2024-10-12]

[DOI: 10.52547/wjps.11.2.110]

dysfunction and mandibular advancement surgery are among the predisposing factors for condylar resorption [30].

Suggestions and limitation

Since this study was carried out through a small population, it would be best if similar studies with a multicenter population were conducted across the country. Future studies would work best if a longer follow-up period was incorporated. Using magnetic resonance imaging (MRI) for evaluating the TMJ structures would also be of great diagnostic value and would be highly beneficial.

CONCLUSION

BSSO surgery in class III skeletal patients had no significant effect on the position of the condyle in the glenoid cavity as well as the symptoms of TMD.

ACKNOWLEDGEMENTS

The authors would like to appreciate the continued support of the Research Counselor of Mashhad University of Medical Sciences, Mashhad, Iran

FUNDING

None. This study was self-funded.

CONFLICT OF INTEREST

The authors have no conflict of interests to declare.

REFERENCES

1. Kobayashi T, Honma K, Izumi K, Hayashi T, Shingaki S, Nakajima T. Temporomandibular joint symptoms and disc displacement in patients with mandibular prognathism. *Br J Oral Maxillofac Surg* 1999;**37**(6):455-458.
2. Al-Belasy FA, Tozoglu S, Dolwick MF. Mandibular hypomobility after orthognathic surgery: a review article. *J Oral Maxillofac Surg* 2013;**71**(11):1967 e1-e11.
3. Hupp J, Ellis E, Tucker M. Contemporary oral and maxillofacial surgery. 5th ed. Missouri: Mosby; 2008; pp. 529-38 .
4. Firoozeai A, Momeni H, Shahnaseri S. Impact of orthognathic surgery on articular disc position in skeletal CL II patients. *JIDS* 2009;**4**(1):38-44.
5. Hupp JR TM, Ellis III E. Contemporary oral and maxillofacial surgery: Elsevier Health Sciences; 2013; pp. 529-38
6. Dujoncquoy JP, Ferri J, Raoul G, Kleinheinz J. Temporomandibular joint dysfunction and orthognathic surgery: A retrospective study. *Head Face Med* 2010;**6**(1):17-23.
7. Yoon SY, Song JM, Kim YD, Chung IK, Shin SH. Clinical changes of TMD and condyle stability after two aw surgery with and without preceding TMD treatments in class III patients. *Maxillofac Plast Reconstr Surg* 2015;**37**(1):9.
8. Okeson JP. Management of temporomandibular disorders and occlusion: Elsevier Health Sciences; 2014; pp.130-42.
9. Ueki K, Moroi A, Sotobori M, Ishihara Y, Marukawa K, Takatsuka S, et al. A hypothesis on the desired postoperative position of the condyle in orthognathic surgery: a review. *Oral Surg Oral Med Oral Pathol Oral Radiol* 2012;**114**(5):567-76.
10. White SC PM. Oral radiology: principles and interpretation: Elsevier Health Sciences; 2014;pp. 137-49.
11. Panetta D. Advances in X-ray detectors for clinical and preclinical Computed Tomography. *Nucl Instr Meth Phys Res* 2016;**809**:2-12.
12. Rhee CH, Choi YK, Kim YI, Kim SS, Park SB, Son WS. Correlation between skeletal and dental changes after mandibular setback surgery-first orthodontic treatment: Cone-beam computed tomography-generated half-cephalograms. *Korean J Orthod* 2014;**45**(2):59-65.
13. Eshghpour M SB, Shahakbari R, Mahvelati Shamsabadi R, Nejat AH. Complications of Bilateral Sagittal Split Osteotomy in Patients with Mandibular Prognathism. *JDMT* 2013 Dec 22;**3**(1):1-10.
14. Fang B, Shen GF, Yang C, Wu Y, Feng YM, Mao LX, et al. Changes in condylar and joint disc positions after bilateral sagittal split ramus osteotomy for correction of mandibular prognathism. *Int J Oral Maxillofac Surg* 2009;**38**(7):726-30.
15. Kim YI, Jung YH, Cho BH, Kim JR, Kim SS, Son WS, et al. The assessment of the short- and long-term changes in the condylar position following sagittal split ramus osteotomy (SSRO) with rigid fixation. *J Oral Rehabil* 2010;**37**(4):262-70.
16. Gaggl A, Schultes G, Santler G, Karcher H, Simbrunner J. Clinical and magnetic resonance findings in the temporomandibular joints of patients before and after orthognathic surgery. *Br J Oral Maxillofac Surg* 1999;**37**(1):41-5.
17. Rubin MS, Clouston S, Ahmed MM, K ML, Shetye PR, Broder HL, et al. Assessment of presurgical clefts and predicted surgical outcome in patients treated with and without nasoalveolar molding. *J Craniofac Surg* 2015;**26**(1):71-5.

[Downloaded from wjps.ir on 2024-10-12]

[DOI: 10.52547/wjps.11.2.110]

18. Choi BJ, Choi YH, Lee BS, Kwon YD, Choo YJ, Ohe JY. A CBCT study on positional change in mandibular condyle according to metallic anchorage methods in skeletal class III patients after orthognatic surgery. *J Craniomaxillofac Surg* 2014;**42**(8):1617-22.
19. Kim YJ, Lee Y, Chun YS, Kang N, Kim SJ, Kim M. Condylar positional changes up to 12 months after bimaxillary surgery for skeletal class III malocclusions. *J Oral Maxillofac Surg* 2014;**72**(1):145-56.
20. Ueki K, Moroi A, Sotobori M, Ishihara Y, Marukawa K, Yoshizawa K, et al. Changes in temporomandibular joint and ramus after sagittal split ramus osteotomy in mandibular prognathism patients with and without asymmetry. *J Craniomaxillofac Surg* 2012;**40**(8):821-7.
21. Ueki K, Nakagawa K, Marukawa K, Yamamoto E, Takeuchi N. Stress change on the temporomandibular joint in mandibular prognathism subjects with asymmetry after orthognathic surgery. *Eur J Orthod* 2010;**32**(5):522-529.
22. Freihofer HP, Jr., Petresevic D. Late results after advancing the mandible by sagittal splitting of the rami. *J Maxillofac Surg* 1975;**3**(4):250-7.
23. Hu J, Wang D, Zou S. Effects of mandibular setback on the temporomandibular joint: a comparison of oblique and sagittal split ramus osteotomy. *J Oral Maxillofac Surg* 2000;**58**(4):375-80; discussion 380-1.
24. Will LA, Joondeph DR, Hohl TH, West RA. Condylar position following mandibular advancement: its relationship to relapse. *J Oral Maxillofac Surg* 1984;**42**(9):578-88.
25. Chen S, Lei J, Wang X, Fu KY, Farzad P, Yi B. Short- and long-term changes of condylar position after bilateral sagittal split ramus osteotomy for mandibular advancement in combination with Le Fort I osteotomy evaluated by cone-beam computed tomography. *J Oral Maxillofac Surg* 2013;**71**(11):1956-66.
26. Ghang MH, Kim HM, You JY, Kim BH, Choi JP, Kim SH, et al. Three-dimensional mandibular change after sagittal split ramus osteotomy with a semirigid sliding plate system for fixation of a mandibular setback surgery. *Oral Surg Oral Med Oral Pathol Oral Radiol* 2013;**115**(2):157-66.
27. Shaban B, Eshghpour M, Yaghoobi M, Shahriar F, Esmaeili H. Evaluation of Maximum Mouth Opening after Bilateral Sagittal Split Osteotomy in Patients with Mandibular Prognathism. *JDMT* 2011;**35**(1):43-50.
28. Moore KE, Gooris PJ, Stoelinga PJ. The contributing role of condylar resorption to skeletal relapse following mandibular advancement surgery: report of five cases. *J Oral Maxillofac Surg* 1991;**49**(5):448-60.
29. Arnett GW, Tomborello J. Progressive class II development: female idiopathic condylar resorption. *Oral Maxillofac Surg Clin North Am* 1990 Nov;**2**:699-716.
30. Wolford LM, Reiche-Fischel O, Mehra P. Changes in temporomandibular joint dysfunction after orthognathic surgery. *J Oral Maxillofac Surg* 2003;**61**(6):655-660.

[Downloaded from wjps.ir on 2024-10-12]

[DOI: 10.52547/wjps.11.2.110]