

# Successful Closure of an Oro-Antral Communication, after Three Previously Failed Attempts, Using Bichat Fat Pad Flap: A Case Report

Despina Luciana Bereczki-Temistocle<sup>1,2</sup>, Simona Gurzu<sup>3</sup>, Ioan Jung<sup>3</sup>, Golu Mihai Vlad<sup>1,2</sup>, Gabriela Beresescu<sup>4</sup>, Alina Ormenisan<sup>1</sup>

1. Department of Oral and Maxillo-Facial Surgery, George Emil Palade University of Medicine, Pharmacy, Science, and Technology of Targu Mures, 540142 Targu Mures, Romania
2. IOSUD "G. E. Palade" University of Medicine, Pharmacy, Science, and Technology of Targu Mures, 540142 Targu Mures, Romania
3. Department of Morphopathology George Emil Palade University of Medicine, Pharmacy, Science, and Technology of Targu Mures, 540142 Targu Mures, Romania
4. Department of Tooth and Arch Morphology, George Emil Palade University of Medicine, Pharmacy, Science and Technology of Targu Mures, 540142 Targu Mures, Romania

## ABSTRACT

An oro-antral communication represents an abnormal connection between the oral cavity and the maxillary sinus. It occurs most often after tooth extractions, improper implant placement or incorrect management of the sinus lifts. Surgical repair is challenging and most practitioners usually choose the buccal advancement flap, the palatal flap and in some cases the buccal fat pad flap to close the defect. We present a 43 year-old female of a large oro-antral communication and associated chronic sinusitis which was successfully managed by surgery. Previous interventions including 2 buccal advancement flaps, and a double layer closure using Collagen membrane and buccal advancement flap were unsuccessful. The stepwise intervention consisted on the complete cleaning of the sinus, using the Caldwell Luc technique, followed by the closure of the oro-antral communication using Bichat fat pad flap. The particular aspect was the proper integration of the buccal fat pad flap, after 3 failed attempts, without dehiscence or any other complications. The buccal fat pad flap can be successfully used for closure of large oro-antral communications, even when previous methods have failed and local tissue is of poor quality.

## KEYWORDS

Oro-antral communication; Buccal fat pad; Bichat; Surgery

## Please cite this paper as:

Bereczki-Temistocle DL., Gurzu S., Jung I., Mihai Vlad G., Beresescu G., Ormenisan A. Successful Closure of an Oro-Antral Communication, after Three Previously Failed Attempts, Using Bichat Fat Pad Flap: A Case Report. *World J Plast Surg.* 2023;12(1):90-94.  
doi: 10.52547/wjps.12.1.90

## \*Corresponding Author:

Mihai Vlad Golu- MD,

IOSUD George Emil Palade University of Medicine, Pharmacy, Science, and Technology of Targu Mures, Romania

Gheorghe Marinescu str., No 38  
540142 Targu Mures, Romania

Tel.: +40 752069085

Email: [vlad.golu@umfst.ro](mailto:vlad.golu@umfst.ro)

Received: 01/08/2023

Accepted: 30/04/2023

## INTRODUCTION

An Oro-antral communication is defined as the permanent abnormal connection between the oral cavity and the maxillary sinus. It is mostly iatrogenically induced by interventions upon the lateral maxilla, like tooth extractions (especially upper molars and premolars), inappropriate implant placement, improper management of sinus lifts, trauma, fractures of the tuberosity, etc. <sup>1</sup>. Untreated, the oro-antral communications can induce complications such as sinusitis and chronic oro-antral fistula <sup>1</sup>.

The treatment of oro-antral communication is struggling and includes antibiotic therapy and surgical interventions aimed to ensure a proper drainage of the maxillary sinus and elimination of the pathological tissue



This work is licensed under a Creative Commons Attribution-NonCommercial 4.0 International license (<https://creativecommons.org/licenses/by-nc/4.0/>). Non-commercial uses of the work are permitted, provided the original work is properly cited.

and closure of the defect<sup>2</sup>. The most common grafts, used for this closure, are the buccal flaps and palatal flaps<sup>3</sup>.

In this paper, we present the successful surgical closure of an oro-antral communication using the buccal fat pad in a case with multiple failed surgical attempts which also influenced the quality of the oral mucosa surrounding the defect.

This encapsulated fatty tissue is located within the cheek and includes a main body and four extensions: buccal, temporal, pterygoid and pterygopalatine. The average volume is 9.6 ml and is known to remain constant regardless of age and gender. It has a rich blood supply, being irrigated by the three arteries of the subcapsular plexus: maxillary, superficial temporal and facial artery. The role of the buccal fat pad is to ensure the protection of the neurovascular bundles and ensure intermuscular movement<sup>4</sup>.

In the following case, we also proved that this pedicled fat pad flap can be used in cases where previous closure methods, even modern solutions, have failed.

## CASE PRESENTATION

The patient benefited from surgical treatment at the Oral and Maxillo-Facial Institute of Targu Mures, Romania and gave the signed consent for using data and pictures in scientific publications, with respect to confidentiality. The case study was conducted according to the guidelines of the Declaration of Helsinki and approved by the Ethics Committee of the George Emil Palade University of Medicine, Pharmacy, Sciences, and Technologies of Targu Mures, Romania and by the Emergency County Hospital of Targu Mures (approval number 32647/13.12.2018; 1777/10.06.2022).

A 43 year-old female was admitted with a large left oro-antral communication. At the time of the admission, she reported persistent pressure in the left maxillo-malar area, nasal regurgitation of fluids, whistling sound during phonation and oral secretion discharge at the site of the defect.

The personal medical history included hypothyroidism (treated with Euthyrox) and chronic asthma. Because of the loss of the lateral teeth, the patient had undergone several surgical interventions which started approximately 1 year ago. They included sinus lift, implant placement and bone augmentation. After these improper

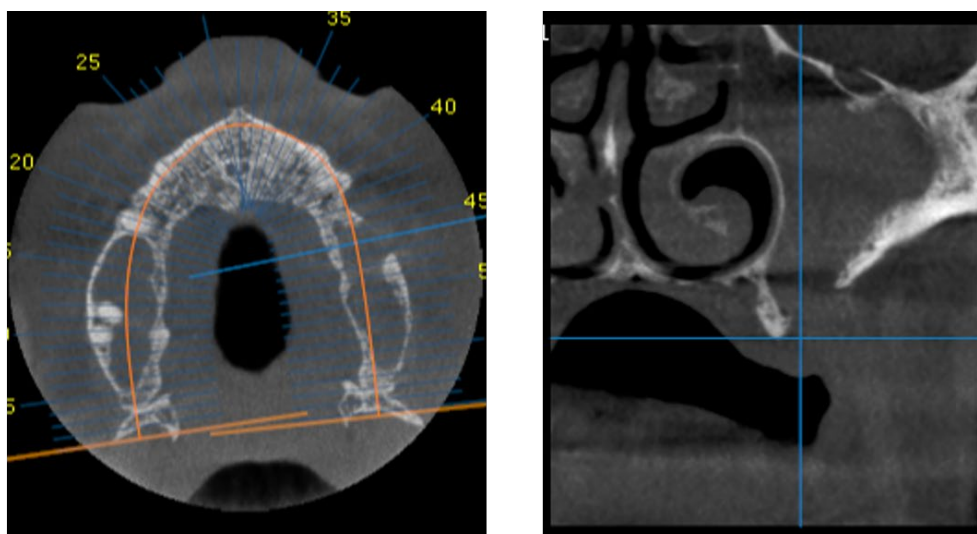
performed procedures, because of the failed bone augmentation and the placement of the implants inside the sinus cavity, she developed an oro-antral communication which was surgically treated after removing the unintergrated implants corresponding to 25 and 26, two times using buccal advancement flaps (two months apart). After another 2 months, check-up revealed that the oro-antral fistula persisted and the buccal area was compromised because of the scarring and poor blood supply. The defect was surgically treated a third time, after sinus irrigation with antibiotic solutions, using Collagen membrane and the poor quality buccal flap as a second layer, unfortunately without success.

At the time of the admission, local examination showed slight erythema of the gingival mucosa, corresponding to the lateral region and two fistulous orifices on the buccal mucosa, adjacent teeth region 2.5/2.6, surrounded by granulation tissue. Probing of the fistulas presented a large bone defect communicating with the left paranasal sinus. The Cone beam computerised tomography (CBCT) image confirms the clinical aspect, showing a considerable oro-antral defect (Fig. 1).

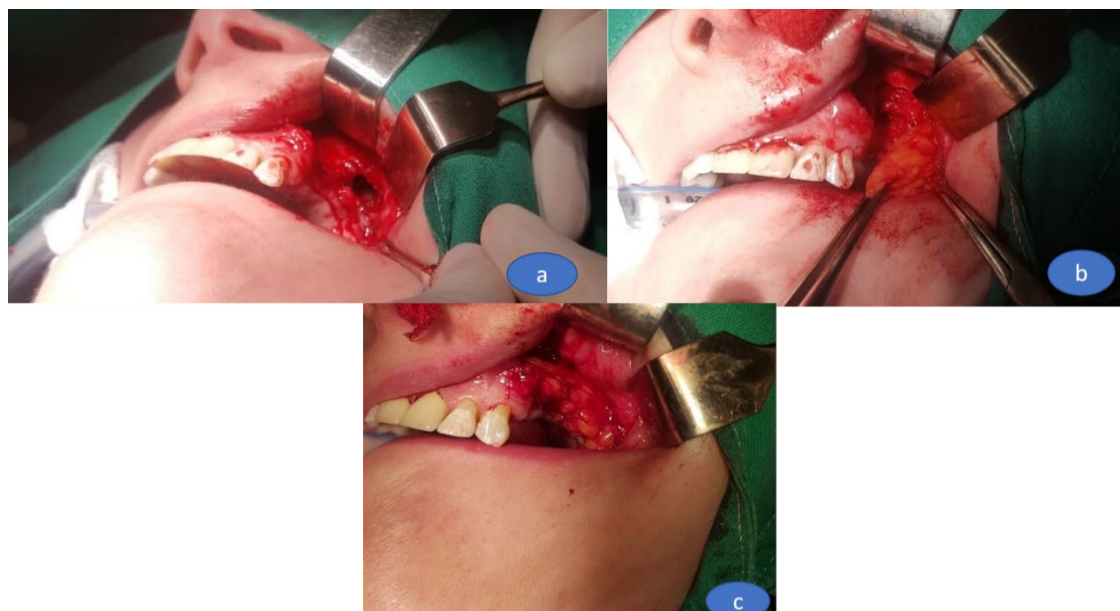Considering the chronic evolution of the oro-antral communication and the patient's symptoms, surgical treatment required radical antrostomy, Caldwell Luc technique and closure of the oro-antral communication under general anesthesia. Based on the experience of the surgical team, we decided to use the autologous pedicled buccal fat pad flap.

Intraoperative a trapezoidal buccal flap was raised continued with an anterior horizontal incision in the mobile mucosa. A large communication of approximately 1.5 cm was found. It included large amounts of granulation tissue and sinus polyps (Fig. 2.a). A thorough cleaning of the sinus was performed, using the bony defect for access. After assuring a proper drainage of the sinus, a small incision in the posterior region of the periosteum of the flap was done, and blunt dissection determined the herniation of the Bichat fat pad. (Fig. 2.b) The buccal fat pad flap was gently pulled with a haemostatic forceps and sutured to the palatal flap margins (Fig. 2.c). The friable buccal flap was also sutured on top, but in an apical position in order to avoid affecting the depth of the vestibule creating partial coverage of the Bichat fat pad flap.

Postoperative profilactic antibiotic therapy was



**Figure 1:** CT aspect of the left oro-antral communication



**Figure 2:** Intraoperative aspect of the oro-antral communication. Visualization and suture of the Bichat fat pad flap

prescribed and daily hygiene of the oral wound was performed. No local or general complications occurred and local healing was optimal without any inflammation or dehiscencies, with complete epithelization of the buccal fat pad flap.

## DISCUSSION

Odontogenic sinusitis is favored especially by the anatomical conformation of the floor of the antral cavity. Usually, there is a thin layer of compact bone that separates the sinus cavity from the roots of the molars and premolars, but in some cases the

dimensions of the bone are neglectable, or the bone is completely absent. In these cases, a thin layer of periosteum can be identified. In such patients, during teeth extractions, or other surgical procedures in the oral cavity, the sinuses can be perforated, creating the oro-antral communication<sup>5</sup>.

Chronic oro-sinusal communications evolve into an oro-antral fistula which is an epithelialized path that assures constant oral contamination of the maxillary sinus. Even though oro-antral communication is considered a possible accident of tooth extraction or oral surgery such as sinus lift, implant placement, it should be considered a surgical emergency. If

surgery is not done in time acute sinusitis, with ethmoiditis and direct spreading of the infection to the orbit and even passing of the blood-brain barrier is possible <sup>6</sup>.

A minimal perforation,  $\leq 2\text{mm}$ , in the absence of a previous sinus injury, may subside spontaneously. Larger defects will require surgical closure <sup>7</sup> which is mainly done using buccal or palatal flaps that are advanced and rotated to seal the wound <sup>1</sup>. In the cases presented by our team, the irreversible injury of the affected sinus, which was induced by the oro-antral communication/fistula, asked for extensive surgery <sup>8</sup>.

The buccal advancement flap, which was used in this case to partially cover the buccal fat pad flap, is created by placing a horizontal incision in the gingival sulcus and two divergent buccal vertical incisions, obtaining a trapezoidal flap. In most of the cases periosteal scoring is necessary to mobilize the flap <sup>9</sup>. It is a simple and quick technique, with sufficient intraoperative blood supply. The disadvantages include a reduced vestibule and, in case of larger defects, wound dehiscence. Also, a constant traction exercised on the flap during mastication and phonation, which may affect the healing process <sup>10</sup>. For this reason, an experienced surgeon is required to perform such interventions. Palatal advanced and rotated flap is another surgical option. A full thickness flap that contains the palatal artery is a good option to close a oro-antral communication, but the main disadvantage is the limited mobility of the flap. It forces the surgeon to create a large palatal defect with further extensive scarring process <sup>11</sup>.

Regarding the type of grafts used for closure of antral-communications, the advantages of using the buccal fat pad for closure of the oro-antral communications are represented by its accessibility, rich blood supply and capacity of dedifferentiation in a short period of time after surgery <sup>4</sup>. Some studies state that there is no significant difference between using a simple buccal flap or a buccal fat pad flap <sup>12</sup>. However, few surgeons concentrated on the surgical results of using these autografts, in comparison with others. Thus, there are no relevant conclusions about the best outcome <sup>12</sup>. In a recent published study, Gheisari R et al. Showed that, for defects larger than 5 mm, best surgical option might be the buccal fat pad flap <sup>13</sup>.

Even though buccal advancement flaps are the

first option chosen for the closure of oro-antral communications, these are most likely to present dehiscencies and most often require a second intervention in order to create an adequate depth of the vestibule <sup>14</sup>.

Several factors have to be taken into consideration when choosing the best treatment option, the most important being the size of the defect, the associated general conditions and the quality of the local tissue. Recent studies underline that in case of large oro-antral defects and immunocompromised patients, the Bichat fat pad flap is the best flap. This fatty tissue has an excellent blood supply and it can be used even if local conditions, such as after radiotherapy, are not favorable <sup>15</sup>.

Other recent case reports state that collagen membranes are appropriate for the successful surgical closure of oro-antral communications <sup>16</sup>, but in our case, this graft was not a viable option.

The original part of this paper consists of the fact that after three unsuccessful attempts to close the oro-antral communication with buccal advancement flaps, but also with collagen membrane, the buccal fat pad flap proved to assure an optimal and functional result. We resorted to the buccal fat pad flap, which proved a remarkable capacity for metaplasia and confirm that, in such cases, the fat cells from the Bichat fat pad act as stem cells and when appropriate stimuli are applied they can be dedifferentiated in other types of tissue and can assure a proper epithelization <sup>17</sup>.

## CONCLUSION

Large oro-antral communication is a surgical emergency that requires a complex medical and surgical treatment. A precise method of closing a large complicated oro-sinusal communication can be obtained by using the Bichat fat pad flap, a tissue with good regeneration properties, even in cases with previous unsuccessful outcomes and poor local quality tissue.

## ACKNOWLEDGMENTS

No funding or financial support was received.

## CONFLICT OF INTEREST

None declared



## REFERENCES

- Kim SM. Definition and management of odontogenic maxillary sinusitis. *Maxillofac Plast Reconstr Surg* 2019 Mar 29;**41**(1):13. doi: 10.1186/s40902-019-0196-2. PMID: 30989083; PMCID: PMC6439010.
- Shukla B, Singh G, Mishra M, Das G, Singh A. Closure of oroantral fistula: Comparison between buccal fat pad and buccal advancement flap: A clinical study. *Natl J Maxillofac Surg* 2021 Sep-Dec;**12**(3):404-409. doi: 10.4103/njms.njms\_323\_21. Epub 2021 Dec 13. PMID: 35153439; PMCID: PMC8820317.
- Khandelwal P, Hajira N. Management of Oro-antral Communication and Fistula: Various Surgical Options. *World J Plast Surg* 2017 Jan;**6**(1):3-8. PMID: 28289607; PMCID: PMC5339603.
- Hassani A, Shahmirzadi S, Saadat S. Applications of the Buccal Fat Pad in Oral and Maxillofacial Surgery [Internet]. A Textbook of Advanced Oral and Maxillofacial Surgery Volume 3. InTech; 2016. Available from: <http://dx.doi.org/10.5772/63133>
- Iwanaga J, Wilson C, Lachkar S, Tomaszewski KA, Walocha JA, Tubbs RS. Clinical anatomy of the maxillary sinus: application to sinus floor augmentation. *Anat Cell Biol* 2019 Mar;**52**(1):17-24. doi: 10.5115/acb.2019.52.1.17. Epub 2019 Mar 29. PMID: 30984447; PMCID: PMC6449588.
- Chang YS, Chen PL, Hung JH, Chen HY, Lai CC, Ou CY, Chang CM, Wang CK, Cheng HC, Tseng SH. Orbital complications of paranasal sinusitis in Taiwan, 1988 through 2015: Acute ophthalmological manifestations, diagnosis, and management. *PLoS One* 2017 Oct 3;**12**(10):e0184477. doi: 10.1371/journal.pone.0184477. PMID: 28972988; PMCID: PMC5626037.
- Bravo Cordero G, Minzer Ferrer S, Fernández L. Odontogenic sinusitis, oro-antral fistula and surgical repair by Bichat's fat pad: Literature review. *Acta Otorrinolaringol Esp* 2016 Mar-Apr;**67**(2):107-13. English, Spanish. doi: 10.1016/j.otorri.2015.03.001. Epub 2015 Oct 17. PMID: 26481975
- Belmehti A, El Harti K. Management of oroantral communication using buccal advanced flap. *Pan Afr Med J* 2019 Oct 3;**34**:69. doi: 10.11604/pamj.2019.34.69.19959. PMID: 31819785; PMCID: PMC6884724.
- Kwon MS, Lee BS, Choi BJ, Lee JW, Ohe JY, Jung JH, Hwang BY, Kwon YD. Closure of oroantral fistula: a review of local flap techniques. *J Korean Assoc Oral Maxillofac Surg* 2020 Feb;**46**(1):58-65. doi: 10.5125/jkaoms.2020.46.1.58. Epub 2020 Feb 26. PMID: 32158682; PMCID: PMC7049762.
- Patel R, Patel P, Kalariya V, Patel H, Chavda C. Closure of Oro-Antral Communication Using Buccal Advancement Flap. *World J Plast Surg* 2019 May;**8**(2):262-264. doi: 10.29252/wjps.8.2.262. PMID: 31309067; PMCID: PMC6620811.
- Sakakibara A, Furudoi S, Sakakibara S, Kaji M, Shigeta T, Matsui T, Minamikawa T, Komori T. Tunnel Technique for the Closure of an Oroantral Fistula with a Pedicled Palatal Mucoperiosteal Flap. *J Maxillofac Oral Surg* 2015 Sep;**14**(3):868-74. doi: 10.1007/s12663-014-0703-z. Epub 2014 Oct 7. PMID: 26225093; PMCID: PMC4510092.
- Kiran Kumar Krishanappa S, Eachempati P, Kumbargere Nagraj S, Shetty NY, Moe S, Aggarwal H, Mathew RJ. Interventions for treating oro-antral communications and fistulae due to dental procedures. *Cochrane Database Syst Rev* 2018 Aug 16;**8**(8):CD011784. doi: 10.1002/14651858.CD011784.pub3. PMID: 30113083; PMCID: PMC6513579.
- Gheisari R, Hosein Zadeh H, Tavanafar S. Oro-Antral Fistula Repair With Different Surgical Methods: a Retrospective Analysis of 147 Cases. *J Dent (Shiraz)* 2019 Jun;**20**(2):107-112. doi: 10.30476/DENTJODS.2019.44920. PMID: 31214638; PMCID: PMC6538900.
- Azzouzi A, Hallab L, Chbicheb S. Diagnosis and Management of oro-antral fistula: Case series and review. *Int J Surg Case Rep* 2022 Aug;**97**:107436. doi: 10.1016/j.ijscr.2022.107436. Epub 2022 Jul 21. PMID: 35917603; PMCID: PMC9403197.
- Bereczki-Temistocle DL, Gurzu S, Jung I, Cosarca A, Beresescu G, Golu V, Petrovan C, Ormenisan A. Selecting the Best Surgical Treatment Methods in Oro-Antral Communications. *Int J Environ Res Public Health* 2022 Nov 5;**19**(21):14543. doi: 10.3390/ijerph192114543. PMID: 36361422; PMCID: PMC9658250.
- Baek JH, Kim BO, Lee WP. Implant Placement after Closure of Oroantral Communication by Sinus Bone Graft Using a Collagen Barrier Membrane in the Shape of a Pouch: A Case Report and Review of the Literature. *Medicina (Kaunas)* 2021 Jun 16;**57**(6):626. doi: 10.3390/medicina57060626. PMID: 34208644; PMCID: PMC8235364.
- Conti G, Bertossi D, Dai Prè E, Cavallini C, Scupoli MT, Ricciardi G, Parnigotto P, Saban Y, Sbarbati A, Nocini P. Regenerative potential of the Bichat fat pad determined by the quantification of multilineage differentiating stress enduring cells. *Eur J Histochem* 2018 Oct 23;**62**(4):2900. doi: 10.4081/ejh.2018.2900. PMID: 30362673; PMCID: PMC6250101.