

A Giant Frontal Sinus Mucocele in an Opium Addict Patient: A Case Report

Gholamreza Motazedian¹, Elnaz Koushki², Mehryar Nahaei³
Fateme Salari⁴, Hamid Reihani², Ebtesam Jabbari⁵, Alireza Keshtkar^{2*}

1. Burn and Wound Healing Research Centre, Plastic and Reconstructive Surgery Ward, Shiraz University of Medical Sciences, Shiraz, Iran
2. Student Research Committee, School of Medicine, Shiraz University of Medical Sciences, Shiraz, Iran
3. Department of Plastic Surgery, Shiraz University of Medical Sciences, Shiraz, Iran
4. Trauma Research Center, Shahid Rajaei (Emtiaz) Trauma Hospital, Shiraz University of Medical Sciences, Shiraz, Iran
5. School of Dentistry, Shiraz University of Medical Sciences, Shiraz, Iran

*Corresponding Author:

Alireza Keshtkar

Student Research Committee,
School of Medicine, Shiraz
University of Medical Sciences,
Shiraz, Iran

Tel.: +989177074339

Email: alireza.keshtkar.med@gmail.com

Received: 2023/02/08

Accepted: 2023/07/15

ABSTRACT

Mucocele is a benign soft tissue mass that could occur in all accessory glands. Mucocele can also occur in paranasal sinuses. It is mostly placed in the frontal sinus and barely grows larger than 1.5 centimeters(cm). Based on the affected site, it could cause facial pain and headache. Analgesics like opioids could relieve and potentially make patients ignore the headache and cause giant frontal mucocele.

This article discusses a patient with giant frontal sinus mucocele (7×8×8 cm) and opium addiction that presented with severe and intolerable pain. A 32 yr old man came to Rajaei Trauma Hospital, Shiraz, Iran with a severe headache and a large swelling of the face frontal region that developed gradually. In physical examination, the mass was non-tender, non-pulsatile, and free from the overlying normal skin. Computed tomography (CT) scan and magnetic resonance imaging (MRI) demonstrated a frontal sinus mucocele. The operation was planned, and the patient was discharged after two days. Subsequently, the 6-month follow-up of the patient was normal.

Two different hypotheses are declared in this article. First, the potential role of opium addiction as a risk factor for giant mucoceles was noted, then the analgesic non-responsiveness of sinus mucoceles was described. The latter hypothesis is more likely. So, we should consider that if the patient had an analgesic-resistant headache, one differential diagnosis could be sinus mucocele. Moreover, the possible psychological effect of addiction on discounting face beauty was acknowledged.

KEYWORDS

Frontal sinus; Mucocele; Opium dependence; Drug resistance; Case report

Please cite this paper as:

Motazedian G., Koushki E., Nahaei E., Salari F., Reihani H., Jabbari E., Keshtkar A. A Giant Frontal Sinus Mucocele in an Opium Addict Patient: A Case Report. *World J Plast Surg.* 2021;12(2):107-111.
doi: 10.52547/wjps.12.2.107

INTRODUCTION

Mucocele is a benign soft tissue mass that could occur in all accessory glands. Mucocele can also occur in paranasal sinuses. It is mostly placed in the frontal sinus, and by fewer chances, it occurs in the ethmoid, sphenoid, and maxillary sinus. Mucoceles are mainly positioned superficially and scarcely grow larger than 1.5 cm^{1,2}. Causes of mucoceles could be classified into two categories: post-traumatic and post-inflammatory. Based on the affected site, it could cause facial pain, nasal obstruction,

ophthalmological complications, headache, swelling, and fever in the case of infection ³.

Opium is a brown substance that includes alkaloids such as morphine, codeine, tramadol, methadone, and heroin which can be used orally, intravenously, or smoked ⁴. These are analgesic opioids that affect the μ receptor and increase the pain threshold. Furthermore, methadone by itself prevents pain transmission due to its antagonistic effects on glutamatergic NMDA receptors ⁵.

In this case study, we discuss a patient with giant frontal mucocele and opium addiction that came with a severe headache that is in contrast with his opium abuse.

CASE REPORT

Ethics approval and consent to participate

Our study has been reviewed and approved by the Medical Ethics Committee of Shiraz University of Medical Sciences. Written informed consent was obtained from the patient to publish this Case report.

A 32-year-old male came to Rajaei Trauma Hospital, Shiraz, Iran with a severe headache and a significant swelling in the frontal region of the head on March 2022. The headache started as a minor swelling above the eyebrows five months earlier. The patient had a history of old forehead trauma, surgery, and reconstruction with bone cement at that site about ten years ago. The mass slowly and gradually increased in size, causing huge bulging, giving the

appearance of a giant neoplasm. The patient had a history of smoking and addiction.

Physical examination of the patient on admission revealed no abnormalities. On neurological examination, his visual acuity was normal in both eyes. Local examination revealed a swelling in the forehead region that was non-tender, non-pulsatile, and free from the overlying normal skin. There was no ulceration or discharging sinus. Hematological and biochemical parameters were normal (WBC: 7500 per microliter, Hb:12.1 mg/dl). Computed Tomography (CT) scan of the brain revealed a 7×8 cm mass in the maximal transverse dimensions in the frontal sinus with homogeneous contents and expansion and thinning of its bony wall without cortical destruction or extension into the adjacent brain tissue. The contents inside the lesion were homogeneous, with intermediate attenuation on CT. After contrast administration, peripheral enhancement of the lesion was noted, with no enhancement of the contents and no evidence of vascularity. The appearance is typically consistent with fluid contents (Figure 1). MRI showed high signal contents filling the swelling that revealed peripheral enhancement after contrast administration. The lesion was observed to have no connection with the brain tissues, and there was thinning of the bony wall of the sinus without bone destruction. The findings were consistent with a typical case of frontal mucocele (Figure 2).

The surgery was planned. A previous forehead scar was chose for incision, and the mucocele (7×8×8

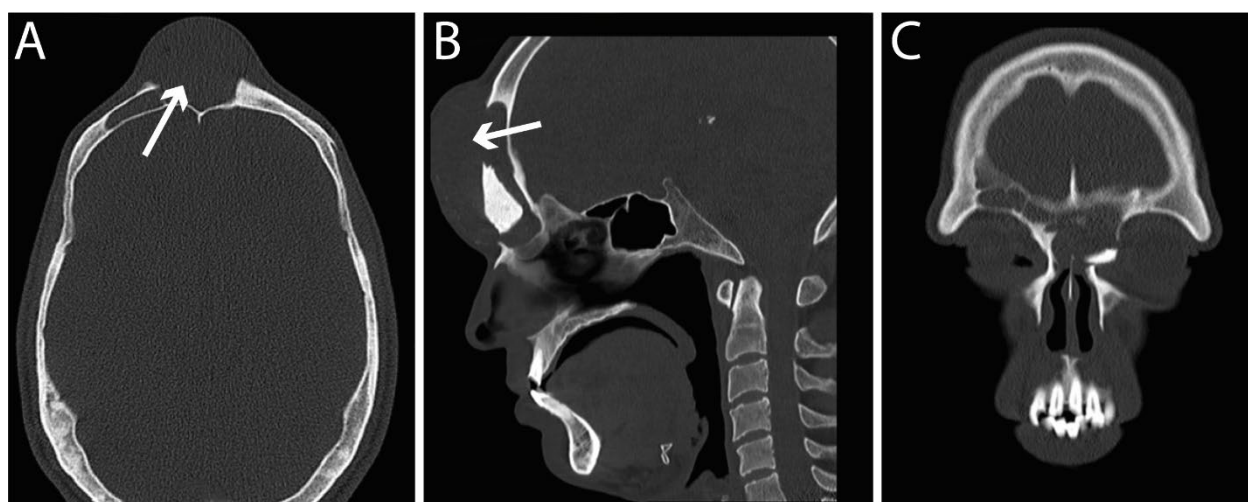


Figure 1: A 7×8 cm mass in the maximal transverse dimensions in the frontal sinus with homogeneous contents and expansion and thinning of its bony wall without cortical destruction or extension into the adjacent brain tissue

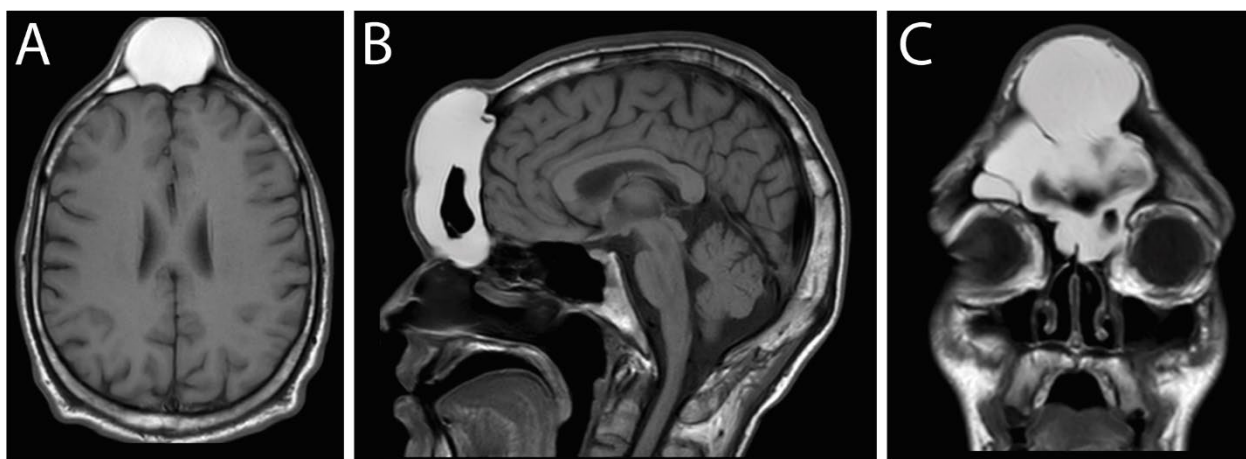


Figure 2: High signal contents filling the swelling that revealed peripheral enhancement after Contrast administration. The lesion was observed to have no connection with the brain tissues, and there was thinning of the bony wall of the sinus without bone destruction

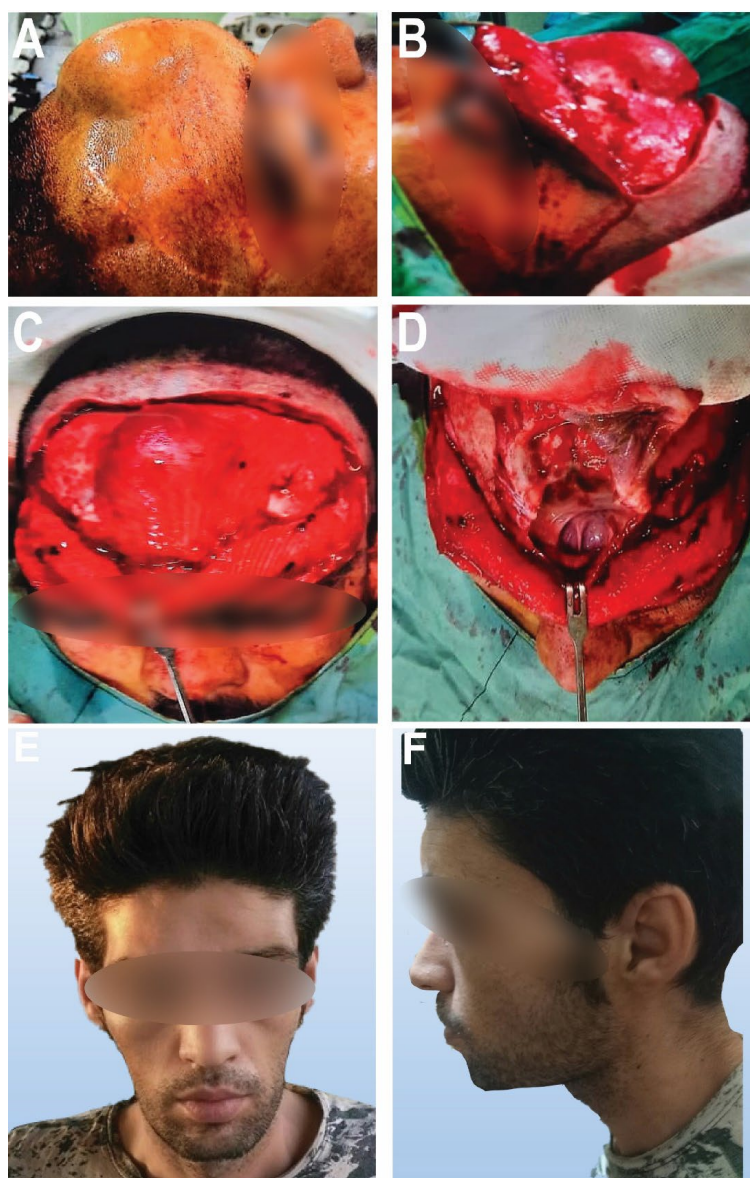


Figure 3: Operation figures and 6 months follow-up pictures of the patient

cm) as well as the bone cement were completely excised and removed from the frontal sinus. Mucosa about 150 ccs of thick pus were drained. Due to the extension of the mucocoele to the nasal cavity, opening the nasal cavity was done bilaterally. The defect was covered with titanium mesh. Pedicled galea flap (40 cm²) was prepared, and the cavity was filled with a general flap. The postoperative period was satisfactory, and the patient was discharged after two days with good cosmetic results. Subsequently, the 6-month follow-up of the patient was normal (Figure 3).

DISCUSSION

Mucocoele is a mucus assortment which enfolded with a pouch of epithelium sinus liner. It is a slow-growing and benign tumor that usually takes place in the frontal sinus ⁶. It can invade the orbit or intracranial compartment by the bony area and cause retro-orbital pain or headache ⁷.

In line with our study, Bosmans et al. investigated giant frontal and paranasal mucocoeles in a case report and review of the Literature. In their study, the largest mucocoele was 10×9 cm ¹. Therefore, considering the size of our patient's mucocoele (7×8×8 cm), it could be one of the biggest mucocoeles in recent years.

On the other hand, to the best of our knowledge, pain is one of the most critical signs that push the patient to see a doctor and start treatment ⁸. In several cases, pain prevents the progress of diseases and further irreversible damage. Opium consumption which has been seen predominantly in low socio-economic patients ⁹, suppresses that effect of pain due to its analgesic effects ¹⁰. Therefore, opioid abuse could consider a risk factor for giant frontal mucocoele. Hence, we recommend more frequent follow-up of opium addict patients after surgeries and informing their families about probable mucocoele formation to prevent irreversible complications.

An interesting point about this case was that he was a young man that presented to our hospital with the chief complaint of severe pain even though he had a huge mass in his frontal area. It may be because of his opium addiction that he did not pay that much attention to his facial beauty and did not seek help when the mass was smaller and painless. In another view, a different hypothesis could be possible. Maybe, some of sinus mucocoeles could cause a

pain that is opioid non-responsive. Few articles support this hypothesis. For instance, Zakaria et al.¹¹ reported an ethmoido-orbital mucocoele with analgesic resistance. Moreover, Bouhafas et al.¹² reported an analgesic-resistant frontal mucocoele, and Bola et al.¹³ described a sinus mucocoele that was analgesic resistant. According to current evidence, the latter hypothesis is more probable.

CONCLUSION

Two different hypotheses are declared in this article. First, the potential role of opium addiction as a risk factor for giant mucocoeles was stated, and then the analgesic non-responsiveness of sinus mucocoeles was detailed. The latter hypothesis is more likely. Consequently, we should consider that if the patient had an analgesic-resistant headache, one differential diagnosis could be sinus mucocoele. Moreover, the possible psychological effect of addiction on discounting face beauty was acknowledged.

ACKNOWLEDGMENTS

The authors would like to be thankful to the patient for his cooperation in the current article. This research did not receive any specific grant from funding agencies in the public, commercial, or not-for-profit sectors.

COMPETING INTERESTS

The authors declare that they have no competing interests.

REFERENCES

1. Baurmash HD. Mucocoeles and ranulas. *J Oral Maxillofac Surg* 2003;**61**(3):369-78.
2. Capra GG, Carbone PN, Mullin DP. Paranasal sinus mucocoele. *Head Neck Pathol* 2012;**6**(3):369-72.
3. Carvalho BVd, Lopes IdCC, Corrêa JdB, Ramos LFM, Motta EGP, Diniz RLFC. Typical and atypical presentations of paranasal sinus mucocoele at computed tomography. *Radiologia Brasileira* 2013;**46**(6):372-5.
4. Masoudkabar F, Sarrafzadegan N, Eisenberg MJ. Effects of opium consumption on cardiometabolic diseases. *Nat Rev Cardiol* 2013;**10**(12):733-40.
5. Ghelardini C, Di Cesare Mannelli L, Bianchi E. The pharmacological basis of opioids. *Clin Cases Miner Bone Metab* 2015; **12**(3):219-21.

6. Sushil Kumar Aggarwal KB, Amit Keshri, Raj Kumar, Arun Srivastava. Frontal sinus mucocele with orbital complications: Management by varied surgical approaches. *Asian J Neurosurg* 2012; 7(3):135-40.
7. Ellath Valappil Bijith SM, and Krishnaswamy Mahadevan. Frontal Mucocele Mimicking a Frontal Subcutaneous Tumor. *Asian J Neurosurg* 2017; 12(4): 760-762.
8. Mäntyselkä P, Kumpusalo E, Ahonen R, et al. Pain as a reason to visit the doctor: a study in Finnish primary health care. *Pain* 2001;89(2):175-80.
9. Jalilian F KMB, Ahmadpanah M, Ataee M, Ahmadi Jouybari T, Eslami AA, Mirzaei Alavijeh M. Socio-demographic characteristics associated with cigarettes smoking, drug abuse and alcohol drinking among male medical university students in Iran. *J Res Health Sci* 2015;15(1):42-6.
10. Pathan H, Williams J. Basic opioid pharmacology: an update. *Br J Pain* 2012;6(1):11-6.
11. Zakaria C. Management of a Ethmoido-Orbital Mucocele with an Acute Installation: a Case Report. *Global J Otolaryngol* 2017;4(4): 555642.
12. Bouhafs K, Lachkar A, Bouamama T, Benfadil D, Ghailan MR. Bilateral orbito-cerebral-extending frontal mucocele following nasosinus polyposis: A case report. *Ann Med Surg (Lond)* 2021;66:102432.
13. Bola AS, Andjock YCN, Choffor EN, Nanci E, Esene IN, Djomou F. Bilateral sphenoid sinus mucocele observed in Yaounde-Cameroon: a case report. *Pan Afr Med J* 2021;39:198.