

Assessment of Maxillary Sinus Variations Post-LeFort: A Systematic Review

Majid Eshghpour¹, Touraj Vaezi¹, Sahand Samieirad¹, Ali Manafi²,
Alireza Ebrahimpour³, Abdolrahim Shams^{3*}

1. Department of Oral and Maxillofacial Surgery, School of Dentistry, Mashhad University of Medical Science, Mashhad, Iran
2. Department of Plastic Surgery, Iran university of Medical Sciences, Tehran, Iran
3. Department of Oral and Maxillofacial Surgery, Student Research Committee, Faculty of Dentistry, Mashhad University of Medical Science, Mashhad, Iran

ABSTRACT

Background: The purpose of this article was to systematically review maxillary sinus changes after LeFort. We examined and analyzed the anatomical abnormalities that occurred following LeFort I osteotomy, as well as the abnormalities of maxillary sinus volume (MSV) before and after the operation.

Methods: A systematic search was conducted on various databases, such as Google Scholar, PubMed, and Scopus. The articles used were in English and original. This study was conducted until September 2023, and after reviewing the articles, several keywords, such as “Maxillary sinus” and “LeFort I osteotomy”, were employed. The obtained data were evaluated based on the PICO framework.

Results: Findings from 15 studies showed that the amount of MSV decreased before and after the operation (considering the three dimensions of the sinus, the measurement was performed linearly). These reduction values differed between men and women, with men having a greater reduction. As is the case with other operations, there were some side effects associated with this type of operation that some patients experienced postoperatively.

Conclusion: In both male and female patients, the MSV was reduced after one-piece and multi-segment osteotomies. Nonetheless, one-piece LeFort I osteotomy showed a higher reduction in MSV than the multi-segment osteotomy method, according to this systematic review and meta-analysis.

KEYWORDS

LeFort; Maxillary sinus; Orthognathic surgery; Osteotomy

Please cite this paper as:

Eshghpour E., Vaezi T., Samieirad S., Manafi A., Ebrahimpour A., Shams A. Assessment of Maxillary Sinus Variations Post-LeFort: A Systematic Review. *World J Plast Surg.* 2023;12(3):3-10.
doi: 10.61186/wjps.12.3.3

*Corresponding Author:

Abdolrahim Shams,

Oral and Maxillofacial Surgery
Department, Faculty of Dentistry,
Mashhad University of Medical
Science, Mashhad, Iran

Email: shama971@mums.ac.ir

Received: 2023.07.22

Accepted: 2023.11.25

INTRODUCTION

Maxillofacial surgeons utilize the LeFort 1 osteotomy procedure to correct a range of dentofacial deformities. Its versatility and simplicity have made it popular for a variety of purposes¹. The history of this surgery goes back a century. Rene LeFort, in 1901, described a fracture pattern that extends from the nasal septum through the pterygomaxillary junction, and this fracture pattern is now referred to as the LeFort I osteotomy. Cheever was the first to describe a LeFort 1 surgery in 1864 for the removal of a nasopharyngeal tumor². The

state of the pterygoid plates is what distinguishes the fracture pattern described by LeFort from the osteotomy. The pterygoid plates remain intact when the LeFort 1 osteotomy is performed at the pterygomaxillary junction. Wassmund was the first who used the procedure in 1921 to correct dentofacial deformities through repositioning the maxilla after osteotomy and postoperative orthopedic traction³. Axhausen corrected an open bite by mobilizing the osteotomized maxilla intraoperatively in 1934⁴.

In other words, Le Fort I osteotomy is one of the methods that allow for the treatment of midface dentofacial abnormalities⁵. This procedure necessitates the temporary detachment of the whole maxilla from the midface⁶. Superior repositioning of the maxilla is often required in the treatment of maxillofacial deformities with a vertical maxillary excess, such as cases of long face, open bite, or mentum protrusion, even though it allows the maxilla to be moved in three dimensions^{7,8}.

The maxillary sinus is one of the four pairs of paranasal sinuses located in the human skull. It is the largest of the paranasal sinuses and is situated within the maxillary bone, which forms the upper jaw. The maxillary sinus is lined with a mucous membrane and is filled with air. The primary function of the maxillary sinus is to lighten the weight of the skull and enhance voice resonance. Additionally, it acts as a buffer to protect vital structures, such as teeth roots, nerves, and blood vessels in the upper jaw⁹.

After Le Fort I osteotomy, the air cavity as a whole, the total maxillary sinus volume (MSV), and the membrane thickness (MT) had all decreased. The advancement motions that result in a modification in the posterior maxillary sinus wall and a change in the morphology of the sinus chamber can be used to reflect a decrease in MSV¹⁰.

Due to the clear fact that the maxillary sinus (MS) lies in the line of the osteotomy, a surgical procedure may also have an impact on the MS's physiology. When the MS is functioning normally, the mucociliary action causes secretions to be discharged into the ostium. After LeFort I osteotomy, there is a drop occurrence of MS¹¹. This happens as a result of MS growing a shelf or plica after surgery, which limits the natural discharge range of motion¹².

Using a range of methods, including cadavers, stereology, two-dimensional conventional radiography, computational tomography (CT), magnetic resonance imaging (MRI), and cone-beam

computed tomography (CBCT), several studies have been conducted on the measurement of MSV¹³.

The majority of research on individuals with LeFort I MS that has been published focuses on postoperative complications, treatments, and the links between surgeries and conditions, such as sinusitis. With the investigated MSV in LeFort patients, the overall volume of maxillary sinus was statistically significantly reduced following the procedure. The mean MSV was found to be 20.512 mm³ prior to and 17.560 mm³ following the LeFort I procedure¹⁴. The periosteum is tightly connected to the Schneiderian membrane (a thin respiratory mucous membrane that lines the maxillary sinus) and is 0.8 to 1 mm thick¹⁵. Moreover, a common radiographic finding in an asymptomatic individual is sinus membrane thickness (SMT) of the maxillary sinuses, which can range in prevalence from 8% to 29%¹⁶.

We aimed to evaluate the changes in size, shape, and position of the maxillary sinus after Le Fort surgery. It also provides a comprehensive understanding of these variations and their potential implications.

METHODS

The criteria for considering studies for this review were as follows:

Types of studies

This research looked at studies that were published in English. The following articles were excluded: reviews, case reports, editorials, guidelines, letter to the editors, and abstracts from conferences. Randomized controlled trials (RCTs) that were both double-blinded and single-blinded were included in the current study.

Types of participants

The participants were aged 18 years or older and had changes in the maxillary sinus after LeFort.

Types of interventions

The types of interventions that can be mentioned for a review with the title "Assessment of Maxillary Sinus Variations post-Le Fort" include Le Fort I surgery, Sinus surgery, Sublabial surgery, Bone grafting surgery, and Sinus region surgery.

Types of outcome measures

The type of outcome measures for a review with the title “Assessment of Maxillary Sinus Variations post-Le Fort” would likely include:

1. Radiographic assessments: This may involve analyzing pre- and post-operative imaging scans, such as CT scans or MRI, to measure changes in maxillary sinus volume, shape, or position.
2. Clinical evaluations: This could include assessing symptoms related to maxillary sinus variations, such as nasal congestion, facial pain, or sinus infections. It may also involve evaluating functional outcomes, such as breathing difficulties or speech changes.
3. Objective measurements: These may involve quantifying specific parameters related to maxillary sinus variations, such as the distance between the maxillary sinus and other anatomical structures, the angle of maxillary sinus deviation, or the presence of any complications.
4. Patient-reported outcomes: This could involve collecting self-reported data from patients regarding their satisfaction with the surgical outcomes, quality of life improvements, or any adverse effects experienced post-Le Fort surgery.
5. Histological assessments: In some cases, a review may include analyzing histological samples obtained during the surgical procedure to evaluate tissue changes within the maxillary sinus.

Search methods for the identification of studies

To identify RCTs deemed suitable for inclusion in this study, a comprehensive search was conducted utilizing various databases until September 2023. Accordingly, PubMed, EMBASE, Cochrane databases, Scopus, and Google Scholar databases were extensively searched to identify studies about the research question. Any further references that were overlooked in the electronic database searches were manually sought in the reference lists of the selected papers. All searches were made in the databases. Duplicate hits were deleted using the EndNote Basic® software (Thompson Reuters, New York, NY).

DATA COLLECTION AND ANALYSIS

Selection of studies

First, two writers (AE and AS) independently

assessed all articles' titles and abstracts. Any articles that did not appear to fit the criteria for inclusion were discarded. Then, full texts were evaluated and screened separately. Disagreements were settled through conversation. When the first two reviewers couldn't come to an agreement, a third author (ME) was brought in to make the final choice.

Based on a review of the title and abstract, ineligible papers were disqualified from the analysis. During the search process, the selected Medical Subject Headings terms included “Maxillofacial surgery”, “Orthognathic surgery”, and “LeFort I”. We then used the PICO framework: P (Patient, Population), I (Intervention or Exposure in the case of observational studies), C (Comparison), and O (Outcomes). In this systematic review, the PICO approach involved Population (male and female patients of all age groups), Exposure (LeFort I osteotomy), Comparison (MSV before and after LeFort I osteotomy), and Outcome (increase or decrease in total MSV).

Dealing with missing data

Data that were deemed to be lacking and not reported in the papers were purposefully left out. We extracted the essential data from the aforementioned graphical representations during the trials if the data were displayed in graph form rather than a textual explanation.

Assessment of heterogeneity

The trials under investigation were assessed by the parameters of their environment, study participants, and interventions used, and aggregation was not performed in cases where clinical heterogeneity was observed within trials.

RESULTS

Description of studies

We found 123 articles conducted to assess maxillary sinus changes after LeFort. After reviewing the titles and abstracts, 65 studies remained, out of which 35 documents were left after removing duplicate studies. Of these, 15 documents were excluded due to being non-English and type of research (reviews, case reports,

editorials, guidelines, letter to the editors, and abstracts from conferences), as well as for other reasons related to maxilla declination; finally, 15 articles were assessed (Figure 1). In each article, we considered surgical procedures, the amount of surgical maxillary advancement, data obtained from surgery, postoperative complications, the time of operation, the amount of lost blood, and follow-up. Some articles confirmed discolored or slightly severely discolored teeth. A total of 250 patients participated in the maxillary sinus trial, of which only approximately 30 patients were related to maxillary sinus changes after LeFort.

Inclusion criteria

To collect studies directly related to the current study, the following eligibility criterion was applied: original articles only, including randomized clinical trials, prospective, retrospective, or cohort studies, for which the full text rather than just an abstract was available. Moreover, studies that focused on MSV, LeFort I orthognathic surgery, and all genders

were needed. Studies were included if MSV was diagnostically confirmed radiographically. For each study, the collected data included author/year, age group, male-to-female ratio, skeletal relationship, surgical procedure, diagnostic method, follow-up interval, and the total number of patients.

Among these articles, three were about LeFort osteotomy and related to maxillary sinus^{5,6,8,10,13} one about anatomical changes of the jaw after LeFort², one about the impact of age⁸, one about the evaluation of sinonasal change after LeFort I osteotomy¹², and the rest about maxillary sinus.

Exclusion criteria

Studies with the following characteristics were excluded: non-English articles and non-original articles, including systematic reviews, literature reviews, and case reports. Studies reporting maxillary sinus changes due to other reasons than LeFort I osteotomy as well as studies performed on individuals with orofacial syndromes were also excluded.

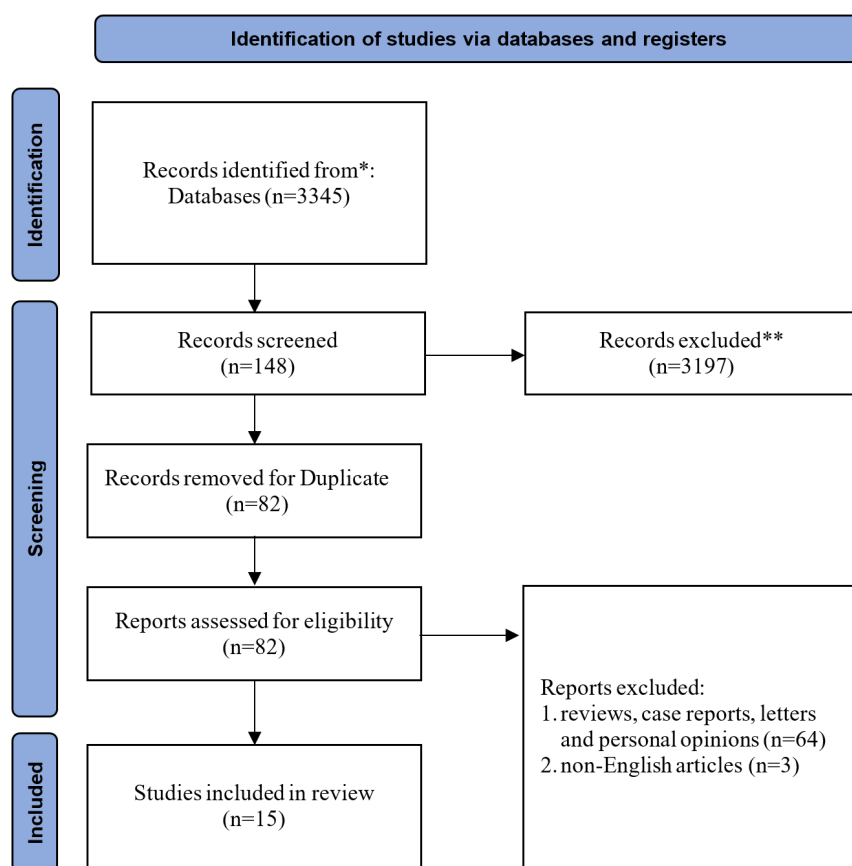


Figure 1: Flow diagram of the study

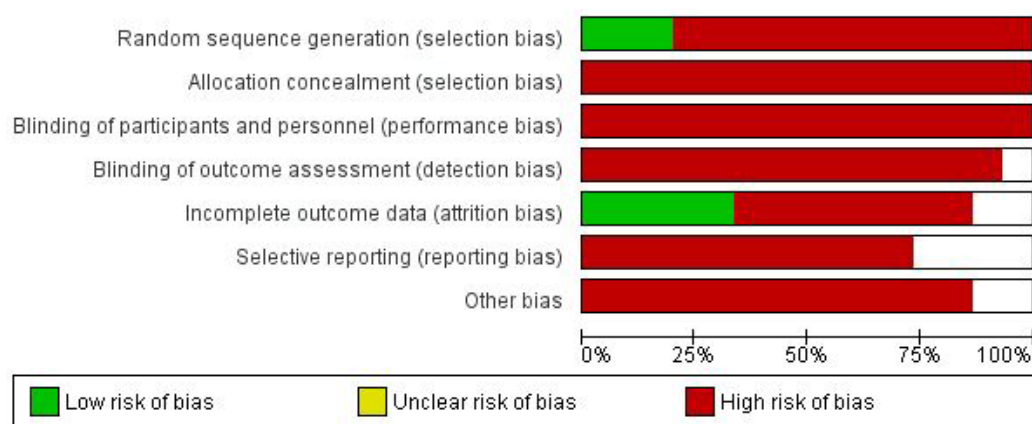


Figure 2: Risk of bias graph: authors' judgments about each risk of bias item presented as percentages across all included studies

Incomplete outcome data

In three articles, the amount of anatomical reduction after the LeFort operation was discussed; however, there was no report on the extent of these reductions. The advantages and disadvantages of these changes, as well as how these changes were made, were not documented either^{5, 6, 9, 10, 15}.

In some studies, although the thickening of the membrane was mentioned, it was neither discussed what events or anatomical changes this thickness caused after the operation nor reported whether the thickening led to some disadvantages in the future^{2, 4}.

Main result

In most of the articles, MSV was reduced. In general, the mean MSV on both sides was $29.06 \pm 7.829 \text{ cm}^3$.⁷ Some articles mentioned that there was no statistically significant difference between the right and left sinus volumes. However, the right MSV was slightly smaller than the left one, and considering all changes in the sinus, MSV was measured linearly⁸. Various techniques had been employed to measure MSV, including a CT scan, MRI, and CBCT¹¹.

The mean score of MSV for women ($27.188 \pm 6.788 \text{ cm}^3$) was a little lower than that for men ($31.62 \pm 8.430 \text{ cm}^3$). In addition to the gender difference, age affected the amount of MSV varying by aging⁷.

Some articles showed that after the operation, SMT caused membrane thickening and there was an anatomical change. The left SMT was found to be significantly higher than the right SMT postoperatively; nevertheless, while there was no difference in the right SMT before and after the

operation, a significant difference was found in the left SMT after the operation⁹. Additionally, except for a higher SMT on the right side in men, no other significant differences were found between genders.

Allocation

Most studies did not report the method of allocation concealment and were scored as 'high risk' on these items.

Risk of bias in included studies

We have presented the 'Risk of bias' assessment in Figure 2. Seven of the 15 studies were considered to have a low risk of bias^{2, 4-9}.

Blinding

In trials with surgical interventions, it is not possible to blind patients, care providers, or outcome assessors. Besides, no blinding was reported in the studies.

DISCUSSION

This study included 15 RCTs that assessed maxillary sinus changes after the LeFort procedure. Many research articles have investigated the method of reducing the volume of the maxillary sinus after the Le Fort I operation.

Akbulut et al. in a study, evaluated 30 patients who underwent Le Fort I osteotomy just before and 1 year after the surgical operation. Their study aimed to investigate changes in maxillary sinus volume,

SMT, and the distance between the maxillary sinus floor and ostium after Le Fort I osteotomy. They concluded that the deterioration of ciliary activity and drainage could occur due to the impact of Le Fort I osteotomy on the thickness and volume of the maxillary sinuses, which increased the likelihood of sinus pathologies¹³.

A search by Baeg et al. was carried out on 33 patients who underwent orthognathic surgery, including Le Fort I osteotomy. There was a clear reduction in the air cavity itself, a reduction in the total volume of the maxillary sinus, and an increase in mucosal thickening. Additionally, the posterior lower portion of the maxillary sinus appeared to be the primary location of the postoperative mucosal thickening¹².

One-piece and multi-segment osteotomies caused a decrease in maxillary sinus volume for both skeletal class II and class III in male and female patients. The one-piece LeFort I osteotomy technique results in a greater reduction in the sinus volume compared to the multi-segment osteotomy technique. The maxillary sinus thickness did not change after the operation¹⁷.

Bell et al., in an investigation reported that Le Fort I osteotomy did not lead to an increase in maxillary sinusitis¹⁸.

The Le Fort I osteotomy technique used in orthognathic surgery resulted in substantial alterations in the upper airway volume, which involved the nasal fossa airways, rhinosinusal, and maxillary sinuses¹⁹.

In some cases, patients are faced with slowing down the functional improvement of the maxillary sinus after the Le Fort I operation. According to a report, the recovery of the maxillary sinus after surgery might be slow and the changes might be irreversible, as the pathologic conditions might remain for up to 6 months²⁰.

None of the trials that were reviewed documented the negative effects or postoperative complications of a reduced MSV. Moreover, few articles discussed the negative or positive impacts of changes in the MSV. A decreased MSV had been linked to a small number of other diseases, though. Additionally, Kim et al. found that in adult patients, a decreased MSV was predicted²¹.

Chronic rhinosinusitis and decreased MSV have been linked in several other papers. This result was in line with that of a research conducted by Kim et

al., who reported a relationship between a decreased MSV and persistent chronic rhinosinusitis in young patients. The side effect of reduced MSV could be the development of a maxillary sinus fungal ball^{22, 23}. On the other hand, an increase in MSV was associated with the development of cysts and antrochoanal polyps²⁴. Therefore, surgeons need to be aware of how changes in maxillary sinus volume affect their patients. Nevertheless, further research is required to provide additional evidence in this regard.

Men experience a larger decline in MSV following LeFort I osteotomy and impaction than women. Our review found no significant correlation between the changes in the right and left MSV and the surgical movement or the rate of impaction and advancement after LeFort I orthognathic surgery. LeFort I osteotomy inevitably involves the mandibular sinus^{25, 26}.

LIMITATIONS OF THE STUDY

The limitations of the study were related to the small number of studies, incomplete data, the absence of patient information, and the small number of studies documenting postoperative side effects of a reduced maxillary sinus.

CONCLUSION

Le Fort I surgery can lead to the reduction of the maxillary sinus after surgery. These changes in the maxillary sinus may occur due to changes in the structure and anatomy of the face and jaws. Furthermore, the results have shown that the incidence of this decrease is more common in men than in women, probably due to gender differences in the structure of the face and jaw. These changes in the maxillary sinus after Le Fort I surgery may cause side effects.

ACKNOWLEDGMENTS

This research was carried out in the form of self-funding.

CONFLICT OF INTEREST

The authors declare that there is no conflict of interests.

REFERENCES

- Buchanan EP, Hyman CH. LeFort I Osteotomy. *Semin Plast Surg* 2013;**27**:149-54. doi:10.1055/s-0033-1357112.
- ALSTAD, ABTAHI, Jahan. Surgical removal of keratocystic odontogenic tumours via a Le Fort I osteotomy approach: a retrospective study of the recurrence rate. *Int J Oral Maxillofac Surg* 2017;**46**:434-9.]
- WANG, Qian, Qi, Ge, Cao, Zhang, Meng. Evaluation of Related Factors of Maxillary Sinusitis After Le Fort I Osteotomy Based on Computed Tomography: A Retrospective Case-Control Study. *Arch Craniofac Surg* 2022;**33**:1795-9]
- KHIABANI, Keyhan. Effect of using different methods of plate fixation in maxillary Lefort one fractures. *J Oral Maxillofac Surg Med Pathol* 2019;**31**:386-400].
- O, HH. Effect of maxillary surgical movement on nasal cavity and maxillary sinus dimensions and function after Le Fort I osteotomy. *Int J Oral Maxillofac Surg* 2022;**51**(6):806-12. doi: 10.1016/j.ijom.2021.10.006. Epub 2021 Nov 2. PMID: 34740472.
- Valstar MH, Baas EM, Te Rijdt JP, De Bondt BJ, Laurens E, De Lange J. Maxillary sinus recovery and nasal ventilation after Le Fort I osteotomy: a prospective clinical, endoscopic, functional and radiographic evaluation. *Int J Oral Maxillofac Surg* 2013;**42**:1431-6. doi:10.1016/j.ijom.2013.05.009.
- Iwamoto M, Watanabe M, Yamamoto M, Narita M, Kamio T, Takaki T, Shibahara T, Katakura A. Prognostic factors for maxillary sinus mucosal thickening following Le Fort I osteotomy: a retrospective analysis. *Maxillofac Plast Reconstr Surg* 2019;**41**:12-22. doi:10.1186/s40902-019-0195-3.
- Tomomatsu N, Kurohara K, Nakakuki K, Yoshitake H, Kanemaru T, Yamaguchi S, Yoda T. Influence of the anatomical form of the posterior maxilla on the reliability of superior maxillary repositioning by Le Fort I osteotomy. *Int J Oral Maxillofac Surg* 2019;**48**:612-9. doi:10.1016/j.ijom.2018.11.004.
- Kapusuz Gencer Z, Ozkırış M, Okur A, Karaçavuş S, Saydam L. The effect of nasal septal deviation on maxillary sinus volumes and development of maxillary sinusitis. *Eur Arch Otorhinolaryngol* 2013;**270**:3069-73. doi:10.1007/s00405-013-2435-y.
- Nocini PF, D'Agostino A, Trevisiol L, Favero V, Pessina M, Procacci P. Is Le Fort I Osteotomy Associated With Maxillary Sinusitis? *J Oral Maxillofac Surg* 2016;**74**:400.1-12. doi:10.1016/j.joms.2015.10.006.
- Moses JJ, Lange CR, Arredondo A. Endoscopic treatment of sinonasal disease in patients who have had orthognathic surgery. *Br J Oral Maxillofac Surg* 2000;**38**:177-84. doi:10.1054/bjom.1999.0195.
- Baeg SW, Hong YP, Cho DH, Lee JK, Song SI. Evaluation of Sinonasal Change After Lefort I Osteotomy Using Cone Beam Computed Tomography Images. *J Craniofac Surg* 2018;**29**:34-41. doi:10.1097/scs.0000000000004001.
- Akbulut N, Kurşun Çakmak E, Bayrak S. Assessment of Maxillary Sinus Changes After Le Fort I Osteotomy Surgery. *J Craniofac Surg* 2020;**31**:497-501. doi:10.1097/scs.0000000000006659.
- Kramer FJ, Baethge C, Swennen G, Teltzrow T, Schulze A, Berten J, Brachvogel P. Intra- and perioperative complications of the LeFort I osteotomy: a prospective evaluation of 1000 patients. *J Craniofac Surg* 2004;**15**:971-7; discussion 8-9. doi:10.1097/00001665-200411000-00016.
- Bayrak S, Ustaoglu G, Demiralp K, Kurşun Çakmak E. Evaluation of the Characteristics and Association Between Schneiderian Membrane Thickness and Nasal Septum Deviation. *J Craniofac Surg* 2018;**29**:683-7. doi:10.1097/scs.0000000000004254.
- Soikkonen K, Ainamo A. Radiographic maxillary sinus findings in the elderly. *Oral Surg Oral Med Oral Pathol Oral Radiol Endod* 1995;**80**:487-91. doi:10.1016/s1079-2104(05)80375-0.
- Othman A, AlQahtani FA, Kuriadom S, Ahmed SW, AlMutairi F, AlAnzy H, AlAssiri N. Is the volume of the maxillary sinus altered after LeFort I orthognathic surgery? A systematic review and meta-analysis. *J Stomatol Oral Maxillofac Surg* 2023;**124**:101310. doi:10.1016/j.jormas.2022.10.009.
- Bell CS, Thrash WJ, Zysset MK. Incidence of maxillary sinusitis following Le Fort I maxillary osteotomy. *J Oral Maxillofac Surg* 1986;**44**:100-3. doi:10.1016/0278-2391(86)90189-8.
- Faur CI, Roman RA, Bran S, Dinu C, Coclici A, Rotaru H, Hedesiu M. The Changes in Upper Airway Volume after Orthognathic Surgery Evaluated by Individual Segmentation on CBCT Images. *Maedica (Bucur)* 2019;**14**:213-9. doi:10.26574/maedica.2019.14.3.213.
- Toskala E, Rautiainen M. Electron microscopy assessment of the recovery of sinus mucosa after sinus surgery. *Acta Otolaryngol* 2003;**123**:954-9. doi:10.1080/00016480310005110.
- Kim YJ, Shin HK, Lee DY, Ryu JJ, Kim TH. Decreased maxillary sinus volume is a potential predictor of obstructive sleep apnea. *Angle Orthod* 2020;**90**:556-63. doi:10.2319/080819-520.1.
- Sonone J, Nagpure PS, Puttevar M, Garg D. Changes in Maxillary Sinus Volume and It's Walls Thickness Due to Chronic Rhinosinusitis: A Prospective Study. *Indian J Otolaryngol Head Neck Surg* 2019;**71**:2182-5. doi:10.1007/s12070-019-01613-1.
- Michel J, Radulesco T, Mancini J, Paganelli A, Varoquaux A, Adalian P, Ranque S, Dessi P. Maxillary

- sinus volume: new physiopathological data in fungal ball genesis? A retrospective study. *Clin Otolaryngol* 2017;**42**:831-6. doi:10.1111/coa.12813.
24. Pérez Sayáns M, Suárez Quintanilla JA, Chamorro Petronacci CM, Suárez Peñaranda JM, López Jornet P, Gómez García F, Guerrero Sánchez Y. Volumetric study of the maxillary sinus in patients with sinus pathology. *PLoS One* 2020;**15**:0234915. doi:10.1371/journal.pone.0234915.
25. Koppe T, Nakatsukasa M, Yamanaka A. Implication of craniofacial morphology for the pneumatization pattern of the human alveolar process. *Acta Medica Lituanica* 2005;**12**:40-6.
26. Panou E, Motro M, Ateş M, Acar A, Erverdi N. Dimensional changes of maxillary sinuses and pharyngeal airway in Class III patients undergoing bimaxillary orthognathic surgery. *Angle Orthod* 2013;**83**:824-31. doi:10.2319/100212-777.1.