

Oral Submucous Fibrosis: a Premalignant Condition in a 22-Year-Old Iranian Man

Mojgan Balverdi¹, Tayebeh Ghasemi¹, Sadra Amirpour Haradasht^{1*}

1. Department of Oral and Maxillofacial Surgery, School of Dentistry, Zahedan University of Medical Sciences, Zahedan, Iran

ABSTRACT

Oral submucous fibrosis (OSF) is a chronic, irreversible disease. The etiology of OSF has been linked to several risk factors, including local factors, systemic factors, and immunological disorders. We report a 22-year-old male patient case of Oral submucous fibrosis, referred to the Maxillofacial Surgery Department of Zahedan University of Medical Sciences, Zahedan, Iran. Treatment for oral submucous fibrosis is based on the disease's clinical involvement and rate of advancement. Even though there are numerous innovative therapeutic techniques for this illness, none of them can cure it. Early diagnosis and treatment can improve the quality of life of a person. Some of the findings of this study are different from reference texts and other studies.

KEYWORDS

Fibrosis; Oral submucous fibrosis; Precancerous disorder; Management; Treatment

Please cite this paper as:

Family N. Oral Submucous Fibrosis: a Premalignant Condition in a 22-Year-Old Iranian Man. *World J Plast Surg.* 2023;12(3):100-105.
doi: 10.61186/wjps.12.3.100

INTRODUCTION

Oral submucous fibrosis (OSF) is a chronic, resistive, irreversible, and susceptible malignant disease. The clinical view of this pathologic lesion is presented as a scar and increasing fibrosis of the mucosa covering the upper sections of the digestive tract, particularly the oral cavity, oropharynx, and upper third of the esophagus¹. Of all oral premalignant lesions, this one has the highest chance of turning malignant².

The signs of this disease, such as paleness and stiff mucus, primarily affect one side, though studies have also mentioned both sides being affected². Burning in the mouth, aversion to hot meals, and dry mouth are some symptoms that the lesion may cause. In severe cases of the condition, a problem in tongue movement, swallowing, articulation, microstomia, and trismus (irreversible restriction in the degree of mouth opening) occurs in the patients³.

In particular geographic regions like Southeast Asia, Sri Lanka, Bangladesh, India, and its nearby regions (southeast of Iran), the disease is also quite prevalent¹⁻⁴.

The etiology of OSF has been linked to several risk factors, including local

*Corresponding Author:

Sadra Amirpour Haradasht

Department of Oral and Maxillofacial Surgery, School of Dentistry, Zahedan University of Medical Sciences, Zahedan, Iran

Tel.: +98 911 4704715

Email: sdraharadasht@gmail.com

Received: 10/04/2023

Accepted: 29/10/2023

factors (hot foods, lemon powder, lime, capsaicin, areca nut, and betel quid), systemic factors (anemia, iron deficiency, vitamin B deficiency, connective tissue/collagen diseases, and malnutrition), as well as genetic predisposition, collagen, and immunological disorders⁵. Although the exact cause of OSF is still unknown, some studies have found a link between smoking, diet, and lesion growth⁶.

Fibroelastic alterations in the lamina propria and epithelial atrophy are observed in this disease¹.

OSF affects people of all ages, however, it is more common in adults between the decade of 2 to 4 and slightly more frequently in females than in males^{5,7}. It begins gradually and often lasts between 2 to 5 years but several cases with sudden onset and different periods have been reported⁸.

CASE REPORT

A 22-year-old male patient was referred to the Maxillofacial Surgery department of Zahedan University of Medical Sciences in November 2022 with a chief complaint of restricted mouth opening with a chronic reduction of MIO (Maximum Interincisal Opening) and bilateral fibrosis. The patient reported progressively reduced mouth opening from 3-4 years ago.

The patient had a history of using a substance called "betel nut" which came from Pakistan. The patient did not report any systemic or allergic diseases. Based on the clinical examination of the patient indicated MIO: 7mm, and in addition to the oral mucosa, the buccinators, and orbicularis oris muscle were also involved in the disease. The patient did not experience any facial pain in regular condition, but he had burning sensations in his mouth while eating. The patient received six intralesional triamcinolone injections (TriamHEXAL ampoule 40 mg/1 ml

mixed with lidocaine 2%) over a period of three months from November 2019 to January 2020, once every two weeks, to treat fibrosis. However, there was no improvement in the extent of MIO. After ceasing betel nut use, the patient started using Supari, a lime-containing product, and consuming areca nut products as a breath freshener.

Following the initial workup, the patient was admitted to Khatam Hospital's Oral and Maxillofacial Ward, Zahedan, Iran. Due to the patient's severe reduction in MIO, Retrograde Intubation, and awake laryngoscopy were performed.

After the patient preparation, a bilateral incision was made along with the patient's occlusal plane on the buccal mucosa. To prevent this incision from injuring the Stensen duct, first, the Stensen duct on both sides of the mouth was detected by milking parotid glands. Then, incisions were made by using an electrosurgical knife spread from the corner of the mouth to the soft palate at a level of the occlusal plane until the full width of the buccal mucosa was reached.

To expand the range of the lateral motion of jaws and increase MIO, the coronoid processes were approached through the same incision, and a coronoid ectomy on the right side and coronoidotomy on the left side were performed. Then, bilateral dissection was carried out on the initial incision line to reach the buccinators and orbicularis oris muscle then the fibrotomy procedure was performed on both sides. The buccal fat pad was harvested through the posterior-superior margin of the incision and was used to completely cover the defect to prevent secondary epithelization. After the aforesaid bilateral actions, to prevent dead space, and biting and displacing the buccal fat pad flap, Tetracycline 1 % ophthalmic ointment was applied on a pair of small bandages and placed on the bilateral buccal

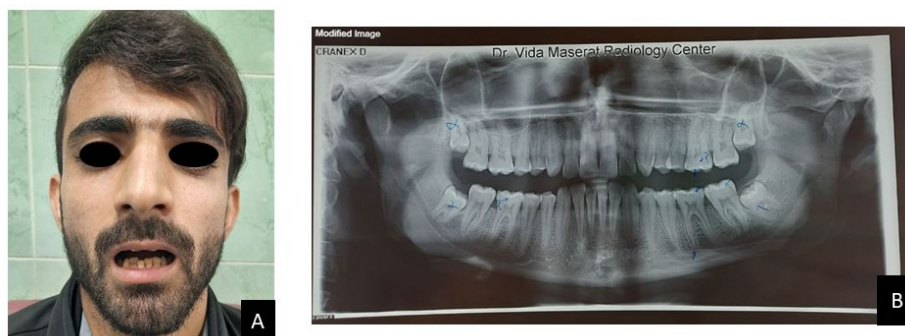

Figure 1: A: Decreased mouth opening in oral submucous fibrosis patient; B: radiographic view of the patient

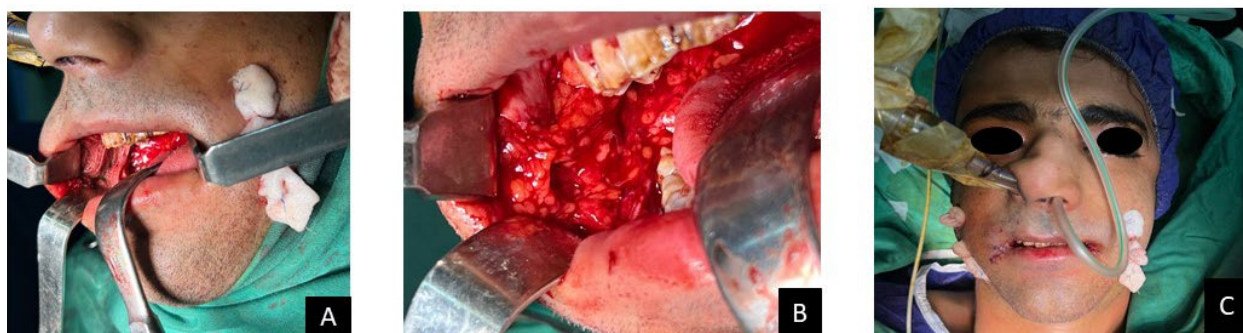

Figure 2: A: Harvesting of buccal fat pad; B: BFP sutured intraorally over the defect
C: After the surgery with NG tube

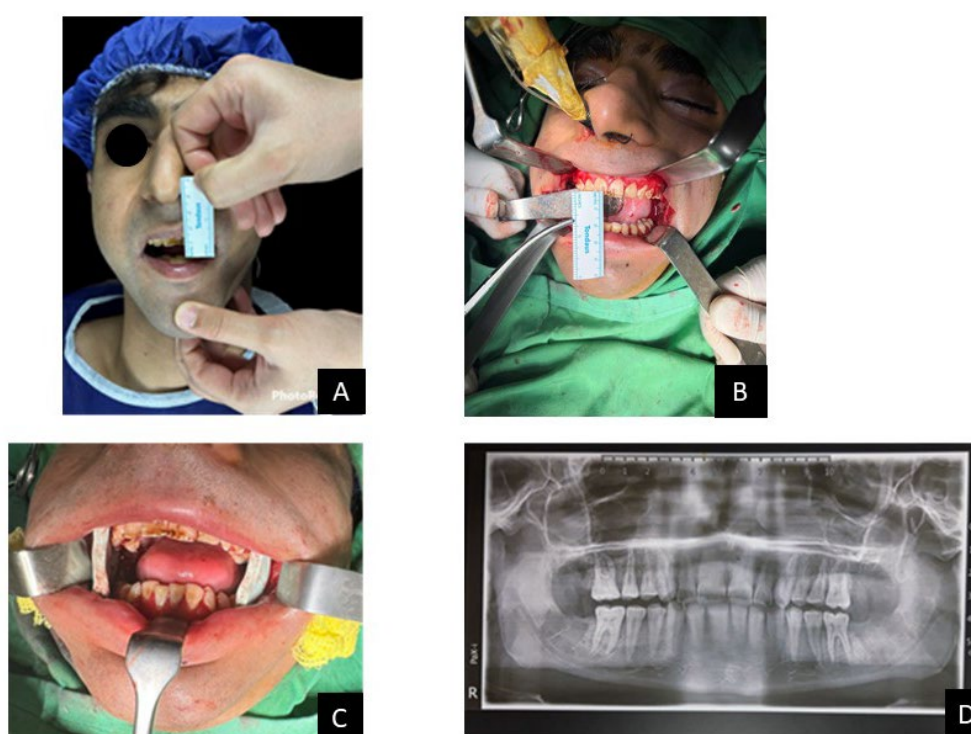


Figure 3: A: MIO before the last surgery; B: MIO after last the surgery; C: patient's intraoral temporary splint; D: OPG After the tooth extraction

mucosa, then fixed by tie-over sutures on the skin. To perform an incisional biopsy from the patient's labial mucosa for histopathologic analysis in light of the disease's potential for malignancy, a visible white discoloration was discovered there. The little bandages were removed five days following the procedure, and the patient received an NG tube for ten days to use for feeding. Ten days following surgery, passive physiotherapy to increase MIO was initiated.

The pathologist's report indicated that there were no indications of malignancy and only the following points were noted: subepithelial fibrosis, chronic

inflammation, and atrophic overlying epithelium.

In the first 2 weeks after the operation, the patient's MIO was increasing favorably. After 2 weeks after the operation, the patient was referred to a physiotherapist to improve his condition. Unfortunately, after the physiotherapy, the patient suffered facial swelling and excess tissue at the surgical site. To remove the excess tissue, the patient was taken to the operating room after 40 days after the first operation, and in addition to removing the excess tissue, a combination of triamcinolone and Lidocaine (TriamHEXAL ampoule 40 mg/1 ml mixed with lidocaine 2%) were also injected into the

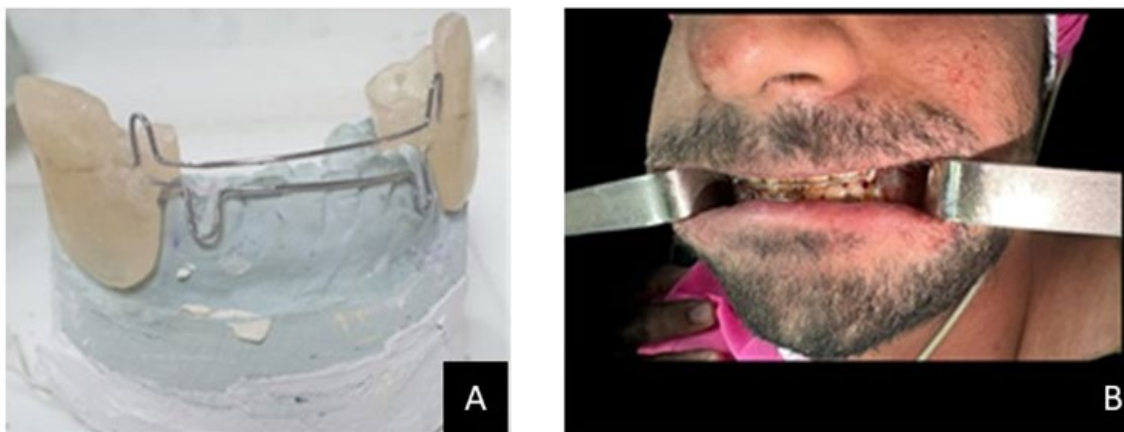


Figure 4: A: intraoral appliance; B: After placement intraoral appliance

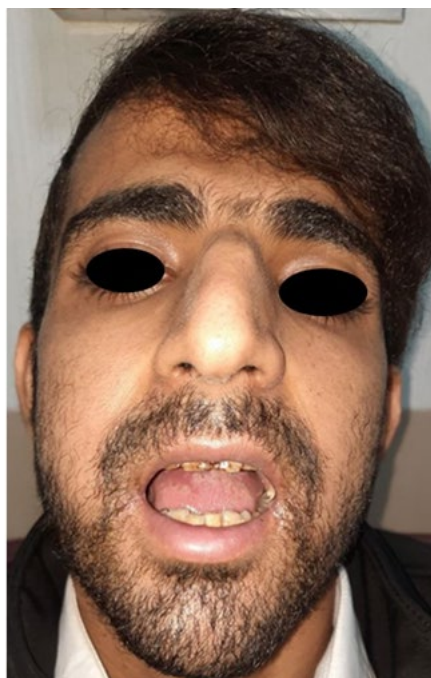

Figure 5: patient MIO 3 months after the last surgery

fibrosis sites. After 20 days of the second surgery, the patient underwent surgery again. Excess tissues were removed again and the patient's 7 and 8 molars were extracted.

Taking into account the failure of the previous surgeries, in the third surgery, after removing the extra tissues, we take a dental impression to make an intraoral appliance. Until the preparation of the patient's intraoral appliance, two temporary splints made of putty were placed in the patient's buccal mucosa to prevent tissue regrowth.

An intraoral appliance with a buccal shield was created for the patient seven days following surgery

to prevent tissues from being bit. Following the procedure, on the twentieth day, it was discovered that the patient's MIO had risen to 15 mm thanks to ongoing passive physiotherapy. The patient's state of health was becoming better overall. Within 3 months of the previous surgery, the patient's MIO had increased to 23 mm. The patient continues to receive routine monitoring.

DISCUSSION

Treatment for oral submucous fibrosis is based on the disease's clinical involvement and rate

of advancement. Breaking bad behaviors and recommending food supplements are the first steps to take. In the intermediate stage, pharmacotherapy is used with conservative treatments such as intralesional injection. However, surgical therapy is required in later stages, as in the case of the patient described in the present article⁹⁻¹¹.

Although there are now many new therapeutic methods for this disease, none of them can cure it. Steroid therapy has long been used as an effective treatment, but newer treatments, such as the use of interferon-gamma (IFN- γ), pentoxifylline and hyaluronidase, cryosurgery, and laser therapy have also been employed. If the patient does not respond to these treatments, surgical treatment is usually used as the ultimate solution in the advanced stages of the disease⁸.

Although buccal mucosa is the most common site of oral subcutaneous fibrosis, the involvement of other areas of the oral cavity has also been reported. In the case of this article, in addition to the oral mucosa, the buccinators, and orbicularis oris muscle were also involved in the disease¹².

Maher et al. did not find any relationship between age and the incidence of the disease and severe cases of this disease can be seen unexpectedly at any age, like the study patient¹³.

The authors of this study described a case of submucosal fibrosis in a 22-year-old man, even though submucosal fibrosis in adults is slightly more common in women⁵.

Oral submucous fibrosis cases with severe trismus and mouth opening less than 20 mm require surgical treatments. Considering that the patient's MIO was extremely low, it was explained to him the necessity of performing surgery¹².

Rai et al. recommended the use of a buccal fat pad flap in comparison with nasolabial flap. The use of BFP was better than for reconstruction of the intraoral defects after the release of fibrous bands in OSF patients and according to the recommendations, we used this technique for our patient¹⁴.

Kamath VV et al. applied different procedures include, including coronoidectomies, muscle myotomies, palatal flap, buccal fat pad, nasolabial flap, collagen membrane, and artificial dermis to relieve the symptoms of OSF. Significant improvement in the symptoms of OSF was seen in all procedures and no definite protocols were recommended¹⁵.

CONCLUSION

Oral submucosal fibrosis is a degenerative, persistent condition. Despite the availability of numerous treatment options, it is extremely challenging to entirely cure and, in certain circumstances, may even be incurable. The inability of the current therapies to completely heal the lesion has become a significant issue for maxillofacial surgeons. In patients with submucous fibrosis-related reduced mouth opening, a proper diagnosis and treatment strategy are extremely important and also the primary drivers of success and excellent outcomes. It is advised that maxillofacial surgeons familiarise themselves with the signs, symptoms, and therapies of this condition.

According to the treatment process of this patient, the prognosis of treating severe grades of this disease is extremely poor and the patient's condition may even worsen from the initial condition so we advise a maxillofacial surgeon not to treat this disease without accurate examination. Aggressive treatments greatly reduce the patient's cooperation. Taking into account the prevalence of this disease and the number of cases reported of unsuccessful treatments of this disease, it can be said that a large number of unsuccessful treatments of these patients have not been reported.

ACKNOWLEDGMENTS

We would like to extend our sincere gratitude to the Department of Oral and Maxillofacial Surgery at the Faculty of Dentistry, Zahedan University of Medical Sciences, for their invaluable support.

CONFLICT OF INTEREST

The authors declare that there is no conflict of interests.

REFERENCES

1. Shih YH, Wang TH, Shieh TM, Tseng YH. Oral Submucous Fibrosis: A Review on Etiopathogenesis, Diagnosis, and Therapy. *Int J Mol Sci* 2019 Jun;20(12):82-9. [DOI:10.3390/ijms20122940]
2. Rao NR, Villa A, More CB, Jayasinghe RD, Kerr AR, Johnson NW. Oral submucous fibrosis: a contemporary narrative review with a proposed inter-

- professional approach for an early diagnosis and clinical management. *J Otolaryngol Head Neck Surg* 2020 Jan;**49**(1):3:121-32. [DOI:10.1186/s40463-020-0399-7]
3. Jha VK, Kandula S, Ningappa Chinnannavar S, Rout P, Mishra S, Bajoria AA. Oral Submucous Fibrosis: Correlation of Clinical Grading to Various Habit Factors. *J Int Soc Prev Community Dent* 2019 Jul-Aug;**9**(4):363-71. [DOI: 10.4103/jispcd.JISPCD-92-19]
 4. Pindborg JJ, Sirsat SM. Oral submucous fibrosis. *Oral Surg Oral Med Oral Pathol* 1966 Dec;**22**(6):764-79. [DOI: 10.1016/0030-4220(66)90367-7]
 5. Duggirala T, Marthala M, Gannepalli A, Podduturi S. Oral submucous fibrosis in children: Report of three cases and review. *J Indian Acad Oral Med Radiol* 2015 Jan;**27**(1):105-11. [DOI: 10.4103/0972-1363.167127]
 6. Ranganathan K, Devi MU, Joshua E, Kirankumar K, Saraswathi TR. Oral submucous fibrosis: a case-control study in Chennai, South India. *J Oral Pathol Med* 2004 May;**33**(5):274-7. [DOI: 10.1111/j.0904-2512.2004.00116.x]
 7. Kariya P, Khobragade V, Sura S, Singh S. No age predilection for a disease like OSMF. A case report of a 5-year-old child. *J Oral Biol Craniofac Res* 2020 Apr-Jun;**10**(2):153-7. [DOI: 10.1016/j.jobcr.2020.03.010]
 8. Passi D, Bhanot P, Kacker D, Chahal D, Atri M, Panwar Y. Oral submucous fibrosis: Newer proposed classification with critical updates in pathogenesis and management strategies. *Natl J Maxillofac Surg* 2017 Jul-Dec;**8**(2):89-94. [DOI: 10.4103/njms.NJMS_32_17]
 9. Pindborg JJ. Is submucous fibrosis a precancerous condition in the oral cavity? *Int Dent J* 1972 Dec;**22**(4):474-80.
 10. Pindborg JJ, Zachariah J. Frequency of oral submucous fibrosis among 100 South Indians with oral cancer. *Bull World Health Organ* 1965;**32**(5):750-3.
 11. Pindborg JJ, Murti PR, Bhonsle RB, Gupta PC, Daftary DK, Mehta FS. Oral submucous fibrosis as a precancerous condition. *Scand J Dent Res* 1984 Jun;**92**(3):224-9. [DOI: 10.1111/j.1600-0722.1984.tb00883.x]
 12. Lai DR, Chen HR, Lin LM, Huang YL, Tsai CC. Clinical evaluation of different treatment methods for oral submucous fibrosis. A 10-year experience with 150 cases. *J Oral Pathol Med* 1995 Oct;**24**(9):402-6. [DOI: 10.1111/j.1600-0714.1995.tb01209.x]
 13. Maher R, Lee AJ, Warnakulasuriya KA, Lewis JA, Johnson NW. Role of areca nut in the causation of oral submucous fibrosis: a case-control study in Pakistan. *J Oral Pathol Med* 1994 Feb;**23**(2):65-9. [DOI: 10.1111/j.1600-0714.1994.tb00258.x.]
 14. Rai A, Datarkar A, Rai M. Is buccal fat pad a better option than a nasolabial flap for the reconstruction of intraoral defects after surgical release of fibrous bands in patients with oral submucous fibrosis? A pilot study: a protocol for the management of oral submucous fibrosis. *J Craniomaxillofac Surg* 2014 Jul;**42**(5): 111-6. [DOI: 10.1016/j.jcms.2013.07.006]
 15. Kamath VV. Surgical Interventions in Oral Submucous Fibrosis: A Systematic Analysis of the Literature. *J Maxillofac Oral Surg* 2015 Sep;**14**(3):521-31. [DOI: 10.1007/s12663-014-0639-3]