

Evaluation of the relationship between maxillary canine impaction with arch dimensions and maxillary sinus dimensions using Cone Beam Computed Tomography (CBCT)

Homa Farhadifard¹, Abbas Shokri², Maryam Salehzadeh³, Maryam Farhadian⁴,
Yousef Ahmadpour^{5*}

1. Department of Orthodontics, School of Dentistry, Dental Research Center, Hamadan University of Medical Sciences, Hamadan, Iran
2. Dental Implants Research Center, Department of Oral and Maxillofacial Radiology, School of Dentistry, Hamadan University of Medical Sciences, Hamadan, Iran.
3. Department of Orthodontics, School of Dentistry, Tabriz University of Medical Sciences, Tabriz, Iran.
4. Department of Biostatistics, School of Public Health and Research Center for Health Sciences, Hamadan University of Medical Sciences, Hamadan, Iran.
- 5- Department of Orthodontics, School of Dentistry, Kurdistan University of Medical Sciences, Sanandaj, Iran.

ABSTRACT

Background: We aimed to evaluate the morphology of maxilla and sinus dimensions in subjects with unilaterally and bilaterally impacted canine using cone beam computed tomography (CBCT) records.

Methods: CBCT records taken during 2020-2022 of 120 patients were obtained to investigate the relationship between impacted canine and maxillary morphology as well as sinus dimensions. The CBCT images were then divided into three groups: control, unilaterally canine impaction and bilaterally canine impaction. Then morphology-related variables (arch circumference, arch length, inter molar width, inter first premolar width, palatal depth, anterior posterior dimension of the right and left sinuses, and mediolateral dimension of the right and left sinuses) were analyzed and compared between groups. All measurements were done by Ondeman 3D dental software. Statistical analysis was carried out by SPSS software version 21 using one-way ANOVA.

Results: There were meaningful differences in patients with canine impaction compared with control group in arch circumference (P value= 0.004) and arch length (P value= 0.001), inter molar width (P value= 0.001), inter first premolar width (P value= 0.001), mediolateral dimension of the right (P value=0.001) and left (P value= 0.001) sinuses of maxilla. Furthermore, Palatal depth and anterior posterior dimension of the right and left sinuses did not show statistically significant difference between groups.

Conclusion: Canine impaction can considerably affect the morphology of maxillary and sinuses dimensions. Nevertheless, future studies are needed to determine the exact structural and molecular effects of the canine impaction on maxillary sinuses and neighboring tissues.

KEYWORDS

Tooth, Impacted; Maxillary sinus; Cone-Beam Computed Tomography

Please cite this paper as:

Farhadifard H, Shokri A, Salehzadeh M, Farhadian M, Ahmadpour Y. Evaluation of the relationship between maxillary canine impaction with arch dimensions and maxillary sinus dimensions using Cone Beam Computed Tomography (CBCT). *World J Plast Surg.* 2024;13(2):32-38.
doi: 10.61186/wjps.13.2.32

*Corresponding Author:

Yousef Ahmadpour

Department of Orthodontics,
School of Dentistry, Kurdistan
University of Medical Sciences,
Sanandaj, Iran

Email: chrika2020@gmail.com

Received: 4/10/2024

Accepted: 6/11/2024

INTRODUCTION

Impaction of permanent maxillary canine is a common problem in orthodontics. After third molar teeth, maxillary canine teeth are highly prone to be impacted, with an incidence rate of 1.1-13%¹⁻³. Impacted

teeth are referred to teeth that are not able to complete their eruption process in a timely manner⁴. Clinicians have different definitions regarding the term impaction⁵⁻⁹.

More exactly, from pathological perspectives, impacted teeth are remained embedded in oral mucosa or bone after their normal time of eruption. However, clinical definition of impaction is related to teeth that undergo ectopic eruption or teeth that induce root resorption of adjacent teeth, even before the normal eruption time span. The position of an impacted canine can be on palatal, labial or intra-alveolar sides, of which palatal location has the highest degree of prevalence^{10,11}.

The etiology of canine impaction still remains controversial. However, it has been suggested that local pathology, local hard tissue obstruction, departure from or disturbance of the normal development of the incisors, and genetic factors can be considered as the main causes of maxillary canine impaction¹².

The impacted maxillary canine is capable of disturbing adjacent teeth alignment, reducing dental arch length, inducing ankylosis, increasing dentigerous cyst formation and causing recurrent infections¹³. The maxillary canine impaction can affect the morphology of maxillary sinus, which is a bilateral air-filled chamber in the maxilla and the largest paranasal sinus¹⁴⁻¹⁶. More precisely, extraction of premolar and canines can lead to sinus pneumatization and/or expansion, mainly due to proximity of these teeth to maxillary sinuses¹⁷.

After clinical examination, orthodontists apply radiography in order to recognize the location of maxillary canine impaction¹⁸. In this regard, panoramic radiograph determines the existence of an impacted canine. However, three-dimensional (3D) cone-beam computed tomography (CBCT) can detect the exact location of the canine impaction^{19,20}. In addition, CBCT can help predict the link between the impacted canine and its surrounding teeth and other anatomical structures as well as identifying possible resorptions¹⁸.

Data on the effect of maxillary canine impaction on the morphology of maxilla have been revealed to be different among patients and thus are inconsistent. It is also important to note that, hitherto, there has been no study investigating simultaneous effect of maxillary canine impaction on the morphology of maxilla and dimensions of maxillary sinus.

Therefore, we aimed to Evaluate the relationship between maxillary canine impaction with arch dimensions and maxillary sinus dimensions using Cone Beam Computed Tomography (CBCT).

MATERIALS AND METHODS

Samples

CBCT recordings taken during 2020-2022, were collected from Radiology archive of the Hamadan University of Medical Sciences, Hamadan, Iran. These CBCT recordings have been provided with the use of CBCT instrument (Newtom 3G, Verona, Italy, Fov=12 inch, kVp=110, mA=1.6). A total of 120 CBCT scans were selected based on inclusion and exclusion criteria. The inclusion criteria included:

- 1) Canine has not erupted after more than one year since the eruption of the upper first and second molars (only for the group with unilateral and bilateral impaction)
- 2) CBCT radiographs should represent the whole maxillary arch
- 3) The patient must be at least 15 and at last 35 years old.

The exclusion criteria were as follows:

- 1) Patients with cysts, tumors, dental trauma or any lesions that may have obstructed canine growth
- 2) Patients with skeletal anomalies or systemic diseases
- 3) Patients with craniofacial anomalies
- 4) Patients with a history of undergoing orthodontic appliance or dental surgeries
- 5) Patients who have lost their teeth (except for central incisor).

Collected CBCT scans were divided into control (n = 40), unilateral palatal impacted canine (n = 40) and bilateral palatal impacted canine (n = 40) groups. Then nine variables including arch circumference and arch length, inter molar width, inter first premolar width, palatal depth, anterior posterior dimension of right and left sinus, and mediolateral dimension of right and left sinus were compared among three groups. Furthermore, all measurements are measured by Ondeman 3D dental software (Cybermed, Seoul, Korea), the unit of measurement is millimeter.

The variables were measured in the following way:

Arch circumference: In the axial view, from the mesial contact point of first molar on the arch to the mesial contact point of first molar on the opposite

side (Figure 1)

Inter first premolar width: In the axial view, transversely from the buccal cusp of the first premolar to the buccal cusp of the first premolar on the opposite side (Figure 1)

Inter molar width: In the axial view, transversely from the mesiobuccal cusp of the first molar on one side to the mesiobuccal cusp of the first molar on the opposite side (Figure 1)

Arch length: In axial view, longitudinally from the contact point of the centrals to the line that defines the inter molar width (Figure 1)

Palatal depth: In the coronal view, a line was

extended from the tip of the mesiopalatal cusp of first molar on one side to the mesiopalatal cusp of first molar on the opposite side. It was measured from the deepest point of the palate to the connecting line of the cusps (Figure 2)

Mediolateral and anterior posterior dimension of maxillary sinus: In the axial view, the largest dimensions of the sinus was measured from the anterior posterior and medial-lateral view (Figure 3)

Ethical statement: This study was reviewed and approved by the ethics committee of Hamadan University of Medical Sciences (IR.UMSHA.REC.1399.588).

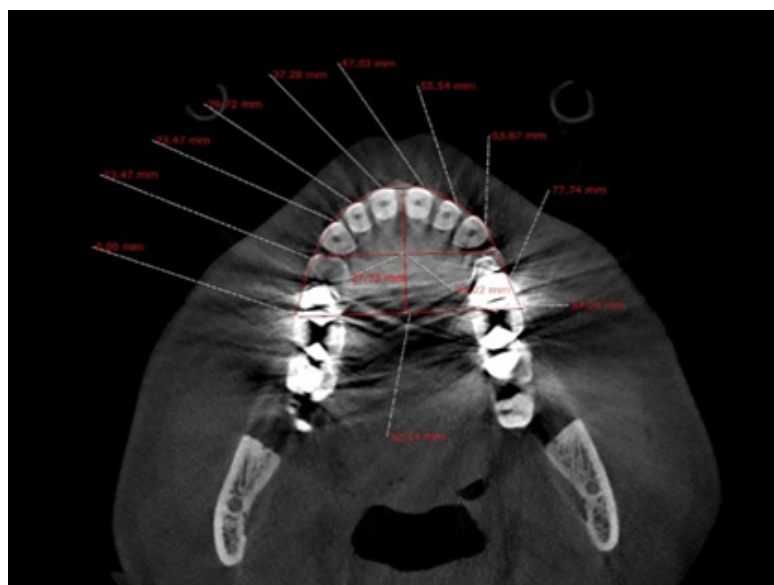


Fig. 1. Measurement of Arch circumference, inter first premolar width, Inter molar width and Arch length

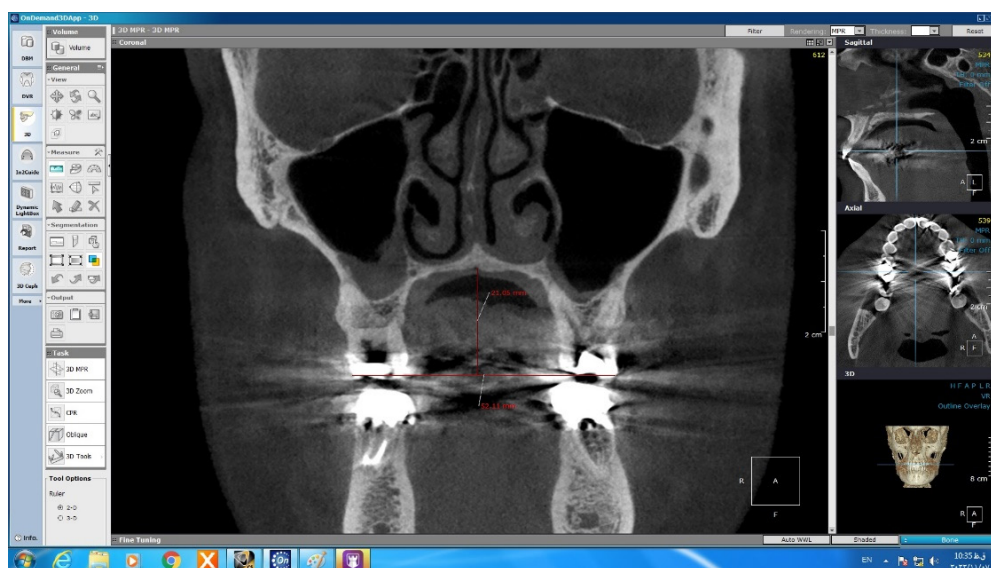


Fig. 2. Measurement of palatal depth

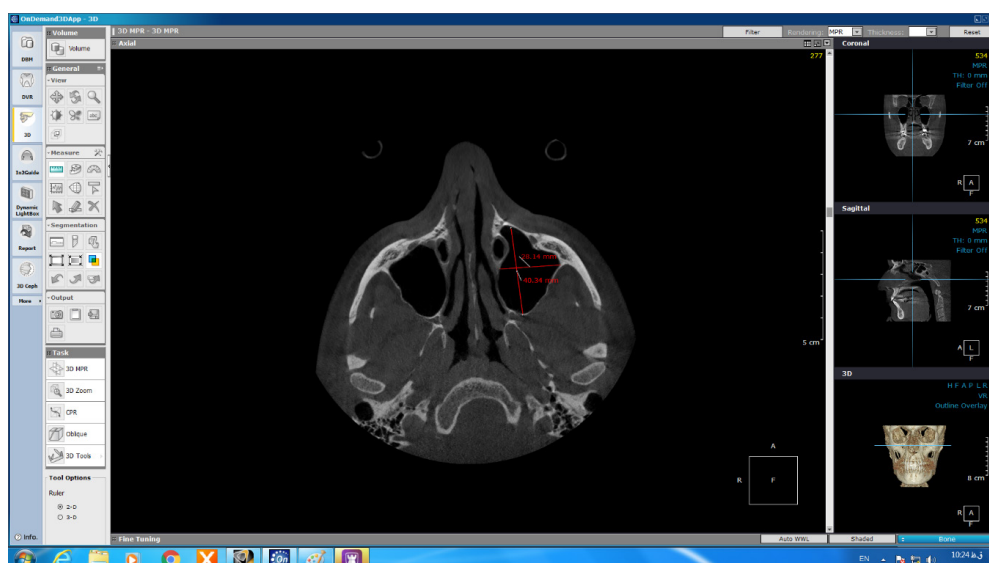

Fig. 3. Measurement of mediolateral and anterior posterior dimension of maxillary sinus

Table 1: Descriptive analysis of maxillary sinus-related variables.

Variable	Position	Number	Average	Standard deviation	Confidence interval 95%		Minimum	Maximum
					Lower range	Upper range		
arch circumference	One side	40	81.36	4.73	79.84	82.87	71.42	92.57
	Two side	40	76.55	5.28	74.86	78.24	67.70	85.50
	Control	40	80.12	4.21	78.77	81.46	67.14	89.22
inter molar width	One side	40	50.97	3.14	49.97	51.97	4.72	57.31
	Two side	40	49.04	3.28	47.99	50.09	42.80	58.25
inter first premolar width	One side	40	3.91	3.04	38.94	40.88	32.58	44.80
	Two side	40	37.32	3.59	36.17	38.47	31.42	45.12
Arch length	One side	40	42.08	2.18	41.38	42.77	37.62	49.07
	Two side	40	25.49	2.35	24.74	26.25	20.17	30.75
	Control	40	23.62	3.07	22.64	24.60	16.46	29.45
palatal depth	One side	40	24.88	2.05	24.22	25.54	18.24	28.30
	Two side	40	19.17	2.75	18.29	20.05	12.40	25.63
	Control	40	24.04	28.49	14.93	33.16	13.14	198.83
anterior posterior dimension of right sinus	One side	40	21.35	2.79	20.46	22.24	13.0	25.0
	Two sides	40	31.61	3.41	30.52	32.70	20.56	36.84
	Control	40	31.04	4.19	29.69	32.38	17.33	36.30
medial lateral dimension of right sinus	One side	40	31.29	4.03	29.99	32.57	13.59	39.30
	Two sides	40	21.42	3.60	20.27	22.57	13.85	31.0
	Control	40	21.09	3.11	20.09	22.08	15.34	27.68
medial lateral dimension of left sinus	One side	40	24.06	3.08	23.07	25.04	14.56	28.80
	Two sides	40	31.54	3.51	30.41	32.66	21.59	36.35
	Control	40	32.34	2.57	31.52	33.16	26.31	35.93
anterior posterior dimension of left sinus	One side	40	33.39	3.59	32.24	34.54	17.49	38.23
	Two sides	40	20.49	4.33	19.09	21.83	12.67	31.39
	Control	40	20.31	3.28	19.26	21.36	15.20	27.20
		40	22.98	2.52	22.17	23.80	12.75	27.18

Table 2: Comparison of dependent variables between unilateral and bilateral impacted canines.

Variable	Position	Sum of quarters	Degrees of freedom	Mean squared	F ratio	P value
arch circumference	Between groups	497.907	2	248.953	10.991	0.001
	In groups	2650.157	117	22.651		
	Total	3148.064	119			
inter molar width	Between groups	160.430	2	80.215	7.678	0.001
	In groups	1222.395	117	10.448		
	Total	1382.825	119			
inter first premolar width	Between groups	453.509	2	226.755	25.281	0.001
	In groups	1049.433	117	8.970		
	Total	1502.943	119			
arch length	Between groups	72.773	2	36.386	5.701	0.004
	In groups	746.712	117	6.382		
	Total	819.485	119			
Palatal depth	Between groups	477.293	2	238.646	0.865	0.424
	In groups	32264.753	117	275.767		
	Total	32742.046	119			
anterior posterior dimension of right sinus	Between groups	6.615	2	3.308	0.218	0.804
	In groups	1775.609	117	15.176		
	Total	1785.224	119			
medial lateral dimension of right sinus	Between groups	211.588	2	105.794	9.866	0.001
	In groups	1254.626	117	10.723		
	Total	1466.214	119			
anterior posterior dimension of left sinus	Between groups	69.499	2	34.749	3.271	0.041
	In groups	1243.110	117	10.625		
	Total	1312.609	119			
medial lateral dimension of left sinus	Between groups	178.313	2	89.157	7.39	0.001
	In groups	1411.567	117	12.065		
	Total	1589.881	119			

Statistical analysis

Statistical analysis was carried out by SPSS software version 21 (IBM Corp., Armonk, NY, USA) using one-way ANOVA. All data were expressed as mean \pm SD. *P* values less than 0.05 were considered as statistically significant.

RESULTS

Descriptive analysis of all study groups has been summarized in Table 1.

Moreover, comparison analysis between study variables have been represented in Table 2. The information provided in this table indicate that both arch circumference and arch length, inter molar width and inter first premolar width were remarkably different between unilaterally and bilaterally canine impaction groups. Comparison between bilaterally impacted canine and control subjects showed statistically significant results for arch length, intermolar width and inter first

premolar width variables. Among these variables, inter first premolar width was revealed to be notably different between unilaterally canine impaction and control groups ($P < .004$). In addition, palatal depth and anterior posterior of right side sinus showed no significant difference in all studied groups. Paired comparison between all groups revealed that mediolateral dimension of right and left side sinuses are remarkably different between unilateral impacted canine and control as well as bilateral impacted canine and control groups.

DISCUSSION

This study was designed to determine the relationship between maxillary impacted canine with the width and depth of the palate and maxillary sinus dimensions using cone beam computed tomography.

Over the past years, CBCT has gained importance as a reliable diagnostic method, due to its high level

of precision in angular and linear measurements²¹. Lateral cephalometric radiographs pose many disadvantages, of which it can be mentioned that images driven from these radiographs might be different from the actual size. Moreover, neighboring structures superimpose boundaries of the maxillary sinus, which is specially occurred in the deeper areas of nasomaxillary complex²².

Intriguingly, CBCT represents more accurate measurement of maxillary sinus volume with smaller radiation doses and lower cost than computed tomography magnetic resonance imaging technique²³. Hence, CBCT recordings were used in this study to evaluate the relationship between canine impaction and maxillary sinus morphology. In the present study, arch circumference and arch length, inter molar width, inter first premolar width, mediolateral dimension of right and left side sinuses, were significantly different in unilateral and bilateral samples with canine impaction as well as control group. These findings indicate that canine impaction and its location can have a remarkable effect on the morphology of maxilla. Our results further support the idea of Kim et al. who demonstrated that in patients with palatally impacted canine, the palatal vault is deep and the shape of maxillary arch is narrow and long²⁴. Findings of this study are also in consistent with previous studies, which reported that canine impaction affects the volume of maxillary sinus^{14, 25}.

Another important finding was that the arch circumference and intermolar width of maxilla are significantly different between patients with unilaterally and bilaterally impacted canine. In accordance with these results, arch circumference was wider in the impaction side²⁶. also, another study showed decreased intermolar width and arch circumference in impacted maxillary canine²⁷. Herein, both arch circumference and intermolar of maxilla were found to be remarkably different between bilaterally impacted canine and control groups. However, we observed no statistically significant difference between unilateral impacted canine samples and control group. Thus, it can be interpreted that bilaterally impacted canine might have stronger impacts on the maxillary sinus. Moreover, we found that mediolateral dimension of right and left sides of sinus in unilaterally and bilaterally impacted canines are significantly different as compared with control samples.

One of our interesting findings was significant changes of inter first premolar width among all groups, indicating that either unilateral or bilateral canine impaction can considerably affect this variable in the maxilla.

In this study, arch circumference in unilateral canine impaction samples were significantly different from control group, which means that for these particular variables, the side of canine impaction can be determinant factor contributing to changes in maxillary morphology.

CONCLUSION

Returning to the hypothesis posed at the beginning of the present study, it is now possible to state that canine impaction can structurally and morphologically impact surrounding maxilla. Impacted canine can alter arch circumference and arch length, inter molar width and mediolateral dimension of maxillary sinus. However, future studies are needed to determine the exact structural and molecular effects of the canine impaction on maxillary sinuses and neighboring tissues.

ACKNOWLEDGEMENT

The current study was financially supported by Hamadan University of Medical Sciences (grant number: 9910026704).

CONFLICT OF INTEREST

All authors declare that they have no potential personal or financial conflict of interest.

REFERENCES

1. Ajami S, Shahidi S, Azadeh N, Naser Jalali H, Zare M. Difficulty of palatal impacted canine treatment in different sagittal and vertical skeletal malocclusions: a retrospective 3D evaluation. *Int Orthod* 2020; 18(1):89-95. doi: 10.1016/j.ortho.2019.11.001.
2. Dalessandri D, Migliorati M, Visconti L, Contardo L, How Kau C, Martin C. KPG index versus OPG measurements: a comparison between 3D and 2D methods in predicting treatment duration and difficulty level for patients with impacted maxillary canines. *Biomed Res Int* 2014;2014:537620. doi: 10.1155/2014/537620.
3. Sunil G, Ranganayakulu L, Ranghu Ram R. Maxillary

- canine impaction-A hitch in orthodontic treatment planning. *IAIM*, 2018; 5(6): 72-76.
4. Lai C S, Bornstein M M, Mock L, Heuberger B M, Dietrich T, Katsaros C. Impacted maxillary canines and root resorptions of neighbouring teeth: a radiographic analysis using cone-beam computed tomography. *Eur J Orthod* 2013;35(4):529-38. doi: 10.1093/ejo/cjs037.
 5. Andreasen J O, Peterson J, Laskin D M. Textbook and color atlas of tooth impactions: Diagnosis, Treatment, Prevention. Elsevier - Health Sciences Division, 1997. pp:354
 6. Becker A. The orthodontic treatment of impacted teeth. Wiley,1998.
 7. Abron A, Mendro R, Kaplan S. Impacted permanent maxillary canines. *N Y State Dent J*. 2004;70(9):24-8.
 8. Mason C, Papadakou P, Roberts G J. The radiographic localization of impacted maxillary canines: a comparison of methods. *Eur J Orthod* 2001;23(1):25-34. doi: 10.1093/ejo/23.1.25.
 9. Lindauer S J, Rubenstein L K, Hang W M, Andersen W C, Isaacson R J. Canine impaction identified early with panoramic radiographs. doi: 10.14219/jada.archive.1992.0069.
 10. Thilander B Myrberg N. The prevalence of malocclusion in Swedish schoolchildren. *Scand J Dent Res*. 1973;81(1):12-21. doi: 10.1111/j.1600-0722.1973.tb01489.x.
 11. Ericson S Kurol J. Resorption of incisors after ectopic eruption of maxillary canines: a CT study. *Angle Orthod* 2000;70(6):415-23. doi: 10.1043/0003-3219(2000)070<0415:ROIAEE>2.0.CO;2.
 12. Becker A Chaushu S. Etiology of maxillary canine impaction: A review. *Am J Orthod Dentofacial Orthop* 2015;148(4):557-67. doi: 10.1016/j.ajodo.2015.06.013.
 13. Alqerban A, Jacobs R, Lambrechts P, Loozen G, Willems G. Root resorption of the maxillary lateral incisor caused by impacted canine: a literature review. *Clin Oral Investig* 2009;13(3):247-55. doi: 10.1007/s00784-009-0262-8.
 14. Oz A Z., Oz A A, EL H, Palomo J M. Maxillary sinus volume in patients with impacted canines. *Angle Orthod* 2017;87(1):25-32. doi: 10.2319/122915-895.1.
 15. Emirzeoglu M, Sahin B, Bilgic S, Celebi M, Uzun A. Volumetric evaluation of the paranasal sinuses in normal subjects using computer tomography images: a stereological study. *Auris Nasus Larynx* 2007;34(2):191-5. doi: 10.1016/j.anl.2006.09.003.
 16. Endo T, Abe R, Kuroki H, Kojima K, Oka K, Shimooka S. Cephalometric evaluation of maxillary sinus sizes in different malocclusion classes. *Odontology* 2010;98(1):65-72. doi: 10.1007/s10266-009-0108-5.
 17. Sharan A, Madjar D. Maxillary sinus pneumatization following extractions: a radiographic study. *Int J Oral Maxillofac Implants* 2008 Jan-Feb;23(1):48-56.
 18. El H, Stefanovic N, Palomo J M, Palomo L. Strategies for Managing the Risk of Mucogingival Changes During Impacted Maxillary Canine Treatment. *Turk J Orthod* 2020;33(2):123-132. doi: 10.5152/TurkJOrthod.2020.20038. eCollection 2020 Jun.
 19. Ba K D, Diouf J S, Badiane A, Ngom P I, Diagne F. Orthopantomographic analysis of the intraosseous position of the maxillary canines. *Int Orthod* 2019;17(2):324-332. doi: 10.1016/j.ortho.2019.03.015. Epub 2019 Apr 12.
 20. Grybieniė V, Juozėnaitė D, Kubiliūtė K. Diagnostic methods and treatment strategies of impacted maxillary canines: A literature review. *Stomatologija* 2019;21(1):3-12.
 21. Tadinada A, Mahdian M, Vishwanath M, Allareddy V, Upadhyay M, Yadav S. Evaluation of alveolar bone dimensions in unilateral palatally impacted canine: a cone-beam computed tomographic analyses. *Eur J Orthod* 2015;37(6):596-602. doi: 10.1093/ejo/cju098.
 22. Baumgaertel SPalomo J M, Palomo L, Hans M G. Reliability and accuracy of cone-beam computed tomography dental measurements. *Am J Orthod Dentofacial Orthop* 2009;136(1):19-25; discussion 25-8. doi: 10.1016/j.ajodo.2007.09.016.
 23. Saccucci M, Cipriani F, Carderi S, Di Carlo G, D'Attilio M, Rodolfo D, Festa F. A *Polimeni* Gender assessment through three-dimensional analysis of maxillary sinuses by means of cone beam computed tomography. *Eur Rev Med Pharmacol Sci* 2015;19(2):185-93.
 24. Kim Y, K. Hyun H-K, Jang K-T. Interrelationship between the position of impacted maxillary canines and the morphology of the maxilla. *Am J Orthod Dentofacial Orthop* 2012;141(5):556-62. doi: 10.1016/j.ajodo.2011.11.015
 25. Mohamed Elmarhoumy S, Safwat W, Ellaithy M. Cone-Beam Computed Tomography Evaluation of Maxillary Sinus Volume In Patients With Unilaterally Maxillary Impacted Canines. *Egyptian Dental Journal* 2022; 68(2): 1165-1170. DOI: 10.21608/edj.2022.111105.1911
 26. Al-Nimri K , Gharaibeh T. Space conditions and dental and occlusal features in patients with palatally impacted maxillary canines: an aetiological study. *Eur J Orthod* 2005;27(5):461-5. doi: 10.1093/ejo/cji022.
 27. Cacciatore G, Poletti L, Sforza C. Early diagnosed impacted maxillary canines and the morphology of the maxilla: a three-dimensional study. *Prog Orthod* 2018;19(1):20. doi: 10.1186/s40510-018-0220-6