

Improved Neurotization in High Peripheral Nerve Injury: Side to Side H-shaped Nerve Graft at the Most Distal Part of an Injured Extremity in a Rabbit Model

Naser Mozafari¹, Masoud Yavari¹, Arian Karimi Rouzbahani^{2,3}, Mohammad Ali Mozafari⁴, Alireza Mozafari⁵, Siavash Beiranvand⁶, Hormoz Mahmoudvand^{3,7*}

1. Department of Plastic Surgery, School of Medicine, Panzdahe Khordad Hospital, Shahid Beheshti University of Medical Sciences, Tehran, Iran
2. Student Research Committee, Lorestan University of Medical Sciences, Khorramabad, Iran.
3. USERN Office, Lorestan University of Medical Sciences, Khorramabad, Iran
4. Corewell Health East, Dearborn, Michigan, USA.
5. Shahid Beheshti University, Daneshjoo Blvd, Tehran, Iran.
6. Department of Anesthesiology, School of Medicine, Lorestan University of Medical Sciences, Khorramabad, Iran.
7. Department of Surgery, School of Medicine, Lorestan University of Medical Sciences, Khorramabad, Iran.

*Corresponding Author:

Dr Hormoz Mahmoudvand

Department of Surgery, School of Medicine, Lorestan University of Medical Sciences, Khorramabad, Iran.

Email: dr.mahmoudvand@gmail.com

Received: 2/4/2024

Accepted: 6/29/2024

ABSTRACT

Background: We aimed to investigate the effects of nerve repair by setting a side-to-side (H-shaped) nerve graft on the most distal part of the damaged nerve to the adjacent intact nerve to accelerate its regeneration in the end organ.

Methods: This pure experimental study was done on the lower extremities of two groups of rabbits in Animal Laboratory Department, 15 Khordad Hospital Tehran, Iran. In both groups, the sciatic nerve at the proximal part of the extremity below the superficial femoral branch was first cut and then repaired. In the investigation group, side-to-side H-shaped nerve grafts were applied between the sciatic and superficial femoral nerves (i.e., two branches) at the most distal to the cut site of the sciatic nerve below the superficial femoral branch at the lower extremity. The sciatic nerve was conventionally repaired in the control group.

Results: None of the rabbits' feet in the control group respond to pain stimulation (were without senses) and had ulcers. They had numb legs and went lame. All had muscular atrophy and lacked nerve growth (regeneration) according to pathology. In the investigation group, 86.7% of the rabbits responded to pain stimulation and only 13.3% of them had ulcers. In addition, in pathology report, 13.3% had suffered muscular atrophy and lacked nerve regeneration. Therefore, nerve regeneration was successful in 86.7% of rabbits who underwent H-shaped nerve grafts.

Conclusion: Side-to-side H-shaped nerve graft at the most distal part of an injured nerve may cause successful recovery of high (proximal) nerve injury.

KEYWORDS

High Nerve Injury; H graft; Side-to-Side Anastomosis; Muscle Atrophy; Sciatic Nerve

Please cite this paper as:

Mozafari N, Yavari M, Karimi Rouzbahani A, Mozafari MA, Mozafari A, Beiranvand S, Mahmoudvand H. Improved Neurotization in High Peripheral Nerve Injury: Side to Side H-shaped Nerve Graft at the Most Distal Part of an Injured Extremity in a Rabbit Model. *World J Plast Surg.* 2024;13(2):50-57.

doi: 10.61186/wjps.13.2.50

INTRODUCTION

Nerve damage because of daily activities can strongly influence the functions of patients. It may cause drastic changes in a person's life or possibly lead to disability and permanent loss of job. Furthermore, this can have a heavy burden on the healthcare system of a country ^{1,2}. Most

nerve damages are in the upper extremities. The annual incidence of hand injuries is estimated to be 7 to 37 per 1000 individuals³.

Damage to the peripheral nerves in the proximal part of an organ may cause severe consequences. Such injuries usually occur to the workers, leading to disability and loss of job. If the nerve repair happens over a long period, the muscles of the organ will atrophy, after which even a successful nerve repair would not be helpful to restore the organ's function. Therefore, decreasing the time of nerve regeneration can be effective and lessen the socioeconomic costs of nerve damage in the hands⁴⁻⁶.

Nerve fibers distal to the site of injury degenerate after a peripheral nerve is injured. When the nerves are repaired proximally, they start to regenerate 1-3 mm per day until they reach the end organs. In the case of motor nerves, there is a chance of muscle atrophy until nerve fibers are completely regenerated to reach the end organ. This process becomes more important when the end organ is far from the place of nerve injury. For example, in the damage to the sciatic nerve in the thigh, the nerve fibers will take a long time to reach the small foot muscles and this can cause muscle atrophy⁷⁻¹⁰.

So far, the results of repairing the sciatic nerve in the calf and thigh have been disappointing. If the process time is reduced or the nerve regeneration occurs faster, better results can be achieved. One way is to start the nerve repair process from a point nearer to the end organ. For instance, nerve anastomosis can be done near the end organ. In case of proximal lesions of the sciatic nerve, below the superficial femoral nerve side-to-side (H-shaped) graft repair between the sciatic nerve and superficial femoral nerve in the thigh has been done¹¹⁻¹⁴.

We aimed to investigate the effects of nerve repair with a side-to-side H-shaped nerve graft on the most distal part of the damaged nerve to accelerate nerve regeneration in the cut at the proximal of the sciatic nerve. This work has been conducted and written in line with the ARRIVE guidelines 2.0¹⁵.

METHODS

Animals and study design

This study was done in Animal Laboratory Department, 15 Khordad Hospital, Shahid Beheshti University of Medical Sciences, Tehran, Iran in 2015

year on thirty mature New Zealand White male rabbits (mean age, 20 weeks; weight, 1.5-2.0 kg). Of these, fifteen rabbits were allocated to the nerve-graft groups. Nerve grafting was performed on one hindlimb. The remaining fifteen rabbits were allocated to the nerve repair and control groups. Nerve repair was performed on one side, which was only incision and the repairing sciatic nerve, and no surgical procedure was performed on the contralateral side. The animals were housed individually with a 12 h light-dark cycle, and food and water were provided ad libitum. Prior to the surgical procedures, the rabbits were anesthetized with intramuscular zoletil (10 mg/kg body weight) and xylazine (10 mg/kg body weight). After surgery, pain was managed with meloxicam (0.2 mg/kg body weight).

The inclusion criterion was intact clinical and immune status. Rabbits were excluded if they had previous surgical procedures. Randomization was done with random allocation software. The study protocol was approved by the Ethical Committee of Shahid Beheshti University of Medical Sciences in Tehran with ID IR.SBMU.RAM.REC.1394.439.

Nerve grafting and Nerve repairing

The main researcher was aware of the group allocation in different stages of the study. In the control group, nerve repair was done conventionally after cutting the sciatic nerve. The repair was done with 10.0 nylon string under a microscope. In the investigation group, two nerve grafts were coaptated side to side in the most distal part of the anastomosis area between the sciatic and superficial femoral nerves (Figs. 1 and 2).

After sciatic nerve transection below the superficial femoral nerve in the control group, nerve repair was done conventionally. In the investigation group, in addition to nerve repair at the site of injury, two strained side-to-side nerve grafts were repaired between the sciatic and superficial femoral nerves with 10.0 nylon strings (Fig. 3-6). Epineurotomy and partial axonotomy were done at the site of H shape nerve graft. One end of the graft was anastomosed to the side of the sciatic nerve and the other to the side of the superficial femoral nerve (Fig. 5).

The post-operative care was the same for all rabbits to minimize potential confounders.

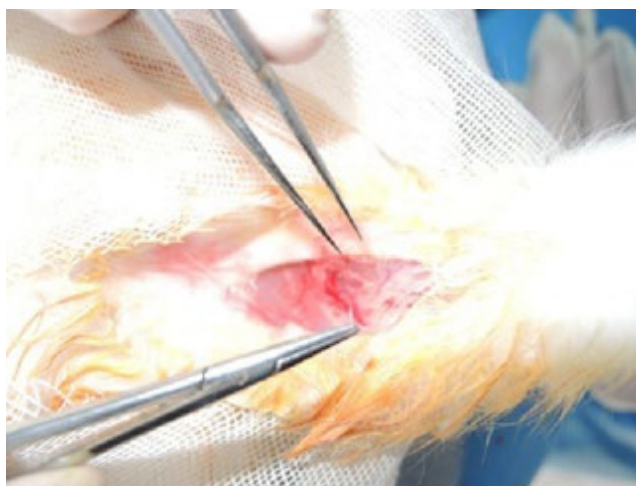


Figure 1: The sciatic and superficial femoral nerves and their anatomical care

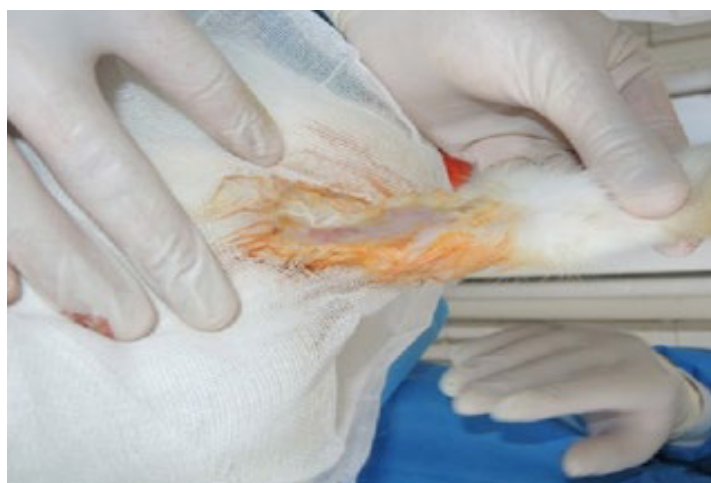


Figure 2: H-shaped anastomosis between sciatic and superficial femoral nerves with 10.0 nylon string under microscope.

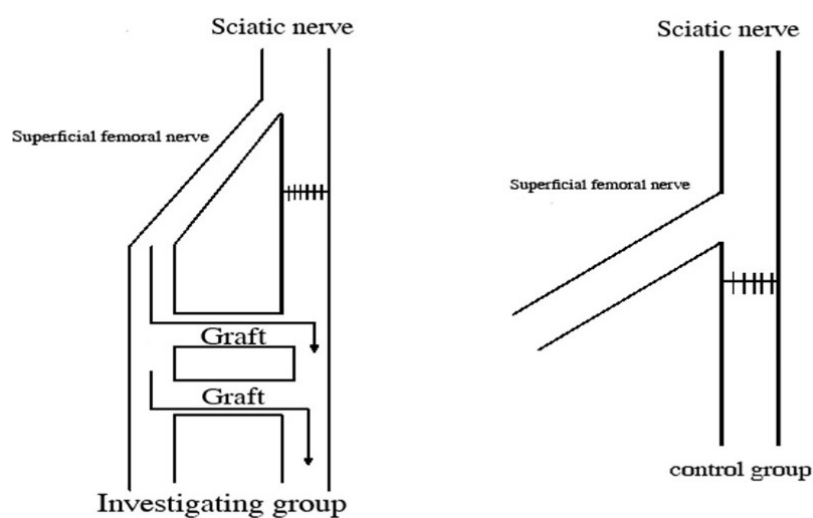


Figure 3: Visual explanation of the H-shaped nerve graft in investigation and control group

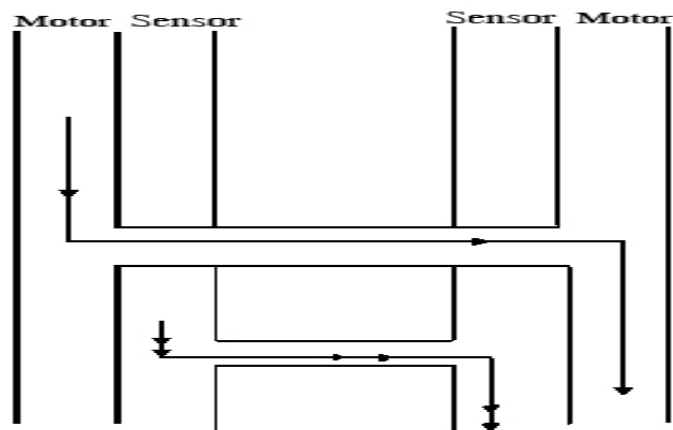


Figure 4: Visual explanation of the side-to-side nerve graft (one anastomosis motor to motor branch and the other sensory to sensory part)

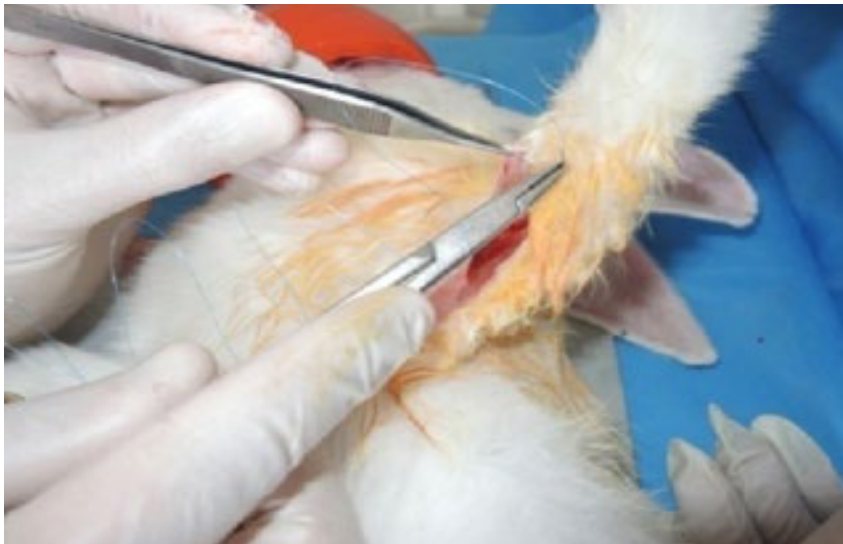

Figure 5: Treating the repaired area with 4.0 nylon string and dressing

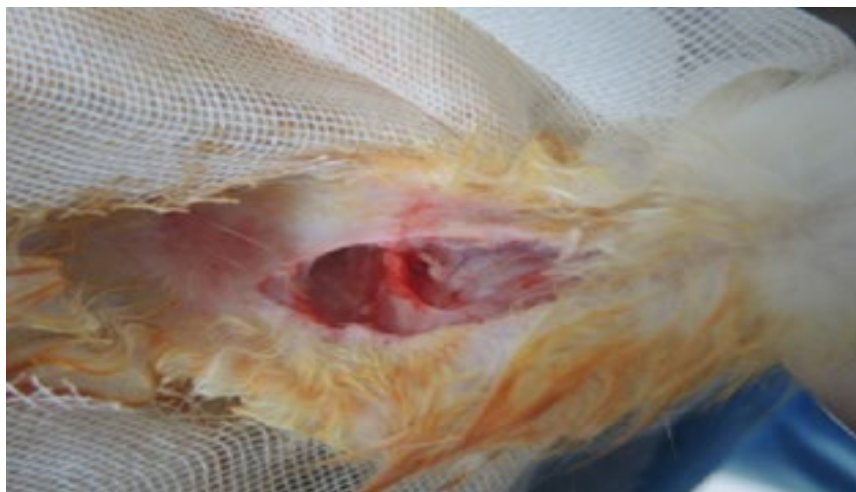


Figure 6: Side to side H-shaped nerve graft anastomosis

Pathology

After three months, the rabbits were physically examined and biopsies were taken from the muscles and nerves. Biopsy was taken from the H-shaped part and was examined by a pathologist from another hospital who was blind to the study group. Pain sensation was evaluated with a pain stimulation device. Having an ulcer was determined based on direct observation (Fig. 7). The existence of muscle atrophy or nerve regeneration was determined by muscle and nerve biopsy. In the nerve biopsy, the H-shaped part was sent in one block.

No rabbit was excluded from the study and data was collected and analyzed from all 30 rabbits in investigation and control groups.

RESULTS

The quantitative results were assessed with student t-test and qualitative results with Fisher's exact test. Parameters such as pain, ulcer, nerve regeneration,

and muscle atrophy were evaluated in both groups. The H-shaped nerve part was sent to the pathology laboratory as a single block. All of the rabbit feet in the control group did not respond to pain stimulation (were without senses) and had ulcers (Fig. 7).

They had numb legs and went lame. All had muscular atrophy and lacked nerve growth (regeneration) according to pathology. In the investigation group, 86.7% of the rabbits responded to pain stimulation and only 13.3% of them had ulcers. In addition, in pathology report, 13.3% had suffered muscular atrophy and lacked nerve regeneration. Therefore, nerve regeneration was successful in 86.7% of rabbits who underwent H-shaped nerve grafts (Table 1).

The muscle biopsies were done in both groups and the pathologist reported that in the investigation group, there was not any muscle atrophy but the other group illustrated muscle atrophy (Fig. 8). The pathologist reported that cells grew in two grafted branches and the sciatic nerve showing that nerve regeneration had happened (Fig. 9).

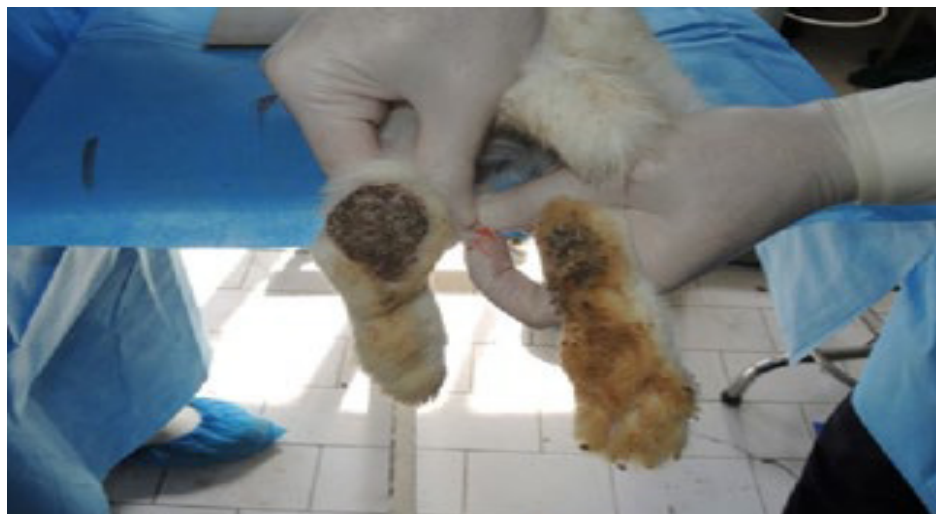

Figure 7: Ulcer in the extremities of the rabbits in the control group

Table 1: Results in control and investigation groups

Group	Physical exam				Pathology report			
	Pain		Ulcer		Nerve regeneration		Muscle atrophy	
	No	Yes	No	Yes	No	Yes	No	Yes
Control	15 100.0%	0 0%	0 0%	15 100.0%	15 100.0%	0 0%	0 0%	15 100.0%
Investigation	2 13.3%	13 86.7%	13 86.7%	2 13.3%	2 13.3%	13 86.7%	13 86.7%	2 13.3%

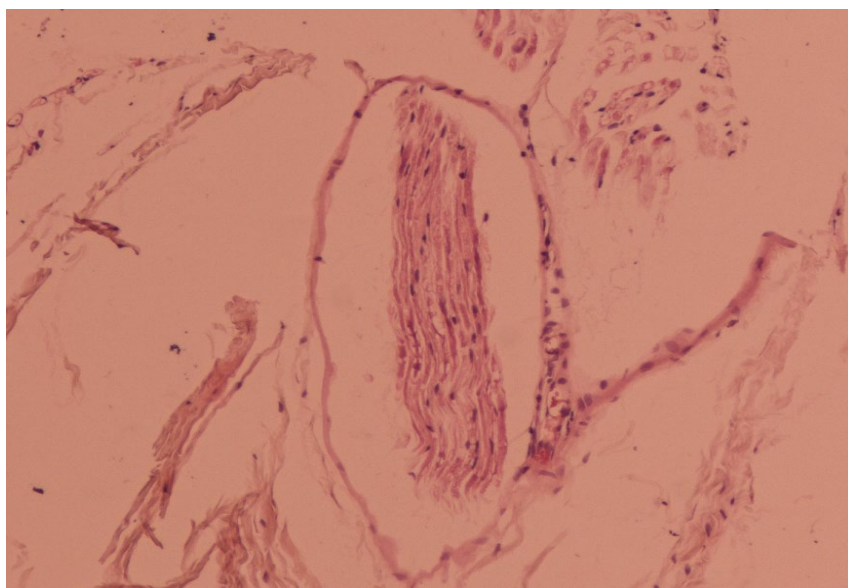


Figure 8: Rabbit nerve. Normal nerve fibers consisting of Schwann cells are seen with a non-inflammatory wave nucleus with a natural appearance attached to the muscle fascia

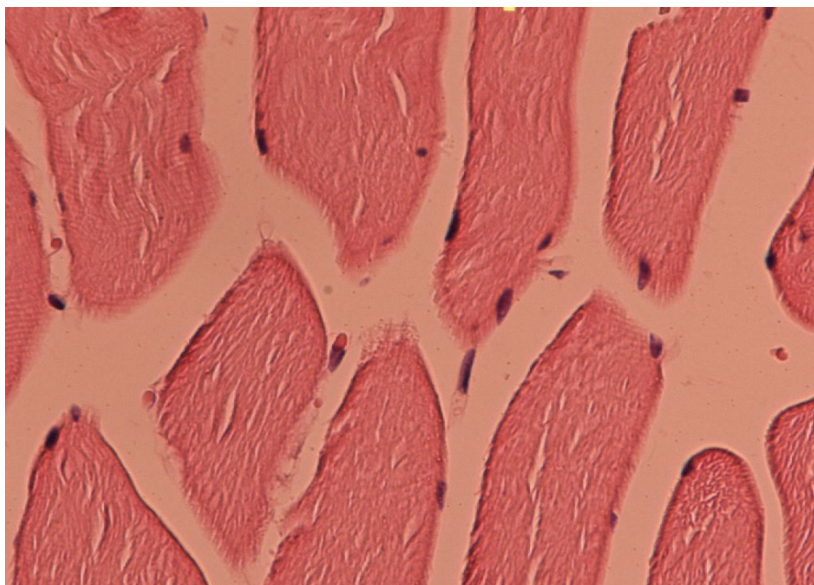


Figure 9: Rabbit muscle. A large number of striated muscle cells with a normal cytoplasmic and nuclear appearance are seen. The nuclei in the cytoplasm under the cell membrane and the cytoplasm have Zan (cross striation) lines. There are no inflammatory or neoplastic changes

DISCUSSION

Cut or damage of peripheral nerve at proximal of extremity has had poor results even after nerve repair. Since the nerve growth speed is limited, the chance of muscular atrophy is high. Protection of muscular function at distal parts of the extremities with bypassing technique using nerve graft can

accelerate recovery. Neurotransmission from an intact nerve adjacent to the damaged nerve using two-strand sural nerve grafts can help to bypass and shorten neurotization to the distal muscle^{1-3, 16, 17}. A previous work has introduced different surgical techniques¹⁸. However, in high-level damages, the conventional techniques lead to poor outcomes because of the long time it takes axons to grow the

end organs. In these cases, even in a successful nerve repair, the nerve reaches the end organ when the muscle has atrophied^{19,20}.

The conventional methods are also challenging regarding injuries with long nerve deficits and the unavailability of proximal nerve stump²⁰. If a method can accelerate regeneration and decrease the time which nerve reaches the end organ, it can maintain muscle function and prevent ulcers and senses disruption^{21,22}. In this pre-clinical study, H-shaped graft technique using a side-to-side Cable nerve graft was applied for the first time on sciatic and femoral nerves. This technique is beneficial in cases in which the end organ is distant from the damaged or cut nerve area. In our study, the nerve was grafted with two strands of the sural nerve between the intact and injured nerves. All of the rabbits in our study that underwent primary nerve repair in the control group suffered from disruption in senses and motion and had ulcers. Based on pathology results (including muscle biopsy from the target organ and injured nerve), all had muscle atrophy and nerve degeneration. However, in the investigation group in which an H-shaped nerve graft was done, 86.7% of rabbits responded to pain stimulation and did not have ulcers. In this group, muscle biopsy showed no muscular atrophy and nerve biopsy showed growth of nerve cells in the grafted branches. Hence, side-to-side nerve graft cells will enhance nerve regeneration. Previous studies have shown similar results^{20,23}. Rönkkö used distal side-to-side neurorrhaphy on the common peroneal and the tibial nerve in 176 rats. This technique decreased muscle atrophy and improved the morphometric and functional results²⁰. Although in our research different animals and nerves were studied, the results were mainly similar to Rönkkö's²⁰. Zhang et al. also investigated the outcomes of side-to-side neurorrhaphy in 25 patients with different types of high-level peripheral nerve injuries. This method improved sensory and motor nerve function and was suggested as a promising method for treatment of high-level peripheral nerve damages²³. This study confirms our findings on a clinical level. Other surgical techniques have also been applied previously and have been associated with different outcomes. End-to-side and side-to-end neurorrhaphy were suggested by Viterbo et al. as techniques to avoid using a donor nerve²⁴. End-to-side and side-to-end neurorrhaphy are considered

as good techniques by many surgeons, however, there is a consensus on the supremacy of end-to-end technique over both these methods²⁵. Hai – Fei Liu et al. reported the Babysitter procedure that improves nerve regeneration²⁶. The current study strongly supports the concept that distal side-to-side H – shaped nerve graft is a prompt and effective strategy for promoting nerve reinnervation and precluded denervated muscle atrophy. However, there are some limitations to the side-to-side nerve graft technique. First, there must be a normal donor nerve adjacent to the injured nerve. Furthermore, the surgical team should have an advanced anatomical knowledge of peripheral nerve to perform this procedure.

CONCLUSION

In patients with proximal peripheral nerve damage who have been repaired with end-to-end anastomosis, especially in sciatic and superficial femoral nerves, results of pain stimulation, ulcer, muscle atrophy, and nerve regeneration have been disappointing. However, this new side-to-side H-shaped nerve graft technique at the distal of the injured area seems to have much better results regarding pain stimulation, nerve regeneration, lack of ulcer, and muscular atrophy. It is recommended that the side-to-side H-shaped nerve graft be studied on human in upper and lower extremities in future clinical trials.

ACKNOWLEDGMENTS

The authors express their gratitude to the Animal Laboratory of Shahid Beheshti University of Medical Sciences and all the people who collaborated in this research.

CONFLICT OF INTEREST

The authors attest that they have no conflict of interest to disclose.

REFERENCES

1. Larsson L, Degens H, Li M, et al. Sarcopenia: aging-related loss of muscle mass and function. *Physiol Rev* 2019;**99**(1):427-511.
2. Faroni A, Mobasser SA, Kingham PJ, Reid AJ. Peripheral nerve regeneration: experimental strategies and future perspectives. *Advanced Drug Delivery*

- Reviews 2015;**82**:160-7.
3. Dahlin LB, Wiberg M. Nerve injuries of the upper extremity and hand. *EFORT Open Reviews* 2017;**2**(5):158-70.
 4. Radić B, Radić P, Duraković D. Peripheral nerve injury in sports. *Acta Clin Croat* 2018;**57**(3.):561-9.
 5. Ruettermann M, Hermann RM, Khatib-Chahidi K, Werker PM. Dupuytren's Disease—Etiology and Treatment. *Deutsches Ärzteblatt International* 2021;**118**(46):781.
 6. Chowdhry R, Sethi V. Hand arm vibration syndrome in dentistry: A review. *Current Medicine Research and Practice* 2017;**7**(6):235-9.
 7. Ortiz AdC, Fideles SOM, Pomini KT, et al. Potential of Fibrin Glue and Mesenchymal Stem Cells (MSCs) to Regenerate Nerve Injuries: A Systematic Review. *Cells* 2022;**11**(2):221.
 8. Carraro U, Boncompagni S, Gobbo V, et al. Persistent muscle fiber regeneration in long term denervation. past, present, future. *European Journal of Translational Myology* 2015;**25**(2).
 9. Abdalmageed OS, Bedaiwy MA, Falcone T. Nerve injuries in gynecologic laparoscopy. *J Minim Invasive Gynecol* 2017;**24**(1):16-27.
 10. Caillaud M, Richard L, Vallat J-M, Desmoulière A, Billet F. Peripheral nerve regeneration and intraneural revascularization. *Neural Regeneration Research* 2019;**14**(1):24.
 11. DeLeonibus A, Rezaei M, Fahradyan V, Silver J, Rampazzo A, Bassiri Gharb B. A meta-analysis of functional outcomes in rat sciatic nerve injury models. *Microsurgery* 2021;**41**(3):286-95.
 12. Sayad-Fathi S, Nasiri E, Zaminy A. Advances in stem cell treatment for sciatic nerve injury. *Expert Opin Biol Ther* 2019;**19**(4):301-11.
 13. Isaacs J. Reverse End-to-Side (Supercharging) Nerve Transfer: Conceptualization, Validation, and Translation. *Hand* 2021:1558944720988076.
 14. Bontioti E, Dahlin LB. Mechanisms underlying the end-to-side nerve regeneration. *Int Rev Neurobiol* 2009;**87**:251-68.
 15. Percie du Sert N, Ahluwalia A, Alam S, et al. Reporting animal research: Explanation and elaboration for the ARRIVE guidelines 2.0. *PLoS Biol* 2020;**18**(7):e3000411.
 16. Hua X-Y, Qiu Y-Q, Li T, et al. Contralateral peripheral neurotization for hemiplegic upper extremity after central neurologic injury. *Neurosurgery* 2015;**76**(2):187-95.
 17. Rasulic L, Samardzic M. Nerve grafting methods. *Nerves and nerve injuries*: Elsevier; 2015. p. 237-48.
 18. Howarth HM, Kadoor A, Salem R, et al. Nerve lengthening and subsequent end-to-end repair yield more favourable outcomes compared with autograft repair of rat sciatic nerve defects. *J Tissue Eng Regen Med* 2019;**13**(12):2266-78.
 19. Rasulic L, Cinara I, Samardzic M, et al. Nerve injuries of the upper extremity associated with vascular trauma—surgical treatment and outcome. *Neurosurg Rev* 2017;**40**(2):241-9.
 20. Rönkkö H. Side-to-side Neurorrhaphy in Peripheral Nerve Surgery. 2019. <https://trepo.tuni.fi/handle/10024/117085>
 21. Gordon T, English AW. Strategies to promote peripheral nerve regeneration: electrical stimulation and/or exercise. *Eur J Neurosci* 2016;**43**(3):336-50.
 22. Li R, Li D, Wu C, et al. Nerve growth factor activates autophagy in Schwann cells to enhance myelin debris clearance and to expedite nerve regeneration. *Theranostics* 2020;**10**(4):1649.
 23. Zhang S, Ji F, Tong D, Li M. Side-to-side neurorrhaphy for high-level peripheral nerve injuries. *Acta Neurochir (Wien)* 2012 2012/03/01;**154**(3):527-32.
 24. Viterbo F, Trindade JC, Hoshino K. Latero-terminal neurorrhaphy without removal of the epineural sheath. Experimental study in rats. *Rev Paul Med* 1992;**110**(6):267-75.
 25. Viterbo F, Brock RS, Maciel F, Ayestaray B, Garbino JA, Rodrigues CP. End-to-side versus end-to-end neurorrhaphy at the peroneal nerve in rats. *Acta Cir Bras* 2017;**32**:697-705.
 26. Liu H-F, Chen Z-G, Lineaweaver WC, Zhang F. Can the babysitter procedure improve nerve regeneration and denervated muscle atrophy in the treatment of peripheral nerve injury? *Plast Reconstr Surg* 2016;**138**(1):122-31.