

A Focus on Myasthenic Ptosis: The Interface of Medical and Surgical Treatment

Mohammad Bahadoram¹, Seyed Ehsan Mohammadianinejad¹, Esma'il Akade¹,
Shana Ahadi², Saleh Rasras^{2*}

1. Iranian Center of Neurological Research,
Neuroscience Institute, Tehran University
of Medical Sciences, Tehran, Iran

2. Department of Neurosurgery, School of
Medicine, Ahvaz Jundishapur University
of Medical Sciences, Ahvaz, Iran

ABSTRACT

Ocular ptosis, or drooping of the upper eyelid, has diverse etiologies, including neurologic and non-neurologic causes. Aponeurotic ptosis is a common cause in the elderly and traumatic or mechanical causes can affect any age, mimicking a neurologic cause. The neurologic causes are diverse but especially arise peripherally from pathologies affecting the nerve, neuromuscular junction, and muscles. The choice of treatment depends on the particular cause, but surgical intervention can also be an option in appropriately selected neurological patients whose ptosis remains embarrassing despite the best medical treatment. Myasthenia gravis, an autoimmune disorder targeting the neuromuscular junction, is a significant cause of ocular ptosis. The treatment is mainly by symptomatic and immunosuppressive medications, but surgical interventions, such as blepharoplasty, may be considered in some cases of socially embarrassing ptosis.

KEYWORDS

Ptosis; Myasthenia gravis; Plastic surgery; Aponeurosis; Blepharoplasty

Please cite this paper as:

Bahadoram M, Mohammadianinejad SE, Akade E, Ahadi S, Rasras S. A Focus on Myasthenic Ptosis: The Interface of Medical and Surgical Treatment. *World J Plast Surg.* 2024;13(3):23-32.
doi: 10.61186/wjps.13.3.23

INTRODUCTION

Ptosis is a common cause of outpatient referrals to ophthalmologists and neurologists. This condition can result from various congenital and acquired disorders affecting the nerve, neuromuscular junction, or tendon of the levator palpebrae superioris or the muscle itself ¹. Some patients may not be satisfied with the ptosis, even with adequate improvement of other symptoms from medical treatment ². Younger patients with socially unpleasant ptosis may seek surgical consults to get help. On the other side, plastic surgeons may have concerns about managing patients with fluctuating or progressive ptosis due to different neuromuscular disorders, which can affect the result of surgical intervention ³. Myasthenia is a common and well-known cause of fluctuating ptosis and is usually the most common cause of neurologic consultation ¹.

This review points briefly to the causes of neurological ptosis, focusing on myasthenia, and briefly discusses some diagnostic pitfalls and the place of surgery in such patients.

*Corresponding Author:

Dr. Saleh Rasras,
Assistant Professor of Neurosurgery
Department of Neurosurgery, School
of Medicine, Ahvaz Jundishapur
University of Medical Sciences,
Ahvaz, Iran

Email: dr.rasras@gmail.com

Received: 16/07/2024

Accepted: 3/11/2024

The definition and causes of ptosis

Normally, the upper lid must reach the upper limbus (the junction point between the cornea or iris and sclera) or cover it for about 1-2 mm⁴. The term "lid retraction" is called if the sclera is visible partly between the upper lid and cornea, and the term "ptosis" is used if the upper lid drops for more than 2 mm or covers more than 20% of the corneal surface⁵.

About one-third of the healthy population may experience slight degrees of asymmetric palpebral fissure, not respecting the above landmarks, especially upon stress, fatigue, or sleep deprivation⁶. Hence, not all patients with droopy lids suffer from ptosis.

The most common causes of ptosis are non-neurologic disorders, which mainly include a mechanical cause or dysfunction of aponeurotic insertion to the Levator Palpebral Superioris (LPS) muscle⁷. The neurologic causes can arise from a lesion at any level of neuraxis including the central and peripheral nervous system innervating the palpebral compartments, elevating the lid⁸.

Mechanical ptosis can result from any disruption to the upper eyelid, leading to ptosis. Examples include tumors of the eyelid or orbit, infections like cellulitis or sites, hematomas, and hemangiomas⁷. Patients suspected of having ptosis due to an underlying mass or infiltrative lesion should receive orbital imaging. Traumatic and postsurgical ptosis also fall into this category and are among the most common causes of ptosis reported in retrospective studies^{7,9}. Aponeurotic ptosis, characterized by thinning or dehiscence of the aponeurosis of the LPS, is the most prevalent cause of acquired ptosis. In this condition, the LPS muscle functions normally, shown by a normal eyelid excursion test on examination, but ptosis is more pronounced during downgaze. Ocular movements and orbicularis oculi muscle function remain normal, though atrophy of the skin or fat of the upper eyelid is often present. Abnormal lid positions, such as ectropion or entropion, can also occur. Aponeurotic ptosis is the most common form of ptosis in the elderly and usually results in bilateral though asymmetric ptosis¹⁰.

Most neurogenic causes of ptosis arise from a pathology affecting the nerve, neuromuscular junction, and the muscles. In these cases, the eyelid excursion test is abnormal, showing a dysfunction

of the LPS. A detailed history taking and clinical examination including the onset and temporal course, unilateral or bilateral onset or evolution, a fluctuating pattern of fatigability, and accompanying neurological symptoms and signs can help to determine the cause¹.

Myogenic causes of ptosis result in weakness of the LPS muscle, leading to either bilateral or unilateral ptosis. These causes can be categorized as congenital or acquired¹¹. Isolated congenital myogenic ptosis is the most common type of ptosis with infantile-onset. Initially thought to be a myogenic disorder, recent researches suggest that it is likely due to abnormal innervation of the LPS muscle¹². Non-congenital myogenic ptosis has various causes. Progressive external ophthalmoplegia (PEO) is a mitochondrial disorder that can manifest at any age, featuring symmetric and bilateral ptosis along with progressive weakness of extraocular muscles (EOM), resulting in a fixed eye position. When accompanied by other neurological or systemic symptoms such as deafness, retinopathy or optic neuropathy, dysphagia, dysarthria, or limb-girdle muscle weakness, the condition is termed PEO-plus¹¹. In addition to genetic myopathies, ptosis can also occur in acquired non-genetic myopathies, such as hypothyroid myopathy. Local inflammation and edema, as seen in orbital myositis or dermatomyositis, can also cause ptosis¹³.

Ptosis can also arise from neurogenic causes, which are due to defects in the innervation of the upper eyelid. These causes can be classified as congenital or acquired. Congenital third nerve palsy typically presents with ptosis associated with oculomotor palsy without affecting the pupil, and most patients do not exhibit other neurological symptoms¹⁴. Marcus Gunn's ptosis, also known as synkinetic ptosis, is caused by an abnormal connection of motor fibers from the fifth to the third cranial nerve. Patients with this condition, who generally have persistent ptosis, exhibit temporary upper eyelid retraction when the pterygoid muscles are stimulated, such as during chewing or laughing. In terms of acquired causes, the most common is injury to the third cranial nerve, usually due to ischemia. Ischemic third nerve palsy typically occurs in elderly patients and is associated with cardiovascular risk factors¹⁵. These patients experience an acute onset of ptosis and ophthalmoplegia without pupillary involvement. Conversely, compressive lesions

often involve the pupil, resulting in under-reactive mydriasis. The common causes of compressive third nerve palsy are the aneurysm of the posterior communicating artery and tumors ¹⁴.

Ptosis can also stem from neuromuscular junction disorders such as myasthenia gravis (MG), Lambert-Eaton syndrome, botulism, and local administration of botulinum toxin ¹⁶. Myasthenia gravis, an autoimmune disorder, is the most common neuromuscular junction disorder associated with ptosis ¹⁷. In Lambert-Eaton syndrome, ptosis occurs less frequently compared to myasthenia gravis. While ptosis or diplopia are not typically initial symptoms in Lambert-Eaton syndrome, between 30 and 50% of patients may develop ptosis as the disease progresses ¹⁸. In botulism, ptosis and diplopia accompany severe bulbar and limb weakness, along with cholinergic symptoms such as mydriasis, bradycardia, and hypotension ¹⁶. Patients with congenital myasthenic syndromes may also experience ptosis or diplopia. However, it is an uncommon finding in patients with mutations in genes primarily associated with limb-girdle weakness, such as DOK7, GFPT1, DPAGT1, and ALG2 ¹⁹.

The clinical assessment of ptosis

The assessment begins with a visual evaluation of the patient, focusing on head position and frontalis muscle contraction. The absence of an upward head position or absence of frontalis contraction in a patient with remarkable ptosis should raise the probability of functional ptosis which is a pseudoptosis caused by abnormal non-organic contraction of some muscles in the face ²⁰. Patients with functional ptosis usually have the contraction of orbicularis oculi on one side leading to the picture of pseudoptosis, but accompanied by the frontalis contraction on the other side, not compatible with organic ptosis in which the patient uses the frontalis contraction on the side of ptosis to compensate for it ²¹. Other causes of pseudoptosis such as widened palpebral fissure in unilateral facial nerve paresis mimicking ptosis in the contralateral normal eye, hemifacial spasm, blepharospasm and/or apraxia of eyelid opening, facial synkinesis, thyroid eye disease, dermatochalasis, and enophthalmos are evident by a close inspection and comparing both eyes and accompanying clinical clues in each condition ²².

After being ascertained of true ptosis, a detailed

history taking, pointed to the duration, mode of onset, and temporal course of symptoms with a particular focus on fatigability, accompanying symptoms, family history, and medications with an especial focus on the recent use of botulinum toxin is suggested ⁷.

The eyelid excursion test should be the next step to determine if there is an abnormal function of the LPS muscle. The patient is asked to look fully alternately upward and downward. Then the physician measures the distance that the upper lid moves between the positions of looking up and down. A distance of 12 mm or more indicates a normal LPS function that points to non-neurologic ptosis (such as LPS dehiscence) and a decreased LPS function indicates a neurologic cause ²⁰. This is followed by a detailed neurologic examination including the ocular movements, the cranial nerves, and motor, sensory, and reflex examinations. Accompanying weakness of the orbicularis oculi muscle in a patient with a droopy eyelid, assessed by asking the patient to close tightly their eyes, is frequently linked with myogenic and neuromuscular junction disorders. In patients with fluctuating ptosis and suspected myasthenia gravis, special techniques such as asking the patient to maintain an upward gaze for one minute, Cogan's lid twitch test, and ice pack test among others can provide added clues ^{20, 7}.

An overview of myasthenia gravis

Myasthenia gravis (MG) is an autoimmune condition characterized by the production of autoantibodies that target the neuromuscular junction. The term ocular myasthenia (OM) is used for patients who present with ptosis and or ophthalmoparesis and the symptoms remain isolated to the eye for at least 2 years. The incidence of OM based on population studies is approximately 1.13 per 100,000 per year, while studies focusing on myasthenia gravis have reported an incidence ranging from 0.17 to 7 per 100,000 per year. Nearly 50% of myasthenia patients initially present with only ocular symptoms ²³. Approximately 85% of patients with generalized MG have autoantibodies against the nicotinic acetylcholine receptor (AChR), while the remaining 15% have autoantibodies against muscle-specific kinase (MuSK) or lipoprotein receptor-related protein 4 (LRP4). Numerous studies have demonstrated the pathogenic effects

of these autoantibodies. In a small subset of patients, no autoantibodies are detected, leading to designation as seronegative myasthenia. Unlike adult and juvenile myasthenia, the pathophysiology of congenital myasthenic syndromes does not involve autoimmunity but rather structural or functional abnormalities, either presynaptic or postsynaptic, leading to inadequate release of acetylcholine or dysfunction of AChR^{23,24}. Anti-AChR antibodies exert their pathological effects at the neuromuscular junction through multiple mechanisms. They can directly block the AChR at the receptor site or nearby, preventing acetylcholine from binding. Additionally, by binding bivalently to the two binding sites of the antibody, they can cross-link AChR, causing internalization and reducing the number of receptors at the neuromuscular junction. Furthermore, they can activate the complement pathway, leading to the formation of the membrane attack complex. This complement-mediated damage results in decreased postsynaptic junctional folds, removal of AChR clustering and voltage-gated sodium channels from the membrane, and increased synaptic distance^{24,25}.

Anti-MuSK antibodies target MuSK, a transmembrane kinase essential for inducing the clustering of AChR. These antibodies, primarily produced by short-lived plasmablasts, belong to the IgG4 subclass²⁶. In their normal divalent state, anti-MuSK autoantibodies disrupt the interaction between LRP4 and MuSK by inducing phosphorylation, which is crucial for AChR clustering²⁴. Another pathophysiological effect of these antibodies is through a process called “Fab-exchange,” unique to the IgG4 subclass²⁶. In this process, antibodies can dissociate into two identical half molecules that recombine to form antibodies with two different Fab regions. Experimental models have shown that these functionally monovalent autoantibodies block the interaction between MuSK and LRP4, thereby reducing AChR clustering^{24,26}.

Compared to the well-understood pathophysiology of AChR and MuSK-mediated myasthenia gravis, less is known about LRP4-mediated MG and seronegative MG. LRP4 antibodies are primarily of the IgG1 subclass, which can activate the complement pathway and disrupt Agrin-LRP4 signaling²⁷. Other autoantibodies implicated in MG include those targeting agrin, collagen Q, cortactin, and the voltage-gated potassium channel Kv1.4.

However, the exact pathogenic mechanisms of these autoantibodies remain not fully understood²⁴.

In cases of OM, the susceptibility of extraocular muscles can be attributed to several physiological characteristics of the postsynaptic endplate, including:

- High-frequency firing of twitch motor units.
- The lower density of AChR at extraocular muscle twitch synapses due to fewer secondary synaptic folds.
- Reduced acetylcholine release at extraocular muscle twitch synapses.
- The presence of a high number of multiterminal fibers, which have one en plaque and several en grappe synapses²⁸.

Ocular myasthenia

Patients with OM have isolated involvement of one or both eyes including ptosis with or without diplopia for at least 2 years, while the disease has not extended to other parts of the body. These patients have usually a good prognosis regarding the critical conditions that may threaten a patient with generalized MG but still can suffer from disabling ptosis and or diplopia. A defining feature of the disease is its fatigability and variability, which can be observed and confirmed during clinical examination. Ptosis may be unilateral or bilateral, and the upper eyelid elevator muscle may exhibit fatigue with sustained upgaze. Enhanced ptosis, also referred to as the “curtain effect,” occurs when one eyelid is lifted, and the contralateral eyelid develops ptosis or worsening of pre-existing ptosis. This phenomenon is attributed to Hering’s law of equal innervation, where yoke muscles acting in the same direction receive equal innervation²⁹. The “Cogan’s lid twitch” is a notable clinical sign characterized by excessive upward movement of the upper eyelid, resembling a twitch, after sustained downward gaze, before returning to its resting position. This sign is attributed to fatigue, increased gain, and rapid muscle recovery. It is peculiar (99%) and moderately sensitive (75%) for the diagnosis of ocular myasthenia gravis, with a low false positive rate³⁰. Another diagnostic maneuver is the “forced eyelid closure test,” where the patient squeezes their eyes shut for a few seconds and then opens them while fixating on a target³¹. An upward overshoot followed by a downward drift of the eyelid constitutes a positive test. This test

has shown high sensitivity (94%) and specificity (91%) for ocular myasthenia gravis. Orbicularis weakness, leading to incomplete eyelid closure (the “Peek-sign”), is another distinctive sign of ocular myasthenia gravis. Ophthalmoplegia in ocular myasthenia gravis can mimic various ocular motility disorders, necessitating careful clinical examination for differentiation³². Testing the pupils is helpful as they are typically unaffected in myasthenia gravis. Variability in orthoptic measurements, intrasaccadic fatigue, and incomitant ocular deviation are characteristic features of ocular myasthenia gravis. However, comitant ocular deviation or deviations changing from comitant to incomitant and vice versa have been reported in a subset of cases. Various clinical presentations such as pseudo-internuclear ophthalmoplegia, pseudo-one-and-a-half syndrome, complete external ophthalmoplegia, divergence, and convergence paresis, and double elevator palsy have been described in ocular myasthenia gravis. Given the potential for mimicry of other ocular motility disorders, particularly in the absence of ptosis, MRI brain imaging may be necessary for diagnostic clarification^{33,34}.

Differential Diagnoses

Isolated ptosis may also warrant consideration of other differential diagnoses, including congenital ptosis, Horner’s syndrome, early chronic progressive external ophthalmoplegia, botulinum toxin injection, and involutional levator dehiscence ptosis. Indeed, distinguishing myasthenia gravis from other conditions necessitates a comprehensive approach

involving a detailed medical history, thorough physical examination, and appropriate diagnostic tests. These tests may include pharmacological tests, serological tests for autoantibodies, electromyography (EMG), and specific clinical tests such as the ice pack or sleep test³⁵. Figure 1 illustrates a diagnostic algorithm for the evaluation of ptosis, showing the stepwise approach to reach a diagnosis and so optimal patient care.

Pharmacological Tests

The edrophonium (cholinesterase inhibitor) test was historically utilized for diagnosing myasthenia gravis ptosis, but newer diagnostic methods have largely replaced it. The test exhibits low sensitivity (60%) and low specificity, as it has been reported to produce positive results in conditions other than myasthenia gravis, such as multiple sclerosis, brain stem glioma, Guillain-Barre syndrome, pituitary tumors, and ischemic cranial neuropathy³⁶. Edrophonium is a short-acting acetylcholinesterase inhibitor administered intravenously, with an onset of action within 10 to 30 seconds, leading to improvement in muscle function. The typical starting dose is 2 mg, with an additional 2 mg administered if no positive response occurs after 45 seconds, up to a maximum of 10 mg until a positive result is observed. However, the test is prone to subjective interpretation, like any clinical test, and is associated with significant systemic side effects, including bradycardia, syncope, and cholinergic crisis³⁷.

More commonly, oral pyridostigmine is utilized in

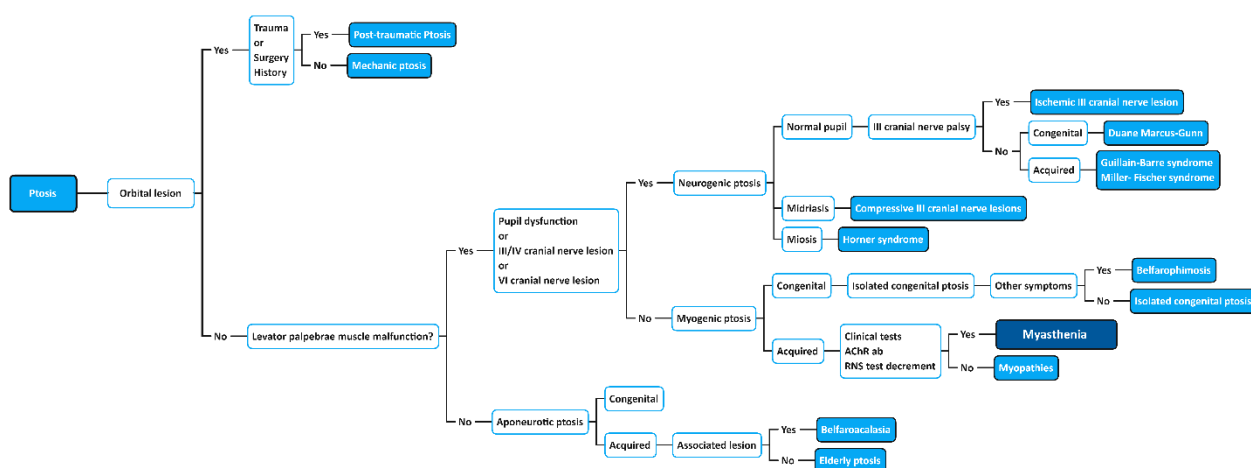


Figure 1: This flow diagram provides the algorithm for the diagnosis of myasthenic ptosis based on clinical findings. RNS: repetitive nerve stimulation; AChR Ab: Acetyl Choline Receptor Antibody (Original)

a therapeutic trial for suspected myasthenia gravis ptosis, particularly in seronegative cases. Thus, the pharmacologic response to treatment indirectly serves as a diagnostic test for myasthenia gravis³⁸.

Serological Tests

AChR antibodies are commonly used in serological testing for diagnosing OM. While the AChR antibody assay is highly sensitive (80–90%) in generalized myasthenia gravis, its sensitivity in OM has traditionally been considered lower, with reported seropositivity ranging between 40–70%³⁹. However, recent studies have reported higher sensitivity of the assay in OM. Peeler et al. found a sensitivity of 70.9% in a study involving 223 OM subjects⁴⁰, while Chung et al. reported a sensitivity of 86.7% in 114 cases referred for suspected OM⁴¹. The increased sensitivity of the AChR antibody assay in OM has been attributed to advancements in radio-immunoassays and the availability of newer cell-based assays, which are more likely to yield positive results, particularly in “seronegative OM” cases²⁹. Additionally, some authors suggest that the increased seropositivity rate may be linked to the rising prevalence of late-onset generalized myasthenia gravis (between 50–70 years) over the past two decades. In a cohort of 133 patients with OM, AChR antibody assay was positive in 65%, with seropositivity increasing with later onset, peaking in patients older than 70⁴². There are three types of AChR antibodies: binding, modulating, and blocking. Binding AChR antibodies are the most useful for diagnostic testing due to their higher seropositivity. However, testing for modulating AChR antibodies may slightly increase test sensitivity, while blocking AChR antibodies is of lower clinical utility as they are not typically detected in isolation^{43,44}.

Anti-MuSK antibodies were initially identified in 38–54% of patients who tested negative for AChR antibodies but were rarely found in cases of “pure” ocular myasthenia gravis. Early reports of Anti-MuSK-positive myasthenia typically described symptoms involving the bulbar, neck, and respiratory muscles. However, more recent studies have demonstrated that ocular manifestations are present in a substantial proportion of Anti-MuSK-positive cases, ranging from 50% to 96.4%, with ocular symptoms being the initial presentation in

58.5% of cases⁴⁵.

In cases of double-seronegative myasthenia gravis (dsNMG), where both AChR and MuSK antibodies are negative, testing for antibodies to LRP4 and other components of the post-synaptic apparatus is recommended⁴⁶. The frequency of positive LRP4 antibodies in dsNMG varies widely across different studies, ranging from 2% to 50%. dsNMG with positive LRP4 antibodies tends to occur more frequently in young females, often presents with mild symptoms, including isolated ocular manifestations, and typically responds well to treatments such as pyridostigmine or prednisone⁴⁷.

It's noteworthy that LRP4 antibodies have also been reported in other neurological disorders such as polymyositis, neuromyelitis optica, multiple sclerosis, and amyotrophic lateral sclerosis²⁹. Therefore, clinicians should exercise caution as some of these disorders are among the differential diagnoses for ocular myasthenia gravis.

Cortactin, a protein concentrated at the neuromuscular junction and acting downstream from agrin/LRP4/MuSK, promotes AChR clustering. Antibodies to cortactin have been detected in approximately 20% of patients with dsNMG, as well as in cases of myositis and other autoimmune diseases. In a series of 38 dsNMG patients, 23.7% were cortactin antibody positive, with a subset presenting at a young age with predominantly ocular involvement. Patients with dsNMG and positive cortactin antibodies, particularly those younger than 50, exhibited a higher frequency of ocular myasthenia gravis and fewer bulbar signs compared to AChR antibody-positive myasthenia²⁶.

The different autoantibodies identified in dsNMG are associated with distinct clinical phenotypes, potentially explaining the variability in treatment responses among patients⁴⁶. In cases of anti-MuSK-positive myasthenia, circulating plasmablasts producing MuSK-specific autoantibodies express higher levels of CD20 compared to their tissue-resident plasma cell counterparts producing AChR antibodies. Consequently, MuSK myasthenia tends to respond more favorably to B-cell-depleting treatment rituximab (anti-CD20) than AChR myasthenia. A systematic review demonstrated that 72% of MuSK myasthenia patients achieved clinical remission with rituximab compared to 30% of AChR myasthenia patients ($P < 0.001$)^{48,49}.

Electrodiagnostic Studies

Repetitive nerve stimulation (RNS) is a diagnostic tool utilized to detect decremental responses in cases of generalized myasthenia gravis. However, it is abnormal in only 30–50% of patients with OM. Therefore, in the absence of generalized symptoms, its diagnostic value is limited. Single-fiber electromyography (SFEMG) is preferred in cases of OM due to its higher sensitivity (88–92%). SFEMG detects variability in the action potential interval between two muscle fibers within the same motor unit, known as “jitter,” which is a critical abnormality in myasthenia. However, SFEMG can also be abnormal in pre-synaptic disorders such as Lambert-Eaton myasthenic syndrome and mitochondrial myopathies⁵⁰.

In a large prospective study of SFEMG of the orbicularis oculi for patients referred for suspected OM, those presenting with both ptosis and diplopia were more likely to have an abnormal SFEMG (98%), whereas patients with isolated diplopia were less likely (32%). The overall sensitivity of SFEMG was 79%, with a specificity of 80%, a positive predictive value of 90%, and a negative predictive value of 61%. Thus, an abnormal SFEMG can help confirm the diagnosis of OM, but a negative result does not exclude it⁵¹.

Comparing the sensitivity and specificity of the ice test and SFEMG of the orbicularis, the ice test demonstrated a sensitivity of 86% and a specificity of 79%, while SFEMG showed a sensitivity of 94% and a specificity of 79%. When both tests were positive, the sensitivity for diagnosing OM increased to 82%, and the specificity to 92%, with a negative predictive value of 94%. Therefore, if both tests are negative, the diagnosis of OM becomes highly unlikely⁵².

Surgical treatment for myasthenic ptosis

Medical management may not always effectively alleviate ocular symptoms in some patients with ocular myasthenia in the long term and may be associated with significant side effects. It is generally recommended to initially treat ptosis in OM with optimal medical therapy, which may include pyridostigmine or steroids/immunosuppressive agents. However, if ptosis or strabismus remains stable for at least two years, surgical intervention for ptosis may be considered appropriate²⁹.

Additionally, older patients with OM may also have comorbid age-related conditions such as levator dehiscence and dermatochalasis, which might potentially benefit from surgery⁵³.

The choice of ptosis repair technique, as with other types of ptosis, depends on factors such as levator function, the risk of corneal exposure, and the integrity of Bell's phenomenon⁵⁴. Impaired or variable Bell's phenomenon, reduced ocular motility, incomplete or infrequent blinking, weakened orbicularis function, and the risk of postoperative lagophthalmos are factors to consider before recommending surgery. The primary goal of surgery should be to elevate the eyelid to a functional level while minimizing the risk of corneal exposure⁵⁵.

The outcomes of surgical interventions in selected patients with OM have been extensively documented. For example, a study conducted at the Mayo Clinic between 1985 and 1999 examined patients who underwent surgical correction for blepharoptosis. Among the procedures performed, including external levator advancements, frontalis slings, and tarsomyectomy, statistically significant improvements in interpalpebral eyelid fissure height were observed postoperatively. However, postoperative complications such as worsened diplopia and exposure keratopathy were noted in some cases, highlighting the importance of careful patient selection and surgical techniques. Additionally, cases of recurrent ptosis requiring additional surgery were reported in a subset of patients who underwent external levator advancements⁵⁶.

In a single-center retrospective study conducted on patients with myasthenia gravis undergoing ptosis surgery between September 2007 and November 2013, sixteen external levator advancement procedures were performed on 11 myasthenia gravis patients. Out of the sixteen procedures, pre- and postoperative upper marginal reflex distance (uMRD) measurements were documented for fourteen procedures. Among these, thirteen procedures demonstrated an improvement in lid height, with a mean increase in uMRD of 2.4 mm ($P=0.0005651$). Two patients required secondary lid elevation due to unsatisfactory outcomes. Postoperative complications included exacerbation of diplopia and exposure keratopathy, underscoring the importance of careful management and monitoring in these cases⁵⁵.

In the latest published study on the outcomes of surgery in myasthenia gravis ptosis conducted by Andre S. Litwin et al., a cohort of 30 patients with symptomatic eyelid concerns despite appropriate medical treatment underwent eyelid surgery. The mean age at diagnosis was 47 years, with 13 patients diagnosed with generalized myasthenia gravis, 14 with ocular myasthenia gravis, and 3 with congenital myasthenia gravis. A total of 38 blepharoptosis procedures were performed on 23 patients, with a mean age at the time of surgery of 62 years and an average follow-up period of 29 months. Among the surgical procedures, 10 patients (16 eyelids) underwent anterior approach levator advancement, 4 patients (5 eyelids) underwent posterior approach surgery, and 8 patients (15 eyelids) underwent brow suspension. Additionally, one patient (2 eyelids) underwent tarsal switch surgery. On average, an improvement in eyelid height of 1.9 mm was achieved postoperatively. Postoperative symptoms or signs of exposure keratopathy occurred in 17% of patients, leading to the necessity of lid lowering in one eyelid of one patient. During the follow-up period, 37% of eyelids required further surgical intervention to improve upper eyelid height, with an average interval of 19 months between the initial surgery and subsequent interventions (range 0.5–49 months). These findings underscore the importance of continued monitoring and the potential need for additional surgical interventions in the management of myasthenia gravis-related ptosis⁵⁷.

CONCLUSION

Ocular ptosis, or drooping of the upper eyelid, can have various non-neurologic including mechanical and aponeurotic ptosis and neurologic causes affecting any level of neuraxis, mostly the nerve, NMJ, and the muscles elevating the lid. Aponeurotic ptosis is the most common type of acquired ptosis and is also the most common cause of surgical intervention. The neurologic causes mostly arise from the nerve, NMJ, and muscles, the myasthenia gravis being a fundamental and challenging cause for chronic ptosis. While the treatment is mainly medical with symptomatic and disease-modifying treatments, some patients with chronic and stable ptosis or almost stable ptosis from OM, or those with comorbid conditions such as aponeurotic ptosis or blepharochalasis, may prefer to take help

from surgical intervention. However, careful patient selection and monitoring are crucial, considering the potential for postoperative complications and the need for additional surgeries in some cases.

FUNDING/SUPPORT

This article has not received any financial support.

ACKNOWLEDGMENTS

The authors declare that they have no conflicting interests regarding this article.

REFERENCES

1. Shahzad B, Siccardi MA. Ptosis. StatPearls. Treasure Island (FL): StatPearls Publishing. Copyright © 2024, StatPearls Publishing LLC.; 2024.
2. Jeong JH, Park CS. Evaluating the Correlation between Ptosis Improvement and Immediate Postoperative Lagophthalmos following Blepharoptosis Surgery under General Anesthesia in Pediatric Patients. *J Clin Med* 2024; **19**;13(4):1173.
3. Keene KR, Kan HE, van der Meeren S, et al. Clinical and imaging clues to the diagnosis and follow-up of ptosis and ophthalmoparesis. *J Cachexia Sarcopenia Muscle* 2022 Dec;**13**(6):2820-34.
4. Gooris PJJ, Cornelius C-P. Anatomy of the Orbit: Overall Aspects of the Peri- and Intra Orbital Soft Tissues. In: Gooris PJJ, Mourits MP, Bergsma JE, editors. *Surgery in and around the Orbit: CrossRoads*. Cham: Springer International Publishing; 2023. p. 59-119.
5. Oestreicher J, Mehta S. Complications of blepharoplasty: prevention and management. *Plast Surg Int* 2012;**2012**:252368.
6. Song WC, Kim SJ, Kim SH, Hu KS, Kim HJ, Koh KS. Asymmetry of the palpebral fissure and upper eyelid crease in Koreans. *J Plast Reconstr Aesthet Surg* 2007;**60**(3):251-5.
7. Bacharach J, Lee WW, Harrison AR, Freddo TF. A review of acquired blepharoptosis: prevalence, diagnosis, and current treatment options. *Eye (Lond)* 2021 Sep;**35**(9):2468-81.
8. Hamedani AG, Gold DR. Eyelid Dysfunction in Neurodegenerative, Neurogenetic, and Neurometabolic Disease. *Front Neurol* 2017; **8**:329.
9. Nichols KK, Malloy KA, Karpecki PM, et al. Topical Review: An Update of Diagnostic and Management Algorithms for Acquired Blepharoptosis. *Optom Vis Sci* 2022 Mar 1;**99**(3):230-40.
10. Koka K, Patel BC. Ptosis Correction. StatPearls.

- Treasure Island (FL): StatPearls Publishing. Copyright © 2024, StatPearls Publishing LLC.; 2024.
11. Hirano M, Pitceathly RDS. Progressive external ophthalmoplegia. *Handb Clin Neurol* 2023;**194**:9-21.
 12. Nalci Baytaroglu H, Kaya B, Korkusuz P, Hoşal MB. A Study of Histopathologic Evaluation and Clinical Correlation for Isolated Congenital Myogenic Ptosis and Aponeurotic Ptosis. *Ophthalmic Plast Reconstr Surg* 2020 Jul/Aug;**36**(4):380-4.
 13. Park RB, Akella SS, Aakalu VK. A review of surgical management of progressive myogenic ptosis. *Orbit* 2023 Feb;**42**(1):11-24.
 14. Pauly M, Sruthi R. Ptosis: Evaluation and management. *Kerala Journal of Ophthalmology* 2019;**31**(1):11-6.
 15. Margolin E, Freund P. Third Nerve Palsies: Review. *Int Ophthalmol Clin* 2019 Summer;**59**(3):99-112.
 16. Wray SH. 83Ptosis and Neuromuscular Syndromes. In: Wray SH, editor. *Eye Movement Disorders in Clinical Practice*: Oxford University Press; 2014. p. 0.
 17. Nair AG, Patil-Chhablani P, Venkatramani DV, Gandhi RA. Ocular myasthenia gravis: a review. *Indian J Ophthalmol* 2014 Oct;**62**(10):985-91.
 18. Katyal N, Govindarajan R. Pure Ocular Weakness as the Initial Manifestation of Lambert-Eaton Myasthenic Syndrome. *Cureus* 2017 Dec 31;**9**(12):e2007.
 19. Evangelista T, Hanna M, Lochmüller H. Congenital Myasthenic Syndromes with Predominant Limb Girdle Weakness. *J Neuromuscul Dis* 2015 Jul 22;**2**(Suppl 2):S21-s9.
 20. Zoumalan CI, Lisman RD. Evaluation and Management of Unilateral Ptosis and Avoiding Contralateral Ptosis. *Aesthetic Surgery Journal* 2010;**30**(3):320-8.
 21. Putterman AM. Functional ptosis blepharoplasty diagnostic clamp. *Ophthalmic Plast Reconstr Surg* 2012 Jul-Aug;**28**(4):311-2.
 22. Ting SL, Koay AC, Yew YH, Chua CN. Challenges in diagnosis and management of pseudoptosis secondary to asymmetrical skin creases. *Med J Malaysia* 2011 Jun;**66**(2):121-3.
 23. Dresser L, Wlodarski R, Rezanian K, Soliven B. Myasthenia Gravis: Epidemiology, Pathophysiology and Clinical Manifestations. *J Clin Med* 2021 May 21;**10**(11).
 24. Lazaridis K, Tzartos SJ. Myasthenia Gravis: Autoantibody Specificities and Their Role in MG Management. *Front Neurol* 2020;**11**:596981.
 25. Marcuse F, Brandts L, Moens D, et al. The association between anti-acetylcholine receptor antibody level and clinical improvement in myasthenia gravis. *European Journal of Neurology* 2022 2022/04/01;**29**(4):1187-97.
 26. Vakrahou AG, Karachaliou E, Chroni E, et al. Immunotherapies in MuSK-positive Myasthenia Gravis; an IgG4 antibody-mediated disease. *Frontiers in Immunology* 2023 2023-July-26;**14**.
 27. Rivner MH, Quarles BM, Pan JX, et al. Clinical features of LRP4/agrin-antibody-positive myasthenia gravis: A multicenter study. *Muscle Nerve* 2020 Sep;**62**(3):333-43.
 28. De Baets M, Stassen MH. The role of antibodies in myasthenia gravis. *J Neurol Sci* 2002 Oct 15;**202**(1-2):5-11.
 29. Behbehani R. Ocular Myasthenia Gravis: A Current Overview. *Eye Brain* 2023;**15**:1-13.
 30. Singman EL, Matta NS, Silbert DI. Use of the Cogan lid twitch to identify myasthenia gravis. *J Neuroophthalmol* 2011 Sep;**31**(3):239-40.
 31. Apinyawasisuk S, Zhou X, Tian JJ, Garcia GA, Karanjia R, Sadun AA. Validity of Forced Eyelid Closure Test: A Novel Clinical Screening Test for Ocular Myasthenia Gravis. *J Neuroophthalmol* 2017 Sep;**37**(3):253-7.
 32. Osher RH, Griggs RC. Orbicularis fatigue: the 'peek' sign of myasthenia gravis. *Arch Ophthalmol* 1979 Apr;**97**(4):677-9.
 33. Engstrom JW. Myasthenia gravis: diagnostic mimics. *Semin Neurol* 2004 Jun;**24**(2):141-7.
 34. Keene KR, Notting IC, Verschuuren J, et al. Eye Muscle MRI in Myasthenia Gravis and Other Neuromuscular Disorders. *J Neuromuscul Dis* 2023;**10**(5):869-83.
 35. Díaz-Manera J, Luna S, Roig C. Ocular ptosis: differential diagnosis and treatment. *Curr Opin Neurol* 2018 Oct;**31**(5):618-27.
 36. Pascuzzi RM. The edrophonium test. *Semin Neurol* 2003 Mar;**23**(1):83-8.
 37. Hood L. The Tensilon Test. *AJN The American Journal of Nursing* 1999;**99**(5).
 38. Maggi L, Mantegazza R. Treatment of myasthenia gravis: focus on pyridostigmine. *Clin Drug Investig* 2011 Oct 1;**31**(10):691-701.
 39. Bindu PS, Nirmala M, Patil SA, Taly AB. Myasthenia gravis and acetylcholine receptor antibodies: a clinico immunological correlative study on South Indian patients. *Ann Indian Acad Neurol* 2008 Oct;**11**(4):242-4.
 40. Peeler CE, De Lott LB, Nagia L, Lemos J, Eggenberger ER, Cornblath WT. Clinical Utility of Acetylcholine Receptor Antibody Testing in Ocular Myasthenia Gravis. *JAMA Neurol* 2015 Oct;**72**(10):1170-4.
 41. Chung IY, Sheth SJ, Wells KK, Campbell TG. The Usefulness of Anti-acetylcholine Receptor Binding Antibody Testing in Diagnosing Ocular Myasthenia Gravis. *J Neuroophthalmol* 2021 Dec 1;**41**(4):e627-e30.
 42. Monte G, Spagni G, Damato V, Iorio R, Marino M, Evoli A. Acetylcholine receptor antibody positivity rate in ocular myasthenia gravis: a matter of age? *J Neurol* 2021 May;**268**(5):1803-7.
 43. Meriggioli MN, Sanders DB. Muscle autoantibodies in myasthenia gravis: beyond diagnosis? *Expert Rev Clin Immunol* 2012 Jul;**8**(5):427-38.

44. Li Y, Peng Y, Yang H. Serological diagnosis of myasthenia gravis and its clinical significance. *Ann Transl Med* 2023 Apr 15;**11**(7):290.
45. Caress JB, Hunt CH, Batish SD. Anti-MuSK Myasthenia Gravis Presenting With Purely Ocular Findings. *Archives of Neurology* 2005;**62**(6):1002-3.
46. Goto T, Kimura A, Masuda A, Mochizuki Y, Gomi F. Clinical features of double seronegative ocular myasthenia gravis. *Graefes Arch Clin Exp Ophthalmol* 2024 Aug;**262**(8):2617-23.
47. Vinciguerra C, Bevilacqua L, Lupica A, et al. Diagnosis and Management of Seronegative Myasthenia Gravis: Lights and Shadows. *Brain Sci* 2023 Sep 5;**13**(9).
48. Gallardo E, Martínez-Hernández E, Titulaer MJ, et al. Cortactin autoantibodies in myasthenia gravis. *Autoimmun Rev* 2014 Oct;**13**(10):1003-7.
49. Tandan R, Hehir MK, 2nd, Waheed W, Howard DB. Rituximab treatment of myasthenia gravis: A systematic review. *Muscle Nerve* 2017 Aug;**56**(2):185-96.
50. Patel P, Pobre T. Electrodiagnostic Evaluation of Neuromuscular Junction Disorder. StatPearls. Treasure Island (FL): StatPearls Publishing. Copyright © 2024, StatPearls Publishing LLC.; 2024.
51. Rakocevic G, Moster M, Floeter MK. Single-fiber electromyography in the orbicularis oculi muscle in patients with ocular myasthenia gravis symptoms: does abnormal jitter predict response to treatment? *BMC Neurol* 2017 Jun 7;**17**(1):108.
52. Giannoccaro MP, Paolucci M, Zenesini C, et al. Comparison of ice pack test and single-fiber EMG diagnostic accuracy in patients referred for myasthenic ptosis. *Neurology* 2020 Sep 29;**95**(13):e1800-e6.
53. Grob SR, Cypen SG, Tao JP. Acquired Ptosis. In: Albert DM, Miller JW, Azar DT, Young LH, editors. *Albert and Jakobiec's Principles and Practice of Ophthalmology*. Cham: Springer International Publishing; 2022. p. 5647-64.
54. Kratky V. Treatment of congenital ptosis. *Annals of Eye Science* 2020;**5**:37.
55. Brogan K, Farrugia ME, Crofts K. Ptosis Surgery in Patients with Myasthenia Gravis: A Useful Adjunct to Medical Therapy. *Semin Ophthalmol* 2018;**33**(3):429-34.
56. Bradley EA, Bartley GB, Chapman KL, Waller RR. Surgical correction of blepharoptosis in patients with myasthenia gravis. *Trans Am Ophthalmol Soc* 2000;**98**:173-80; discussion 80-1.
57. Litwin AS, Patel B, McNab AA, McCann JD, Leatherbarrow B, Malhotra R. Blepharoptosis surgery in patients with myasthenia gravis. *Br J Ophthalmol* 2015 Jul;**99**(7):899-902.