

# Presence of Martin-Gruber Anastomosis among a Cohort of Mexican Origin; a Corpse Dissection Study

Orozco Grados, Jose de Jesus<sup>1</sup>, Cárdenas Mejia, Alexander<sup>2</sup>, Velazquez Zabaleta, Enrique<sup>2</sup>, Maillard Olvera, Jimena<sup>3</sup>, Garcia Garcia, Jose Antonio<sup>4\*</sup>

1. Department of Plastic and Reconstructive Surgery, Hospital Angeles de Querétaro, Querétaro, Mexico
2. Department of Plastic and Reconstructive Surgery, Hospital Dr. Manuel Gea González, Mexico City, Mexico
3. Department of Anesthesiology, Hospital Dr. Manuel Gea González, Mexico City, Mexico
4. Harvard TH Chan School of Public Health, Social and Behavioral Sciences, Boston, MA, USA

## ABSTRACT

**Background:** At the forearm level, Martin-Gruber anastomosis is described as the most common anatomic variation. Early recognition of this anastomosis in patients with peripheral nerve lesions and preserved function of the hand musculature lowers the rate of misdiagnosis and prevents unnecessary treatment approaches. We aimed to determine the prevalence and characteristics of Martin-Gruber anastomosis in a Mexican cohort and discuss its impact on clinical diagnostics and approach.

**Methods:** We conducted a cross-sectional dissection study on 40 inert anatomical models at the National Forensic Sciences Institute in Mexico City. Each model was dissected to trace and measure Martin-Gruber anastomoses from the median nerve to the ulnar nerve. Measurements were recorded using a digital Vernier caliper, and the presence of anastomosis, its length, nerve of origin, and side were analyzed. Chi-square tests evaluated the association between the presence of anastomoses and sex, and nerve origin and arm side.

**Results:** Martin-Gruber anastomosis was found in 47.5% of the specimens, with bilateral anastomoses in 11 and unilateral in eight. The majority of anastomoses (62.5%) originated from the left arm. There was no significant association between the presence of anastomosis and sex ( $P=0.093$ ) or between the nerve origin and arm side ( $P=0.809$ ).

**Conclusion:** The high prevalence of Martin-Gruber anastomosis in this study highlights its clinical importance, particularly in preventing misdiagnoses of ulnar nerve injuries and unnecessary surgical interventions. Anatomical variations like Martin-Gruber anastomosis should be considered in clinical assessments of peripheral nerve injuries to enhance diagnostic accuracy and treatment outcomes.

## KEYWORDS

Martin-Gruber; Ulnar nerve; Median nerve; Peripheral nerve lesions

## Please cite this paper as:

Orozco Grados JJ, Cárdenas Mejia A, Velazquez Zabaleta E, Maillard Olvera J, Garcia Garcia JA. Presence of Martin-Gruber Anastomosis among a Cohort of Mexican Origin; a Corpse Dissection Study. *World J Plast Surg.* 2025;14(1):59-63.

doi: 10.61186/wjps.14.1.59

## \*Corresponding Author:

Jose Antonio Garcia Garcia MD, MPH, 40 Saint Botolph St. Boston, MA. 02116

Tel.: +1 (857) 3130662

Email:

[josegarcia@hsph.harvard.edu](mailto:josegarcia@hsph.harvard.edu)

Received: 11/19/2024

Accepted: 2/19/2025

## INTRODUCTION

Peripheral nerve injuries are a common diagnosis that conditions the functionality of the affected limb and involves a variable degree of morbidity. Traumatic injuries are the most common cause of these lesions, along with iatrogenic surgical injuries, usually affecting the

muscles of the forearm and the hand. Interestingly, certain anatomical variations can be manifested clinically and neurophysiologically in such a way that they complicate necessary treatment decisions for providers<sup>1</sup>. Nerve anastomoses (crossings of axons from one nerve to another) are a type of anatomical variation that frequently occurs in human beings; thus, they should not be considered anomalies<sup>2</sup>.

For instance, different locations have been described where axons anastomose and connect the median nerve and the ulnar nerve below the elbow, such as the proximal and distal parts of the forearm and the palm of the hand. The literature describes Martin-Gruber anastomosis as the most common presentation of this variant at the forearm level, with an estimated average prevalence between 18 - 40% and no significant difference between both sexes<sup>3,4</sup>. This type of anastomosis is usually bilateral, and when it is unilateral, it is usually more common in the right arm<sup>5</sup>. Similarly, a family inheritance — probably autosomal dominant — has been previously described<sup>5,6</sup>.

The Martin-Gruber anastomosis occurs proximally and travels from the median to the ulnar nerve. It consists of axons that leave either the main trunk of the median nerve or the anterior interosseous nerve. These axons cross through the forearm to join the main trunk of the ulnar nerve, innervating the intrinsic muscles of the hand, most commonly at the dorsal interosseous nerves<sup>1</sup>. This anastomosis rarely includes sensory axons, with practically exclusive motor involvement. Consequently, this anastomosis produces changes in the muscular innervation of the upper limb and intrinsic muscles of the hand.

The results in this study provide insight into identifying anatomical variants that manifest as ulnar nerve lesions with preserved innervation of the intrinsic musculature at the hand level. Early recognition of these lesions in patients with preserved function of the hand musculature would lower the rates of misdiagnosis and, therefore, would prevent unnecessary treatment approaches. Moreover, suspecting these variants would achieve a better functional prognosis for patients and a lower rate of complications in the medium and long term<sup>7</sup>.

## METHODS

We conducted an observational, cross-sectional dissection study of inert anatomical models at the

National Forensic Sciences Institute in Mexico City for a year, aiming to identify the presence of Martin-Gruber anastomoses in the specimens' forearms. A random sample of 40 models was obtained, adhering to inclusion criteria of intact arms and recorded ages at death between 18 to 85 years.

Ethical considerations were strictly adhered to, with all procedures performed in accordance with the guidelines of the National Forensic Sciences Institute, ensuring adequate handling of the anatomical models.

Dissection was performed on the volar face of both forearms of each model. Using a standardized "S" Italic incision, the flexor mass was carefully separated to expose the median and ulnar nerves. We traced the axons to identify the presence and characteristics of Martin-Gruber anastomoses. Measurements of anastomotic lengths were taken with a digital Vernier caliper, ensuring a precision of 0.01 mm. Each anastomosis was measured from its point of origin to the point of termination into the ulnar nerve. The caliper jaws were placed at the origin and termination points, and the length was recorded to the nearest hundredth of a millimeter.

Among the variables we identified were the presence of anastomosis, its length, the linear pattern that it followed, and the nerve of origin of the axons. In the same way, we recorded demographic data such as the age and sex of the model. Chi-square tests of independence were conducted using Stata 8 software to assess statistically significant differences between sex and the presence of the anatomical variant, and nerve of origin (AIN or Median) and the arm side (left or right), with a threshold set at a *P*-value of less than 0.05.

## RESULTS

The Martin-Gruber anastomosis was present in 37.5% of a total sample of 80 dissected arms. We calculated a 47.5% overall prevalence, with 19 out of 40 specimens presenting this variant, 11 of which presented it bilaterally and eight unilaterally. Interestingly, contrary to what has previously been reported, the majority (62.5%) of the axons originated from the left arm in our sample<sup>5</sup>.

Upon dissection of 80 arms from our 40 randomly selected specimens, Martin-Gruber anastomosis was identified in 19 specimens, resulting in an overall prevalence of 47.5%. The anastomosis was

bilateral in 11 specimens and unilateral in eight. Interestingly, contrary to what has previously been reported, we found that the majority (62.5%) of the axons originated from the left arm in our sample<sup>5</sup>. In the specimens' left arm, 40% of the axons originated from the anterior interosseous nerve (AIN) and 40% from the median nerve (MN), with an average anastomosis length of 12.9 cm. In the right arm, 33.33 % of the axons originated from the AIN and 66.66% from the MN, with an average length of the anastomosis of 12.2 cm. (Table 1, Figures 1 and 2) As to the demographic distribution of the specimens, 79% were males, and 21% were females, with an average age of 50.5 years. To further assess whether the occurrence of the Martin-Gruber anastomosis's preference for nerve of origin differs based on the side of the arm, we conducted a Chi-square test of independence. The

analysis yielded a Pearson Chi-square statistic of 0.06 ( $p=0.81$ ). This implies that the frequency of anastomosis originating from either the AIN or the Median nerve was independent of whether it was in the left or right arm. Additionally, to evaluate the potential association between sex and the presence of the anastomosis, a Chi-square test was performed. The results showed a Pearson Chi-square value of 2.82 ( $p=0.09$ ). Although this analysis did not reveal a statistically significant association between the presence of Martin-Gruber anastomosis and the sex of the specimens, there was a trend suggesting that this could warrant further investigation with a larger sample size.

DISCUSSION

Hand and forearm injuries are a common diagnosis in emergency services worldwide, resulting in a

Table 1: Nerve of origin in the presence of Martin-Gruber anastomosis

Nerve of origin		Frequency	Percentage
Right arm	AIN	5	33.33%
	Median nerve	10	66.66%
Left arm	AIN	6	40%
	Median nerve	9	60%

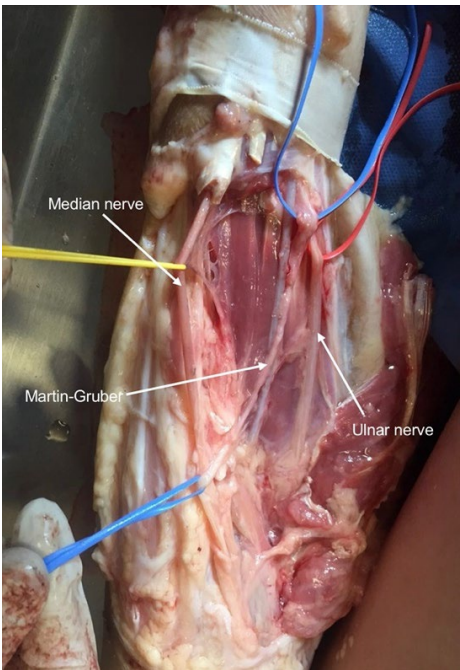


Figure 1: Martin-Gruber anastomosis originating from the main trunk of the median nerve to the main trunk of the ulnar nerve

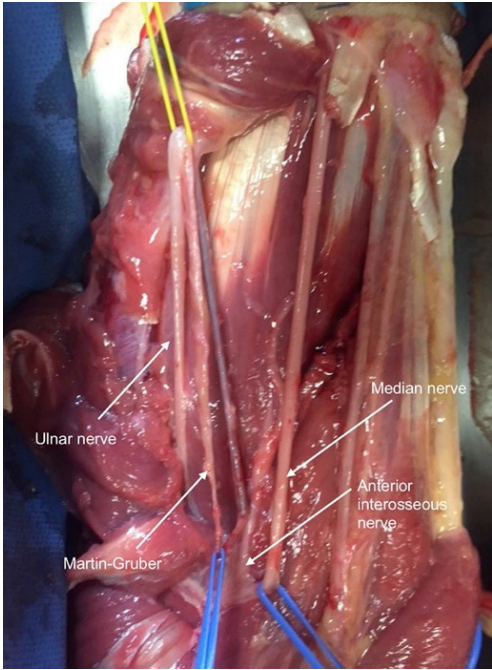


Figure 2: Martin-Gruber anastomosis originating from the anterior interosseous nerve to the main trunk of the ulnar nerve

high incidence of sequelae and disability. Of these, nerve injuries are the most catastrophic for the functional prognosis of the patient. Moreover, incorrect identification of these injuries worsens the patient's prognosis and sometimes leads to unnecessary treatment. Previous descriptions of anatomical variants in the forearm have been made in populations unrelated to this cohort's ethnic group<sup>5,8-10</sup>. Therefore, we decided to identify the presence of Martin-Gruber anastomosis to estimate its prevalence in a cohort with similar demographic characteristics.

The present descriptive study aimed to determine the presence and frequency of Martin-Gruber anastomoses through a corpse-dissection of a sample of 40 specimens in Mexico. It is accepted that between 15-31% of the population presents a forearm anastomosis from the median nerve to the ulnar nerve, which abnormally innervates the intrinsic muscles of the hand instead of being traditionally innervated by axons of the ulnar nerve<sup>3</sup>. However, this study found a prevalence of almost 50% among the studied specimens, which could have relevant diagnostic and clinical implications for our population.

The changes in muscular innervation of the upper limb produced by nerve anastomoses and anatomical variations hinder an adequate clinical diagnosis of peripheral nerve injuries. Remarkably, due to the pattern of innervation in the intrinsic muscles of the hand, it is usually observed that patients who present this variation and suffer from median nerve injury do not demonstrate motor alterations or complete motor deficits. Thus, in the presence of anastomosis between the median and the ulnar nerve, a complete median nerve lesion can be mistakenly interpreted as a partial lesion<sup>11</sup>.

This is particularly important in patients with focal neuropathy of the upper limb that are potential candidates for surgical intervention. We strongly suggest that median to ulnar anastomosis (Martin-Gruber) — among other anatomical variants — be considered in these patients. Additionally, we encourage electrophysiological evaluations as a part of the diagnostic process for patients with upper limb neuropathies. This approach could substantially decrease the likelihood of misdiagnosis, thereby reducing unnecessary surgical interventions and improving patient outcomes<sup>12</sup>.

## CONCLUSION

The results of this study will hopefully shed light on the high prevalence (up to 50% in our cohort) of Martin-Gruber's anastomosis and its clinical implications in patients with ulnar nerve damage, promoting clinical suspicion of these anatomic variants. Furthermore, since ulnar intrinsic musculature can be preserved despite a complete section of the nerve in the presence of an anastomosis, electrophysiological evaluation should be contemplated as a diagnostic approach to avoid unnecessary surgical treatment. Hopefully, this study will lead to larger-scale descriptive studies that will allow for the estimation of a more accurate prevalence rate in populations with different ethnic backgrounds.

## ACKNOWLEDGEMENTS

This study was conducted without any external funding, and there were no financial or commercial conflicts of interest influencing the research process or outcomes.

## CONFLICTS OF INTEREST

The authors declare that there is no conflict of interests.

## REFERENCES

1. Duinslaeger L, DeBacker A, Ceulemans L, et al. Ulnar nerve injury with martin-gruber anastomosis. *Eur J Plast Surg* 1987; **10**:37-39. <https://doi.org/10.1007/BF00295651>
2. Leis AA, Stetkarova I, Wells KJ. Martin-Gruber anastomosis with anomalous superficial radial innervation to ulnar dorsum of hand: A pitfall when common variants coexist. *Muscle & Nerve* 2010; **41**(3):313-317. doi:10.1002/mus.21510
3. Kazakos KJ, Smyrnis A, Xarchas KC, Dimitrakopoulou A, Verettas DA. Anastomosis between the median and ulnar nerve in the forearm. An anatomic study and literature review. *Acta Orthop Belg* 2005; **71**(1):29-35.
4. Diz-Díaz J, Gómez-Muñoz E, Sañudo J, Marañillo E, Pascual-Font A, Vazquez T. Which is the function of a martin-gruber connection? *Clinical Anatomy* 2019; **32**(4):501-508. doi:10.1002/ca.23339
5. Kaur N, Singla RK, Kullar JS. Martin-Gruber

- Anastomosis- A Cadaveric Study in North Indian Population. *J Clin Diagn Res* 2016; **10**(2):AC09-11. doi:10.7860/JCDR/2016/16447.7247
6. Crutchfield CA, Gutmann L. Hereditary aspects of median-ulnar nerve communications. *J Neurol Neurosurg Psychiatry* 1980; **43**(1):53-55. doi:10.1136/jnnp.43.1.53
  7. Cavalheiro CS, Filho MR, Pedro G, Caetano MF, Vieira LA, Caetano EB. Clinical repercussions of Martin-Gruber anastomosis: anatomical study. *Rev Bras Ortop* 2016; **51**(2):214-223. doi:10.1016/j.rboe.2016.02.003
  8. Caetano EB, Vieira LÂ, Caetano MF, Cavalheiro CS, Razuk M, Sabongi JJ. Intramuscular martin-gruber anastomosis. *Acta Ortop Bras* 2016; **24**(2):94-97. doi:10.1590/1413-785220162402149097
  9. Sur A, Sinha M, Ughade J. Prevalence of Martin-Gruber Anastomosis in Healthy Subjects: An Electrophysiological Study from Raigarh, Chhattisgarh. *Neurol India* 2021; **69**(4):950. doi:10.4103/0028-3886.325369
  10. Hefny M, Sallam A, Abdellatif M, Okasha S, Orabi M. Electrophysiological Evaluation and Clinical Implication of Martin-Gruber Anastomosis in Healthy Subjects. *J Hand Surg Asian Pac Vol* 2020; **25**(1):87-94. doi:10.1142/S2424835520500125
  11. Unver Dogan N, Uysal II, Seker M. The communications between the ulnar and median nerves in upper limb. *Neuroanatomy* 2009; **8**:15-19.
  12. Kretschmer T, Heinen CW, Antoniadis G, Richter HP, König RW. Iatrogenic nerve injuries. *Neurosurg Clin N Am* 2009; **20**(1):73-vii. doi:10.1016/j.nec.2008.07.025