

# A Giant Osteochondroma of Mandibular Coronoid that Mimicking Coronoid Hyperplasia: A Rare Clinical Case Report

Moosa Mahmoudi <sup>1</sup>, Kianoosh Mobasseri <sup>2</sup>, Sara Samiei <sup>2</sup>, Ali Labafchi <sup>2,3\*</sup>

1. Oral and maxillofacial Diseases Research Center, Kerman University of Medical Sciences, Kerman, Iran
2. Department of Oral and Maxillofacial Surgery, Dental School, Kerman University of Medical Sciences, Kerman, Iran
3. Student Research Committee, Dental School, Kerman University of Medical Sciences, Kerman, Iran

## ABSTRACT

Osteochondroma, the most common benign tumor in the axial and appendicular skeleton, presents a unique challenge when encountered in the craniofacial region. We report a rare case of a 35-year-old female with a massive osteochondroma located on the mandibular coronoid process, resulting in a 20-year history of progressive mouth opening limitation, facial asymmetry, and zygomatic deformity. Comprehensive diagnostic procedures, including panoramic radiography and computed tomography (CT) imaging, were employed to accurately assess the extent of the lesion. This case highlights the importance of CT scans and three-dimensional reconstructions in confirming the diagnosis, particularly when panoramic radiographs exhibit limitations. The patient underwent a successful extraoral approach for coronoidectomy and excision of the osteochondroma, addressing both the functional and cosmetic aspects of the condition. Postoperative evaluations revealed significant improvement in mouth opening capacity, with no signs of recurrence during a 12-month follow-up period.

## KEYWORDS

Osteochondroma; Coronoid process; Computed tomography

## Please cite this paper as:

Mahmoudi M, Mobasseri K, Samiei S, Labafchi A. A Giant Osteochondroma of Mandibular Coronoid that Mimicking Coronoid Hyperplasia: A Rare Clinical Case Report. *World J Plast Surg.* 2025;14(1):105-111. doi: 10.61186/wjps.14.1.105

## INTRODUCTION

The most frequent benign tumor in the axial and appendicular skeleton is osteochondroma. It is responsible for 35%-50% of benign bone tumors and 8%-15% of primary bone tumors. It has a distinctive mushroom shape and cartilage-capped protrusion. Although it may occur in the mandibular condyle or coronoid process, osteochondroma is uncommon in the maxillofacial bones considering most of them go through an intramembranous ossification developing phase <sup>1,2</sup>. In 1899, Jacob was the first to describe the occurrence of osteochondroma of the coronoid process, which results in the formation of a pseudojoint between the coronoid process and the zygoma. However, coronoid process hyperplasia had already been defined by Von Langenbeck back in 1853. Subsequently, this condition came to be known as Jacob disease <sup>3</sup>. Symptoms of this condition, whether it affects unilateral or bilateral, typically include an enlargement of the zygoma or zygomatic arch,

## \*Corresponding Author:

Ali Labafchi

Department of Oral and Maxillofacial Surgery, Dental School, Kerman University of Medical Sciences, Kerman, Iran

Tel.: +989158903237

Email: labafchiali@yahoo.com

Received: 11/24/2024

Accepted: 2/24/2024

accompanied by a sensation of tightness and limited mouth opening<sup>1, 4, 5</sup>. Interestingly, patients do not commonly experience pain as a symptom. While the origins of the disease are subject to debate, some researchers propose a genetic or endocrine cause, while others consider hyperactivity of the temporal muscle or displacement of the temporomandibular joint (TMJ) disc as potential factors. Despite disagreement among clinicians regarding the cause, certain demographic characteristics appear to be more established, namely a higher incidence in young males with an average age of 35<sup>3, 6</sup>.

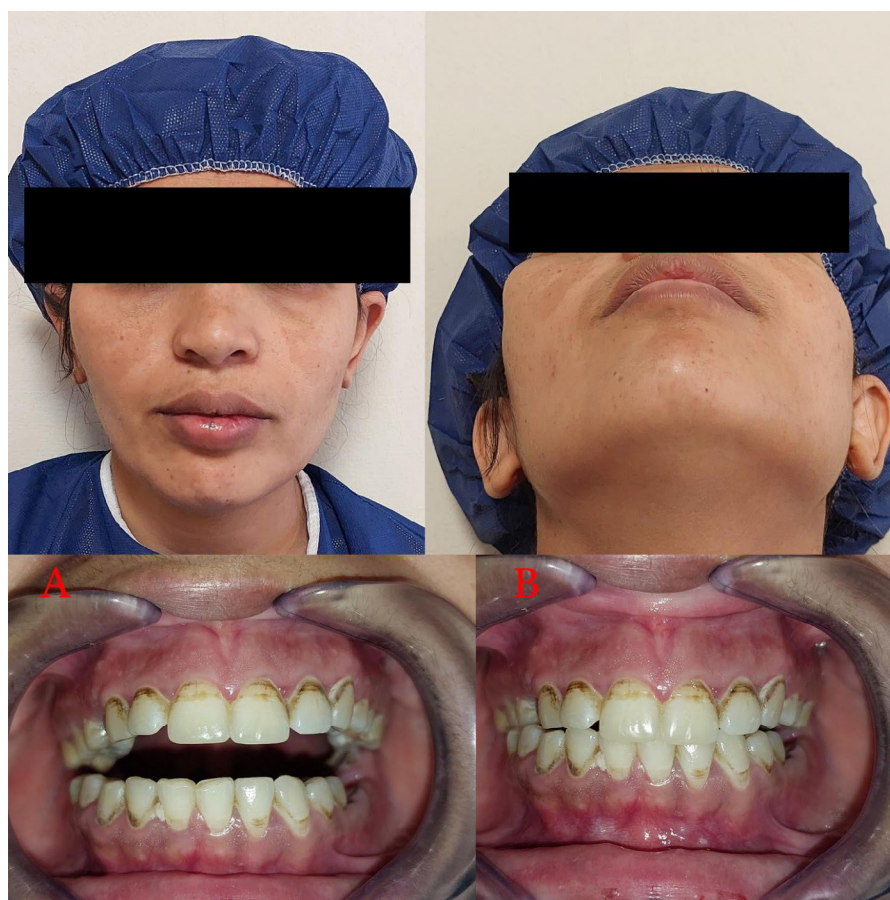Irrespective of the causes and demographic factors, the established treatment for this condition involves performing a coronoidectomy, as well as excising the tumor. Fortunately, the likelihood of osteochondroma recurrence is relatively low<sup>7</sup>. In this case report, we present a unique instance of a large osteochondroma located on the mandibular coronoid process, successfully treated through a coronoidectomy, along with the removal of the attached osteochondroma.

## CASE REPORT

All procedures performed in this study involving the human participant were in accordance with the ethical standards of our institutional research committee and with the 1964 Helsinki declaration. The patient's ethical consent form was signed and approved by the patient.

In Dec 2023, a 35-year-old female, a non-smoker case, was referred to the Department of Oral and Maxillofacial at Kerman University of Medical Sciences, Kerman, eastern Iran.

The patient had gradually lost the ability to open their mouth for 20 years. In the last two years, there had also been facial asymmetry and swelling in the right zygomatic area. No congenital bone disorders or history of trauma was mentioned, and no anomalies in other musculoskeletal regions were discovered. Physical examination revealed facial asymmetry and swelling in the area of the right zygomatic arch. The patient had a 5 mm maximum opening of their mouth (Figure 1). When opening the mouth, no



**Figure 1:** The deformity of right side of zygomatic arch; A: the maximum mouth opening. B: upper and lower dental view in occlusion with no significant findings

complaints related to the temporomandibular joint (TMJ), such as clicking or pain, were noted.

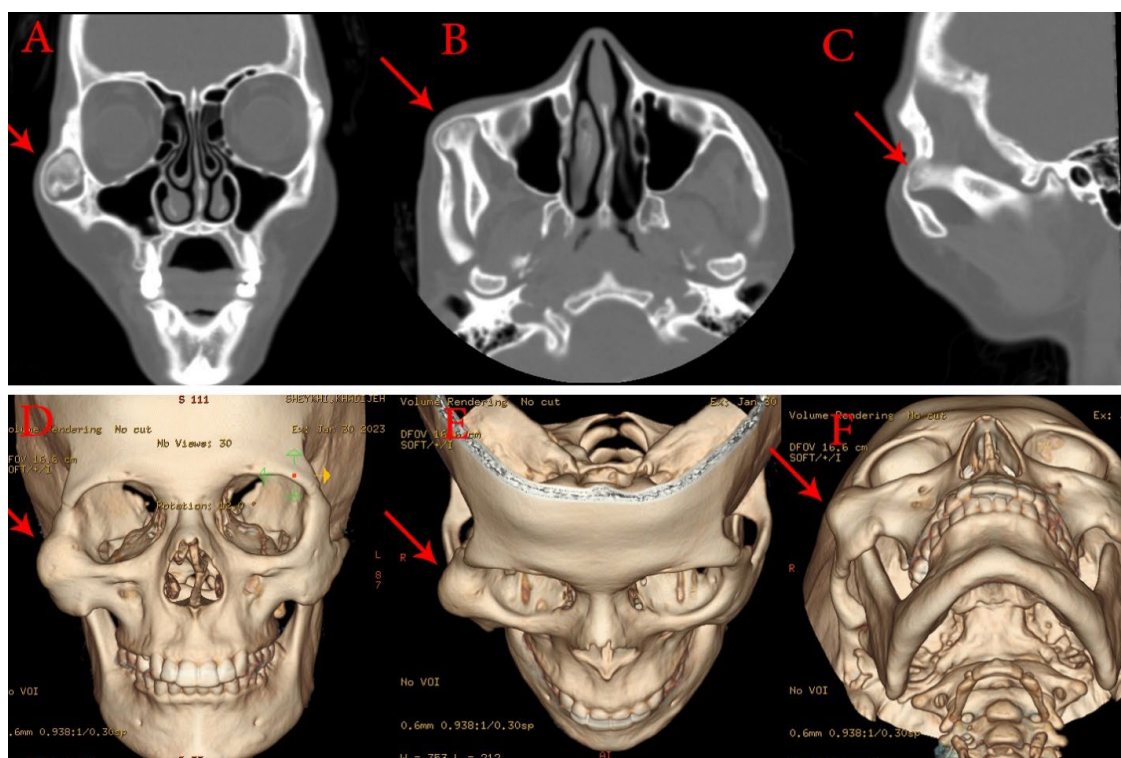
A panoramic radiograph was utilized to assess the condition, revealing an enlargement of the right coronoid process. However, due to limited clarity and the inability to accurately determine the size and shape of the hyperplastic left coronoid process, a computed tomography (CT) scan was performed for a more detailed diagnosis. The CT scan revealed the presence of a mushroom-shaped outgrowth extending from the lateral aspect of the coronoid process to the inner surface of the zygomatic arch. This outgrowth exhibited outward expansion, forming a pseudojoint. Additionally, the zygomatic arch had undergone remodeling, positioning itself more outwardly in comparison to the unaffected right side. This remodeling led to facial asymmetry, manifested clinically as swelling over the zygoma region. Based on these findings, the patient was scheduled for a left coronoidectomy, along with the excision of the osteochondroma mass (Figure 2).

Due to the significant restriction in mouth opening experienced by the patient, all procedures were performed under general anesthesia with the use

of fiberoptic nasotracheal intubation. After nasal intubation, a right-sided hemi-coronal incision was made. Subsequently, the tissues were carefully dissected to gain access to the right zygomatic arch. The zygomatic arch was then precisely cut using a surgical saw through an osteotomy procedure, and a right coronoidectomy was performed. The immediate result of the coronoidectomy was an improvement in the patient's maximum mouth opening capacity. The protruding portion of the zygoma was cut using a saw and then reshaped and adjusted using a miniplate at the site of fixation. Furthermore, the zygomatic arch was stabilized and fixed using a miniplate.

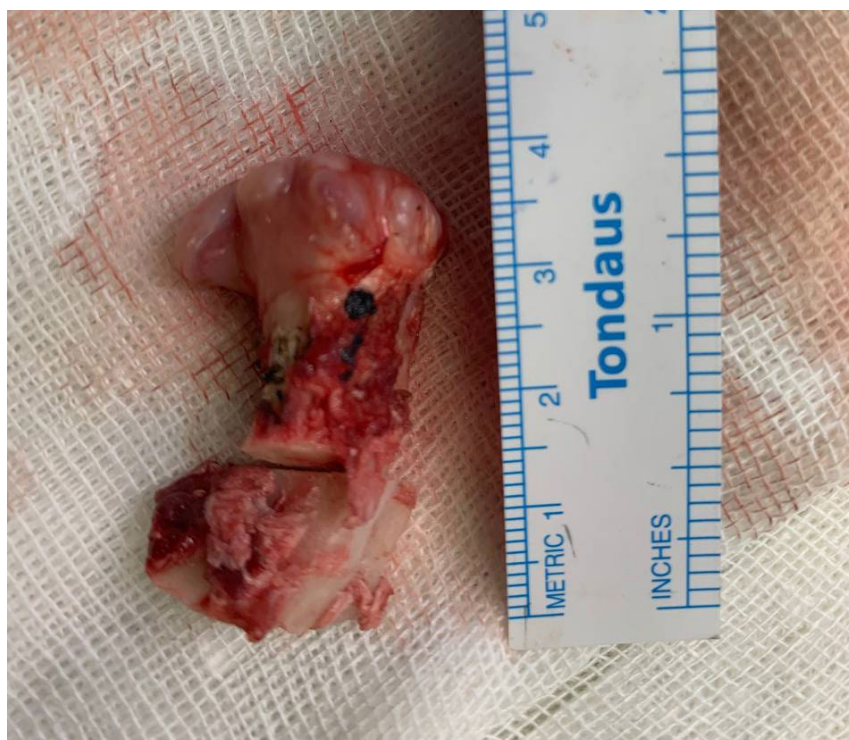The post-operative radiograph revealed complete excision of the tumor and the right coronoid process. The dimensions of the mass were approximately  $2.7 \times 2.5 \times 1.5$  cm (Figure 3). Histologically, the tumor exhibited three distinct layers, starting from the surface and progressing towards the interior: fibrous tissue, mature cartilaginous tissue, and mature cancellous bone. This histological finding confirmed the diagnosis of osteochondroma (OC) (Figure 4).

Following the surgical procedure, the patient

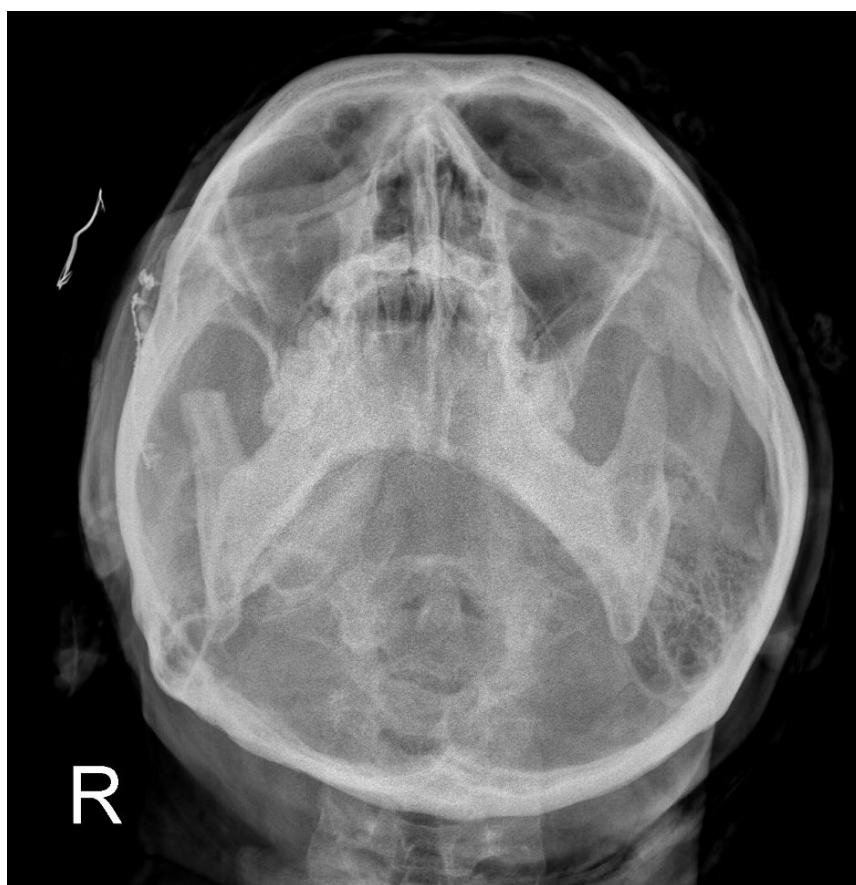

**Figure 2:** A: The CT axial section exhibits an osseous enlargement seamlessly connected to the extremity of the right coronoid process. B: The CT coronal section displays the elongation of the right coronoid mass along the inner surface of the zygomatic arch. C: The sagittal section of the CT scan reveals an outward growth of the left coronoid process. D,E,F: 3D view of zygomatic arch deformity due to OC

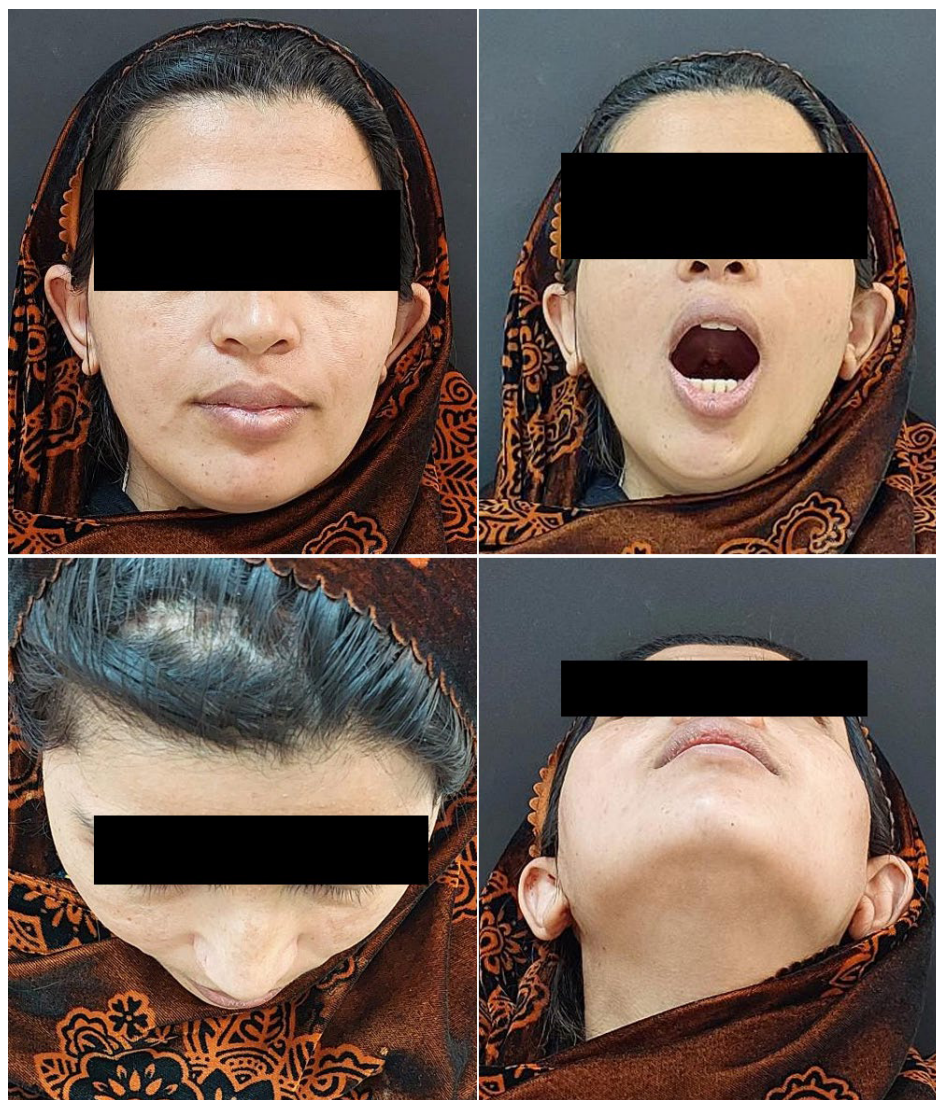



**Figure 3:** The gross surgical specimen around 4.0 X 2.0 cm, which was white in color, smooth surfaced and hard in consistency



**Figure 4:** post-operation radiography that revealed the absence of right side coronoid



**Figure 5:** Post-operation images in the closed-mouth position demonstrate enhanced improvement in the deformity of the right zygomatic arch. In the open-mouth position, there is a noticeable enhancement in facial symmetry, and an increase in Maximum Mouth Opening (MMO) is observed

demonstrated a mouth opening capacity of 35 millimeters. Subsequent to a 12-month postoperative observation, no indications of recurrence were identified, and the patient remained asymptomatic. Ongoing surveillance is being conducted at six-month intervals, with plans for an extended follow-up duration (Figure 5).

## DISCUSSION

While osteochondroma (OC) is infrequently observed in the facial, it has been documented in the maxillary sinus and various regions of the mandible, including the condyle, ramus, body, and symphyseal region<sup>8</sup>. Osteochondroma constitutes approximately 35.5% of benign bone tumors and 8.5% of all bone

tumors overall. When it manifests in the coronoid process, there is a slight predilection for males, with a preference for the left coronoid process<sup>9</sup>.

This mushroom-like growth, capped with cartilage, is usually identified with probing of the afflicted region or regular radiography checks are used to identify it initially. A CT scan with three-dimensional reconstruction is warranted if any of these suggestive indicators exist in order to validate the clinician's findings<sup>5</sup>.

Usually, probing of the afflicted region or regular radiography checks are used to identify it initially. A computed tomography (CT) scan with three-dimensional reconstruction is warranted if any of these suggestive indicators exist in order to validate the clinician's findings.



In this particular case, 3D reconstruction scans and CT imaging clearly showed an expanded coronoid process and an osteoid mass resembling a mushroom. In order to confirm the diagnosis, evaluate the size and connection of the tumor to surrounding tissues, and aid in surgical planning, 3D reconstruction, sometimes referred to as 3DCT, is essential. According to Totsuka et al., CT offered precise information regarding the morphology of the enlarged coronoid process and the displaced surrounding bone in addition to revealing the enlargement of the coronoid process and abnormalities in the surrounding bones<sup>5</sup>. Additionally, a number of authors, including Kerscher et al. and Yesildag et al., have documented the benefits of CT imaging<sup>4, 10-12</sup>. Due to this, in the current case, we were unable to establish the diagnosis of osteochondroma using panoramic radiography alone. Additionally, we used CT scan imaging to verify the presence of a mass whose morphological features matched those reported in earlier publications.

Osteochondroma's principal clinical symptom is restricted mouth opening. It is typical to see lateral deviation toward the afflicted side, although disocclusion and discomfort are less frequent clinical signs<sup>4</sup>. Other than the restriction of mouth opening, there were no particular complaints or further clinical findings in the case that was described.

OC is characterized histologically by the presence of bony trabeculae coated in fibrous tissue and a cartilaginous cap. It is important to explore the potential of various lesions while investigating the differential diagnosis of OC. These lesions include hyperplasia, chondroma, osteoma, and odd parosteal osteochondromatous proliferations. Furthermore, less common bone cancers such metastatic tumors and chondroblastomas, osteoblastomas, chondrosarcomas, and osteosarcomas should also be taken into account.<sup>4, 7, 10</sup>

The two major surgical techniques include intraoral and extraoral, or a combination of either. Since it offers a straight line to the coronoid process and reduces the possibility of scarring and facial nerve damage, the intraoral technique is frequently chosen. On the other hand, difficulties might occur in severe trismus patients, which could hinder surgical access. When the mass is huge and situated close to the zygomatic arch, an extraoral method facilitates better access and vision.<sup>13, 14</sup>. The tumor

in this particular case was rather enormous, and the patient's ability to mouth opening was severely restricted. The coronoid process was firmly entrapped in the zygomatic arch, with the additional consideration of reshaping the zygoma deformity, we opted for a successful extraoral approach in the surgical intervention.

## CONCLUSION

This case report contributes to the understanding of osteochondroma in the craniofacial bones, emphasizing the role of advanced imaging techniques in diagnosis and the efficacy of surgical interventions, such as coronoidectomy, in achieving favorable outcomes. The prognosis remains excellent, highlighting the importance of timely intervention and the rarity of recurrence or malignant transformation in osteochondromas of the craniofacial region.

## ACKNOWLEDGEMENTS

The authors appreciate the continued support of the Research Council of Kerman University of Medical Sciences, Kerman, Iran.

## FUNDING

None.

## CONFLICT OF INTERESTS

None.

## REFERENCES

1. Stringer DE, Chatelain KB, Tandon R. Surgical Treatment of Jacob's Disease: A Case Report Involving an Osteochondroma of the Coronoid Process. *Case Rep Surg* 2013;**2013**:253740.
2. Aoki N, Okamura K, Niino D, Iwamoto O, Kusakawa J. Osteochondroma of the right coronoid process (Jacob disease): a case report. *Cranio* 2013 Jan;**31**(1):66-9.
3. Roychoudhury A, Gupta YK, Parkash H, Karak AK. Jacob disease: report of a case and review of the literature. *J Oral Maxillofac Surg* 2002 Jun;**60**(6):699-703.
4. Kerscher A, Piette E, Tideman H, Wu PC. Osteochondroma of the coronoid process of the

- mandible. Report of a case and review of the literature. *Oral Surg Oral Med Oral Pathol* 1993 May;**75**(5):559-64.
5. Totsuka Y, Fukuda H, Iizuka T, Shindoh M, Amemiya A. Osteochondroma of the coronoid process of the mandible. Report of a case showing histological evidence of neoplasia. *J Craniomaxillofac Surg* 1990 Jan;**18**(1):27-32.
  6. Gross M, Gavish A, Calderon S, Gazit E. The coronoid process as a cause of mandibular hypomobility--case reports. *J Oral Rehabil* 1997 Oct;**24**(10):776-81.
  7. Dandriyal R, Giri KY, Pant S, Alam S, Joshi A. Giant osteochondroma of the coronoid process. *J Maxillofac Oral Surg* 2015 Mar;**14**(Suppl 1):412-6.
  8. Kung'u A. Tumours of bone and cartilage. *East Afr Med J* 1978 Dec;**55**(12):572-8.
  9. Vezeau PJ, Fridrich KL, Vincent SD. Osteochondroma of the mandibular condyle: literature review and report of two atypical cases. *J Oral Maxillofac Surg* 1995 Aug;**53**(8):954-63.
  10. Emekli U, Aslan A, Onel D, Cizmeci O, Demiryont M. Osteochondroma of the coronoid process (Jacob's disease). *J Oral Maxillofac Surg* 2002 Nov;**60**(11):1354-6.
  11. Tavassol F, Spalthoff S, Essig H, Brecht M, Gellrich NC, Kokemüller H. Elongated coronoid process: CT-based quantitative analysis of the coronoid process and review of literature. *Int J Oral Maxillofac Surg* 2012 Mar;**41**(3):331-8.
  12. Yesildag A, Yarikas M, Doner F, Aydin G, Munduz M, Topal U. Osteochondroma of the coronoid process and joint formation with zygomatic arch (jacob disease): report of a case. *Eur J Dent* 2010 Jan;**4**(1):91-4.
  13. Hernández-Alfaro F, Escuder O, Marco V. Joint formation between an osteochondroma of the coronoid process and the zygomatic arch (Jacob disease): report of case and review of literature. *J Oral Maxillofac Surg* 2000 Feb;**58**(2):227-32.
  14. Lan T, Liu X, Liang PS, Tao Q. Osteochondroma of the coronoid process: A case report and review of the literature. *Oncol Lett* 2019 Sep;**18**(3):2270-7.