

Unilateral Sensation Loss of the NAC After Superomedial Pedicle Reduction Mammoplasty

Elif Sari*

Kirikkale University Faculty of Medicine,
Department of Plastic, Reconstructive and
Aesthetic Surgery, Kirikkale, Turkey

DEAR EDITOR

Superomedial pedicle reduction mammoplasty has become the most preferred technique in our clinic. While performing the technique, the surgeon can predict the final breast volume and shape, as well as limit sensation loss of the nipple-areola complex (NAC).¹ Another advantage of this procedure is the improved long-term projection of the breast. Moreover, the technique obtains younger-looking breasts with elevated inframammary folds.¹

A total of 40 patients were operated by using superomedial pedicle reduction mammoplasty technique last year in our clinic. However, sensation loss of the NAC has not been reported except one patient. The aim of this letter is to report a unilateral sensation loss of the NAC of a patient who underwent reduction mammoplasty by using superomedial pedicle technique.

A 33-year-old female patient without any systemic disease was admitted to our clinic with macromasty (Figure 1a). Her body mass index was 27 kg/m². The distance between the sternal notch-to-nipple was 30 cm in right breast, and 31 cm in left one before the surgery. The classical superomedial pedicle reduction mammoplasty was performed. A total of 310 g soft tissue was removed in right breast, and 315 g in left one. The NAC transposition was 10 cm in right breast and 11 cm in left breast. No complication was occurred during or after the surgery such as hematoma, infection, seroma, wound healing problem or NAC necrosis.

The patient was followed-up for 12 months. In the first month visit, she suffered from sensation difference between two NAC of the breasts. Complete sensation loss of the right NAC was detected in Semmes-Weinstein monofilaments test. The sensation loss was not resolved during the other visits in 3rd, 6th and 12th months (Figure 1b). This complication could not based on any reason such as nerve injury or traction of the soft tissues. Because, it was reported that the NAC is only innervated by the third, fourth, or fifth intercostal nerves.²

Reduction mammoplasty is an effective surgical procedure to improve the quality of life, especially in severe gigantomasty patients.³ However, loss of sensation of the NAC is a major challenge for plastic surgeons. Heine *et al.*⁴ treated 25 gigantomasty patients by using Lejour technique, and reported a reduced NAC sensation in 8 patients (32%). However, Nahabedian *et al.*⁵ reported a 98% retained NAC sensation after medial-pedicle

* Corresponding Authors:

Elif Sari, MD,
Kirikkale University, Faculty of
Medicine,
Department of Plastic, Reconstructive
and Aesthetic Surgery,
Ankara, Kirikkale Road, 7th km
Yahsihan, 71450 Kirikkale, Turkey
Tel: +90-506-3813703
Fax: +90-580-2252819
E-mail: drelifsanli@hotmail.com
Received: Dec. 20, 2014
Revised: Feb. 11, 2015
Accepted: March 20, 2015

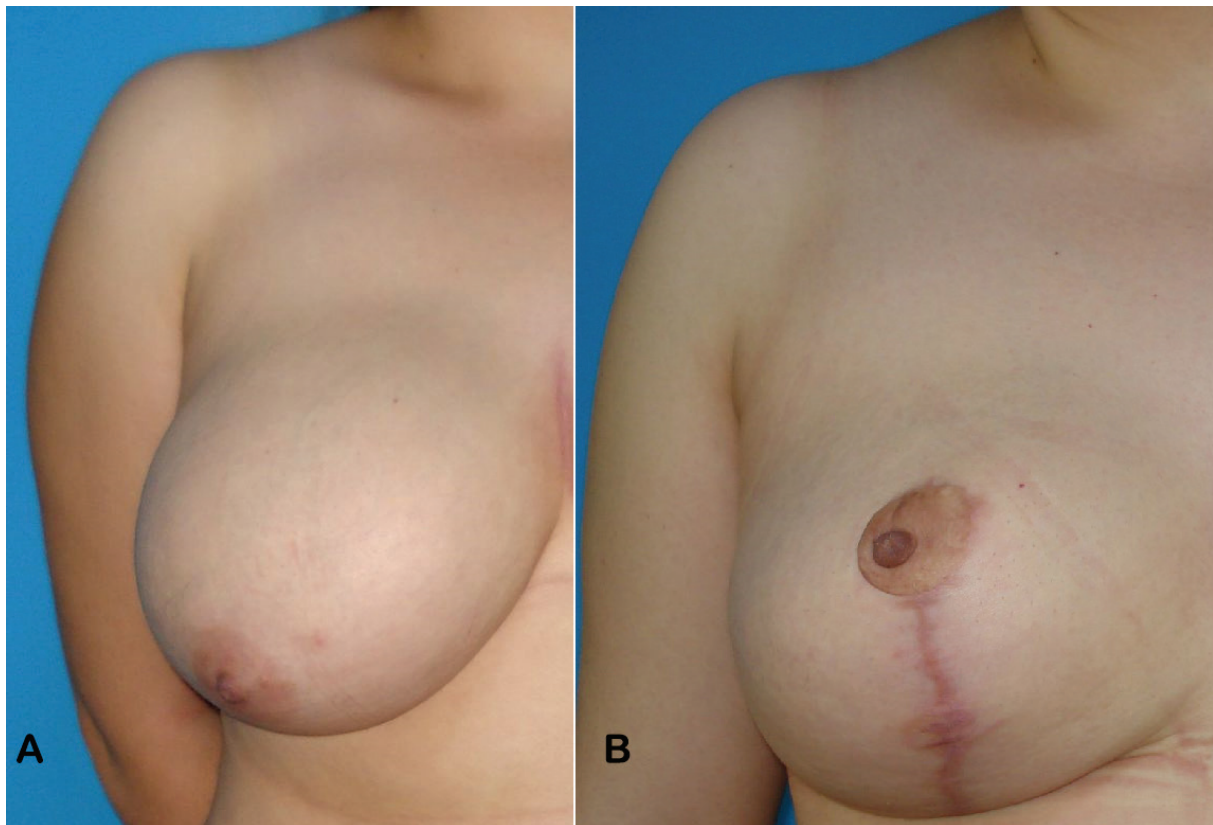


Fig. 1: Picture of a 33-year-old female patient who underwent superomedial pedicle reduction mammoplasty. **(a)** Preoperative frontal view of the right breast, and **(b)** postoperative 6th month frontal view of the right breast were demonstrated in these figures.

reduction mammoplasty.

Similarly, Lugo *et al.*¹ reported 98% normal sensation of the NAC in 200 patients treated with superomedial pedicle reduction mammoplasty. To the best of our knowledge, unilateral sensation loss of the NAC in superomedial reduction mammoplasty was not reported before. Actually, we could not understand the reason of this complication and decided to share this case with our colleagues.

CONFLICT OF INTEREST

The authors declare no conflict of interest.

KEYWORDS

Nipple-areola complex; Sensation; Reduction mammoplasty

Please cite this paper as:

Sari E. Unilateral Sensation Loss of the NAC After Superomedial Pedicle Reduction Mammoplasty. *World J Plast Surg* 2015;4(2):175-176.

REFERENCES

- 1 Lugo LM, Prada M, Kohanzadeh S, Mesa JM, Long JN, Torre J. Surgical outcomes of gigantomastia breast reduction superomedial pedicle technique. *Ann Plast Surg* 2013;**70**:533-7.
- 2 Kuzbari R, Schlenz I. Reduction mammoplasty and sensitivity of the nipple-areola complex. Sensuality versus sexuality? *Ann Plast Surg* 2007;**58**:3-11.
- 3 Spear ME, Nanney LB, Phillips S, Donahue R, Rogers KM, Wendel JJ, Summit B, Kelly K, Shack RB, Hagan KF. The impact of reduction mammoplasty on breast sensation. *Ann Plast Surg* 2012;**68**:142-9.
- 4 Heine N, Eisenmann-Klein M, Prantl L. Gigantomasty: treatment with a short vertical scar. *Aesthetic Plast Surg* 2008;**32**:41-7.
- 5 Nahabedian MY, McGibbon BM, Manson PN. Medial pedicle reduction mammoplasty for severe mammary hypertrophy. *Plast Reconstr Surg* 2000;**105**:896-904.