Original Article

Evaluation of the Imaging Characteristics of Rhino-Orbital Cerebral Mucormycosis

Ayeh Kiani[1], Mohammad Ghasem Hanafi[2], Shokrollah Salmanzadeh[3], Golshan Mirmomeni[4], Zahra Javadzade[1]*

1. Department of Otolaryngology, Head and Neck Surgery, Imam Khomeini Hospital, Ahvaz Jundishapur University of Medical Science, Ahvaz, Iran
2. Department of Radiology, Ahvaz Jundishapur University of Medical Sciences, Ahvaz, Iran
3. Department of Infectious Diseases, Faculty of Medicine, Ahvaz Jundishapur University of Medical Sciences, Ahvaz, Iran
4. Hearing Research Center, Ahvaz Jundishapur University of Medical Sciences, Ahvaz, Iran

***Corresponding Author:**

Dr. Zahra Javadzade, MD

Department of Otolaryngology, Head and Neck Surgery, Imam Khomeini Hospital, Ahvaz Jundishapur University of Medical Science, Ahvaz, Iran

Email: zahrajavadzade4@gmail.com

Received: 02/05/2025
Accepted: 08/14/2025

ABSTRACT

Background: Mucormycosis is a fungal infection with diverse clinical manifestations, the most common of which, i.e., the classical form of rhino-orbital cerebral mucormycosis (ROCM), has had a significant prevalence among patients recovered from COVID-19. We aimed to investigate the findings of ROCM imaging recorded at Imam Khomeini Hospital in Ahvaz, Iran, in 2022.

Methods: This retrospective study reviewed the files of patients definitively diagnosed with mucormycosis and COVID-19. Imaging procedures performed on patients included non-contrast CT scans (CT imaging protocol: from vertex to mandible without contrast for evaluating sinus contents, bone erosion, osteomyelitis, pre-sinus or orbital invasion). Key imaging findings were assessed and documented, and findings were evaluated.

Results: The mean age of subjects was 53.11 ± 14 years, with the majority being male (55.3%). All subjects had nasal and sinus involvement, but their brains were unaffected. Approximately 36% of subjects had ocular involvement. In imaging findings, left pterygopalatine involvement had the highest prevalence (27.7%), while left extraocular muscle involvement had the lowest prevalence (4.3%). Patients with lamina papyracea and extraocular muscle involvement all had ocular involvement, which was statistically significant. Additionally, those with hard palate erosion had significantly higher ocular involvement rates (5 out of 6 cases with hard palate erosion).

Conclusion: Rhino-orbital cerebral mucormycosis is associated with nasal and sinus involvement, and diabetes and male gender are predisposing factors to this disease. CT, as a complement to other clinical evaluations, dramatically aids in diagnosing and identifying the extent and complications of the disease.

KEYWORDS
Rhino-orbital cerebral mucormycosis (ROCM 9); Mucormycosis; Imaging

Please cite this paper as:
Kiani A, Hanafi MG, Salmanzadeh S, Mirmomeni G, Javadzade Z. Evaluation of the Imaging Characteristics of Rhino-Orbital Cerebral Mucormycosis. World J Plast Surg. 2025;14(2):79-85.
doi: 10.61186/wjps.14.2.79

INTRODUCTION

The potentially fatal infection known as mucormycosis (MCR) is brought on by saprophytic fungi that belong to the genera Rhizopus, Absidia, and Mucor. Immunocompromised individuals usually exclusively experience this condition since normal phagocytosis in

[Downloaded from wjps.ir on 2026-11-25]

[DOI: 10.61882/wjps.14.2.79]

immunocompetent hosts acts as a sufficient barrier against infection [1].

The COVID-19 pandemic has resulted in a rise in MCR cases, given rise to a new illness known as Coronavirus-associated Mucormycosis (CAM) [2]. Corticosteroids used in the treatment of COVID-19 have been identified as a potential risk factor for MCR infection due to their immunosuppressive effects and alteration of glucose homeostasis. Furthermore, severe COVID-19 disease with hyperferritinemia increases the risk of cellular damage and subsequent elevation of free iron levels, leading to an increased risk of MCR [3, 4].

The vascular invasion-induced tissue necrosis and subsequent thrombosis are the clinical hallmarks of invasive MCR. Unless the underlying risk factors (metabolic acidosis) are treated, vigorous antifungal therapy and surgical debridement are undertaken, the infection is typically very progressive and will eventually result in mortality. Based on clinical manifestations and anatomical site, invasive MCR has six main clinical presentations: (1) rhinocerebral, (2) pulmonary, (3) cutaneous, (4) gastrointestinal, (5) disseminated, and (6) uncommon forms (e.g., endocarditis, osteomyelitis, peritonitis, and renal infection) [5]. Each species of Mucorales can potentially cause infection in these sites. The most reported common sites of invasive MCR are sinuses (39%), lungs (24%), and skin (19%), respectively [6]. The classical form of rhino-orbital cerebral mucormycosis (ROCM) is MCR's most common clinical hallmark [7].

Orbital extension manifestations include periorbital swelling, palpable edema, orbital cellulitis, proptosis, chemosis, decreased vision, vitritis, endophthalmitis, orbital apex syndrome, and ophthalmoplegia. Almost all patients diagnosed with intracranial involvement also suffer from orbital involvement [8].

Prompt action and early diagnosis are the key factors in successful treatment of this disease [9-11]. Therefore, initial imaging for assessing the extent of this deadly disease is functional and can lead to timely diagnosis and prevention of more severe complications. Imaging helps confirm clinical suspicion, assess disease extent and complications, and follow the treatment course [12].

CT and MRI aid in the early diagnosis of ROCM before surgery. Imaging plays a vital role in evaluating the extent of the disease and guiding the management of patient treatment and surgery. Typical findings on CT include sinonasal opacification and obliteration of deep neck fat planes. Osteolysis, if present, is easily recognized in CT bone window views. In an appropriate clinical setting, imaging features of ROCM are diagnostic [13].

It is crucial to diagnose MCR as soon as possible, as it increases the chances of survival, reduces the need for surgery, and decreases patient suffering [14].

Given the importance of rapid diagnosis of this disease, as well as its serious complications, high mortality rate, and increased prevalence during the COVID-19 pandemic, the present retrospective study was conducted to determine imaging findings of rhino-orbital cerebral mucormycosis (ROCM).

MATERIAL AND METHODS

Ethical considerations

This study was approved by the Golestan Hospital Research Ethics Committee (Ethics code: IR. IR.AJUMS.HGOLESTAN.REC.1401.078).

In this retrospective study, the records of 47 patients diagnosed with mucormycosis (using histopathology and/or culture methods) and COVID-19 (using PCR) were reviewed. The statistical population included patients hospitalized at Imam Khomeini Hospital in Ahvaz in 2022 undergone CT imaging in the PACS system.

Organizational and ethical approval was obtained for collecting demographic, clinical, and imaging data (recorded in the PACS system). The reviewed images included non-contrast CT images (CT imaging protocol: from vertex to mandible without contrast for evaluating sinus contents, bone erosion, osteomyelitis, pre-sinus or orbital invasion) stored in the PACS system.

Key imaging findings are as follows:

Stage 1: Search for specific signs of invasive sinusitis other than thickening or non-specific mucosal collection, including palate erosion, pterygopalatine fossa involvement, and bone erosion in maxillary sinus walls (Figure 1).

Stage 2: Looking for specific signs of sinusitis invading the orbit (Figure 2), including early involvement of the internal wall of the orbit and extraocular muscles, as well as erosion in lamina papyracea.

Demographic and clinical information of patients including age, gender, underlying diseases, and history of immunosuppressive drug use were

[Downloaded from wjps.ir on 2026-11-25]

[DOI: 10.61882/wjps.14.2.79]



Figure 1: a) Hard palate erosion, b) Left pterygopalatine fossa involvement; c) Left posterior maxillary wall erosion

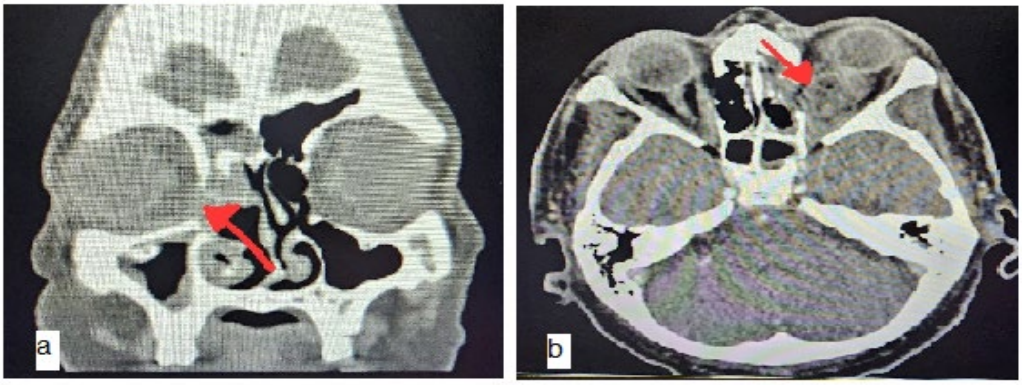

Figure 2: a) Right lamina papyracea erosion; b) Left extraocular muscle involvement

extracted from their records. Then, their imaging findings were collected, and the findings were examined.

Statistical Analysis

All collected data were analyzed using SPSS software v. 26 (IBM Corp., Armonk, NY, USA), and statistical analyses, including t-test and chi-square, were performed. A *P*-value <0.05 was considered statistically significant.

RESULTS

The mean age of subjects was 53.11 ± 14 years, with the majority being male (55.3%). 70.2% of subjects had a history of using immunosuppressive medications. All subjects had nasal and sinus involvement, but their brain was unaffected. Approximately 36% of subjects had ocular involvement. Among the imaging findings, the involvement of left pterygopalatine and left extraocular muscles had the highest (27.7%) and lowest (4.3%) prevalence, respectively (Table 1).

In the analysis performed, there was a correlation between gender, age, and use of immunosuppressive drugs with involvement of the nose, sinuses, eyes, and brain. Patients with nasal and sinus involvement were mostly had a history of taking immunosuppressive medications; however, this correlation was not statistically significant. Additionally, younger patients with less immunosuppressive medications were more likely to have ocular involvement; however, this difference was not statistically significant (Table 2).

The CT scan findings of patients showed that "left posterior maxillary wall erosion + left pterygopalatine involvement" and "left pterygopalatine involvement + left lamina papyracea erosion" had the highest prevalence among patients.

In the evaluation of the relationship between the general patterns of CT scan findings and sinus, nasal, ocular, and brain involvement, it was found that among patients with ocular involvement (n=17), 4 cases had "left pterygopalatine involvement + left lamina papyracea erosion" and 3 cases had "hard palate erosion + right lamina papyracea erosion + right posterior maxillary wall erosion + right internal rectus muscle involvement + right pterygopalatine involvement" and these

[Downloaded from wjps.ir on 2026-11-25]

[DOI: 10.61882/wjps.14.2.79]

Table 1: Descriptive findings of study participants

Variable		Result
Age, year, mean±SD		53.91±14.00
Sex, n (%)	Male	26 (55.3)
	Female	21 (44.7)
Taking immunosuppressive drugs, n (%)		33 (70.2)
Nasal and sinus involvement, n (%)		47 (100)
Eye involvement, n (%)		17 (36.2)
Brain involvement, n (%)		0
Imaging findings, n (%)	Left pterygopalatine involvement	13 (27.7)
	Right pterygopalatine involvement	9 (19.1)
	Right Lamina Papyrus involvement	7 (14.9)
	Left Lamina Papyrus involvement	9 (19.1)
	Hard palate erosion	6 (12.8)
	Involvement of the left maxillary posterior wall	8 (17)
	Right extraocular muscle involvement	4 (8.5)
	Left extraocular muscle involvement	2 (4.3)

Table 2: Correlation between indicators of gender, age, and history of using immunosuppressive medications with nose, sinus, eye, and brain involvement

Variable		Sex		*P*-value	Age (Year)	*P*-value	Taking immunosuppressive drugs		*P*-value
		Male	Female				Yes	No	
Nasal and sinus involvement	Yes	26	21	Ns	53.0±11.14	Ns	33	14	Ns
	No	0	0		0		0	0	
Eye involvement	Yes	12	5	0.113	52.0±14.14	0.585	14	3	0.204
	No	14	16		54.77±14.15		19	11	
Brain involvement	Yes	0	0	Ns	0	Ns	0	0	Ns
	No	21	26		53.0±11.14		33	14	

Ns: Non-significant.

numbers were statistically significant (*P*-value <0.001). Moreover, in patients without ocular involvement, 6 cases had "right pterygopalatine involvement + left posterior maxillary wall erosion + left pterygopalatine involvement". However, in other cases, no significant relationship was found between the imaging findings with brain and sinus involvement.

The results showed that all subjects with lamina papyracea and extraocular muscle involvement had ocular involvement, which is statistically significant. In addition, in subjects with hard palate erosion, the rate of ocular involvement was significantly higher (5 out of 6 cases); however, no statistically significant relationship was observed between the type of involvement observed in imaging with brain and sinus involvement (Table 3).

DISCUSSION

The objective of the current investigation was to ascertain the imaging results for rhino-orbital cerebral mucormycosis (ROCM). Mucormycosis is a rare and potentially fatal fungal illness that has experienced an unusual rise in cases worldwide due to the COVID-19 pandemic [15].

Ghayas Ansari et al. who evaluated the risk factors, clinical manifestations, and outcomes of mucormycosis, reported that among 50 patients, 78% had COVID-19; and mucormycosis was more common among males (58%) aged ≥40 (80%) (18) [16]. In our study, the mean age of the subjects was 53.11 ± 14 years, with the majority being male (55.3%), and with 70.2% using immunosuppressive medications. Comparing our findings with previous

[Downloaded from wjps.ir on 2026-11-25]

[DOI: 10.61882/wjps.14.2.79]

Table 3: Correlation of the type of involvement in imaging with brain, nose, and sinus involvement

Variable			Nasal and sinus involvement		P-value	Eye involvement		P-value	Brain involvement		P-value
			Yes	No		Yes	No		Yes	No	
Imaging findings	Left pterygopalatine involvement	Yes	13	0	Ns	6	7	0.378	0	13	Ns
		No	14	0		11	23		0	34	
	Right pterygopalatine involvement	Yes	9	0	Ns	5	4	0.252	0	9	Ns
		No	38	0		12	26		0	38	
	Right Lamina Papyrus involvement	Yes	7	0	Ns	7	0	0.001	0	40	Ns
		No	40	0		10	30		0	7	
	Left Lamina Papyrus involvement	Yes	9	0	Ns	9	0	0.001	0	9	Ns
		No	38	0		10	28		0	38	
	Hard palate erosion	Yes	6	0	Ns	5	1	0.018	0	6	Ns
		No	41	0		12	29		0	41	
	Involvement of the left maxillary posterior wall	Yes	8	0	Ns	2	6	0.692	0	8	Ns
		No	39	0		15	24		0	39	
	Right extraocular muscle involvement	Yes	4	0	Ns	4	0	0.013	0	4	Ns
		No	43	0		13	30		0	43	
	Left extraocular muscle involvement	Yes	2	0	Ns	2	0	0.126	0	2	Ns
		No	45	0		15	30		0	45	
	Right posterior maxillary wall involvement	Yes	4	0	Ns	3	1	0.128	0	4	Ns
		No	43	0		14	29		0	43	

studies revealed that older age and male gender are risk factors for mucormycosis. Currently, corticosteroids are the primary treatment for severe COVID-19 patients because they can effectively improve survival and reduce mortality in COVID-19 patients [17, 18]. Corticosteroid use impairs the phagocytosis ability of WBCs, making patients susceptible to fungal infections and even death [19].

In their study, Chakravarty et al. [20] reported that the most common manifestations of mucormycosis were rhino-orbital (n = 160; 76.9%), followed by rhino-orbital cerebral (n = 57; 27.4%), and nasal/sinus involvement was observed in only 49 (23.55%) patients. The predominant clinical manifestations in these patients were facial swelling (n = 201; 96.6%), followed by facial pain (n = 183; 88%), nasal discharge (53.4%), and visual impairment (n = 21.5%) and neurological manifestations included ocular involvement (n= 30; 13.7%), facial nerve palsy (n = 20; 9.1%), and sensory alterations (n = 16; 7.3%). In our study, all subjects had nasal and sinus involvement, but their brains were unaffected, and approximately 36% had ocular involvement. Due to differences in sample size, geographic location, and research methodology, critical comparison of the above findings with this study seems challenging.

The elevated incidence of mucormycosis during the COVID-19 pandemic may be due to host immunodeficiency along with the synergistic effects of thrombotic microangiopathy. The spread of infection to the infratemporal, orbital, or cavernous soft tissues occurs through neurovascular structures rather than bone erosion [21].

PAL et al. studied the spread and neurovascular involvement in patients with mucormycosis associated with COVID-19. Diagnosis was confirmed by potassium hydroxide (KOH) staining, fungal culture, or histopathological examination. Based on their study, the ethmoid sinus was involved in all patients. Pterygopalatine fossa involvement was present in 77.4% and was detected on MRI with contrast[22].

The nasal cavity is the first area to be infected after breathing in sporangiospores, resulting in nasal

[Downloaded from wjps.ir on 2026-11-25]

[DOI: 10.61882/wjps.14.2.79]

obstruction from thick discharge and crust, as well as blackening and necrosis of the nasal septum and turbinates (24). However, as demonstrated by PAL's study, where necrotic turbinates were seen in just 7 (22.6%) of the patients, this may not always be the case [18].

The infection then spreads to the paranasal sinuses, reaching the orbit, causing preseptal cellulitis, ophthalmoplegia, optic neuritis, and vision loss, or extending intracranially to involve the cavernous sinus. The infection may even spread inferiorly, leading to severe cavernous sinus thrombosis or affect soft tissue anteriorly without direct extension, as evidenced by the absence of posterior or anterior maxillary wall erosion, lamina papyracea, or cavernous sinus involvement [23].

Following sporangiospore inhalation, infection is transmitted from the sphenopalatine foramen to the pterygopalatine fossa. Subsequently, the pterygopalatine fossa acts as a disease focus, providing a pathway for infection to spread along various associated nerves and vessels [24].

In patients without ocular involvement, 6 cases had "right pterygopalatine involvement + left posterior maxillary wall erosion + left pterygopalatine involvement". However, in other cases, no significant relationship was found between the imaging findings with brain and sinus involvement. All subjects with lamina papyracea and extraocular muscle involvement had ocular involvement, which is statistically significant. In addition, in subjects with hard palate erosion, the rate of ocular involvement was significantly higher (5 out of 6 cases); however, no statistically significant relationship was observed between the type of involvement observed in imaging with brain and nasal/sinus involvement. To the best of our knowledge, there was no comprehensive study that we can refer to and criticize the findings of this part of the study, which is one of our study's strengths.

CONCLUSION

All subjects had nasal and sinus involvement, but their brains were not affected. In the imaging findings, left pterygopalatine and left extraocular muscle involvement had the highest and lowest prevalence, respectively. All subjects with lamina papyracea and extraocular muscle involvement had ocular involvement. Moreover, in cases with hard palate erosion, the rate of ocular involvement was significantly higher. According to the findings, it can be concluded that CT, as a complement to other clinical evaluations, greatly assists in diagnosing the extent and consequences of the disease.

CONFLICT OF INTERESTS

There is no conflict of interests.

REFERENCES

1. Petrikkos G, Skiada A, Lortholary O, Roilides E, Walsh TJ, Kontoyiannis DP. Epidemiology and clinical manifestations of mucormycosis. *Clin Infect Dis* 2012;**54**(suppl_1):S23-S34.
2. Arora U, Priyadarshi M, Katiyar V, et al. Risk factors for Coronavirus disease-associated mucormycosis. *J Infect* 2022;**84**(3):383-90.
3. John TM, Jacob CN, Kontoyiannis DP. When uncontrolled diabetes mellitus and severe COVID-19 converge: the perfect storm for mucormycosis. *J Fungi* 2021;**7**(4):298.
4. Sarda R, Swain S, Ray A, Wig N. COVID-19-associated mucormycosis: an epidemic within a pandemic. *QJM* 2021;**114**(6):355-6.
5. González-Martín-Moro J, López-Arcas-Calleja JM, Burgueño-García M, Cebrián-Carretero JL, García-Rodríguez J. Rhinoorbitocerebral mucormycosis: a case report and literature review. *Med Oral Patol Oral Cir Bucal* 2008;**13**(12):E792-E5.
6. Bouza E, Muñoz P, Guinea J. Mucormycosis: an emerging disease? *Clin Microbiol Infect* 2006;**12**:7-23.
7. Sani AT, Fata AM, Arian M. Presenting features and outcome of rhino-orbital-cerebral mucormycosis in two referral center in Mashhad. *Tehran University Medical Journal* 2014;**72**(1).
8. Mallis A, Mastronikolis S, Naxakis S, Papadas A. Rhinocerebral mucormycosis: an update. *Eur Rev Med Pharmacol Sci* 2010;**14**(11).
9. Bhansali A, Bhadada S, Sharma A, et al. Presentation and outcome of rhino-orbital-cerebral mucormycosis in patients with diabetes. *Postgrad Med J* 2004;**80**(949):670-4.
10. McDevitt Jr GR, Brantley MJ, Cawthon MA. Rhinocerebral mucormycosis: a case report with magnetic resonance imaging findings. *Clin Imaging* 1989;**13**(4):317-20.
11. Press GA, Weindling SM, Hesselink JR, Ochi JW, Harris JP. Rhinocerebral mucormycosis: MR manifestations. *J Comput Assist Tomogr* 1988;**12**(5):744-9.
12. Jindal G, Sethi A, Bhargarva K, et al. Imaging findings in invasive rhino-orbito-cerebral mucormycosis in

[Downloaded from wjps.ir on 2026-11-25]

[DOI: 10.61882/wjps.14.2.79]

post–COVID-19 patients. Baylor University Medical Center Proceedings; 2022: Taylor & Francis; 2022. p. 32-4.
13. Chamilos G, Lewis RE, Kontoyiannis DP. Delaying amphotericin B–based frontline therapy significantly increases mortality among patients with hematologic malignancy who have zygomycosis. *Clin Infect Dis* 2008;**47**(4):503-9.
14. Pathak L, Tripathi A, Nayyar SS, et al. Management of post-COVID mucormycosis at a tertiary care center in Northern India. *The Egyptian Journal of Otolaryngology* 2023;**39**(1):19.
15. Dam P, Cardoso MH, Mandal S, et al. Surge of mucormycosis during the COVID-19 pandemic. *Travel Med Infect Dis* 2023 2023/03/01/;**52**:102557.
16. A GA, Ashraf H, HaiderMehdi HS. Mucormycosis and Covid-19 : Risk Factors, Clinical Presentation and Outcome in a Tertiary Care Centre in North India. *J Assoc Physicians India* 2022 Apr;**70**(4):11-2.
17. Nehara HR, Puri I, Singhal V, Sunil I, Bishnoi BR, Sirohi P. Rhinocerebral mucormycosis in COVID-19 patient with diabetes a deadly trio: Case series from the north-western part of India. *Indian J Med Microbiol* 2021;**39**(3):380-3.
18. Sterne JA, Murthy S, Diaz JV, et al. Association between administration of systemic corticosteroids and mortality among critically ill patients with COVID-19: a meta-analysis. *JAMA* 2020;**324**(13):1330-41.
19. Ahmed N, Mahmood MS, Ullah MA, et al. COVID-19-associated candidiasis: possible patho-mechanism, predisposing factors, and prevention strategies. *Curr Microbiol* 2022;**79**(5):127.
20. Chakravarty J, Gupta MK, Tilak R, et al. COVID-19-associated Mucormycosis: A clinico-epidemiological study. *J Diabetes Complications* 2022;**36**(9):108284.
21. Dogra S, Arora A, Aggarwal A, et al. Mucormycosis Amid COVID-19 Crisis: Pathogenesis, Diagnosis, and Novel Treatment Strategies to Combat the Spread. *Front Microbiol* 2021;**12**:794176.
22. Pal P, Singh B, Singla S, Kaur R. Mucormycosis in COVID-19 pandemic and its neurovascular spread. *Eur Arch Otorhinolaryngol* 2021:1-8.
23. Kemper J, Kuijper E, Mirck P, Balm A. Recovery from rhinocerebral mucormycosis in a ketoacidotic diabetic patient: a case report. *J Laryngol Otol* 1993;**107**(3):233-5.
24. Hussain S, Salahuddin N, Ahmad I, Salahuddin I, Jooma R. Rhinocerebral invasive mycosis: occurence in immunocompetent individuals. *Eur J Radiol* 1995;**20**(2):151-5.

[Downloaded from wjps.ir on 2026-11-25]

[DOI: 10.61882/wjps.14.2.79]