

Ameloblastic Fibro-Odontoma in a 16-Month-Old Male: A Case Report and Literature Review

Touraj Vaezi¹, Ali Mirzaei², Alireza Ebrahimpour^{1,2*}

1. Department of Oral and Maxillofacial surgery, Faculty of Dentistry, Mashhad University of Medical Sciences, Mashhad, Iran

2. Student Research Committee, Faculty of Dentistry, Mashhad University of Medical Sciences, Mashhad, Iran

*Corresponding Author:

Alireza Ebrahimpour

Department of Oral and Maxillofacial Surgery, Faculty of Dentistry, Mashhad University of Medical Sciences, Mashhad, Iran

AND

Student Research Committee, Faculty of Dentistry, Mashhad University of Medical Sciences, Mashhad, Iran

Email:

alireza.ebrahimpour.1996@gmail.com

Received: ***

Accepted: ***

ABSTRACT

Ameloblastic fibro-odontoma (AFO) is a rare benign mixed odontogenic tumor characterized by both soft tissue proliferation and dental hard tissue formation. This case report presents a 16-month-old male with AFO in the anterior mandible, representing one of the youngest documented cases. The patient presented with progressive facial swelling first noted at 10 months of age. Clinical examination revealed facial asymmetry with non-tender buccal expansion, while CT imaging demonstrated a well-defined 23×28mm lytic lesion with internal calcifications in the right parasymphysal region. Treatment consisted of conservative surgical enucleation and curettage under general anesthesia, with extraction of involved teeth. Histopathological analysis confirmed the diagnosis of AFO, showing islands of ameloblastic epithelium within mesenchymal stroma and evidence of dentin and cementum formation. A literature review of AFO cases in children under 5 years (2014-2024) yielded eight cases with equal gender distribution and no clear predilection for maxilla versus mandible. All reported cases showed lesional expansion, and most were treated with enucleation and curettage with no recurrence noted during follow-up periods. The patient recovered uneventfully with resolution of facial asymmetry and showed no signs of recurrence at six-month follow-up. This case highlights that AFO could manifest at an exceptionally young age, expanding the recognized age range and underscoring the effectiveness of conservative surgical management for this rare odontogenic tumor.

KEYWORDS

Ameloblastic fibro-odontoma; Children; Surgery; Tumor; Odontogenic

Please cite this paper as:

Vaezi T, Mirzaei A, Ebrahimpour A. Ameloblastic Fibro-Odontoma in a 16-Month-Old Male: A Case Report and Literature Review. *World J Plast Surg.* 2025;14(3):1-6.

doi: 10.61186/wjps.14.3.**

INTRODUCTION

Ameloblastic fibro-odontoma (AFO) is a benign mixed odontogenic tumor that exhibits the proliferative characteristics of ameloblastic fibroma alongside dental hard tissue formation resembling complex odontoma¹. Despite its slow-growing nature, AFO can cause notable jaw expansion due to its inductive capacity, producing both soft and mineralized components².

The epidemiological profile indicates predominant occurrence in pediatric and adolescent populations, typically appearing within the

first two decades of life³. Although its precise maxilla-mandible distribution varies in the literature, many reports note a tendency for AFO to occur in the posterior segments of the mandible^{4,5}. Clinically, AFO often presents as a painless swelling or asymmetry of the jaw, frequently discovered incidentally on radiographic examinations⁴.

Radiographic examination reveals well-circumscribed lesions with distinct sclerotic margins, exhibiting either unilocular or multilocular architecture⁶. The internal structure demonstrates heterogeneous radiodensity, comprising variable proportions of radiopaque and radiolucent components. The lesion frequently demonstrates association with unerupted dentition or presents in regions of dental agenesis, introducing additional diagnostic complexity⁷.

Histopathological analysis demonstrates a fibroblastic mesenchymal component analogous to ameloblastic fibroma, with concurrent presence of odontogenic epithelium and mesenchyme forming enamel organs and dental papilla. The lesion exhibits atypical enamel matrix and dentin production patterns resembling compound or complex odontomas. Microscopic examination confirms lesional circumscription through encapsulation or distinct connective tissue delineation from adjacent osseous structures⁸.

The therapeutic protocol consists of conservative surgical enucleation, facilitated by the lesion's encapsulation and well-defined margins. Post-surgical recurrence potential necessitates implementation of systematic long-term monitoring protocols to ensure therapeutic efficacy⁸.

We present a case of extensive AFO in a very young patient—only 16 months old—and discuss surgical

management and outcomes. Additionally, we provide a concise review of the literature regarding AFO in children under 5 years of age.

CASE PRESENTATION

A 16-month-old male was referred to the Department of Oral and Maxillofacial Surgery at Mashhad University of Medical Sciences, Mashhad, Iran, in early 2024 with a progressive swelling in the anterior region of the mandible. According to the parents, the swelling was first noticed around the child's 10 months of age. The child had no systemic illnesses or significant hospital admission history, and there were no reports of trauma or infection.

External examination revealed facial asymmetry without cutaneous involvement (Figure 1a). Intraoral assessment demonstrated a non-tender buccal expansion extending from the midline to the region of the right primary second molar (tooth E). The overlying mucosa maintained normal color and integrity, with no evidence of ulceration (Figure 1b). A computed tomography (CT) scan of the mandible demonstrated a well-defined, lytic lesion in the right parasymphyseal region, measuring approximately 23 × 28 mm. Cortical thinning with buccal expansion and internal calcified foci suggesting nascent dental structures were noted (Figure 2a & 2b). The radiographic differential diagnoses included mixed odontogenic lesions such as dentigerous cysts, ameloblastic fibroma, or related pathologies.

Considering the lesion's well-defined borders and expansile nature, the treatment plan consisted of enucleation and curettage, combined with extraction of any involved teeth^{2,3}. Under general

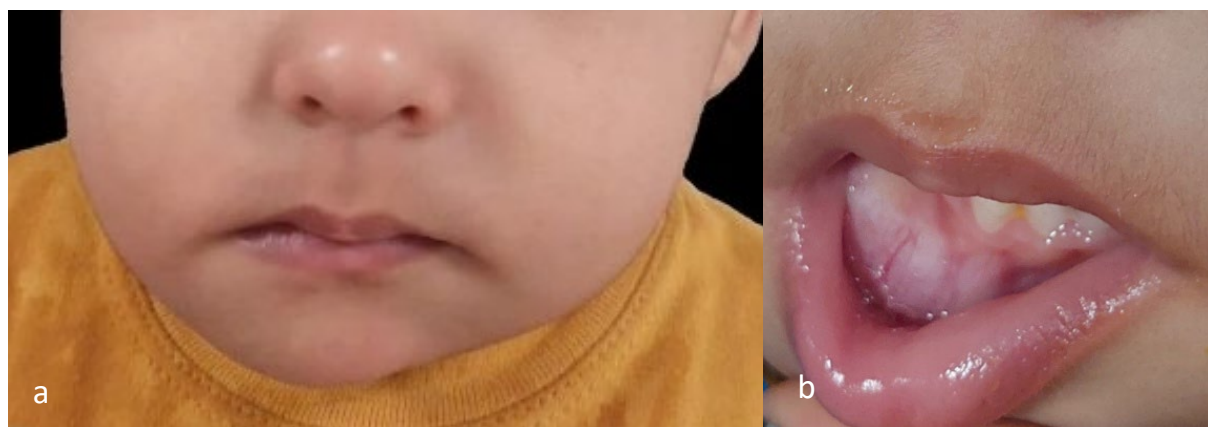


Figure 1: (a) Extraoral view of the patient; (b) Intraoral view of the patient

anesthesia and sterile conditions, the patient was orally intubated. After preparation and draping, local anesthesia was administered via infiltration in the buccal and lingual vestibule using 2% lidocaine with 1:100,000 epinephrine for hemostasis and pain management.

A crestal and sulcular incision was made from the midline to the approximate area of the permanent first molar, and a flap was reflected. The entire lesion was then enucleated using a curette, followed by curettage. The teeth involved were also extracted. Hemostasis was achieved, and the surgical site was sutured using 4-0 polyglycolic acid (PGA) absorbable sutures (Supa®, Tehran, Iran). The specimen was submitted for histopathological evaluation.

Gross examination revealed two tissue specimens: a primary cream-colored mass measuring 3 x 2 x 2 cm

with variable consistency, and a smaller specimen containing dental tissue with surrounding soft tissue. Microscopic evaluation demonstrated islands and cords of attenuated ameloblastic epithelium, characterized by a two-cell thickness, embedded within immature mesenchymal stroma (Figures 3a & 3b). The specimen exhibited evidence of dentin and cementum formation with identifiable stellate reticulum, confirming the diagnosis of ameloblastic fibro-odontoma.

Postoperatively, the patient recovered uneventfully. At six months' follow-up, no signs of recurrence or complications were noted. Facial asymmetry had resolved, and the child displayed normal feeding and speech development. Written informed consent was obtained from the patient's legal guardian for publication of this case and accompanying images.

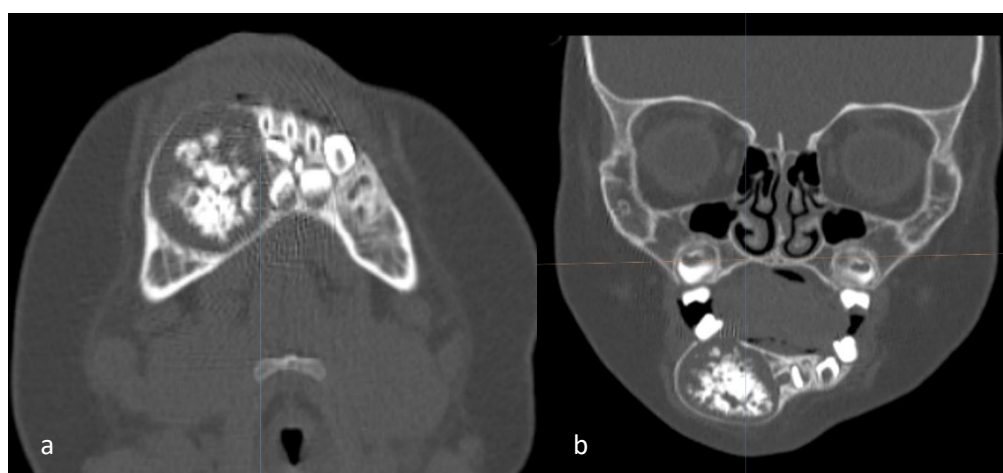


Figure 2: (a) Axial view of the lesion in CT; and (b) Coronal view of the lesion in CT

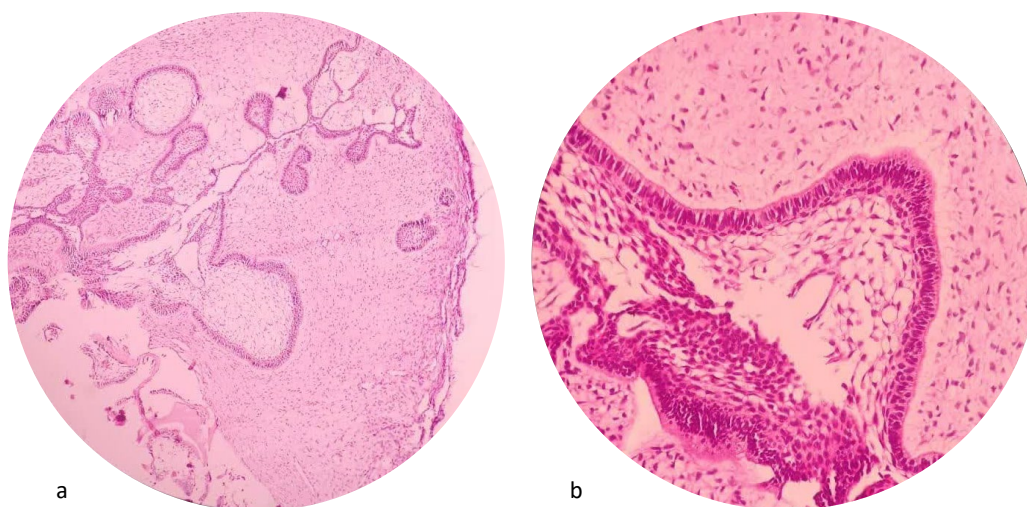


Figure 3: (a) Specimen image at 10× magnification; (b) Specimen image at 40× magnification

Table 1: Reported cases of ameloblastic fibro-odontoma in children under five

Reference	Year	Country	Gender	Age (Years)	Jaw	Location	Locularity	Cortical Bone	Treatment	Follow-up	Recurrence
[9]	2017	Iran	Female	0.58 (7 mo)	Lower	Anterior	Unilocular	Expansion	Enucleation + Curettage	1 year	No
[3]	2021	Brazil	Male	3	Lower	Posterior	Unilocular	Expansion	Enucleation + Extraction	3 years	No
[12]	2022	Iran	Male	4	Upper	Posterior	NR	Expansion	Enucleation + Curettage	NR	NR
[11]	2014	Switzerland	Female	3	Upper	Posterior	NR	Expansion	Resection	6 months	No
[13]	2016	Iran	Male	4	Upper	Anterior	Unilocular	Expansion	Enucleation + Curettage	1 year	No
[14]	2020	India	Male	3	Lower	Anterior	Unilocular	Expansion	Enucleation + Curettage	NR	NR
[10]	2014	Taiwan	Female	3	Upper	Anterior	NR	NR	NR	1 year	No
[15]	2018	Iran	Female	2.41 (29 mo)	Lower	Anterior	Unilocular	Expansion	Enucleation + Curettage	2 years	No

NR = Not reported

DISCUSSION

Because of the rarity of ameloblastic fibro-odontoma in children under 5 years, a literature review was undertaken to further characterize clinical presentation and treatment outcomes in this age group. Searches were conducted in PubMed, Scopus, ScienceDirect, and Web of Science for English-language case reports of histologically confirmed AFO in patients under five, published from 2014 to 2024. After screening titles, abstracts, and references, eight relevant case reports met the inclusion criteria, and key data were extracted on demographics, lesion location, radiographic features, treatment modalities, and recurrence.

Table 1 summarizes the eight pediatric AFO cases identified in the review. Out of eight reported cases, four cases were in males and four cases were in females. Aldelaimi et al.⁴ reported an equal distribution between males and females, which is in line with our findings. Although most cases have been reported in children aged three to four years, our case and that of Mashhadiabba et al.⁹ demonstrate that AFO can manifest earlier, suggesting that early odontogenic dysregulation might occasionally lead to such lesions. Furthermore, the anatomical distribution in the reviewed cases is split almost equally between the maxilla and mandible, with some studies noting a slight

predominance in the anterior regions³. Clinically, AFO tends to present as painless, slowly enlarging swelling that often results in facial asymmetry. In our case, the patient exhibited a buccal expansion in the anterior mandible that was both non-tender and progressive, a finding that parallels previous reports. Radiographically, AFO is characterized by well-circumscribed radiolucent lesions that contain mixed radiopaque foci, corresponding to calcified dental tissues. Such features, as observed in our computed tomography scans, not only aid in differentiating AFO from other odontogenic cysts or tumors (such as dentigerous cysts) but also help in planning the surgical approach^{5,6}.

Histopathologic examination of the lesion reveals a distinctive combination of features characteristic of both ameloblastic fibroma and odontoma. The histomorphological analysis demonstrates islands and cords of attenuated ameloblastic epithelium within an immature mesenchymal stroma, accompanied by evidence of enamel matrix, dentin, and cementum formation, establishing the diagnosis of AFO⁸. This mixed odontogenic pattern serves as a crucial determinant for both diagnostic accuracy and surgical planning. The primary diagnostic consideration involves differentiation from entities with similar histopathologic features, particularly ameloblastic fibroma and complex odontoma, necessitating thorough evaluation for definitive

diagnosis. In five cases, the lesion was described as unilocular, with no description provided in three cases. All cases were associated with expansion, except for one where expansion was not reported¹⁰. In 6 cases, the treatment involved enucleation and curettage of the lesion, whereas one study reported resection of the jaw¹¹. One study did not specify the treatment¹⁰. Follow-up durations ranged from 6 months to 3 years, with no recurrence reported in any of the cases. Given the encapsulated nature and well-defined borders of AFO, conservative surgical management in the form of enucleation and curettage is generally considered the treatment of choice. Our approach, which also included the extraction of involved teeth, is supported by multiple studies, including the work by Goel et al.⁸, who reported no recurrence with similar treatment protocols. While there are instances in the literature where more aggressive management, such as resection, has been undertaken¹¹, the absence of recurrence in our patient over a six-month follow-up period further endorses conservative management. This outcome also mirrors the favorable prognoses observed in other case reports^{3,10}.

Given that the tumor can disturb normal odontogenesis, follow-up remains important to monitor post-surgical jaw development and potential eruption disturbances. This case highlights the possibility of AFO arising at an exceptionally young age, expanding the recognized age range and underscoring the need for early detection and intervention.

CONCLUSION

AFO could be observed in individuals under 5 years of age. The lesions are characterized by expansion and do not exhibit specific patterns in terms of jaw distribution or gender. Given the absence of recurrence reports, the recommended treatment is conservative surgical management—specifically enucleation and curettage, often accompanied by extraction of any involved teeth. This case, involving a 16-month-old patient, contributes to the limited body of literature on early-onset AFO and reinforces the efficacy of such conservative management. It also underscores the importance of thorough clinical, radiographic, and histopathological evaluations in achieving an accurate diagnosis and guiding optimal treatment planning for pediatric patients presenting with odontogenic tumors.

ETHICAL CONSIDERATIONS

Written informed consent was obtained from the patient's legal guardian prior to inclusion in the study and for publication of any accompanying images. Patient anonymity has been safeguarded by omitting identifying details and ensuring that photographs do not reveal recognizable features.

CONFLICT OF INTEREST

The authors declare that they have no relevant financial or non-financial interests and no conflicts of interest to disclose.

REFERENCES

1. Liu S, Li H, Dong Y, Zhang D. Ameloblastic fibrosarcoma of the maxilla arising in an old woman, a rare case report and literature review. *BMC Oral Health* 2024;24(1):743.
2. Omar N, Ullah A, Ghleilib I, Patel N, Abdelsayed RA. A Locally Aggressive Ameloblastic Fibro-Odontoma: A Case Report and Literature Review. *Cureus* 2021 Dec;13(12):e20366.
3. Ferreira GZ, Danieleto-Zanna CF, Iwaki Filho L, Lustosa RM, Jacomacci WP, Gonçalves ES. Ameloblastic fibro-odontoma in a child patient: case report and literature review: case report and literature review. *Research, Society and Development* 2021;10(2):1-2.
4. Aldelaimi TN, Khalil AA, Abdulkaream SM. Ameloblastic Fibro-Odontoma of the Mandible. *Arab Board Med J* 2024;25(3):170-3.
5. Kurimoto T, Yamanishi T, Harada T, et al. Differential diagnosis of ameloblastic fibro-odontoma: case report and literature review. *Journal of Oral and Maxillofacial Surgery, Medicine, and Pathology* 2019/01/01;31(1):38-42.
6. Mahdavi N, Kardooni Khoozestani N, Hasheminasab M, Soltani N. Hybrid Odontogenic Tumor of Calcifying Odontogenic Cyst and Ameloblastic Fibroma: a Case Report and Review of Literature. *J Dent (Shiraz)* 2020 Jun;21(2):153-7.
7. Sánchez-Romero C, Paes de Almeida O, Bologna-Molina R. Mixed odontogenic tumors: A review of the clinicopathological and molecular features and changes in the WHO classification. *World J Clin Oncol* 2021 Dec 24;12(12):1227-43.
8. Goel M, Qamar A, Daftary M, Chhabile S, Pundkar S. Ameloblastic Fibro-Odontoma of the Posterior Mandible: A Rare Pathological Entity. *Cureus* 2023 Sep;15(9):e46264.

9. Mashhadiabba F, Shamloo N, Jafari M, Vafadar S. Ameloblastic Fibro-Odontoma in a 7-Month-Old Infant: A Case Report. *J Dent (Shiraz)* 2017 Sep;**18**(3):234-6.
10. Lin YC, Hsu HM, Liu CS, Yuan K. A peripheral ameloblastic fibro-odontoma in a 3-year-old girl: case report, immunohistochemical analysis, and literature review. *Case Rep Dent* 2014;**2014**:321671.
11. Ülgür II, Caduff R, Erb J, van Waes H, Jacobsen C, Bredell MG. Ameloblastic fibro-odontoma located in the maxilla of a 3-year-old girl. *Pediatric Dental Journal* 2014/08/01;**24**(2):106-10.
12. Zahra Jahanshahiafshar, Mina Yazdizadeh, Ramin Forooghi, Maryam Johari. An Ameloblastic fibro-odontoma in the posterior maxilla. *Journal of Dentomaxillofacil Radiology, Pathology and Surgery* 2022; **11**(1): 19-23. magiran.com/p2432083
13. Ghandehari-Motlagh M, Khosravi Z, Meighani G, Baradaran-Nakhjavani Y. Ameloblastic Fibro-Odontoma in a 4-Year-Old Boy. *Iran J Pediatr* 2016;**26**(2):e3124. doi:10.5812/ijp.3124
14. Ponniah I, Gopalakrishnan S, Selvam SP, Sharief RM. Ameloblastic fibro-odontoma with ameloblastin immunohistochemistry. *Austin J Dent* 2020;**7**(4):1148.
15. Mirmohamad Sadeghi H, Fayazi Boroujeni M, Poorian B. A report of ameloblastic fibro-odontoma in the 29-month-old girl: a case report. *J Craniomax Res* 2018;**5**(3):131-135.