Sort Communication

Anti-skid Genioplasty Osteotomy by Pre-scoring with a Fissure Bur (Technical Note)

Ali Moradi[1], Ali Mirzaei[2], Ricardo Grillo[3], Sina Samieirad[4], Sahand Samieirad[1*]

[1] Department of Oral and Maxillofacial Surgery, Faculty of Dentistry, Mashhad University of Medical Sciences, Mashhad, Iran

[2] Student Research Committee, Faculty of Dentistry, Mashhad University of Medical Sciences, Mashhad, Iran

[3] Department of Surgery, Prosthesis and Maxillofacial Traumatology, School of Dentistry (FOUSP), University of São Paulo, São Paulo, Brazil

[4] Otolaryngology–Head & Neck Surgery, Private Practice, Mashhad, Iran

***Corresponding Author:**

Sahand Samieirad

Department of Oral and Maxillofacial Surgery, Faculty of Dentistry, Mashhad University of Medical Sciences, Mashhad, Iran

Email: SamieeRadS@mums.ac.ir

Received: 26-08-2025
Accepted: 21-03-2026

ABSTRACT

BACKGROUND: Starting a genioplasty osteotomy on the curved anterior mandible can cause the saw to skid. This poses a risk of deviating from the planned trajectory and potentially injuring the mental nerve. We propose a simple modification: pre-scoring the osteotomy line with a fissure bur to create shallow cortical tracks. These tracks act as a mechanical guide for the micro-saw.

METHODS: After bilateral exposure of the parasymphysis with visualization of the mental nerve, the planned osteotomy was marked beneath the foramina. A fissure bur was then used with copious irrigation to gently score the marked line, creating linear cortical tracks. A reciprocating or oscillating micro-saw was then introduced and advanced within these tracks to complete the osteotomy.

RESULTS: In a representative adult case, the saw engaged the bur-scored grooves without skidding, allowing the osteotomy to follow the planned path. The segment was mobilized and plated as intended. The pre-scoring step added approximately 2 minutes to the procedure and required no additional instruments. Transient lower-lip/chin hypoesthesia resolved by 8 weeks, and no re-operations were necessary.

CONCLUSION: Pre-scoring provides a low-cost, easily adopted anti-skid step that improves initial directional control of the saw during genioplasty. This modification uses routine instruments and may enhance accuracy and safety near the mental nerve. However, meticulous retraction and irrigation remain essential.

KEYWORDS
Genioplasty; Mandible; Osteotomy; Mental Nerve; Surgical Instruments; Oral Surgery

Please cite this paper as:
Moradi A, Mirzaei A, Grillo R, Samieirad S, Samieirad S. Anti-skid Genioplasty Osteotomy by Pre-scoring with a Fissure Bur (Technical Note). World J Plast Surg. 2026;15(1):94-97.
doi: 10.61882/wjps.15.1.94

INTRODUCTION

Precise control of osteotomy is crucial in genioplasty for achieving optimal skeletal and soft-tissue results. However, starting a cut on the curved front of the mandible, especially with soft-tissue retraction, can cause the saw to slip. This slipping, or “skidding,” can lead to the saw deviating from the planned path and potentially injuring the mental nerve [1].

[Downloaded from wjps.ir on 2026-11-24]

[DOI: 10.66224/wjps.15.1.94]

While ultrasonic devices like piezosurgery offer benefits such as reduced nerve and soft-tissue damage [2], they come with higher costs, require special equipment, and can extend the surgical time [3]. To improve directional control without adding complexity, we propose a simple change to the procedure: pre-scoring the osteotomy line with a high-speed fissure bur. This creates shallow grooves in the outer layer of the bone, which then guide the saw blade as it begins the cut. This mechanical stabilization helps prevent the saw from slipping, an approach inspired by similar anti-skid techniques used in other dental and craniofacial procedures [4]. This technical note explains the step-by-step method, the required instruments, and the reasoning behind this modified approach.

METHODS

A vestibular intraoral incision is made and a mucoperiosteal flap is elevated to expose the parasymphysis with bilateral visualization of the mental nerve. The intended osteotomy path is marked on each side beneath the mental nerve. Using copious irrigation, a fissure bur is used to score the marked line to a shallow depth sufficient to generate a linear track in cortical bone while avoiding thermal injury. A reciprocating or oscillating micro-saw is then introduced into these tracks and advanced along the pre-scored path to connect both sides and complete the genioplasty cut. The chin segment is mobilized in the usual fashion, positioned as planned, and fixed with plates and screws per surgeon preference.

The modification uses the standard genioplasty set with retractors, elevators, suction, and irrigation, a fissure bur on a surgical handpiece to create the tracks, and a micro-saw to connect the scored lines. Routine fixation hardware is used for definitive stabilization.

In an adult patient undergoing genioplasty, bur-scored grooves were created beneath the mental nerve and a micro-saw was advanced within these tracks to complete the cut without skidding. The segment was then mobilized and plated in the planned position. Intraoperative photographs demonstrate the scored track and the completed osteotomy.

The approach improves directional control at the start of the cut, reduces the risk of saw slippage, and requires no additional devices beyond a bur and saw. Because work is performed close to the mental nerve, careful retraction and irrigation are mandatory. The modification does not address manipulation of the mobile segment, which still relies on conventional grasping and plate application.

The sequence of pre-scoring and saw advancement is illustrated in Figure 1.

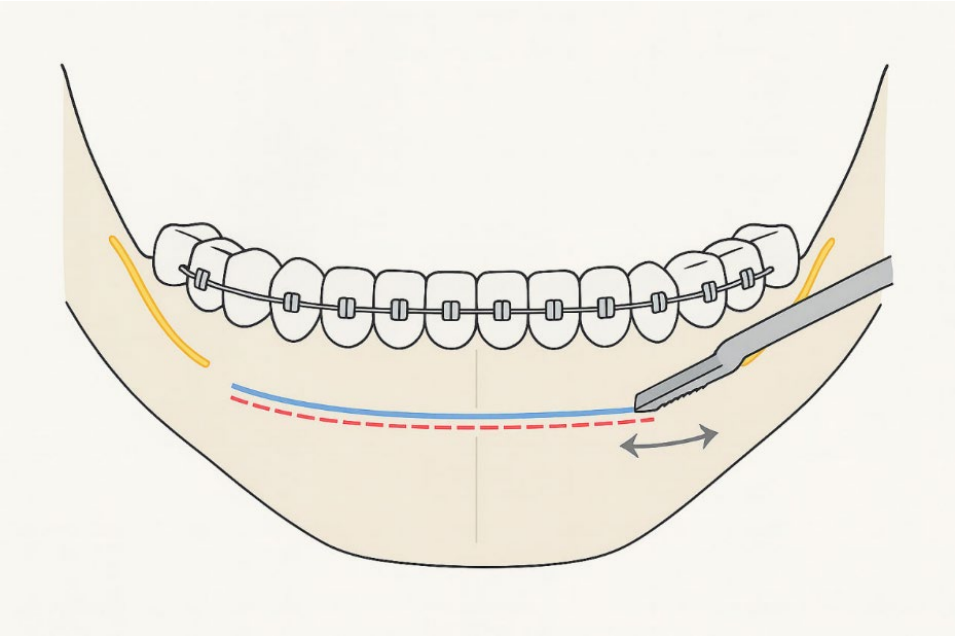

Figure 1: Schematic of the pre-scoring technique. The intended osteotomy line (red) is lightly scored with a fissure bur to create shallow cortical tracks (blue) beneath the mental nerves (yellow), guiding the micro-saw and reducing skidding

[Downloaded from wjps.ir on 2026-11-24]

[DOI: 10.66224/wjps.15.1.94]

RESULTS

An adult 22-year-old male undergoing genioplasty for advancement was treated with the pre-scoring modification. Shallow bur-scored cortical tracks were created bilaterally beneath the mental foramina; the micro-saw engaged the tracks at first contact and advanced along the planned path without visible skidding or deviation from the marked line. No additional guiding maneuvers were required. The mental nerves were visualized and remained intact at closure. The pre-scoring step added approximately 2 minutes to the osteotomy phase and required no extra instruments. The chin segment was mobilized and plated as planned. Postoperatively, the patient had mild lower lip/chin hypoesthesia that resolved by 8 weeks; there were no early wound problems or re-operations.

DISCUSSION

Starting a genioplasty osteotomy on the curved front of the mandible carries a risk of the saw slipping, especially with soft-tissue retraction near the mental nerve. This can affect surgical accuracy and endanger the nerves and blood vessels in the area. The pre-scoring method we describe offers a simple, low-cost way to mechanically stabilize the micro-saw during the beginning of the cut.

Our technique relies on shallow cortical grooves created with a fissure bur; an approach inspired by standard anti-wander practices in bone surgery. These tracks "capture" the saw blade during the early passes, improving directional control and reducing the likelihood of lateral drift. In the illustrative case, the saw remained aligned with the marked osteotomy path without requiring additional manipulation or instruments.

The literature continues to look for ways to improve precision and reduce nerve injury during mandibular osteotomies. For instance, Qadir et al. [5] found that even brief contact between piezoelectric devices and the mental nerve can cause microscopic damage to the nerve fibers, emphasizing the need for a careful technique regardless of the tool used.

While piezosurgery has shown improved safety because of its selective cutting and reduced soft-tissue damage [6], it requires specialized equipment, is more expensive, and often leads to longer surgeries [7]. Furthermore, Zandi et al. [8] found no statistically significant difference in inferior alveolar nerve damage when comparing piezosurgery to traditional rotary tools, suggesting that even advanced tools require careful handling near neural structures.

In contrast, our bur-scoring modification provides a mechanical safety feature using instruments that are already part of most genioplasty kits. This adds minimal time to the procedure and doesn't require any special jigs or custom guides. Although 3D-printed cutting guides have been developed to improve precision, they rely on digital processes, equipment access, and pre-operative imaging, which might not be widely available [9].

It is important to remember that this modification still requires careful tissue retraction and thorough irrigation to prevent thermal or mechanical nerve injury from the bur. The technique does not change how the bone segment is moved or secured, which still depends on the surgeon's skill and standard surgical principles.

Future studies with larger groups of patients could help to quantify how pre-scoring affects osteotomy accuracy, complication rates, and long-term sensory outcomes. However, this initial case suggests that a simple groove in the bone can significantly improve safety and control during a critical phase of genioplasty.

CONCLUSION

Pre-scoring the genioplasty osteotomy line with a fissure bur is an easily adopted, equipment-neutral anti-skid maneuver that can improve initial directional control and may enhance safety. Prospective evaluation could quantify effects on accuracy and sensory outcomes.

ACKNOWLEDGMENTS

The authors gratefully acknowledge the use of AI-based tool (ChatGPT, version GPT-4/Gemini 2.5) to assist with improving the clarity of the manuscript text, and OpenAI's DALL·E to generate some of the schematic assets used in the illustrative figure. All outputs were reviewed, verified, and edited by the authors for accuracy and appropriateness.

CONFLICT OF INTEREST

None declared.

[Downloaded from wjps.ir on 2026-11-24]

[DOI: 10.66224/wjps.15.1.94]

FUNDING

No external funding was received for this work.

REFERENCES

1. Wang C, Gui L, Liu J. A Practical Surgical Technique to Expose the Mental Nerve in Narrowing Genioplasty. *Plast Reconstr Surg Glob Open* 2015;**3**(11):e554.
2. Bertossi D, Albanese M, Mortellaro C, et al. Osteotomy in Genioplasty by Piezosurgery. *J Craniofac Surg* 2018;**29**(8):2156-9.
3. Akbar Z, Saleem H, Ahmed W. Critical analysis of piezoelectric surgery with oscillating saw in bimaxillary orthognathic surgery. *J Coll Physicians Surg Pak* 2017;**27**(6):348-51.
4. Anesi A, Negrello S, Checchi M, et al. Piezosurgery versus Reciprocating Saw: Qualitative Comparison of the Morphology of Cutting Surfaces in Ex Vivo Human Bone. *App Sci* 2024;**14**(5):2203.
5. Qadir SH, Kheder KA, Hassan SMA. Histological assessment of potential inferior alveolar nerve injury following osteotomy of the mandibular buccal cortex using a piezoelectric saw: Histological assessment of potential IAN injury. *Cell Mol Biol (Noisy-le-grand)* 2024 10/08;**70**(9):44-9.
6. Cascino F, Aboh IV, Giovannoni ME, et al. Orthognathic surgery: A randomized study comparing Piezosurgery and Saw techniques. *Ann Ital Chir* 2021;**92**(3):299-304.
7. Isufi R. P-66159072-366 - Piezosurgery positive outcomes in orthognatic surgery. *International Journal of Oral and Maxillofacial Surgery* 2023 2023/02/01/;**52**:4.
8. Zandi M, Heidari A, Jamshidi S, et al. Histological evaluation of inferior alveolar nerve injury after osteotomy of mandibular buccal cortex using piezoelectric versus conventional rotary devices: a split-mouth randomised study in rabbits. *Br J Oral Maxillofac Surg* 2021;**59**(5):561-6.
9. Oth O, Orellana MF, Glineur R. The Minimally Invasive-Guided Genioplasty Technique using Piezosurgery and 3D printed surgical guide: An innovative technique. *Ann Maxillofac Surg* 2020;**10**(1).

[Downloaded from wjps.ir on 2026-11-24]

[DOI: 10.66224/wjps.15.1.94]