

Brow Ptosis after Upper Blepharoplasty: Findings in 70 Patients

Seyed Esmail Hassanpour*, Houman Khajouei Kermani

Department of Plastic and Reconstructive Surgery, Shahid Beheshti University of Medical Sciences, Tehran, Iran

ABSTRACT

BACKGROUND

Brow ptosis is a potential complication after upper eyelid blepharoplasty. The aim of this study was to analyze the effect of upper blepharoplasty on eyebrow position.

METHODS

In this Between April 2011 and March 2013, eighty three patients (166 eyes with mean age of 49.7 years) underwent upper eyelid blepharoplasty. The patients were assessed using pre- and post-operatively digital photographs, in the primary position of the eye while the distance between the upper lid margin and the brow were measured before surgery. The postoperative degree of brow ptosis was evaluated as being mild (<2 mm), moderate (2-4 mm), and marked (>4 mm).

RESULTS

The postoperative brow position was unchanged in 46 cases (65.8%), and brow depression was noted in 24 cases (34.2%), including 7 males (58.3%) , and 17 females (29.3%).

CONCLUSION

Our study shows that postoperative brow position should be explained to patients before surgery, particularly in male and senile patients as concomitant brow lift or internal brow fixation through the blepharoplasty incision can help to stabilize the eyebrow in the proper position and to prevent this complication.

KEYWORDS

Upper blepharoplasty; Brow ptosis; Complication

Please cite this paper as:

Hassanpour SE, Khajouei Kermani H. Brow Ptosis after Upper Blepharoplasty: Findings in 70 Patients. *World J Plast Surg* 2016;5(1):58-61.

INTRODUCTION

The eyes and periorbital area are the focal point during human communication. Changes in the eyelid appearance due to aging may convey an inappropriate message of sadness, tiredness, and absence of vigor, which may reduce the aesthetic appearance of the face.^{1,2} So blepharoplasty is a complex and challenging issue that continues to be the most common invasive cosmetic surgical procedure of the face.³ Upper eyelid blepharoplasty results in improvement of the natural aging changes and improves the appearance.⁴

Postoperative complications of upper eyelid blepharoplasty

***Corresponding Author:**
Seyed Esmail Hassanpour, MD;
Professor and Chairman of Plastic and Reconstructive Surgery,
Karimkhan Aven, South Aban St., 15
Khordad Hospital,
Shahid Beheshti University of Medical Sciences,
Tehran, Iran
Tel: +98 21 88901108
Fax: +98 21 88909193
E-mail: esmail_hassanpour@yahoo.com
Received: April 31, 2015
Revised: September 19, 2015
Accepted: October 10, 2015

range from skin changes to vision-threatening emergencies while some of complications are seen early in the postoperative period including infection, retrobulbar hemorrhage, and eyelid hematoma. Other complications happen later in the postoperative period, such as eyelid malposition, over-and under-resection of skin or orbital fat.⁵⁻⁷ The findings on brow after upper blepharoplasty is still controversial.⁸ Some authors insist that brow position remains unchanged after surgery. On the other hand, there is also an opinion that brow position changes after surgery.^{9,10} The aim of this study was to assess the influence of upper blepharoplasty on brow position and to analyze the effect of major risk factors on eyebrow to move down.

MATERIALS AND METHODS

Between April 2011 and March 2013, eighty three patients (166 eyes) underwent upper eyelid blepharoplasty. Thirteen cases were excluded because of incomplete follow up referrals. Finally, 70 patients (140 eyes) were included in this study. There were 58 women and 12 men and the mean age of patients was 49.7 years (48.9 years in females and 53.7 years in males).

Individuals who had undergone lid surgery had eyebrow, previous eyebrow surgery while those with eyelid ptosis were excluded. Patient age, sex, indications, complications and changes in brow position after upper blepharoplasty were recorded. Photographic documentation was performed by a professional medical photographer in a standardized manner using a Nikon D 300 camera. Preoperatively, surgical landmarks and planned skin excisions were marked on the patients. All operations were performed through a traditional blepharoplasty incision. Immediately after the surgery, an antibiotic ophthalmic ointment was placed over the skin incision. Ice compresses were used for 48 hours, 20 minutes per hour while awake, following the procedure.

Acetaminophen was routinely prescribed, and showering was permitted the day following the procedure. The hospital stay was one day. Patients were then seen 5–7 days after operation to remove the sutures. Patients, were followed for at least 6 months after surgery to monitor surgical results, so these patients underwent no other procedures, either before or during the time span between the photographs that could

affect eyebrow position.

The patients were assessed by means of a comparative analysis using pre- and post-operative digital photographs, in the primary position of the eye. The images were processed using Image J “software”, transferred to a computer, to an electronic Microsoft Excel 2002® worksheet. Distance measurements were used, taking the brow–lid margin distance (BMD), brow–pupil distance (BPD), lid margin– pupil distance (MPD), brow–lateral canthal distance (BLCD), brow–medial canthal distance (BMCD), as anatomical reference points (Figure 1).

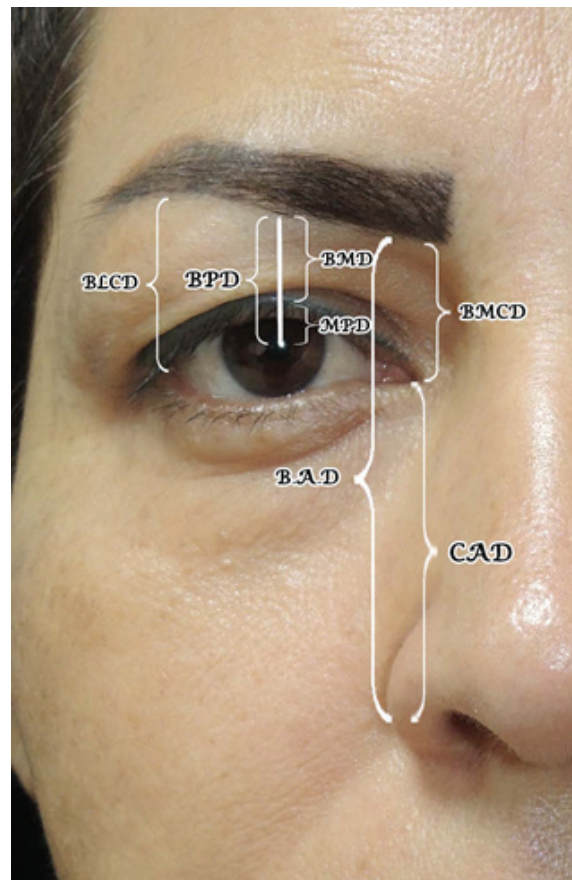


Fig. 1: Photography of right eyelid & eyebrow for measurement of parameters

BLCD= Brow-lateral canthal distance, BMD= Brow-lid margin distance, MPD= Lid margin-pupil distance, BPD= Brow-pupil distance, BMCD= Brow-medial canthal distance, CAD= Canthal-nasal alar distance, BAD= Brow alar distance

The difference between the pre-operative and 6 months post-operative measurements were analyzed statistically using the student's t – test for paired samples and the distance variation was compared with their corresponding contralateral sample using Wilcoxon's non-parametric test. The post-operative degree of brow ptosis was

assessed as being mild (<2 mm), moderate (2–4 mm), and marked (>4 mm).

RESULTS

In all, 140 eyes upper eyelid blepharoplasty operations were performed on 70 patients identified from the departmental database. This group of patients consisted of 58 women and 12 men with an average age of 49.7 years (range: 29-68 years). All patients underwent traditional upper eyelid blepharoplasty. The mean follow up period was 6 month. The most common chief complaint was dermatochalasis in 57 patients and dermatochalasis with visual field impairment in 13 patients. Echymosis and swelling lasting more than two weeks, were the most frequently documented complications, occurring in 12 cases. There were no complications such as wound infection, wound dehiscence or blindness (Table 1).

The postoperative degree of brow ptosis was assessed objectively by means of a comparative analysis using pre- and post-operatively digital photographs, in the primary position of the eye, as being mild (<2 mm), moderate (2-4 mm), and marked (>4 mm) (Table 2).

The measurement obtained after the blepharoplasty, showed significant difference from those before the surgery, indicating that the correction of redundant tissues in eyelid accentuates the tendency of the eyebrow to move down. The changes were more significant in the lateral portion of the eyebrow and they occur bilaterally. This study showed that age

over 55 years, particularly in male patients may influence brow position after blepharoplasty (Table 3).

Table 3: Frequency of brow depression after upper eyelid blepharoplasty

Age (years)	Female	Male
20-29	-	
30-39	-	
40-49	2	1
50-59	13	4
>60	2	2
Total	17 (29.3%)	7 (58.3%)

DISCUSSION

The assessment of distance measurement between the upper lid margin and the brow, obtained pre- and post-operatively, showed that there were secondary changes in the position of the eyebrow as a result of upper eyelid blepharoplasty. Our study also implies to the possibility of a change in postoperative brow position that should be explained to patients before surgery, particularly in male and senile patients.

Excessive skin in the upper eyelid may be wholly or partially attributable to ptosis of the eyebrows.¹¹ In such cases, performing a blepharoplasty alone may inadequately correct the dermatochalasis. More seriously, it may produce further lowering of the eyebrow, that has a compensatory elevated position before blepharoplasty leading to an unacceptable cosmetic result.^{12,13}

Table 1: Demographic features of patients

Variable	Male	Female
Number of patients	12 (17.2%)	58 (82.8%)
Total	70 (140 eyes)	
Age (mean, years, ranges)	53.7 (40-68)	48.9 (29-65)
Overall	49.7 year (29-68)	
Brow depression	7 (58.3%)	17 (29.3%)
Surgical indication	57 (81.4%) 13 (18.6%)	cosmetic cosmetic+visual field defect

Table 2: Comparisons of objective changes of measured parameters in patients with eyebrow position change

Variable	Mild (<2 mm)	Moderate (2-4 mm)	Severe (>4 mm)
Female	11 (64.7%)	4 (23.5%)	2 (11.7%)
Male	4 (57.2%)	2 (28.5%)	1 (14.2%)
Total	15	6	3

Overall: 24 cases (34.2%)

If the patient had chronic brow strain and elevation before surgery due to the dermatochalasis and the extra skin was removed by performing the blepharoplasty, the brow no longer would need to maintain an elevated position and sank down. If brow strain is evident during preoperative evaluation, strong consideration must be given to brow lift and an upper lid blepharoplasty or ptosis repair is to be performed.

Preoperative measurements of upper eyelid heights appear useful in determining the amount of skin excision required in blepharoplasty for senile patients.¹⁴ Therefore, transplapebral techniques should be indicated only with special attention to the age and sex. Concomitant brow lift or internal brow fixation through the blepharoplasty incision can help to stabilize the eyebrow in the proper position and prevention of this complication.^{15,16}

CONFLICT OF INTEREST

The authors declare no conflict of interest.

REFERENCES

- 1 Neligan PC. Plastic Surgery. 3rd Ed. ELSEVIER, USA. 2013;**2**:108-37.
- 2 Lieberman DM, Quatela VC. Upper lid blepharoplasty: a current perspective. *Clin Plast Surg* 2013;**40**:157-65.
- 3 Balik A, Ozdemir-Karatas M, Cifter ED, Peker K, Sancakli E, Gökçen-Röhlrig B. Soft tissue response and survival of extraoral implants: a long term follow up. *J Oral Implantol* 2014 Oct 8. [Epub ahead of print]
- 4 Nahai F. The art of aesthetic surgery: Principles and techniques. 2nd ed., Karen Berger, Italy. 2011;**1**:807-995.
- 5 Prischmann J, Sufyan A, Ting JY, Ruffin C, Perkins SW. Dry eye symptoms and chemosis following blepharoplasty: a 10-year retrospective review of 892 cases in a single-surgeon series. *JAMA Facial Plast Surg* 2013;**15**:39-46.
- 6 Morax S, Touitou TV. Complications of blepharoplasty. *Orbit* 2006;**25**:303-18.
- 7 Paulla SJ, Codner MA. Minor complications after blepharoplasty: dry eyes, chemosis, granuloma, ptosis, and scleral show. *Plast Reconstr Surg* 2010;**125**:709-18.
- 8 Prado RB, Silva-Junior DE, Padovani CR, Schellini SA. Assessment of eyebrow position before and after upper eyelid blepharoplasty. *Orbit* 2012;**31**:222-6.
- 9 Lee JM, Lee TE, Lee H, Park M, Baek S. Change in brow position after upper blepharoplasty or levator advancement. *J Craniofac Surg* 2012;**23**:434-6.
- 10 Frankel AS, Kaminer FM. The effect of blepharoplasty on eyebrow position. *Arch Otolaryngol Head Neck Surg* 1997;**123**:393-6.
- 11 Booth AJ, Murray A, Tyers AG. The direct brow lift: efficacy, complications, and patient satisfaction. *Br J Ophthalmol* 2004;**88**:688-91.
- 12 Cahill KV, Bradley EA, Meyer DR, Custer PL, Holck DE, Marcet MM, Mawn LA. Functional indications for upper eyelid ptosis and blepharoplasty surgery: a report by the American Academy of Ophthalmology. *Ophthalmology* 2011;**118**:2510-7.
- 13 Gladstone HB. Blepharoplasty: indications, outcomes, and patient counseling. *Skin Therapy Lett* 2005;**10**:4-7.
- 14 Maegawa J, Kobayashi S, Yabuki Y, Hirotoimi K, Yasumura K, Iwai T. Blepharoplasty in senile blepharoptosis: preoperative measurements and design for skin excision. *Aesthet Surg J* 2012;**32**:441-6.
- 15 Rogers SA, Khan-Lim D, et al. Does upper lid blepharoplasty improve contrast sensitivity? *Ophthalm Plast Reconstr Surg* 2012;**28**:163-5.
- 16 Cohen BD, Reiffel AJ, Spinelli HM. Browpexy through the upper lid (BUL): a new technique of lifting the brow with a standard blepharoplasty incision. *Aesthet Surg J* 2011;**31**:163-9.