Letter to Editor

Contralateral Pedicled Anterolateral Thigh Flap (ATL) for Upper Thigh Defect in the Era of Free ATL?

Narendra Hulika*, Ramana Reddy Naru, Azhagamuthu, Basheeruddin Inamdar, Abha Chandra

Department of Surgical Oncology, Department of Cardiovascular and Thoracic Surgery, Sri Venkateswara Institute of Medical Sciences, Tirupati, India

***Corresponding Author:**
Narendra Hulikal, MD;
Professor of Department of Surgical oncology,
Sri Venkateswara Institute of Medical Sciences,
Tirupati, 517501, India
E-mail: drnarendrah@yahoo.co.in
Received: August 11, 2015
Revised: December 25, 2015
Accepted: January 25, 2016

DEAR EDITOR

The radical surgery for fungating inguinal lymph nodes is commonly done in patients with penile and vulvar cancers, creating complex groin defects. These defects are managed most commonly with either pedicled ipsilateral anterolateral thigh (ATL) flap or tensor fascia lata (TFL) flap. The reconstruction with complex flaps provide durable coverage and prevent scar contractures, which tend to form in the flexural regions such as the groin. The pedicled ATL flap is one of the most commonly used flaps for ipsilateral groin defects. Its blood supply depends on intact femoral vessels. In a scenario where femoral vessels are resected and reconstructed with synthetic graft as part of radical surgery for cancer, either a free or ipsilateral pedicled anterolateral thigh flap is not an option.[1,2]

We report a case of recurrent synovial sarcoma of thigh with skin and femoral vessel infiltration following prior wide excision and external beam radiotherapy, for which wide excision and femoral vascular reconstruction was done creating a large skin and soft tissue defect in upper thigh and groin area. As options of both ipsilateral pedicled ATL or free ATL could not be exercised, we planned and covered the defect with pedicled anterolateral thigh flap from the opposite thigh. We are reporting this case as the literature describing the use of contralateral pedicled ATL is sparse.

A 34-year-old lady who was treated earlier for soft tissue sarcoma of the right upper thigh area with surgery, radiotherapy and chemotherapy presented 2 years later with local recurrence. On local examination, there was a 7x6 cm hard mass present over the medial aspect of the right upper thigh with fixity to the overlying skin. The femoral artery pulsation could not be felt in the area of the mass. There was no clinically significant inguinal lymphadenopathy. The Preoperative MRI revealed vascular involvement. As the patient desired limb preservation a multidisciplinary discussion was held a decision was made to re resect the tumor with femoral vascular reconstruction.

Hence a radical excision of the tumor, wide area of involved skin along with the involved segment (15 cm) of femoral artery and vein was done, leaving a large defect (15x10 cm). The vascular reconstruction was done by the vascular surgeon with the PTFE graft (17 cm). The large skin defect needed a flap to cover the vascular graft area. Since no microvascular reconstruction was possible due to lack of vessels for anastomosis in the thigh, a pedicled contralateral ATL was planned (Figure 1).

[Downloaded from wjps.ir on 2026-11-24]

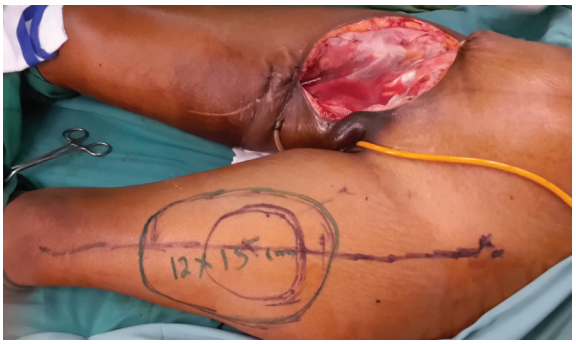

Fig. 1: Thigh defect and flap design

The flap cover was done as a staged procedure after 72 hours of radical surgery. The ATL flap was harvested as musculocutaneous flap based on the contralateral descending branch of lateral circumflex femoral vessels as described earlier by several authors and passed beneath the skin and subcutaneous tissue of the pubic area following an open lay incision and brought to the thigh defect and sutured in place covering the vascular reconstruction (Figure 2, 3, 4 and 5). The donor area was covered with split thickness skin graft. Postoperatively, the wound healed well in the flap area with minor graft loss at the donor area.

The standard technique of flap harvesting was followed, which consisted of flap planning, harvesting and flap in-setting. On the donor thigh, a line corresponding to the intermuscular septum between rectus femoris (RF) and vastus lateralis (VL) was drawn from the anterior superior iliac spine to the lateral aspect of upper patella. A circle of 3 cm radius was drawn around the middle point of this line and perforators were mapped. The medial incision was placed first up to sub fascial level. The RF and VL were separated and the pedicle was identified and safeguarded. The vastus lateralis muscle was taken along with the flap preserving the musculocutaneous perforators and flap was fully mobilized up to the origin of the pedicle from profunda vessels.

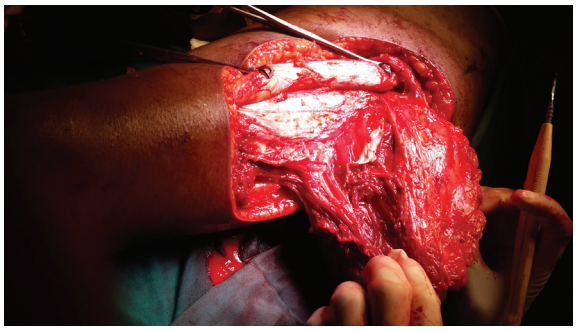

Fig. 2: Flap Harvest



Fig. 3: Flap raising



Fig. 4: Flap placement



Fig. 5: Final appearance after flap insetting

The flap was then passed below the rectus femoris and Sartorius muscles medially. An incision was made in the skin and subcutaneous tissue of supra pubic area and the composite flap was transferred to the defect in contralateral thigh and sutured over the exposed vessels after placing suction drains away from the vascular grafts (Figures 2-5).

Large thigh and groin defects are common following radical surgery for the soft tissue tumors or metastatic deposits of the inguinal nodes from primary arising from penis or vulva. The management of groin defects is often challenging for the reconstructive surgery team. The most common flaps used for these defects are Tensor fascia lata myocutaneous flap, Gracilis myocutaneous flap, Rectus Abdominis flap, RF and Sartorius muscle flaps.[3,4]

[Downloaded from wjps.ir on 2026-11-24]

But the area of coverage offered by these flaps is often limited. In contrast, ATL flap, a relatively new flap described in 1984 by Song *et al.* as a free flap,[5] is based on descending branch of lateral circumflex femoral artery (LCFA) which originates from the profunda femoris artery[6] offers wider area of soft tissue and skin coverage. The use of free ATL has been well established in the reconstruction of oral, maxillofacial and tongue defects as well as defects of the chest, abdominal wall, scalp and face. The pedicled ATL is used for ipsilateral groin, trochanteric, ischial, abdominoperineal and genital defects as proximal based flap and for knee defects as distally based flaps.

One advantage of the ATL flap which is often exploited by the reconstructive surgeons is the large area of coverage it provides. In fact, when large area is to be covered the entire lateral thigh can be used along with the tensor fascia lata and anteromedial thigh flap with minimal morbidity of the donor area.[1] The flap can be harvested as fasciocutaneous or musculocutaneous composite flap depending on the needs of the defect. Since our case involved coverage of the defect along with the vascular grafts we preferred musculocutaneous flap.

The ATL flap is harvested based on the descending branch of the lateral circumflex femoral vessels. These vessels comprise of an artery and 2 veins and run in the intermuscular septum between the RF and VL muscles for varying distance before entering in to the VL muscle.[1] In one of the large series of pedicled ATL flaps, Kimata *et al.* reported their experience with 74 flaps primarily for reconstructing groin and abdominal wall defects.[7] In general, the average pedicle length reported is about 12 cm, which can be extended up to 20 cm.[8] The pedicle length can be increased by dissecting up to the origin from the profunda vessels and basing the flap on distal perforators or from proximal eccentric placement of the selected perforator,[9,10] In a series of 17 pedicled ATL flaps, Quazi *et al.*[4] described tunneling of the flap between the rectus and the fascial septa for ipsilateral inguinal defects.

Our case is different in the sense that there were limited options to cover the defect as the ipsilateral femoral vessels and their branches were sacrificed with the tumor and a vascular graft were used to reconstruct the vessels. Hence there were no recipient vessels to offer a microvascular reconstruction. Similarly, other loco-regional flaps such as transverse rectus abdominis or ipsilateral ATL could not be used. We used ATL flap pedicled from contralateral thigh by extending the pedicle to the origin of descending branch of lateral circumflex femoral artery and placing the flap in subcutaneous plane after rotating to opposite thigh, showing that it is safe and reliable in reaching opposite groin without any vascular compromise.

We buried the pedicle in a lay open incision at the suprapubic area. Postoperatively the wound healed well with prolonged drainage for up to 3 weeks and with minor donor area morbidity. Pedicled ATL flap can be used for reconstruction of contralateral groin defects safely and reliably without any vascular compromise particularly when the ipsilateral ATL flap is not feasible.

CONFLICT OF INTEREST

The authors declare no conflict of interest.

KEYWORDS
Pedicled anterolateral thigh flap; Groin defect; Soft tissue sarcoma

Please cite this paper as:
Hulika N, Reddy Naru R, Azhagamuthu, Inamdar B, Chandra A. Contralateral Pedicled Anterolateral Thigh Flap (ATL) for Upper Thigh Defect in the Era of Free ATL?. World J Plast Surg 2015;5(2):194-197.

REFERENCES

1 Wong CH, Wei FC. Anterolateral thigh flap. *Head Neck* 2010;**32**:529-40.
2 Chen HC, Tang YB. Anterolateral thigh flap: an ideal soft tissue flap. *Clin Plastic Surg* 2003;**30**:382-401.
3 Luo SK, Raffoul W, Piget, David V, Egloff. Anterolateral Thigh Fasciocutaneous Flaps in the difficult Perineo-genital reconstruction. *Plast Reconstr Surg* 2000;**105**:171-3.
4 Quazi AG, Reddy M, Shetty KP, Prasad R, Hosi JS, Bhathena M. Groin reconstruction by anterolateral thigh flap: A review of 16 cases. *Indian J Plast Surg* 2004;**37**:34–9
5 Song TG, Chen GZ, Song YL. The free thigh flap: A new free flap concept based on the septocutaneous artery. *Br J Plast Surg* 1984;**37**:149–59.
6 Wei FC, Jain V, Celik N, Chen HC, Chuang DCC, Lin CH. Have we found an ideal

[Downloaded from wjps.ir on 2026-11-24]

soft-tissue flap? An experience with 672 anterolateral thigh flaps. *Plast Reconstr Surg* 2002;**109**:2219–26.
7 Kimata Y, Uchiyama K, Elsihara S, Nakatsukha T, Harii K. Anatomic variations and technical problems of ALT flaps: A report of 74 cases. *Plast Reconstr Surg* 1998;**102**:1017-23.
8 Lee YC, Chiu HY, Shieh SJ. The clinical application of anterolateral thigh flap. *Plast Surg Int* 2011;2011:127353.
9 Shieh SJ, Chiu HY, Yu JC, Pan SC, Tsai ST, Shen CL. Free anterolateral thigh flap for reconstruction of head and neck defects following cancer ablation. *Plast Reconstr Surg* 2000;**105**:2349–57.
10 Lee JT, Cheng LF, Lin CM, Wang CH, Huang CC, Chien SH. A new technique of transferring island pedicled anterolateral thigh and vastus lateralis myocutaneous flaps for reconstruction of recurrent ischial pressure sores. *J Plast Reconstr Aesthet Surg* 2007;**60**:1060–6.

[Downloaded from wjps.ir on 2026-11-24]