

Primary Tuberculosis of Hand Soft Tissue

Mohd Altaf Mir*, Imran Ahmad, Mihd Yaseen

Department of Burns, Plastic and
Reconstructive Surgery, Jawaharlal Nehru
Medical College, AMU, Aligarh, India

ABSTRACT

The musculoskeletal extrapulmonary tuberculosis is uncommon, the upper extremity tuberculosis is not common and the mycobacterial involvement of skin of hands and synovial sheath of tendons is rare. This prospective observational study was undertaken between August 2014 and December 2015 in a tertiary referral hospital. Patients attending with suspected primary tuberculosis of soft tissue of the hand were included. Anteroposterior and lateral radiographs of the hand, wrist and lung and MRI were undertaken. A diagnosis of tuberculosis was made based on histology, and positive culture for *Mycobacterium*. Split thickness skin grafting was done after excision of tubercular cutaneous ulcers of hand. Postoperatively patients were treated with home based anti-tubercular chemotherapy. Lesions of synovial sheath of tendons were excised. Splints or plaster slabs were used in all patients. There were 3 males and 2 females with a mean age of 44.75 ± 6.61 years (19-48 years). Based on clinical suspicion, plain radiographs and MRI, there were 3 patients with involvement of synovial sheath of tendons and 2 patients with involvement of skin of hand. Tuberculosis was confirmed histologically and *Mycobacterium bovis* was confirmed microbiologically. The delayed diagnosis is often due to slow progression and numerous differential diagnoses, which often leads to complications. Early radical excision of the infected tissues combined with anti-tubercular multidrug therapy gives good functional results and prevents recurrence.

KEYWORDS

Tuberculosis; Flexor tendon sheath; Cutaneous; Hand

Please cite this paper as:

Altaf Mir M, Ahmad I, Yaseen M. Primary Tuberculosis of Hand Soft Tissue. World J Plast Surg 2016;5(3):313-318.

INTRODUCTION

The musculoskeletal extrapulmonary tuberculosis is uncommon accounting for about 10-15% of all extrapulmonary tuberculosis.¹ The upper extremity tuberculosis is not common² and the mycobacterial involvement of skin of hands and synovial sheath of tendons is rare. *Mycobacterium bovis* infection accounts for 5-10% of tuberculosis.² The source of *Mycobacterium bovis* for humans is the use of unpasteurized milk, direct contact with infected animals like cow and goat, and inhalation of contagious aerosols.³ The infection may be also acquired by workers at

*Corresponding Author:

Mohd Altaf Mir, MD, MCh Senior
Resident Postgraduate,
Department of Burns, Plastic and
Reconstructive Surgery,
Jawaharlal Nehru Medical College,
AMU, Aligarh, 202002, India
Tel: +91-7060320658
E-mail: draltafmir@gmail.com
Received: December 16, 2015
Revised: May 15, 2016
Accepted: July 15, 2016

slaughter houses.³ Synovial sheath tuberculosis may present with chronic synovitis with or without swelling. The condition may mimic rheumatoid arthritis, sarcoidosis or soft tissue sarcoma. The diagnosis of tuberculosis of synovial sheath of tendon is usually achieved with magnetic resonance imaging and confirmed by histopathology and tubercular cultures. However, the diagnosis of tubercular skin lesions of hand are achieved clinically and confirmed by histopathology and tubercular cultures.³ Here, we described cases of primary tuberculosis of soft tissue of hand.

CASE REPORT

This was a prospective observational study undertaken between August 2014 and December 2015 in a tertiary referral hospital. Patients attending with suspected tuberculosis of soft tissue of the hand were included. Those with a past history of operative treatment were excluded. There were 3 males and 2 females with a mean age of 44.75 ± 6.61 years (19 to 48 years). A detailed history and examination were recorded. A full blood count, ESR, and HIV, hepatitis B and C testing were performed following informed consent. Anteroposterior and lateral radiographs of the hand and wrist were taken in all cases.

MRI was undertaken in patients with suspected tubercular soft tissue swelling in the hand. All patients underwent chest radiography to exclude healed or active pulmonary tuberculosis. A diagnosis of tuberculosis was made on the basis of characteristic histopathology, a positive culture for *Mycobacterium* after excision of the lesion. Split thickness skin grafting (STSG) was done after excision of tubercular cutaneous ulcers in both the cases. Postoperatively patients were treated with home based anti-tubercular chemotherapy (ATT). Splints or plaster slabs were used for a short time in all patients after operative management except in case 1 who required tendon repair and splintage was continued for 6 weeks. All patients were followed up regularly. We represent here two cases of tuberculosis of synovial sheath of tendon and one case of cutaneous tuberculosis of hand.

CASE 1

A 19 year old female presented with painless swelling Zone II index finger of left hand

of 2 years duration restricting the flexion of index finger at inter-phalangeal and metacarpophalangeal joints (Figure 1). She has sustained an injury to the same finger with the knife 3 years back. A radiograph of the left hand shows soft tissue swelling zone II left index finger without any bony lesion. Magnetic resonance image of left hand shows contrast enhanced soft tissue lesion arising from flexor tendon sheath zone II of left index finger (Figure 2). On surgical exploration of flexor compartment of left index finger zone II with Brunner's incision, the swelling arising from flexor tendon sheath of flexor digitorum profundus (FDP) and superficialis (FDS) tendons fixed at the chiasma of FDS (Figure 3), has been excised and the specimen (Figure 4) send for histopathological and microbiological examination.

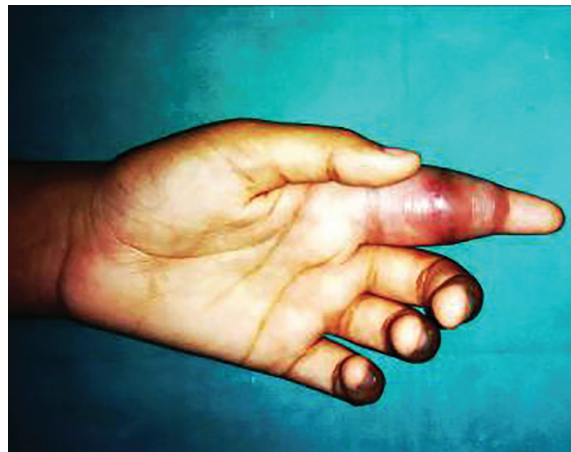

Fig. 1: Preoperative photograph

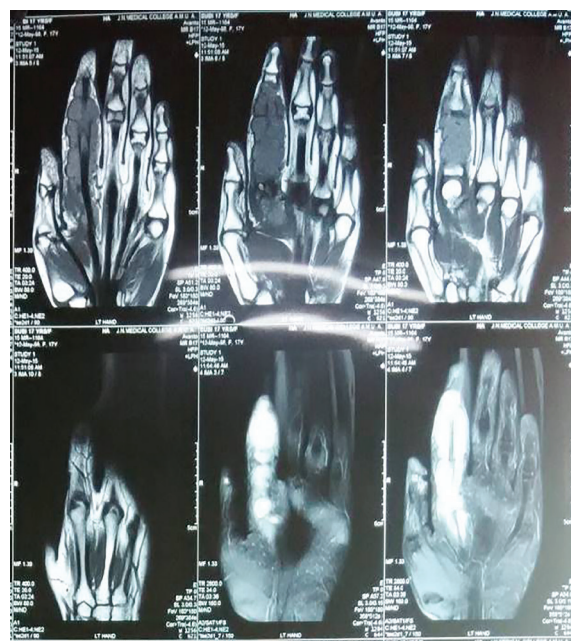


Fig. 2: Magnetic resonance image

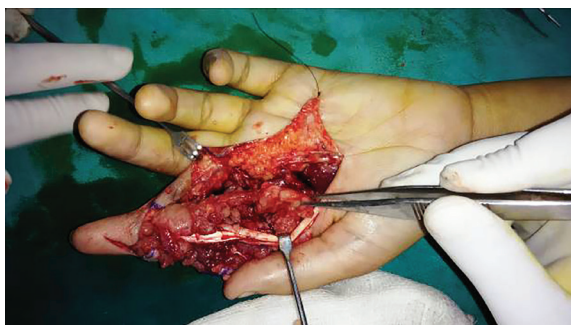


Fig. 3: Intraoperative photograph showing lesion

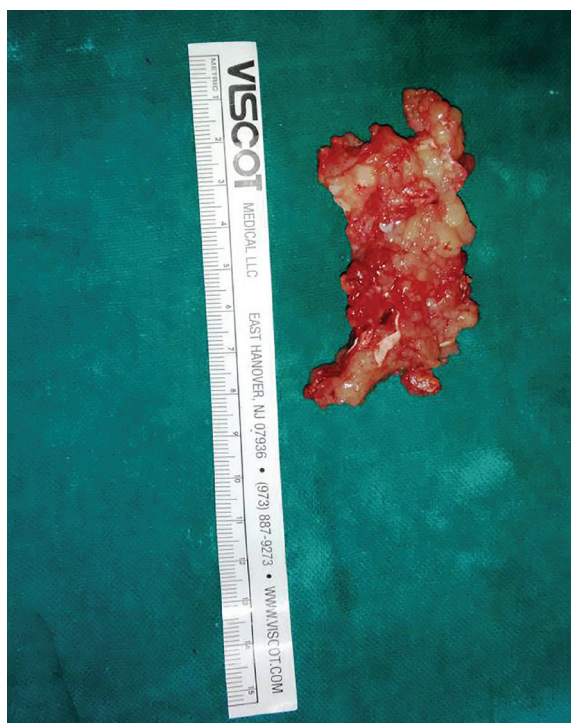

Fig. 4: Excised specimen

The flexor tendons and pulley system of zone II left index finger has been repaired as is shown in (Figure 5), and Brunner's incision closed. Histopathological examination of the excised specimen confirmed the diagnosis of granulomatous tuberculosis as evidenced by rice bodies (Figure 6). The aerobic and anaerobic cultures were negative. The tubercular culture using BACTEC confirmed the presence of *M. bovis*. There is satisfactory functional recovery of hand (Vediot) and she has completed anti-tubercular therapy under the national tuberculosis control program of our country.

CASE 2

A 45 year old male chef presented with painless swelling Zone II of thumb of right hand of 3 years duration restricting the flexion of thumb at inter-phalangeal joint (Figure 7). He

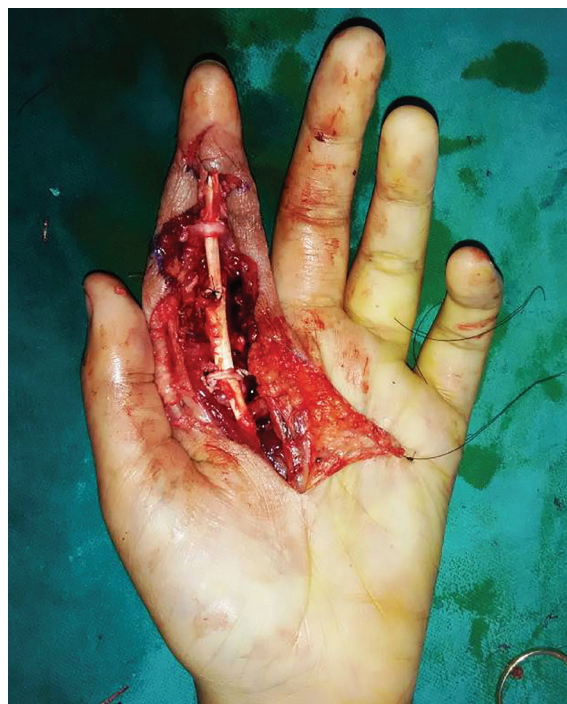

Fig. 5: Intraoperative photograph after excision of lesion

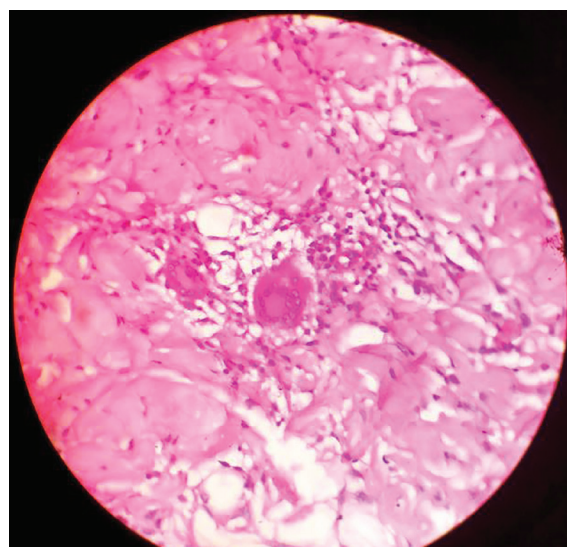


Fig. 6: Histopathological microphotograph

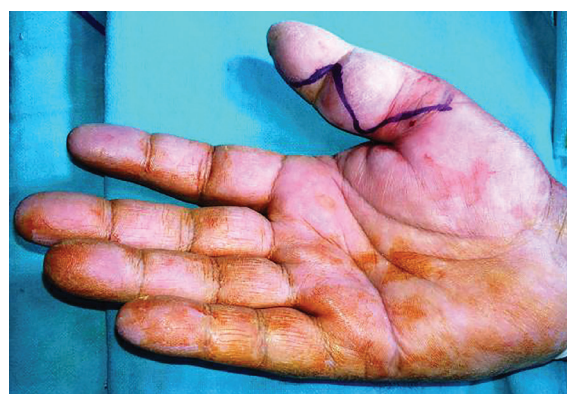

Fig. 7: Preoperative photograph

has sustained an injury to the thumb 5 years back. A radiograph of the right hand shows soft tissue swelling zone II right thumb without any bony lesion. Magnetic resonance image of right hand shows contrast enhanced soft tissue lesion arising from flexor tendon sheath zone II of right thumb. On surgical exploration of flexor compartment of right thumb with Brunner's incision, the swelling arising from flexor tendon sheath of (FPL) flexor pollicis longus (Figure 8), has been excised and the specimen (Figure 9) send for histological and microbiological examination.

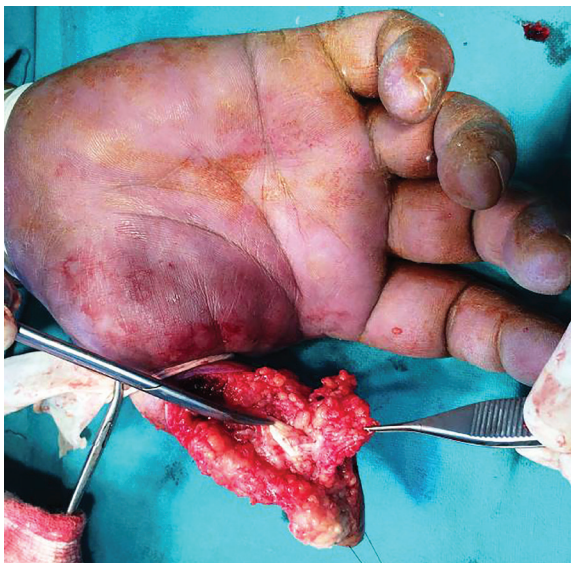

Fig. 8: Intraoperative photograph

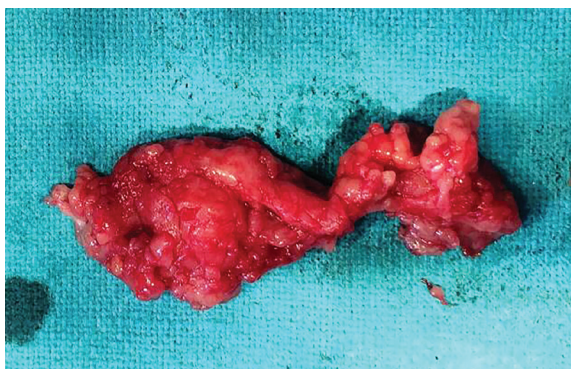

Fig. 9: Photograph of excised specimen

The FPL was intact as shown in (Figure 8), and Brunner's incision closed. The wound healing was satisfactory (Figure 10). Histological examination of the excised specimen confirmed the diagnosis of granulomatous tuberculosis as evidenced by rice bodies. The aerobic and anaerobic cultures were negative. The tubercular culture using BACTEC confirmed the presence of *M. bovis*. There is satisfactory functional

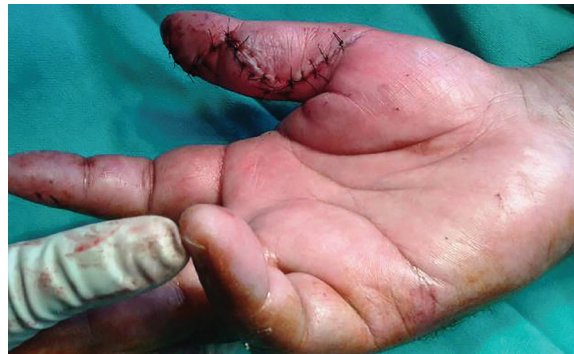

Fig. 10: Postoperative photograph

recovery of hand and he has completed anti-tubercular therapy under the national tuberculosis control program of our country.

CASE 3

A 48 year old male milkman presented with progressive ulcerative lesion dorsum of right hand since 4 years (Figure 11). A radiograph of the right hand excluded any bony lesion. Magnetic resonance image of right hand excluded any tendon sheath lesion. The lesion has been excised and the specimen sent for histopathological and microbiological examination. The postoperative wound was grafted with STSG (Figure 12). The

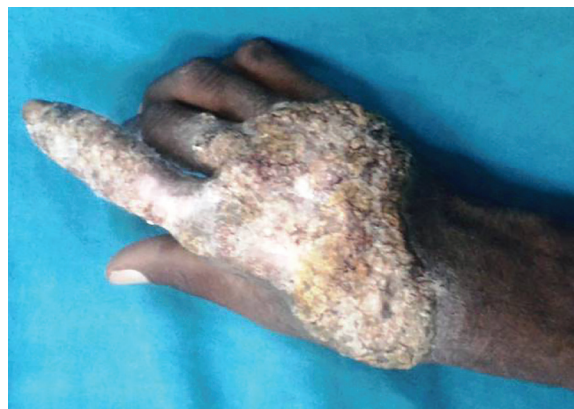

Fig. 11: Preoperative photograph

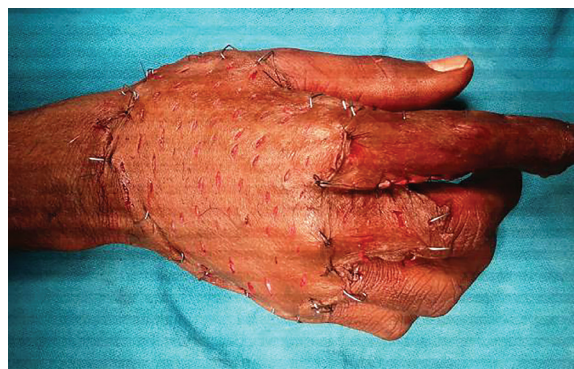

Fig. 12: Intraoperative photograph after excision and Split thickness skin grafting.

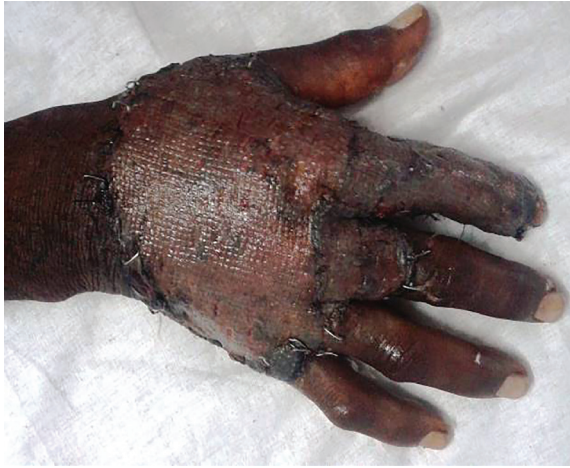

Fig. 13: Postoperative photograph on first dressing

grafted site was inspected for graft taken on 5th day (Figure 13). Histopathological examination of the excised specimen confirmed the diagnosis of granulomatous tuberculosis (Figure 14). The aerobic and anaerobic cultures were negative. The tubercular culture using BACTEC confirmed the presence of *M. bovis*. There is satisfactory functional recovery of hand and he has completed anti-tubercular therapy under the national tuberculosis control program of our country.

The patients with suspected primary tuberculosis of soft tissue of hand were referred to Hand clinic of the department of Plastic and Reconstructive Surgery. There were 3 males and 2 females with a mean age of 44.75 ± 6.61 years (19 to 48 years). Based on clinical suspicion, plain radiographs and MRI, there were 3 patients with involvement of synovial sheath of tendons and 2 patients with involvement of skin of hand. Tuberculosis was confirmed in all the cases by histopathological examination. *M. bovis* was confirmed microbiologically in all the cases as etiological agent.

DISCUSSION

Extrapulmonary tuberculosis of flexor tendon sheath of hand may occur after hematogenous spread of *Mycobacterium* from lungs, lymphatic tissue and other viscera.^{2,4} The *M. bovis* infection may occur due the use of unpasteurized milk, direct contact with infected animals like cow and goat, inhalation of contagious aerosols, and is more common in slaughter house workers.³ Flexor tendon sheath tuberculosis of hand significantly reduce mobility of joints.^{2,5-7} Tendon

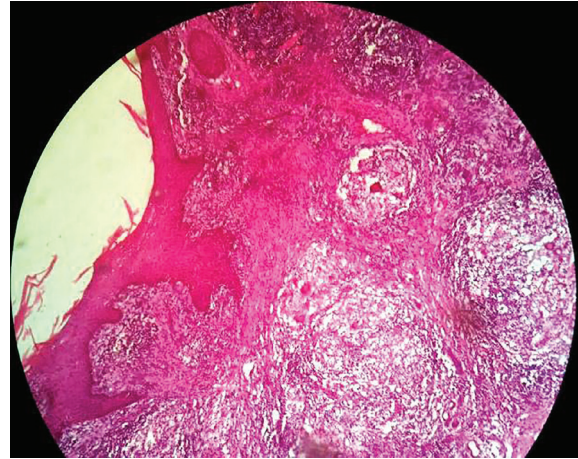


Fig. 14: Histopathological microphotograph

ruptures has been also reported in the literature.^{8,9} Magnetic resonance imaging findings may vary with severity and progression of the disease. It may show thickening of the synovial membrane with increased vascularization, fluid within the tendon sheath, reactive inflammation around the tendon, or swelling of the tendon sheaths.¹⁰⁻¹² Bacteriology of the tissue culture specimen is often required to detect the bacterial infection.¹³

There are three histological forms of tuberculosis of flexor tendon sheath as a result of the progression of the disease, the resistance of the individual, and the varying virulence of the microorganism. In the first stage, the tendon is replaced by vascular granulation tissue. In second stage, the sheath is obliterated by fibrous tissue, fluid is confined within the sheath and rice bodies may appear due to caseation. In third stage, the tendon may be replaced with strands of tissue and may rupture spontaneously. When healing by fibrous tissue formation fails to curtail the pathologic process, extensive caseation and granulation occur which may lead to sinus formation and superimposed secondary infection.^{8,9,14,15}

Rice bodies represent fibrinous masses (tubercles) which are present in 50% of cases.^{15,16} In tuberculosis early diagnosis and radical surgical debridement and anti-tubercular therapy is essential for management.^{13,17,18} Flexor and Extensor tendon involvement and ruptures may need repair or tendon grafting with reconstruction of pulley system. The term "lupus" to describe an ulcerative skin disease dates to the late thirteenth century, though it was not until the mid nineteenth that two specific skin diseases were classified as Lupus erythematosus

and Lupus vulgaris. The diagnosis of cutaneous tuberculosis is complicated and requires a full workup, including a detailed history and physical examination; careful consideration of clinical presentation. Mycobacterial culture remains the most reliable method to determine the presence of mycobacteria.¹⁹

In our study lesions of synovial sheath of tendons of hand, MRI shows contrast enhancement of lesions, histopathological examination of all excised specimen is suggestive of tuberculosis and microbiological examination of all specimen confirmed *M. bovis* infection. Primary tuberculosis of soft tissue of the hand is rare. The delayed diagnosis is often due to slow progression and numerous differential diagnoses, which often leads to complications. Early radical excision of the infected tissues combined with anti-tubercular multidrug therapy gives good functional results and prevents recurrence.

CONFLICT OF INTEREST

The authors declare no conflict of interest.

REFERENCES

- Ozçelik IB, Aydın A, Sezer I, Oztas S. Treatment algorithm in synovial tuberculosis of the hand and wrist: a report of three cases. *Acta Orthop Traumatol Turc* 2006;**40**:255-9.
- Bush DC, Schneider LH. Tuberculosis of the hand and wrist. *Am J Hand Surg* 1984;**9**:391-8.
- Rodwell TC, Moore M, Moser KS, Brodine SK, Strathdee SA. Tuberculosis from *Mycobacterium bovis* in binational communities, United States. *Emerg Infect Dis* 2008;**14**:909-916.
- Tuli SM. General principles of osteoarticular tuberculosis. *Clin Orthop Relat Res* 2002;**398**:11-19.
- Al-Quattan MM, Bowen V, Manktelow RT. Tuberculosis of the hand. *J Hand Surg* 1994;**19-B**:234-7.
- Elbaz JS, Lambilliotte P, Schaeffer. Tuberculous synovitis of the hand. *Bull Mem Soc Chir Paris* 1968;**58**:92-103.
- Leclercq D, Lejeune G, Carlier A, Jodogne G. Spontaneous rupture of the superficial and deep common flexors of the index finger caused by tuberculous synovitis. *Acta Orthop Belg* 1980;**46**:262-71.
- Burkhardt E. Chronic diseases of the synovial sheath (from hand surgery consulting hour). *Beitr Orthop Traumatol* 1972;**19**:377-91.
- Jaovisidha S, Chen C, Ryu KN, Siri Wongpairat P, Pekanan P, Sartoris DJ, Resnick D. Tuberculous tenosynovitis and bursitis: imaging findings in 21 cases. *Radiology* 1996;**201**:507-13.
- Lee SH, Abramson SB. Infections of the musculoskeletal system by *M. tuberculosis*. In: Tuberculosis. 4th edition. Edited by: Rom WN, Garay SM. New York, NY: Little, Brown and Company; 1996; pp. 635-644.
- Jackson RH, King JW. Tenosynovitis of the hand: a forgotten manifestation of tuberculosis. *Rev Infect Dis* 1989;**11**:616-18.
- Fnini S, Ouarab M, Rafai M, Cohen D, Largab A, Trafah M. An uncommon occupational accident: tuberculous tenosynovitis of the extensor of the hand. *Chir Main* 1999;**18**:309-12.
- Visuthikosol V, Kruavit A, Nitiyanant P, Siri Wongpairat P. Tuberculous infection of the hand and wrist. *Ann Plast Surg* 1996;**37**:55-9.
- Kanavel AB. Tuberculous tenosynovitis of the hand: a report of fourteen cases of tuberculous tenosynovitis. *Surg Gynecol Obstet* 1923;**37**:635-47.
- Aboudola S, Sienko A, Carey RB, Johnson S. Tuberculous tenosynovitis. *Hum Pathol* 2004;**5**:1044-6.
- Hoffman KA, Bergman AG, Hoffman DK, Harris DP. Tuberculosis tenosynovitis of the flexor tendons of the wrist: MR imaging with pathologic correlation. *Skeletal Radiol* 1996;**25**:186-8.
- Benkeddache Y, Sidhoum SE, Derridj A. Various aspects of tuberculosis of the hand : A propos of a series of 45 cases. *Ann Chir Main* 1988;**7**:166-75.
- Blue ML, Payne WG, Mannari RI, Moffitt MR, Walusimbi MG, Robson MC. *Mycobacterium kansasii* causing carpal tunnel syndrome with concomitant pulmonary *Mycobacterium tuberculosis* infection. *South Med J* 2002;**95**:1095-8.
- Hernandez C, Cetner AS, Jordan JE, Puangsuvan SN, Robinson JK. Tuberculosis in the age of biologic therapy. *J Am Acad Dermatol* 2008;**59**:363-80.