Case Report

Fibular Bone Graft for Nasal Septal Reconstruction: A Case Report

Yakup Cil[1*]

Diyarbakır Military Hospital, Department of Plastic Surgery 21000 Diyarbakır, Turkey

ABSTRACT

Although various techniques have been described for treatment of severe nose deformities, these problems have high revision rates. Conventional nasal septal surgery may not be adequate for all cases. A 21-year-old male patient with nose deformity underwent a nasal surgery. Patient had both functional and aesthetic nasal problems. Rigid fibular bone graft was used for corrective nasal surgery. Duration of the operation was three hours. Patient recovered without problems. Aesthetic and functional results of the operation were acceptable. Fibular bone graft may offer a long lasting support in treatment of severe nose deformity.

KEYWORDS
Fibula; Bone graft; Nose deformity

Please cite this paper as:
Cil Y. Fibular Bone Graft for Nasal Septal Reconstruction: A Case Report. World J Plast Surg 2017;6(2):220-224.

INTRODUCTION

Although various techniques have been described for nose deformity corrections,[1,2] these problems still have high recurrence and revision rates. Conventional nasal septal surgery may not be adequate for preventing recurrences. In the management of this case; fibular bone graft have been used for corrective nasal surgery.[1,2]

CASE REPORT

A 21-year-old male patient with nose deformity underwent a nasal surgery. Nasal deformity was secondary to congenital cleft lip-nose. He had been operated for cleft lip-nose in childhood. Patient had functional and cosmetic nasal problems when he admitted to our clinic. Physical examination showed that the nasal septum was severely distorted. We decided to use fibular bone graft for nasal septal reconstruction. After local anesthetic infiltration, nasal structures were exposed through an open rhinoplasty approach. Following hump resection, septum was dissected subperichondrially.

Nasal septal cartilage was thick and it was distorted. Septal cartilage sculpturing was not possible and distorted cartilage septum was removed. Fibular bone graft was taken from lateral

***Corresponding Author:**
Yakup Cil, MD;
Diyarbakır Military Hospital,
Department of Plastic Surgery,
21000 Diyarbakır, Turkey
Tel: +90 412 2288225/7930
Fax: +90 412 2236237
E-mail: yakupcil@yahoo.com
Received: July 6, 2016
Revised: January 18, 2017
Accepted: February 11, 2017

[Downloaded from wjps.ir on 2026-11-23]

side of the fibula (Figure 1). Lateral leg muscles were protected during bone graft harvesting procedure. Bone graft was thinned by abrasion and shaped as L-strut as "key in the keyhole pattern" (Figure 2). The dorsal strut was placed as tongue in groove technique on the nasal bone. L-strut frame was sutured to upper lateral cartilage remnants and the domes of two lower lateral cartilages to hide palpable edges and secure it at its place. Lateral and median osteotomies were performed. Duration of the operation was three hours. After closure, nasal packing and plaster cast were applied.

A plaster cast was also applied on the leg and removed 1 week later. The packing and the nasal splint were removed at 3th and 7th days, respectively. Patient has recovered without problems. Aesthetic and functional results of the operation were acceptable in aspect of patient's satisfaction (Figures 3 and 4). The follow-up period was 24 months. The graft did not shift, and did not develop unsightly irregularities over time. No donor site complication has been observed.

DISCUSSION

Nasal septum support is crucial for long lasting results for management of complicated nose reconstruction.[2] The most popular method is reinforcement of corrected septum with spreader grafts.[1,2] Unilateral spreader-extension grafts,[3] asymmetric spreader grafts[4] were described to restore the integrity of septal L-struts. However, relatively weak cartilage grafts (obtained from severe deviated cartilaginous septum itself) cannot maintain adequate septal support. A more rigid framework is necessary against deforming forces during treatment period. However alloplastic materials were used as spreader grafts for more rigid stabilization,[5] there has been concerns about using alloplastic materials. Ribs are shaped as spreader grafts but rib cartilage has an unpredictable tendency to bend overtime.[6]

Other disadvantages of rib harvest comprise risk of pneumothorax. Different bone graft sources were described for nasal reconstruction.[7-9] Fibula is a longitudinal bone



Fig. 1: Bone graft was taken from the lateral side of fibular bone. Radiologic appearance of fibular bone graft donor site is also seen.

[Downloaded from wjps.ir on 2026-11-23]

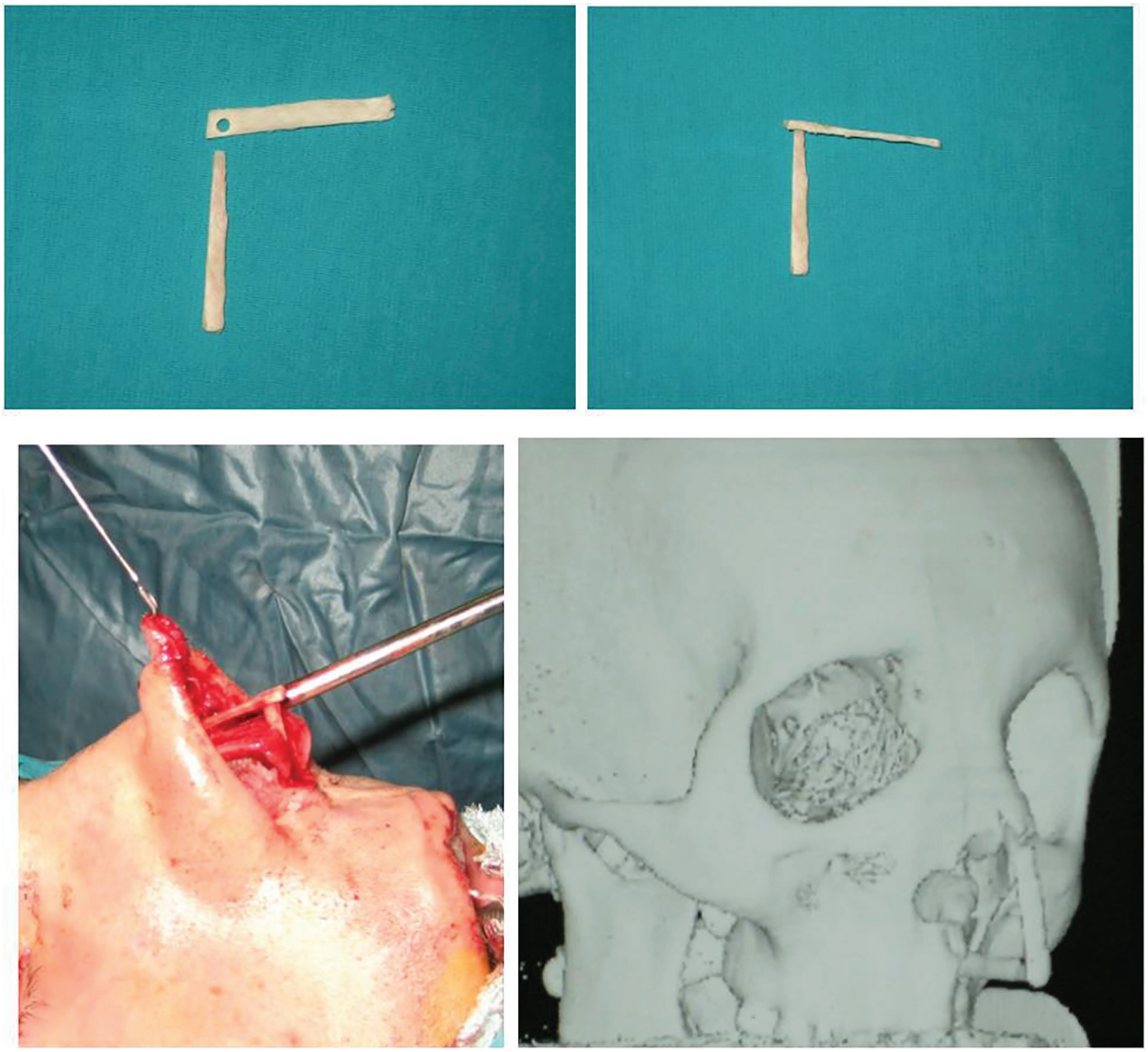

Fig. 2: Two pieces of L-strut bone graft (above, left). A interlocked design (key in the keyhole pattern; above, right) L-strut bone graft was placed the nose (below, left). Three dimensional CT imaging of L-strut bone graft (below, right) is seen.

as radius,[8] and it is not curved as olecranon[9] and calvarial bone.[10] Lateral aspect of fibula provides a source of straight framework when shaped properly. The dorsal strut was placed as tongue in groove technique, and it was interlocked with caudal strut as "key in the keyhole" pattern. L-strut shaped bone graft supports the realigned caudal-dorsal septum position. Fibular bone graft did not obstruct airway for its delicate shape. We believe that fibular bone grafts offer a long lasting support in treatment of selected nose deformities.

CONFLICT OF INTEREST

The authors declare no conflict of interest.

REFERENCES

1 Guyuron B, Uzzo CD, Scull H. A practical classification of septonasal deviation and an effective guide to septal surgery. *Plast Reconstr Surg* 1999;**104**:2202-9.

2 Daniel, R.K. Rhinoplasty: septal saddle nose deformity and composite reconstruction. *Plast Reconstr Surg* 2007;**119**:1029-43.

3 Byrd HS, Salomon J, Flood J. Correction of the crooked nose. *Plast Reconstr Surg*1998;**102**:2148-57.

4 Rohrich RJ, Gunter JP, Deuber MA, Adams WP Jr. The deviated nose: optimizing results using a simplified classification and algorithmic approach. *Plast Reconstr Surg*

[Downloaded from wjps.ir on 2026-11-23]

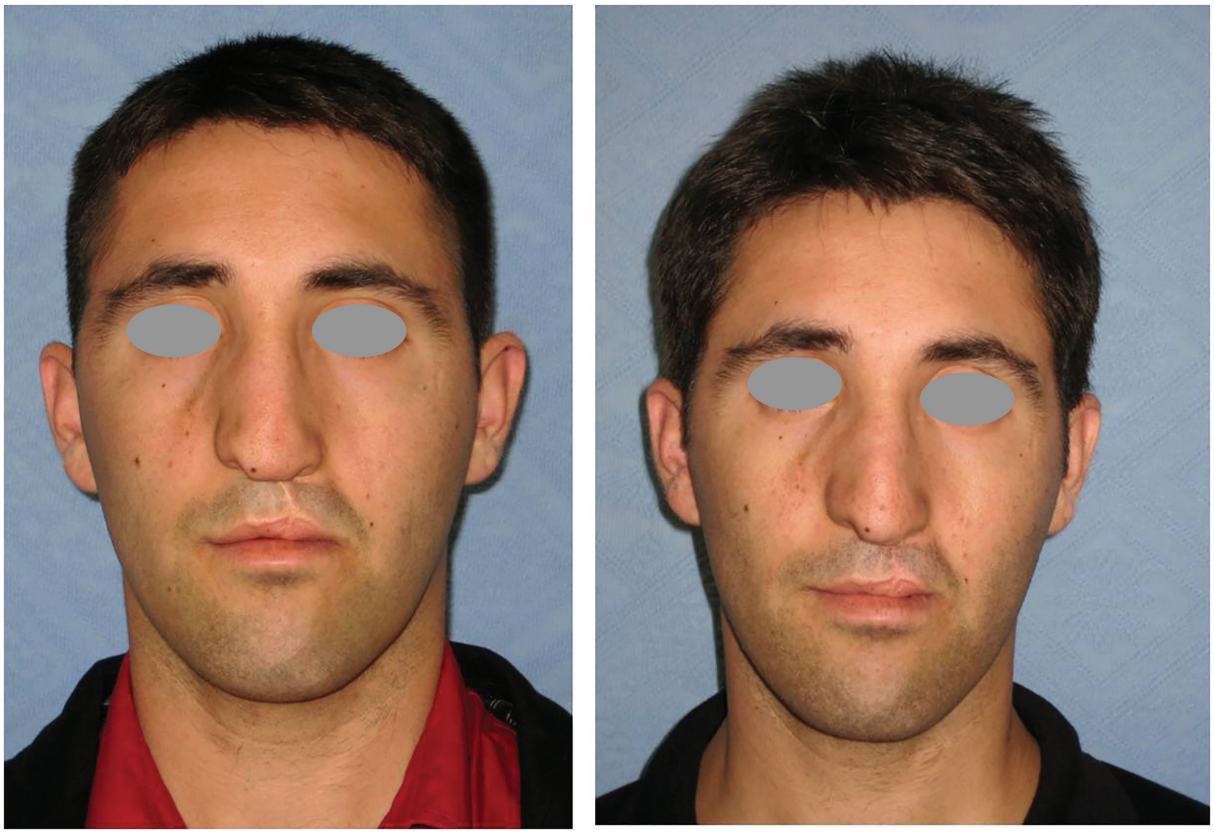

Fig. 3: Preoperative anterior view of the patient with nose deformity (left). Postoperative twenty-four months later view (right).

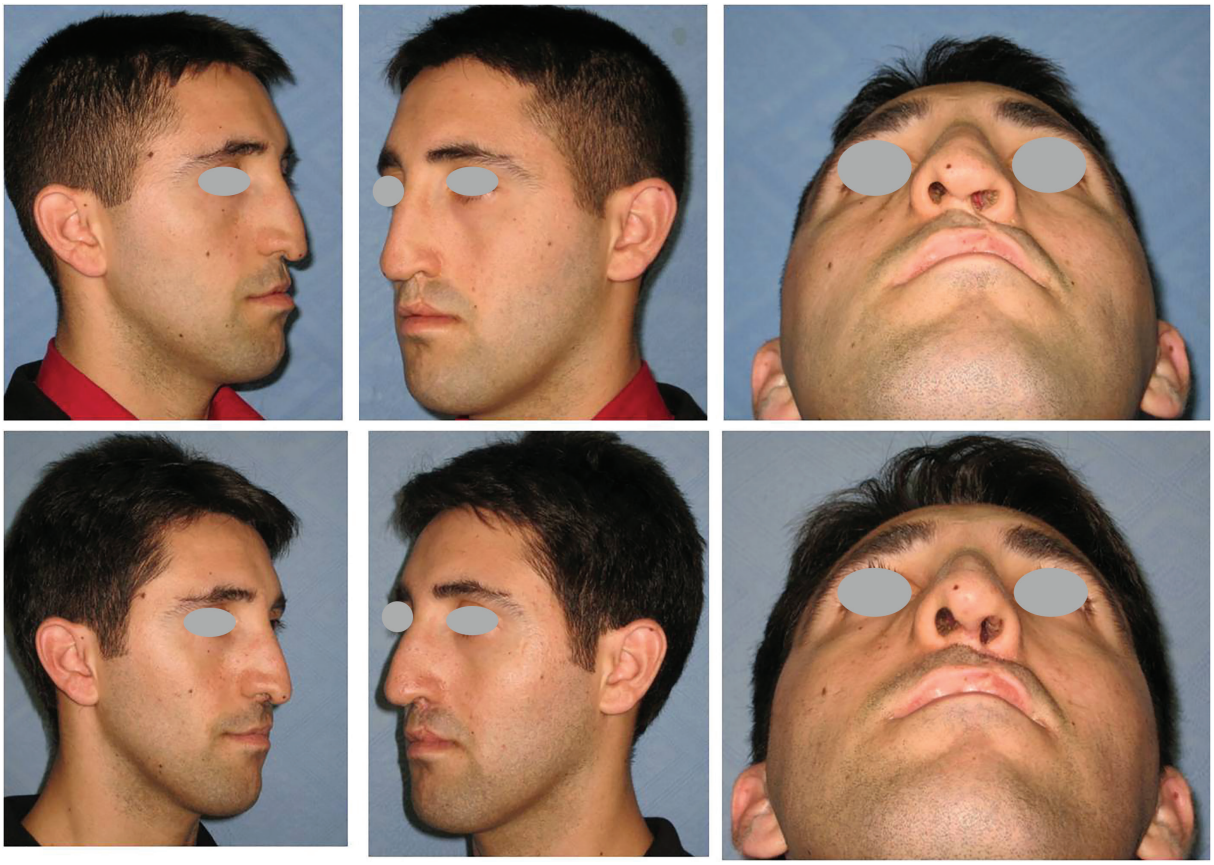

Fig. 4: Preoperative oblique (above; left and center), inferior view (above, right) of the nose deformity. Postoperative twenty-four months oblique (below; left and center), inferior view (below, right).

[Downloaded from wjps.ir on 2026-11-23]

2002;**110**:1509-23.
5 Mendelson M. Straightening the crooked nose middle third of the nose: using porous polyethylene extended spreader grafts. *Arch Facial Plast Surg* 2005;**7**:74-80.
6 Gunter JP, Clark CP, Friedman RM. Internal stabilization of autogenous rib cartilage grafts in rhinoplasty: a barrier to cartilage wraping. *Plast Reconstr Surg* 1997;**100**:161-9.
7 Cil Y, Ozturk S, Kocman AE, Isik S, Sengezer M. The crooked nose: the use of medial iliac crest bone graft as a supporting framework. *J Craniofac Surg* 2008;**19**:1631-8.
8 Cil Y, Kocman AE, Yapici AK, Ozturk S. Radial bone graft usage for nasal septal reconstruction. *Indian J Plast Surg* 2011;**44**:36-40.
9 Hodgkinson, DJ. The Olecranon Bone Graft for Nasal Augmentation. *Aesth Plast Surg* 1992;**16**:129-32.
10 Zanaret M, Bouvier C, Bonnefille E, Estublier N, Giovanni A. The use of calvarial bone in nasal reconstruction. *Ann Otolaryngol Chir Cervicofac* 1999;**116**:16-26.

[Downloaded from wjps.ir on 2026-11-23]