Tendon Transfer in Congenital Deficiency of Flexor Pollicis Longus

Masoud Yavari[1], Ramin Farzam[1*], Azade Riyahi[2]

1. Department of Hand Surgery, 15th Khordad Hospital, Shahid Beheshti University of Medical Sciences, Tehran, Iran;
2. Department of Occupational Therapy, Shahid Beheshti University of Medical Sciences, Tehran, Iran

***Corresponding Author:**
Ramin Farzam, MD;
Department of Hand Surgery,
15th Khordad Hospital,
Shahid Beheshti University of Medical Sciences,
Tehran, Iran
E-mail: raminfarzam2007@yahoo.com
Received: June 26, 2015
Revised: October 11, 2016
Accepted: December 9, 2016

DEAR EDITOR

Congenital absence of flexor pollicis longus without associated anomalies is a rare cause of inability to flex the inter-phalangeal (IP) joint of the thumb. Other causes are: anomalous insertion of flexor pollicis longus (FPL), congenital tenovaginitis of the flexor tendon sheath, partial anterior interosseous nerve paralysis, traumatic rupture of FPL and anomalous bands connecting tendons.[1]

A three year old right handed girl was first observed by her parents to be unable to flex IP joint of her right thumb. The family history was negative for congenital anomalies. She had been operated for Hypertrophic pyloric stenosis when she was three weeks old. IP joint was hyper extended and active flexion was 0 degree and passive flexion was 30 degrees. No thenar muscle atrophy was noted. The patient was candidate for surgery with primary diagnosis of congenital trigger thumb.

The thumb was explored from base of the distal phalanx to distal of thenar muscles. The FPL was absent and a fibrous band was present instead. No pulley was present. Intra operative diagnosis was made and two stage re construction was planned. At first stage, a silicon rubber rod was inserted from zone 1 to zone 5. Then the fibrous band was cut proximally and formed as oblique pulley. The second stage of surgery was carried out by removing the flexor digitorum superficialis of ring finger. The IP joint was tensioned to 15 degree of flexion. Thumb spica cast was applied at the end of surgery. One month later, the cast was removed and rehabilitation by occupational therapist started. Fifty degree of flexion was gained after three months (Figure 1) and (Figure 2).

The absence of FPL associated with aplasia of the thenar muscles was first described by Fromont in 1895.Uchida proposed a classification of absence of FPL with associated anomalies.[1] They are divided into four groups: (i) Absence,[1-5] (ii) Abnormal,[6,7] (iii) Abnormal course,[1] and (iv) Abnormal connection. Our case was type (i) which is a rare type.[1] Clinically, the affected thumb is smaller than the other with a faint or absent flexion crease and restricted flexion at IP joint.

Ultrasound scans, routine X-rays and MRI nave been mentioned in various reports and investigations. Sonography is reported as an initial imaging modality and MRI to be considered as a complementary technique.[8-10]

Treatment options are one or two stage tendon transfer or fusion of IP joint, in functional position, in case of weakness or

[Downloaded from wjps.ir on 2026-11-23]

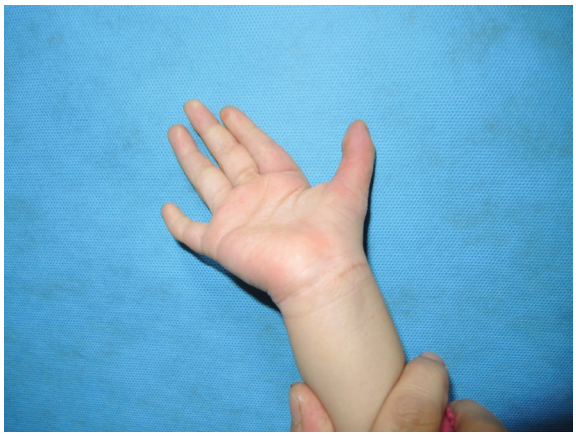

Fig. 1: Thumb position at rest after surgery.



Fig. 2: Thumb position actively flexed after surgery.

painful movements of the thumb. In our case, two stage tendon transfer was done and the result was good according to ´white´ criteria. So tendon transfer can be done at three years of age without fearing of adhesion or co-operation of the child.

CONFLICT OF INTEREST

The authors declare no conflict of interest.

KEYWORDS
Flexor pollicis longus; Tendon transfer; Congenital aplasia

Please cite this paper as:
Yavari M, Farzam R, Riyahi A. Tendon Transfer in Congenital Deficiency of Flexor Pollicis Longus. World J Plast Surg 2017;6(1):123-124.

REFERENCES

1 Uchida M, Kojima T, Sakurai N. Congenital absence of flexor pollicis longus without hypoplasia of thenar muscles. *Plast Recontr Surg* 1985;**75**:413-6.
2 Thomas C, Mathivanan T. Congenital absence of flexor pollicis longus without hypoplasia of the thenar muscles. *J Hand Surg* 1989;**24**:3385-6.
3 DeHaan MR, Wong LB, Petersen DP. Congenital anomaly of thumb: aplasia of the flexor pollicis longus. *J Hand Surg*1987;**12**:108-9.
4 Koster G. Isolated aplasia of the flexor pollicis longus; a case repoprt . *J Hand Surg*1984;**9**:870-1.
5 Usami F. Bilateral congenital absence of the flexor pollicis longus with craniofacial abnormalities. *J Hand Surg* 1987;**12**:603-4.
6 Hagan HJ, Idler RS.Limitation of thumb flexion due to unusual insertion of the flexor pollicis longus. *J Hand Surg* 1988;**13**:474-6.
7 Nacamura J, Kubo E. Bilateral anomalous insertion of flexor pollicis longus. *J Hand Surg* 1993;**18**:312-5.
8 Alicioglu B. Radiologic findings of the flexor pollicis longus hypoplasia. *Shelet Radiol* 2007;**36**:120-30.
9 Demirseren ME, Afandiyer K, Durgan M, Kilicarslan K,Yorubulut M. Congenital absence of flexor pollicis longus tendon without associated anomalies of thumb hypoplasia; a case report and review of the literature. *J Hand* 2007;**2**:184-7.
10 Yavari M, Abdolrazaghi HA, Riahi A. A comparative study on tendon transfer surgery in patients with radial nerve palsy. *World J Plast Surg* 2014;**3**:47-51.

[Downloaded from wjps.ir on 2026-11-23]