

Distally Based Dorsal Flag Flap for the Fingertip Defects

Veena Prabhakar Waiker¹, Shantha Kumar Shivalingappa¹, Kumaraswamy Mohan^{1*},
Manjunath Kamlapurmat Nagabhushanaiah¹

1. Department of plastic surgery, Ramaiah Medical College, Bangalore, India.

ABSTRACT

Background

Fingertip injuries are common in plastic surgery practice, with multiple options for the treatment. Dorsal flag flap has been one of the options for the treatment and it has been explained as a proximally based flap. We have tried to understand the reliability of the distally based dorsal flag flap for the finger defects.

Methods

This work was a retrospective study of consecutive patients with fingertip injuries who had undergone the distally based dorsal flag flap for reconstruction.

Results

Among 19 patients who underwent reconstruction with the flag flap, 16 hetero-digital flap reconstructions, while 4 homo-digital flap reconstructions were done. We lost one flap, which was used for the same fingertip reconstruction. We had four patients with fingertip ulceration on the flap by 2 months which healed by regular dressings.

Conclusion

Distally based dorsal flag flap robust flap, which has a narrow base thus, improves maneuverability and helps in bringing the fingers to a comfortable position.

Keywords

Fingertip Defects; Dorsal flag flap has; India

Please cite this paper as:

Prabhakar Waiker V., Kumar Shivalingappa S., Mohan K., Kamlapurmat Nagabhushanaiah M. Distally Based Dorsal Flag Flap for the Fingertip Defects. *World J Plast Surg.* 2022;11(3):47-52.
doi: 10.52547/wjps.11.3.47

*Corresponding Author:

Dr Kumaraswamy MOHAN

Department of plastic surgery,

Ramaiah Medical College,

New Bel Road,

Bangalore-560054

India.

Tel.: +919886775395

Email: doctorkums@rediffmail.com

Received: 29 May 2021

Accepted: 27 Aug 2021

INTRODUCTION

Fingertip injuries are commonly seen after industrial or domestic accidents. The simple defects (no bone/tendon/joint exposed) which are less than 1.5 sq. cm can be treated by regular dressings and they heal by secondary intention. The simple wounds, which are more than 1.5 sq cm, can be covered with a skin graft. Complex wounds that are less than 2.5 X 3cm can be resurfaced with finger flaps¹ such as V-Y advancement flaps, cutler beard flaps, Venkatswami flaps, cross finger



This work is licensed under a Creative Commons Attribution-NonCommercial 4.0 International license (<https://creativecommons.org/licenses/by-nc/4.0/>). Non-commercial uses of the work are permitted, provided the original work is properly cited.

flaps and its modifications, Moberg flaps, distant flaps like abdominal flaps, groin flaps, chest flaps. Each of these has its advantages and pitfalls. The advantages of the above flaps in each patient differ with the size of the defect, maneuverability of the flap, ease of raising the flap, operative time, etc.

The modifications of the cross-finger flaps² are conventional cross finger flap based either proximally/ distally/laterally. The broad base hinders the movement of the flap from the donor to the recipient site. Hence, effectively the reach of the working area of the flap is less effective. Conventionally, any random pattern flap needs a 1:1 dimension, but, if the base of the flap is decreased or does not include the supporting vessels, the flap would face vascular complications. Many authors have designed flaps based on the perforators of the digital vessels, and have been successful. These propeller flaps of the fingers have improved the movement of the flaps to the defect than conventional flaps. However, the need for magnification, with a very small window for error makes it a difficult flap. Hence, we tried to study the reliability of the flag flap, which is designed to have a small base.

Flag flaps have been described as a flag-shaped flap with the pole as the bridge pedicle carrying the blood vessels. Conventionally dorsal flag flaps are based proximally, our series studies the distally based dorsal flag flaps. Flag flaps have a narrow base, which improves mobility and maneuverability. This could be used as a homo-digital or hetero-digital flap based proximally or distally³. Thus, the flap could reach either the dorsal defect or the palmar defect or the tip on the adjacent finger as well as the same finger.

We aimed to study the feasibility/indications/utility/success of the use of distally based flag flap.

- To analyze the site and size of the defect,
- Flap size, flap donor site,
- Outcomes in terms of flap survival and Complications of flap loss.
- Recovery of sensation and finger movements at 12 months.

METHODS

This retrospective study was conducted at Ramaiah Medical College Hospital, Bangalore, India, after approval from the Ramaiah Medical College institutional Ethics Committee. Informed consent

was obtained from all the patients before the procedure. The study was conducted as per the "Declaration of Helsinki".

We included consecutive patients who had undergone a distally based flag flap for reconstruction between Jan 2018 to Jan 2019. Case records with inadequate data and follow-up were excluded. The patient details like age, sex, defect site, flap size, flap donor site, and the outcomes as mentioned above were recorded and analyzed. In the present series, 15 male patients and 4 female patients (3.75:1) satisfied our inclusion criteria. All the patients had workplace-associated injuries except one lady who had a domestic injury. The patients were aged between 21 to 70 years of age with an average age of 31.2.

Procedure

The procedures were done under regional anesthesia with a digital tourniquet and loupe magnification after written and informed consent. The required flap was planned in reverse. The pole of the flap was designed such that it included half the width of the dorsum of the finger, a minimum of one-third of the length of the phalanx (Figure 1). The dissection was stopped just before the interphalangeal joint. The flap was raised and inset was given. One of our patients, had lost a cross finger flap from the proximal phalanx, a flag flap was harvested from the index finger based distally on the DIP to cover the tip (Figure 2). The donor site was covered with a thick split-thickness skin graft. The hand was immobilized in a functional position. The Flap was divided by 10-15 days. Regular follow up was done for 12 months. Physiotherapy and scar therapy was advised.

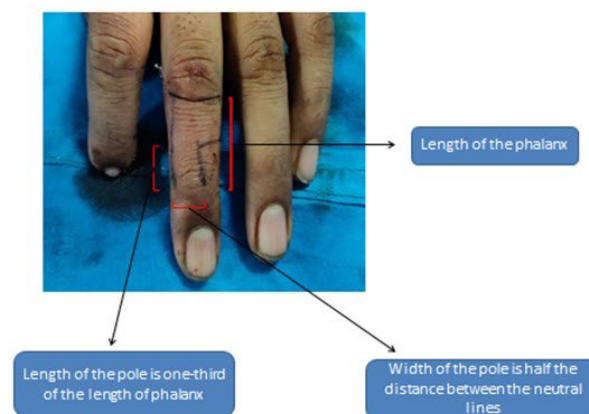


Figure 1: Figure represents the marking of the distally based flag flap.

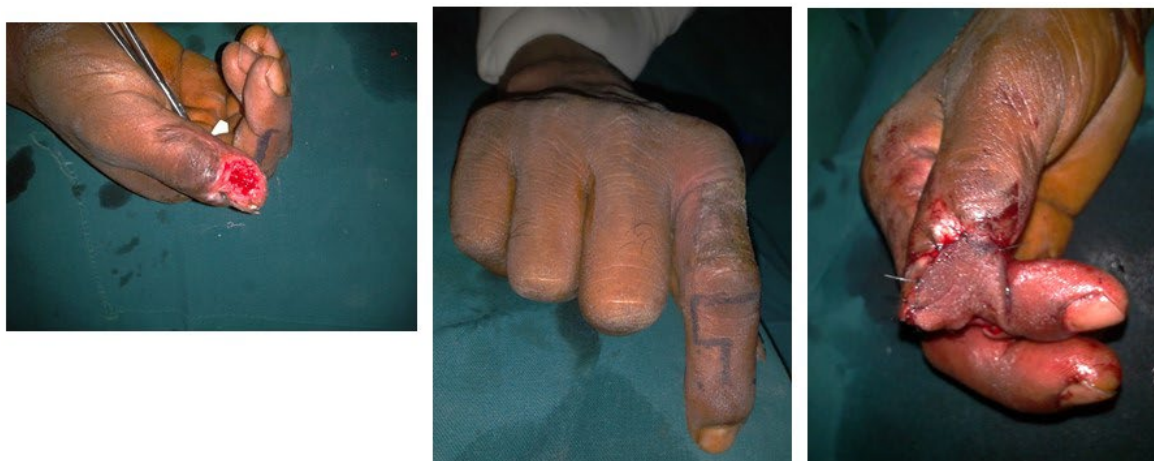

Figure 2: Fingertip injury of the thumb, flag flap harvested from the index finger based distally on the DIP. The patient had lost a cross finger flap from the proximal phalanx before the procedure.

RESULTS

In the present series, 12 (60%) patients were aged between 20 to 30 years. The index finger was the most commonly involved in 9 (45%) patients. The sizes of the defects (Table 1) were between 2cm X 2cm to 3cm X 2.5 cm with a mean of 5.7 square cm size. The donor flap was middle and index finger in 8 (40%) patients, while in 4 (20%) patients ring finger was used as the donor finger. All the flaps were distally based. Among them, 2 flaps were based at the proximal interphalangeal joint and 18 at the distal interphalangeal joint. Homo-digital flaps (Figure 3) were used in 4 (20%) finger-tip injuries and hetero-digital flaps were used in 16 (80%) finger-tip injuries. In one patient, we used hetero-digital flap for index and middle finger (figure4). All the flaps except one homo-digital flap survived, with a success rate of 95%. Wound cover without any flap necrosis was considered as successful use of flap reconstruction. The success rate of the hetero-digital flaps was 100% (16 flaps) and that of homo-digital flaps was 75% (3 cases out of 4 flaps).

All the patients were followed up for 12 months; they were able to perform all their routine activities. All the patients had a full range of motion and the two-point discrimination at the end of 12 months was between 10-15 mm with an average of 12 mm. One patient had venous congestion; skin graft was used to resurface. During follow up, 4 patients came with a superficial wound on the flap after 2 months, which healed with regular dressing.

DISCUSSION

Fingertip injuries are a common occurrence in the workplace as well as at homes, due to accidents. The severity of injuries ranges from simple injuries, which may require only regular dressings to amputations of the tip. Complex injuries that require flap cover are also common. The objective of the treatment is wound healing, functional restoration, and aesthetic restoration. In the present series, we had accidents predominantly due to industrial injuries. The cross-finger flap was first described by Cronin⁴ in 1951, and was called by Gurdin as a trans digital flap⁵. Since then, there are multiple modifications of the flap to suit the reconstruction.

We have observed that the conventional cross finger flaps have a large base, which hinders the movement of the flap. These flaps are indicated commonly for palmar defects. The flaps may be based distally⁶ or proximally to cover the dorsal aspect and the tip. The flag flap is indicated for the tip, dorsal and palmar defects. This is possible because of the pedicle location at the interphalangeal joint. The lateral position of the cross-finger flap pedicle makes it difficult to cover the dorsal defects. The de-epithelialized cross finger flap⁷ can be used to cover the dorsum of the finger when conventional cross finger flap based laterally cannot cover the dorsal defect. Chances of formation of inclusion cysts with this flap are known. The cross finger adipo-fascial flap can be used to cover both dorsum and palmar defects⁸. However, raising flap requires separating

Table 1: Details of the participants indicating the data collected.

| Sl no. | Age/sex | Finger tip involved | Flap size | Donor finger | Flap base | Comp. | Treatment |
|--------|---------|---------------------|--------------|--------------------|-----------|-------------------|---------------------|
| 1 | 20/m | Thumb | 2.5 X 3cm | Index finger(Ht) | PIP | nil | Nil |
| 2 | 24/m | Thumb | 2.5x2cm | Index finger(Ht) | DIP | nil | Nil |
| 3 | 22/f | Thumb | 2.5X3cm | Index finger | PIP | nil | Nil |
| 4 | 21/m | Index | 2.5X2cm | Middle finger (Ht) | DIP | nil | Nil |
| 5 | 40/m | Index | 2.5.X 2cm | Middle finger | DIP | nil | Nil |
| 6 | 25/f | Index | 2X2.5 cm | Middle finger | DIP | nil | Nil |
| 7 | 54/m | Index | 3X2.5 cm | Middle finger (Ht) | DIP | nil | Nil |
| 8 | 25/m | Index | 2.5X3 cm | Index finger (Ho) | DIP | Venous congestion | Split skin grafting |
| 9 | 23/f | Index | 2.5X2cm | Index finger (Ho) | DIP | nil | Nil |
| 10 | 40/m | Index | 2.5 X 2cm | Index finger (Ho) | DIP | nil | Nil |
| 11 | 36/m | Index | 2.5X2cm | Index finger (Ho) | DIP | nil | Nil |
| 12 | 29/m | Index | 2.5X2.5 cm | Middle finger(Ht) | DIP | nil | Nil |
| 13 | 32/m | Middle | 2.5X2cm | Ring finger (Ht) | DIP | nil | Nil |
| 14 | 24/m | Middle | 2.5 X 2.5 cm | Index finger(Ht) | DIP | nil | Nil |
| 15 | 70/f | Middle | 2.5X2.5cm | Ring finger(Ht) | DIP | nil | Nil |
| 16 | 27/m | Ring | 2.5X2cm | Middle finger (Ht) | DIP | nil | Nil |
| 17 | 24/m | Ring | 2.5X2.5 cm | Middle finger | DIP | nil | Nil |
| 18 | 37/m | Ring | 2,5X2cm | Middle finger | DIP | nil | Nil |
| 19 | 27/m | Little | 2X2 cm | Ring finger | DIP | nil | Nil |
| 20 | 36/m | Little | 2X2cm | Ring finger | DIP | nil | Nil |

cm- centimeter, DIP- distal interphalangeal joint, PIP-proximal interphalangeal joint, Ht-hetero digital, Ho- homodigital

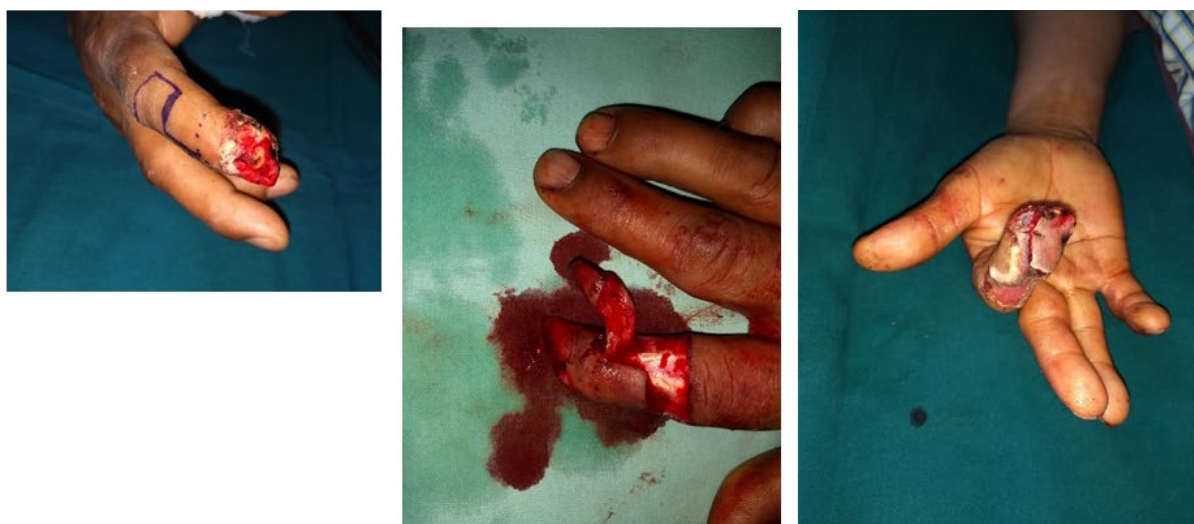


Figure 3: Homo-digital Flag flap has been used for index finger.

the dermis from the adipo-fascial part, which is the difficult part of the flap harvest. The above cross finger flaps may bring the two fingers in an uncomfortable position.

In the present series, we have more male patients, due to the greater number of the male workforce on the machines. Index finger (45%) was the most commonly injured finger in our series similar to other studies^{9,10}.

In the present series, we have used a flap from the same finger in 4 patients and the adjacent finger in 16 patients. These flaps are robust, but when used for the same finger, there is likely a chance of obstruction and cause venous congestion. The advantage of using a homo-digital flap is that it avoids scarring and immobilization of the other finger or other parts of the body¹¹. Many of the homo-digital flaps are palmar flaps, which bring in a better functional

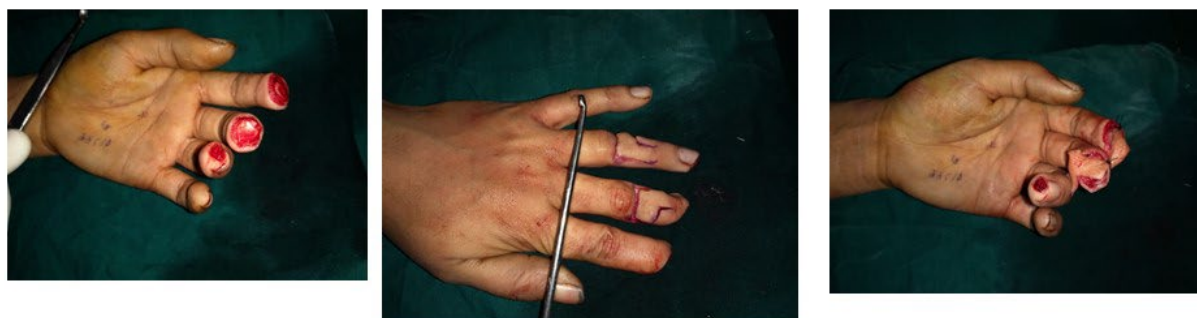

Figure 4: Hetero-digital Flag flap was used to cover index and middle finger tips.

and aesthetic result. The flag flaps are dorsal skin flaps that do not give an aesthetic result as good as the palmar flaps.

The present flap is based distally near the distal interphalangeal joint or the proximal interphalangeal joint. Conventional dorsal flag flap has been based proximally^{12,13}. The dorsal vein is recommended to be included to decrease venous congestion. Flag flaps are recommended with a twist of less than 90 degrees¹². However, the chances of venous problems are more when used on the same fingers because of the need for rotation of around 180 degrees. The present flap with a narrow base helps in achieving a comfortable position. This also helps in decreasing the tension on the flap and easier flap division. The length of the pole was kept to one-third of the length of the phalanx was adequate to improve the movement of the flap and keep the fingers in a comfortable position. The width of the flap was sufficient for adequate vascularity. The digital vessels run on either side of the finger giving lateral branches. The branches communicate with each other while arborizing on the dorsum of the fingers. The flap is based distally on the perforators from the digital vessels and the communication between the two digital vessels and the dorsal communicating branches from palmar digital vessels^{2,14}. The conventional flag flap is contraindicated in the absence of either of the digital vessels¹².

Homo-digital local flaps are used to cover small fingertip defects and small defects of the dorsum and palmar wounds. The advantages are no bulky dressing, we are not trespassing the adjacent fingers, post-operative immobilization and position are comfortable. Axial pattern homo-digital flaps based distally sacrifice the digital neurovascular bundle on one side^{15,16}. The flap cannot be used if the contralateral neurovascular bundle is injured or insufficient and is more radical. In the present series,

we had 4 patients who were covered with homo-digital flag flaps. The flap was rotated between 90-180 degrees. We lost one of the four flaps due to venous congestion. However, the flap was debrided after 10 days; we were able to cover the wound with a skin graft. This was possible probably because of the crane principle. With the homo-digital flag flap, we observed that the pole was wide enough as not to sustain 180 degrees of twist.

Four patients developed superficial ulcers, before 2 months. The patient developed an ulcer due to inadequate protective sensation. These patients regain protective sensation eventually¹⁷. The skin graft used on the donor site may cause a restriction in movement due to secondary contraction. The use of thick split-thickness graft, anti-scar measures, and physiotherapy, we had no problems of scar contractures and stiffness similar to other studies^{18,19}.

CONCLUSION

The flag flap can be used to cover small defects; the flap needs to be used with caution for homo-digital use. The recipient site would be aesthetically suboptimal compared to the palmar flaps. It is an insensate flap; however, adequate sensation develops over a period.

ACKNOWLEDGEMENTS

No financial support was received.

CONFLICTS OF INTEREST

Non- declared.

REFERENCES

- 1- Rehim SA, Chung KC. Local flaps of the hand. *Hand Clin.* 2014;**30**(2):137-v. doi:10.1016/j.hcl.2013.12.004.

- 2- Karthikeyan G, Renganathan G, Subashini R. Versatility and Modifications of the Cross-finger Flap in Hand Reconstruction. *Int J Sci Stud* 2017;**5(6)**:35-46.
- 3- Jiao H, Ding X, Liu Y, Zhang H, Cao X. Clinical experience of multiple flaps for the reconstruction of dorsal digital defects. *Int J Clin Exp Med* 2015;**8(10)**:18058-18065.
- 4- Cronin TD. The cross finger flap: a new method of repair. *Am Surg* 1951;**17(5)**:419-25.
- 5- Gurdin M, Pangman Wj. The repair of surface defects of fingers by trans-digital flaps. *Plast Reconstr Surg* 1950;**5(4)**:368-71.
doi: 10.1097/00006534-195004000-00011.
- 6- Patil RK, Chavre S. Distally based cross-finger flaps for amputation stumps in avulsion amputations. *Indian J Plast Surg* 2012;**45(3)**:504-511. doi:10.4103/0970-0358.105961
- 7- Thatte RL. Deepithelialised turnover flaps. *Plast Reconstr Surg* 1989;**84**:172-10.
- 8- Kumaraswamy mohan kumar, Smitha Segu. Cross finger adipofascial flap- is it a aesthetically better variant? *J Clin Diagn Res* 2013;**7(11)**: 2527-2529.
- 9- Lee LP, Lau PY, Chan CW. A simple and efficient treatment for fingertip injuries. *J Hand Surg Br* 1995;**20(1)**:63-71. doi: 10.1016/s0266-7681(05)80019-1.
- 10- Ratnakar Sharma, Akashdeep Singh, Ravinder Singh. Management of fingertip injuries. *JK Sci* 2015;**17(3)**:127-130.
- 11- Elliot D. Homodigital reconstruction of the digits: the perspective of one unit. *Indian J Plast Surg* 2003;**36(2)**:106-119.
- 12- F Islein, G Prdet. Flag skin flap to the finger. Upper extremities. In: Berish Strauch, Luis o Vasconez, Elizabeth J Hall-Findlay. *Grabb's encyclopedia of flaps*. 2nd ed. Philadelphia, New York: Lippincott-Raven; 1998. pp 860-863.
- 13- Mohieb Mustak, Aravind L Rao. Review of cross finger flaps- indications and modifications. *IJSR* 2017;**6(3)**: 2299-2303.
- 14- Keramidas E, Rodopoulou S, Metaxotos N, Panagiotou P, Iconomou T, Ioannovich J. Reverse dorsal digital and intercommissural flaps used for digital reconstruction. *Br J Plast Surg* 2004;**57(1)**:61-5. doi: 10.1016/j.bjps.2003.10.010.
- 15- Narayanamurthy Sundaramurthy, Surya Rao Venkata Mahipathy, Alagar Raja Durairaj. Why borrow from Peter when Paul can afford it? Reverse homodigital artery flap for fingertip reconstruction. *Indian J Plast Surg* 2017;**50(2)**:187-192.
- 16- Santos TPSD, Oliveira MT, Angelini LC. Retrospective study to evaluate the treatment of digital pulp lesions using a homodigital flap. *Rev Bras Ortop* 2018;**53(2)**:200-207. doi: 10.1016/j.rboe.2017.01.011.
- 17- GanchiPA, Lee WP. Fingertip reconstruction in hand and upper extremity. In: Mathes SJ, Hentz VR, *Plastic Surgery*. 2nd ed. Vol. 7. Philadelphia: Saunders (Elsevier); 2006; pp.154-70.
- 18- Paterson P, Titley OG, Nancarrow JD. Donor finger morbidity in cross-finger flaps. *Injury* 2000;**31(4)**:215-8. doi: 10.1016/s0020-1383(99)00205-3.
- 19- F Rabarin, Y Saint Cast, J Jeudy, PA Fouque, B cesari, N Bigorre, A Petit, G Raimbeau. Cross finger flap for reconstruction of finger tip amputations: long term results. *Ortho & Traumatology: Surgery & research* 2016;**102S**:225-228.