

# Techniques to Enhance Survival of Auricular Composite Graft in Reconstruction of Skin Defects of the Nasal Ala and Nasal Sidewall: A Case Report

Vasileios Efthymiou <sup>1</sup>, Alexandros Georgolios <sup>2</sup>

1. Department of Otolaryngology-Head and Neck Surgery Massachusetts Eye and Ear, Boston, Massachusetts, USA
2. Poplar Bluff Regional Medical Center, Poplar Bluff, Missouri, USA

## ABSTRACT

The auricular composite graft consists of a free tissue graft containing part of the auricular cartilage attached to its overlying skin. The survival of the auricular composite graft depends primarily on its size, and a graft diameter of 1- 2 cm has been previously reported as the critical cut-off size. The auricular composite graft is a reliable option for the reconstruction of skin defects of the nasal sidewall and the nasal ala, and its survival rates can be enhanced with the utilization of specific surgical techniques. These include increasing the contact surface with skin de-epithelization/ perichondrial underlay in the surgical bed, injection of autologous platelet-rich plasma, and non-strangulating nasal sidewall splinting. Here, we report a 64-year-old man with a skin lesion in the right nasal ala who underwent Mohs micrographic surgery. The lesion was reconstructed with the use of composite auricular skin graft.

## KEYWORDS

Composite auricular graft, nasal skin defects, nasal skin reconstruction

## Please cite this paper as:

Efthymiou V, Georgolios A. Techniques to Enhance Survival of Auricular Composite Graft in Reconstruction of Skin Defects of the Nasal Ala and Nasal Sidewall: A Case Report. *World J Plast Surg.* 2022;11(3):84-88. doi: 10.52547/wjps.11.3.84

## INTRODUCTION

The auricular composite graft consists of a free tissue graft containing part of the auricular cartilage attached to its overlying skin. The use of auricular composite grafts in nasal reconstruction is well established in the literature. It includes the advantages of a one-stage procedure and limited mobilization and rearrangement of surrounding soft tissues <sup>1-3</sup>. Conversely, as it relies on imbibition for initial taking to the surgical bed, its increased thickness and the presence of avascular cartilage may compromise its survival potential. It also creates more significant morbidity in the harvesting site <sup>4-5</sup>, when compared to the full thickness skin or the free auricular cartilage graft.

## CASE PRESENTATION

A 64-year-old male was referred to Poplar Bluff Regional Medical Center with the depicted skin lesion (Figure 1) of the right nasal ala. The lesion was present for approximately one year, gradually enlarging.

## \*Corresponding Author:

Vasileios Efthymiou

Department of Otolaryngology-Head and Neck Surgery Massachusetts Eye and Ear, Boston, Massachusetts, USA

Tel.: +16174871689

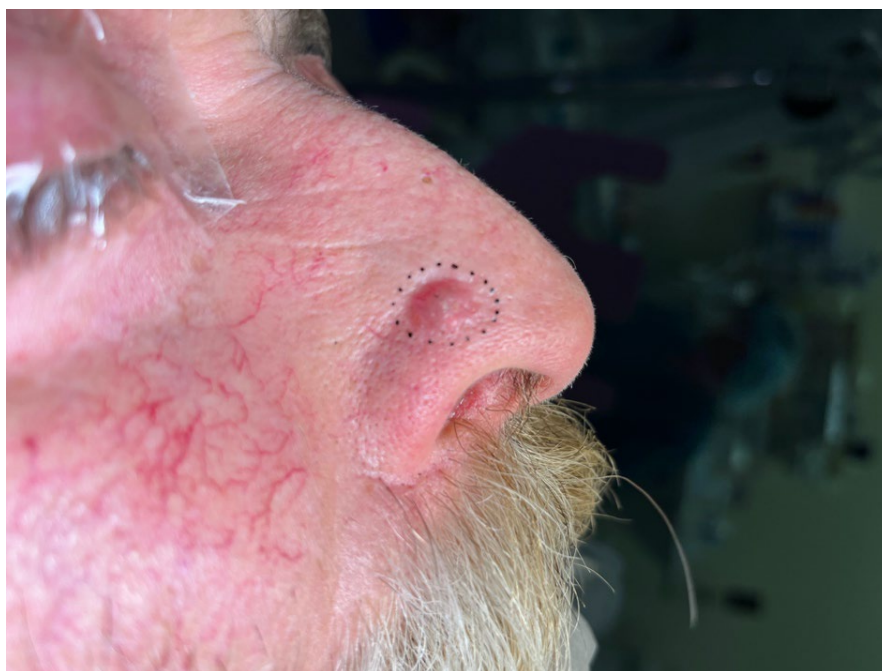Email: [efthibill@gmail.com](mailto:efthibill@gmail.com)

Received: 2022/06/06

Accepted: 2022/09/19



This work is licensed under a Creative Commons Attribution-NonCommercial 4.0 International license (<https://creativecommons.org/licenses/by-nc/4.0/>). Non-commercial uses of the work are permitted, provided the original work is properly cited.



**Figure 1:** 64-year-old patient with right nasal ala lesion

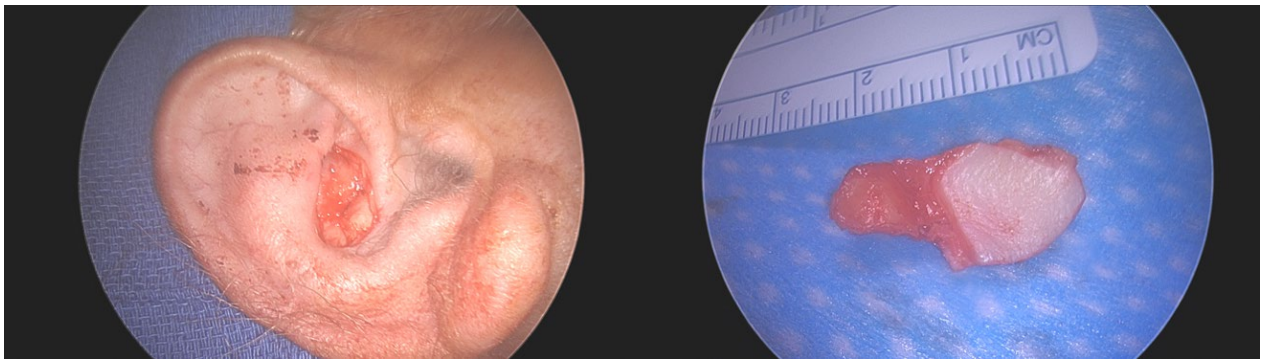
He denied local pain or bleeding. He reported a history of sun exposure but has no history of skin cancer or other lesions. He had a history of multiple medical comorbidities, including chronic obstructive pulmonary disease, hypertension and hypercholesterolemia, stage 4 chronic kidney disease that was managed medically, without regular hemodialysis, and peripheral arterial occlusive vascular disease. He admitted using tobacco, and his daily medications included aspirin, inhalers, and montelukast for his chronic obstructive pulmonary disease, amlodipine, and atorvastatin. He had a history of multiple nasal fractures in the past and moderate nasal airway obstruction, which was not his primary concern.

On physical examination, except for the depicted skin lesion, there was severe C-shaped septal deviation with severe obstruction of the right nasal cavity. The nasal sidewall was weak on palpation, and it was associated with a cephalic orientation of the lower lateral cartilage. The modified Cottle maneuver was positive bilaterally, and the nasal sidewall collapse was more pronounced on the right side. The preoperative Nasal Obstruction, Septoplasty Evaluation questionnaire revealed only moderate level obstruction (NOSE scale 9/20), which was in line with his only modest complaints of nasal breathing.

## CONSENT FORM

Informed consent was obtained by the patient for taking releasing photographs in accordance with protected health information requirements.

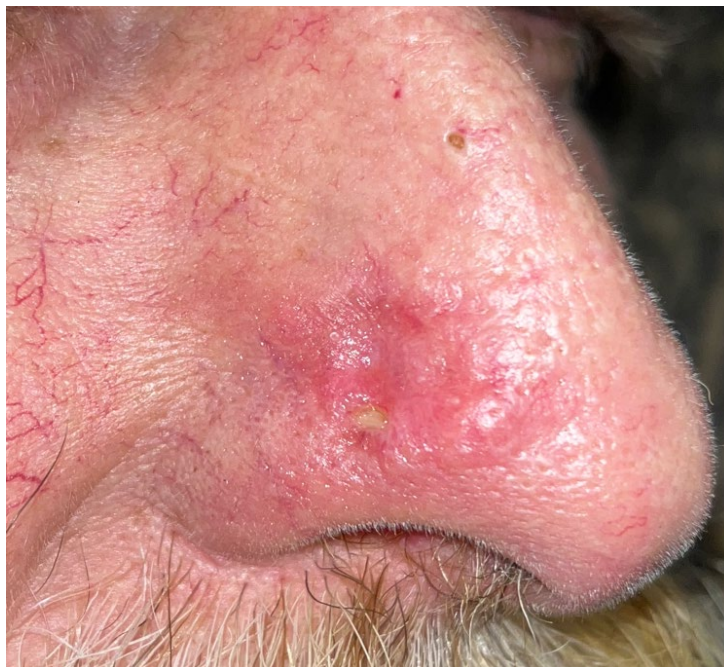The patient was offered a referral for Mohs micrographic surgery, but he elected to have the procedure under general anesthesia. After risk stratification and optimization by his primary care, we proceeded to the operating room and excised the lesion. The intraoperative frozen section was consistent with basal cell carcinoma, margins negative, and was proceeded with reconstruction. The composite auricular graft was harvested from the right auricle using the concha cymba and a part of the concha cavum. On the posterior aspect of the graft, care was taken to dissect in the perichondrial plane to allow the entirety of the perichondrium to the graft (Figure 2a). The graft was soaked for ten minutes in autologous protein-rich plasma (see below- discussion). The graft was de-epithelialized carefully with sharp dissection in the half of its surface, sparing as possible the perichondrium. Then, a pocket was created laterally to the surgical defect with converse rhinoplasty scissors to accommodate the de-epithelialized part of the graft, while the part with the overlying skin was carefully used to cover the surgical defect. Multiple interrupted sutures 5-0



2a.

2b.

**Figure 2a:** Posterior aspect of the auricular composite graft **2b.** Composite auricular skin graft along with the de-epithelized part



**Figure 3:** Patient at postoperative week 8. As is shown in the figure, there was excellent healing and no signs of graft rejection.

plain were used every 3 mm to suture the graft to the surrounding skin. A “sandwich” silicone splint was secured in the nasal sidewall with a 5-0 nylon full-thickness suture. The skin containing part of the composite graft was left uncovered for monitoring. Finally, the PRP was injected into the surrounding skin with a 25-gauge needle. The auricular skin defect was repaired with a full-thickness skin graft obtained from the skin of the right neck (Figure 2b).

## DISCUSSION

The anatomic subunits of the nasal ala and nasal sidewall demonstrate a complex structure consisting

of three different components: the inner mucous membrane, the cartilage, and the covering skin<sup>6</sup>. They both contain the most critical areas of the nasal airway, the internal and the external nasal valve. Due to this anatomic complexity and physiologic role, reconstructing skin defects in these anatomic units can be very challenging. Depending upon the extent of the defect and the exact anatomic site, a local flap, full-thickness skin graft, composite graft, or interpolated flap can be used to reconstruct these challenging defects.

The auricular composite graft is a well-established option and has been previously described in the reconstruction of the nasal vestibule in functional

rhinoplasty<sup>7</sup> as well as the nasal ala and columella skin defects<sup>8</sup>. In our opinion, the auricular composite graft, with its robust structural support, can also be a reliable option for the reconstruction of skin defects of the nasal sidewall. This anatomic subunit corresponds to the area of the internal nasal valve. Patients with pre-existing weakness of the sidewall who need more structural support are the ideal candidates. Furthermore, superiorly lying alar lesions frequently require excision of the nasal sidewall skin to achieve clear margins, and reconstruction is needed for both nasal subunits.

Chen et al., in their nasal ala reconstruction algorithm, propose the auricular composite graft for intermediate-depth defects where the internal lining is present, as it can provide cartilage support and external skin coverage with relative ease and minimal donor site morbidity<sup>9</sup>. In our opinion, the use of the auricular composite graft can be extended to superficial skin defects of the nasal ala/sidewall when the patient has a pre-existing weak nasal sidewall or nasal valve insufficiency. Although our patient did not report severe nasal airway obstruction (NAO), he did recall a history of past nasal trauma. The preoperative physical examination revealed severe septal deviation obstructing the right nasal cavity and impacting the right internal nasal valve. On palpation of the nasal sidewall, there was a significant weakness of the nasal ala and sidewall associated with the cephalic orientation of the lower lateral cartilages. This clinical presentation was considered pre-morbid, although the patient did not express complaints of NAO in the initial encounter. The additional cartilaginous structural support provided by the auricular composite graft will counteract the healing retraction forces in the critical area of the internal nasal valve.

The survival of the auricular composite graft depends primarily on its size<sup>11</sup>. A graft diameter of 2 cm has been previously reported as the critical cut-off size in the literature. Other authors are more conservative<sup>2</sup>. Chen et al. reviewed the relative literature and theorized that without technical and postoperative modifications, auricular composite grafting is likely to be reliable only for defects in the range of 1 to 1.5 cm<sup>9</sup>. Harbison et al. reviewed the perioperative modifications that can increase the survival of auricular composite graft: they report beneficial effects of perioperative and postoperative

corticosteroid administration and mention hyperbaric oxygen therapy as a promising modality<sup>10</sup>.

Although no studies are present in the literature, we find that increasing the hidden surface of an auricular composite graft may increase its survival potential. The graft is harvested on the medial surface at the perichondrial plane, avoiding cartilage exposure as possible. The size of the composite auricular graft is harvested at the double approximate size of the under reconstruction defect, and the redundant skin surface is de-epithelialized, allowing intact the underlying perichondrium. Subsequently, a pocket is created laterally to the skin defect to accommodate the de-epithelialized part of the composite graft. The graft is sutured to the surrounding skin with multiple interrupted sutures. A "sandwich" silicon sidewall splint is secured with a 5-0 full-thickness nylon suture over the covered part of the graft, allowing exposure of the skin graft for postoperative monitoring. The splint is removed on postoperative day 5.

Additionally, we favor the intraoperative use of autologous protein-rich plasma (PRP). This practice is supported by extensive emerging literature showing that topical application of PRP enhances the rate of graft take in split-thickness skin grafts<sup>11-12</sup> and multiple animal studies supporting its use in composite grafts<sup>13-14</sup>. Ten ml of a patient's blood is centrifuged at 3000 rpm for 10 minutes, and the platelet-rich layer is withdrawn and maintained on the surgical table. This is used to soak the harvested grafts for at least 10 minutes and finally injected with a 25-gauge needle in the skin surrounding the recipient bed after completion of the procedure. Finally, postoperative hyperbaric oxygen treatment is always considered, but insurance coverage issues, the expense of treatment, and the lack of an established treatment protocol hinder its extensive use. The patient demonstrated excellent healing during the eight-week postoperative follow-up (Figure 3).

## CONCLUSION

The composite auricular graft can be used for the reconstruction of the nasal sidewall and nasal ala, along with good healing results and favorable outcomes.

## ACKNOWLEDGEMENTS

No funding was received for this study.

## CONFLICT OF INTEREST

The authors declare that there is no conflict of interest.

## REFERENCES

1. Scheithauer MO, Rotter N, Lindemann J, Schulz M, Rettinger G, Veit JA. The auricle's cavum conchae composite graft in nasal reconstruction. *Am J Rhinol Allergy* 2013;**27**(2):e53-7. doi: 10.2500/ajra.2013.27.3883.
2. Teltzrow T, Arens A, Schwipper V. One-stage reconstruction of nasal defects: evaluation of the use of modified auricular composite grafts. *Facial Plast Surg* 2011;**27**(3):243-8. doi: 10.1055/s-0031-1275773.
3. Pépin ME, Rizis D, Servant JM, Danino AM. Contralateral auricular composite graft for ear reconstruction. *Dermatol Surg* 2014;**40**(3):340-3. doi: 10.1111/dsu.12421.
4. Kridel RWH, Delaney SW, Prze C. Primary Closure Technique for Conchal Auricular Composite Graft Donor Site. *JAMA Facial Plast Surg* 2018;**20**(4):328-9. doi: 10.1001/jamafacial.2018.0379.
5. Peach AH, Stretch JR. Improved selection and management of the auricular composite graft donor site. *Br J Plast Surg* 2004;**57**(8):797-9. doi: 10.1016/j.bjps.2004.06.013.
6. Driscoll BP, Baker SR. Reconstruction of nasal alar defects. *Arch Facial Plast Surg* 2001;**3**(2):91-9. doi: 10.1001/archfaci.3.2.91.
7. Tardy ME, Jr., Toriumi D. Alar retraction: composite graft correction. *Facial Plast Surg* 1989;**6**(2):101-7. doi: 10.1055/s-2008-1064716.
8. Son D, Kwak M, Yun S, Yeo H, Kim J, Han K. Large auricular chondrocutaneous composite graft for nasal alar and columellar reconstruction. *Arch Plast Surg* 2012;**39**(4):323-8. doi: 10.5999/aps.2012.39.4.323.
9. Chen C, Patel R, Chi J. Comprehensive Algorithm for Nasal Ala Reconstruction: Utility of the Auricular Composite Graft. *Surg J (N Y)* 2018;**4**(2):e55-e61. doi: 10.1055/s-0038-1639581.
10. Harbison JM, Kriet JD, Humphrey CD. Improving outcomes for composite grafts in nasal reconstruction. *Curr Opin Otolaryngol Head Neck Surg* 2012;**20**(4):267-73. doi: 10.1097/MOO.0b013e328355b1f2.
11. Chen J, Wan Y, Lin Y, Jiang H. The application of platelet-rich plasma for skin graft enrichment: A meta-analysis. *Int Wound J* 2020;**17**(6):1650-8. doi: 10.1111/iwj.13445.
12. Tyagi A, Gupta A, Martires Iii VI, Romo M, Garg I, Tapia D, et al. Efficacy of Platelet-Rich Plasma in Reduction of Post-Operative Split-Thickness Skin Graft Loss and Hematoma Formation: A Meta-Analysis. *Cureus* 2021;**13**(5):e15160. doi: 10.7759/cureus.15160.
13. Sevim KZ, Yazar M, Irmak F, Tekkeşin MS, Yildiz K, Sirvan SS. Use of platelet-rich plasma solution applied with composite chondrocutaneous graft technique: an experimental study in rabbit model. *J Oral Maxillofac Surg* 2014;**72**(7):1407-19. doi: 10.1016/j.joms.2014.01.001.
14. Choi HN, Han YS, Kim SR, Kim HK, Kim H, Park JH. The effect of platelet-rich plasma on survival of the composite graft and the proper time of injection in a rabbit ear composite graft model. *Arch Plast Surg* 2014;**41**(6):647-53. doi: 10.5999/aps.2014.41.6.647.