

Use of Leukocyte-Platelet-Rich Fibrin in Conservative Management of Odontogenic Keratocyst: A Case Report

Parsa Behnia ¹, Mohsen Malekigorji ¹, Reza Tabrizi ¹, Mehrdad Dehghanpour ^{1*}, Arash Ghaffarpasand ¹

1. Department of Oral and Maxillofacial Surgery, School of dentistry, Shahid Beheshti University of Medical Sciences, Tehran, Iran.

ABSTRACT

A 29-year-old female patient was referred to the Department of Oral and Maxillofacial Surgery in Taleghani Hospital of Shahid Beheshti University of Medical Science, Tehran, Iran, in 2019, complaining of increased volume and pain in the posterior mandibular region. Cone-beam computed tomography and multislice computed tomography were performed, and an incisional biopsy was done. The histopathologic examination confirmed the diagnosis of Odontogenic Keratocyst (OKC). Surgical treatment was performed with marsupialization. After a year of follow-up, the resultant small-sized cyst was curetted, and Leukocyte-Platelet-Rich Fibrin (LPRF) was placed in the bony depression. The significant healing of the lesion was noted on regular follow-up visits with complete resolution at 15 months. This report showed that the application of LPRF might accelerate the healing of soft tissues and bone regeneration with no inhibitory effect on the natural healing process.

KEYWORDS

Bone regeneration; Platelet-Rich Fibrin; Growth factors; Odontogenic keratocyst; Mandible

Please cite this paper as:

Behnia P, Malekigorji M, Tabrizi R, Dehghanpour M, Ghaffarpasand A. Use of Leukocyte-Platelet-Rich Fibrin in Conservative Management of Odontogenic Keratocyst: A Case Report. *World J Plast Surg.* 2022;11(3):98-102. doi: 10.52547/wjps.11.3.98

INTRODUCTION

Odontogenic keratocyst (OKC) is a benign intraosseous lesion of the jaws with destructive and locally invasive behavior, high recurrence rate, and specific histological aspects. Although first described in 1956, its etiopathogenesis is not yet entirely clear. There are two accepted theories of OKC origin, including the remnants of the dental lamina and proliferation of cells from the basal layer of the oral epithelium into the mandible or maxilla ¹.

The OKCs are asymptomatic lesions; however, occasionally, some symptoms, such as swelling, drainage, or pain, can be shown in severe cases. Small OKCs, usually asymptomatic, are often discovered only during radiographic examination ². On the other hand, computed tomography allows for the accurate assessment of the true extent of the lesion and its relationship to important anatomic structures. This lesion tends to grow in an anteroposterior direction within the medullary cavity of the bone, without causing obvious bone expansion ³. The OKC has a thin, friable

*Corresponding Author:

Mehrdad Dehghanpour

OMFS Department, Shahid Beheshti Dental School, Velenjak, Tehran, Iran

Tel.: +98912 522 4419

Email: mdmehrdad26@yahoo.com

Received: 2022/07/12

Accepted: 2022/10/12



This work is licensed under a Creative Commons Attribution-NonCommercial 4.0 International license (<https://creativecommons.org/licenses/by-nc/4.0/>). Non-commercial uses of the work are permitted, provided the original work is properly cited.

capsule rich in polysaccharides. The cystic lumen might be filled with a cheesy material which, on microscopic examination, consists of keratinaceous debris. The cystic epithelium is usually 5-8 cell layers thick, containing basophilic nuclei with a palisaded basal layer with a flat epithelial-mesenchymal junction¹. Different surgical techniques are used to treat keratocysts depending on their size and the affected region including enucleation and curettage, marsupialization, or even resection⁴. The patients can have a better quality of life by using a more conservative technique and reducing the time of treatment. To date, several methods have been applied to enhance the postoperative healing process and decrease inflammation⁵. Platelets can be used as an adjunct to stimulate the regenerative capacity of the periosteum and enhance bone and soft tissue healing. Platelet activation results in the formation of platelet plugs and subsequent secretion of bioactive proteins, necessary for tissue regeneration and repair; therefore, it can be used as a valuable therapeutic adjunct in medicine and dentistry⁵.

The presence of high concentrations of leukocytes in leukocyte-platelet-rich fibrin (LPRF) plays a significant role in the enhanced release of some crucial growth factors, such as transforming growth factor-beta 1. The LPRF contains concentrated growth factors, such as platelet-derived growth factor, transforming growth factor-beta, and insulin-like growth factor 1, which enrich the blood clot formation and subsequently enhance wound healing and bone regeneration with no inhibitory effect on the natural healing process⁶.

Here we report a clinical case of an infected OKC addressing its clinical, radiographic, and histological aspects, focusing on the use of LPRF in the biological healing behavior of this type of odontogenic cyst.

CASE PRESENTATION

A 29-year-old female patient was referred to the Taleghani Hospital of Shahid Beheshti University of Medical Sciences, Tehran, Iran, in 2019, presenting with a large swelling and pain on the left side of the face and limited mouth opening (Figure 1). The patient reported that the swelling started a week before, following which she had referred to a local dentist, and panoramic radiography was prescribed. The patient was then referred to a hospital to be

assessed by an oral and maxillofacial surgeon. On arrival to the hospital, the patient was initially admitted to the emergency department based on the clinical signs of swelling, pain, and marked reduction of mouth opening, along with mild odynophagia. Dysphagia and dyspnea were not present, and the temperature was 37.2 °C. Medical history revealed no previous medical conditions, and the patient did not use any specific medication.

Extra-orally an ill-defined swelling measured approximately 10 × 10 cm was present on the left side of the face, extending from the buccal region to the lower border of the mandible. No erythema or pus draining sinus tract or fistula was observed. The swelling was firm with marked tenderness. On intraoral examination, a vestibular swelling measured approximately 2 × 3 cm was evident on the distal aspect of the lower left wisdom tooth extending to the ascending ramus. Erythema and fluctuation were present; nevertheless, no pus or fistula was observed.

The panoramic image showed a well-defined unilocular osteolytic cystic lesion extending from the distal aspect of the lower left third molar posterosuperiorly to the ascending ramus, reaching close to the mandibular condyle (Figure 2). The patient was admitted to the Oral and Maxillofacial Surgery Ward for the management of the acute

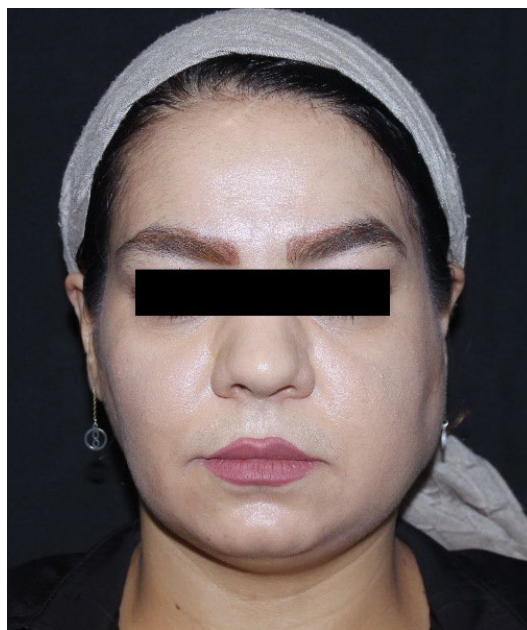

Figure 1: Extraoral photograph of the patient with a swelling on the left side of the face.

inflammatory process provisionally diagnosed as an odontogenic infection caused by a mandibular pathologic lesion. The patient received intravenous serum therapy, parenteral antibiotics, and analgesics and was subjected to further radiographic assessments. The radiographic assessments included cone-beam computed tomography (CBCT) for the evaluation of the intraosseous cystic lesion, conventional tomography with soft-tissue contrast for the evaluation of surrounding tissues invasion, and magnetic resonance imaging for the further evaluation of fascial spaces involvement.

Informed consent was obtained from the patient. The authors read and abided by the Helsinki Declaration.

The incisional biopsy of the lesion was performed in the operating room under general anesthesia, and the fascial space infection was drained with intraoral access simultaneously. The biopsy included the specimens of tan-brown tissues of cyst epithelium, along with the surrounding tissues of buccal and masseteric fibromuscular tissues, to rule out possible soft tissue pathology.

In surgery, a cheesy keratinous substance, along with serosanguinous fluid, was collected, which was suggestive of an OKC. The histopathologic examination confirmed the diagnosis of OKC. The cyst was subjected to marsupialization two weeks after biopsy session, and an obturator was placed in the cyst window. The patient was followed every 3 months, and serial orthopantomograms were taken 6, 9, and 12 months postoperatively. Moreover, 12 months after marsupialization, all the clinical signs, and symptoms of infection were completely resolved. She was admitted to a day-care setting for the definitive treatment of enucleation, curettage, and peripheral ostectomy of the cyst, which was then substantially reduced in size. Simultaneously, LPRF was prepared. The LPRF was then carefully placed in the bony depression, and the site was primarily closed. The patient was followed for a further 6 months, and a final orthopantomograms was taken and evaluated. Healing was notably significant; the bone regenerated properly, and no signs of recurrence were evident in follow-up (Figure 3).

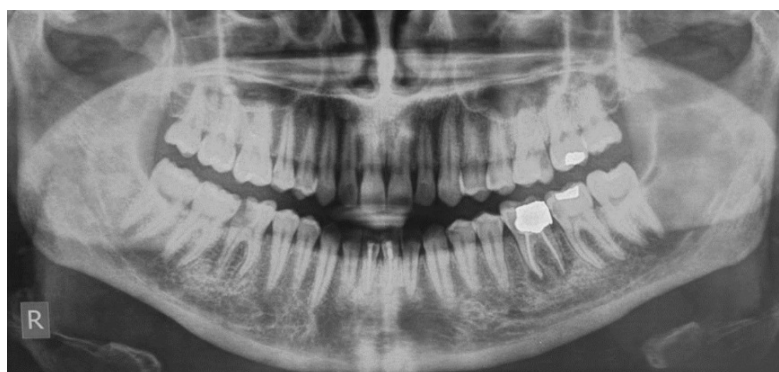


Figure 2: First Panoramic image preoperatively.

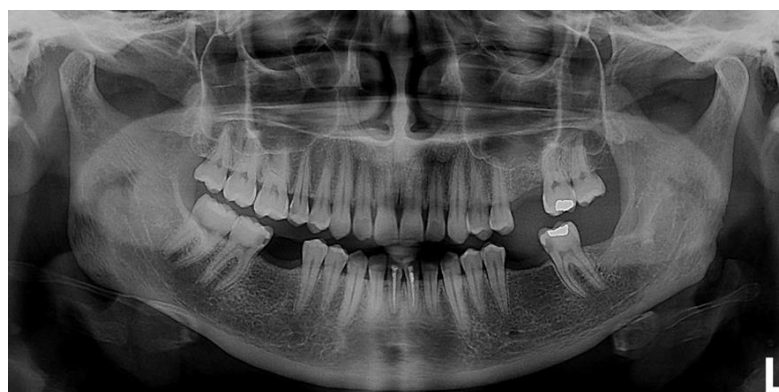

Figure 3: Final panoramic image.

DISCUSSION

Developmental odontogenic cysts arise from the epithelial remnants of the different stages of odontogenesis, whose pathogenesis is not associated with inflammatory stimuli. They include seven different lesions, and the two most common cysts are the dentigerous cyst and the keratinizing odontogenic cyst, also known as keratocyst. The OKCs have an aggressive clinical behavior and a high recurrence rate, unlike other odontogenic cysts¹.

The OKCs can be treated by two different techniques, namely marsupialization/decompression and enucleation. Marsupialization relieves pressure within the cyst through the opening, maintaining continuity between the cyst and the oral cavity⁴. Previous studies concluded that cystectomy is necessary after marsupialization to reduce the recurrence rate, and they demonstrated a lower recurrence rate in decompression, followed by enucleation, than pure enucleation^{3,7}.

Based on the above-mentioned studies, when the lesion does not affect any important anatomical structure, and its removal would not pose aesthetic and/or functional risks, enucleation is the chosen technique. Nevertheless, marsupialization should be used when the lesion affects different anatomical elements. In the present case, marsupialization was chosen since the complete removal of the cyst (i.e., the partial resection of the left posterior mandible with the ramus up to the condyle) posed loss of function and ipsilateral neurosensory structures.

Platelet-rich plasma (PRP) was first introduced to dentistry in 1998 to be combined with autogenous bone grafts to expedite bone maturation and resulted in higher bone density. This retrospective review demonstrated that using a low-cost autogenous material, PRF, can enhance healing/clot retention and greatly decrease the postoperative clinical time⁸.

The LPRF, similar to PRP products, is a mixture of various growth factors, cytokines, and enzymes, which might have overlapping biological effects, and the exact mechanism of action of each ingredient is still unclear. Many of these elements might demonstrate anti-inflammatory effects, responsible for the increased tissue healing capacity. Since then, numerous studies have evaluated the use of LPRF and PRF to facilitate implant placement and periapical surgeries, revascularization procedures,

perforation repair, and bone regeneration in oral and maxillofacial region^{5,6,8}.

There are controversies over the LPRF effect on postoperative pain, swelling, bleeding, and postoperative discomfort. Radiographic examinations revealed an early and significantly increased radiographic density at the PRP-treated sockets in comparison to the ipsilateral not-PRP treated sites, demonstrating the effect of PRP on the early phase of bone healing. The aforementioned results conform to the findings of the present case report after 6 months of follow-up^{9,10}. Previous studies have shown that complete bone healing and complete bone formation of the remaining defect almost occurs after 1 year but in our study, using LPRF accelerate the bone healing process and complete bone formation occurred in 6 months in the approximately same size bone defect³.

Considering the lack of available evidence on the effect of LPRF in the treatment of odontogenic cysts, the results of the present case report are not comparable to the findings of other studies in this field. Therefore, to the best of our knowledge, this case has been the first application of a plasma-derived factor (i.e., LPRF) in the treatment of an OKC. The major limitation of this study was the limited follow-up time following the use of LPRF. Furthermore, the inconvenience related to the need for venipuncture and blood-drawing procedure for the preparation of LPRF should be considered before the clinical application of this method.

A major strength of this study was that it showed the possibility of application of autologous blood-derived LPRF in the healing process of a bony lesion caused by a locally invasive infected odontogenic cyst.

CONCLUSION

The application of LPRF might accelerate the healing of soft tissues and bone regeneration with no inhibitory effect on the natural healing process.

ACKNOWLEDGMENTS

Not applicable.

CONFLICT OF INTEREST

Non-declared.

REFERENCES

1. Rajendra Santosh AB. Odontogenic Cysts. *Dent Clin North Am* 2020 Jan;**64**(1):105-119. doi: [10.1016/j.cden.2019.08.002](https://doi.org/10.1016/j.cden.2019.08.002)
2. Bilodeau EA, Collins BM. Odontogenic Cysts and Neoplasms. *Surg Pathol Clin* 2017 Mar;**10**(1):177-222. doi: [10.1016/j.path.2016.10.006](https://doi.org/10.1016/j.path.2016.10.006)
3. Deboni MC, Brozowski MA, Traina AA, Acay RR, Naclério-Homem Mda G. Surgical management of dentigerous cyst and keratocystic odontogenic tumor in children: a conservative approach and 7-year follow-up. *J Appl Oral Sci* 2012 Mar-Apr;**20**(2):282-5. doi: [10.1590/s1678-77572012000200025](https://doi.org/10.1590/s1678-77572012000200025).
4. Khan AA, Qahtani SA, Dawasaz AA, Saquib SA, Asif SM, Ishfaq M, et al. Management of an extensive odontogenic keratocyst: A rare case report with 10-year follow-up. *Medicine (Baltimore)* 2019 Dec;**98**(51):e17987. doi: [10.1097/MD.00000000000017987](https://doi.org/10.1097/MD.00000000000017987)
5. Schliephake H. Clinical efficacy of growth factors to enhance tissue repair in oral and maxillofacial reconstruction: A systematic review. *Clin Implant Dent Relat Res* 2015;**17**:247-73. doi: [10.1111/cid.12114](https://doi.org/10.1111/cid.12114)
6. Hatakeyama I, Marukawa E, Takahashi Y, Omura K. Effects of platelet-poor plasma, platelet-rich plasma, and platelet-rich fibrin on healing of extraction sockets with buccal dehiscence in dogs. *Tissue Eng Part A* 2014;**20**:874-82. doi: [10.1089/ten.TEA.2013.0058](https://doi.org/10.1089/ten.TEA.2013.0058)
7. Polak K, Jędrusik-Pawłowska M, Drozdowska B, Morawiec T. Odontogenic keratocyst of the mandible: A case report and literature review. *Dent Med Probl* 2019 Oct-Dec;**56**(4):433-436. doi: [10.17219/dmp/110682](https://doi.org/10.17219/dmp/110682)
8. Dragonas P, Katsaros T, Avila-Ortiz G, Chambrone L, Schiavo JH, Palaiologou A. Effects of leukocyte-platelet-rich fibrin (L-PRF) in different intraoral bone grafting procedures: a systematic review. *Int J Oral Maxillofac Surg* 2019 Feb;**48**(2):250-262. doi: [10.1016/j.ijom.2018.06.003](https://doi.org/10.1016/j.ijom.2018.06.003)
9. Chou TM, Chang HP, Wang JC. Autologous platelet concentrates in maxillofacial regenerative therapy. *Kaohsiung J Med Sci* 2020 May;**36**(5):305-310. doi: [10.1002/kjm2.12192](https://doi.org/10.1002/kjm2.12192)
10. Albanese A, Licata ME, Polizzi B, Campisi G. Platelet-rich plasma (PRP) in dental and oral surgery: From the wound healing to bone regeneration. *Immun Ageing* 2013 Jun 13;**10**(1):23. doi: [10.1186/1742-4933-10-23](https://doi.org/10.1186/1742-4933-10-23)