

Two Forehead Flaps for Nasal Reconstruction of a Patient with Arhinia

Naser Mozafari¹, Seyed Esmail Hassanpour¹, Abdolreza Rouientan¹, Arian Karimi Rouzbahani², Golnaz Mahmoudvand², Hormoz Mahmoudvand^{3*}

1. MD Department of Plastic Surgery, School of Medicine, Panzdah-E Khordad Teaching Hospital, Shahid Beheshti University of Medical Sciences, Tehran, Iran
2. Medical student Research Committee, Lorestan University of Medical Sciences, Khorramabad, Iran
3. MD Department of Surgery, Faculty of Medicine, Lorestan University of Medical Sciences, Khorramabad, Iran

ABSTRACT

Complete or total arhinia, in which nasal soft tissue is absent, is an extremely rare disease. The embryological origin of the defect is thought to be the maldevelopment of paired nasal placodes. In this article, we introduce nasal reconstruction with two forehead flaps. The reconstruction was done with two forehead flaps in a 20-year-old male patient with arhinia. Using one frontal flap of the forehead as the inner layer and the other one as the outer layer. The postoperative care was uneventful. He was able to breathe through the nose. No chest pain or any difficulty was mentioned in daily activities. The principal advantage of this technique over previous techniques is that the operation is performed in two stages and at the end of the procedure the patient has the final shape of the nose and is able to breathe normally. Furthermore, this technique could be performed for all age groups.

KEYWORDS

Ahrinia; Congenital malformation; Nasal reconstruction

Please cite this paper as:

Mozafari N, Hassanpour SE, Rouientan A, Karimi Rouzbahani A, Mahmoudvand G, Mahmoudvand H. Two Forehead Flaps for Nasal Reconstruction of a Patient with Arhinia. *World J Plast Surg*. 2022;11(3):103-108. doi: 10.52547/wjps.11.3.103

INTRODUCTION

Congenital absence of nose, known as arhinia, is an exceedingly rare congenital malformation with less than 50 reported cases since 1931¹. Congenital arhinia is usually affiliated with other congenital abnormalities such as the ears, eyes, and palate. Owing to the absence of nose and nasal cavities, the patients may encounter difficulties with breathing and feeding².

EMBRYOLOGY

The development of the face and nose occurs during the 3rd to 10th weeks of pregnancy.

At first, the face consists of a frontal process, bilateral maxillary processes, and a pair of mandibular processes. In the 4th week of pregnancy, the nasal placodes which finally form the nasal swellings develop. Around the 5th week of pregnancy, invagination of these placodes on the underlying mesenchyme creates the nasal pits and the fusion of medial nasal swellings constructs the nasal septum. During the 6th week of gestation, the fusion of the maxillary and frontal processes creates the

*Corresponding Author:

Dr Hormoz Mahmoudvand

MD Department of Surgery,
Faculty of Medicine, Lorestan
University of Medical Sciences,
Khorramabad, Iran

Email: dr.mahmoudvand@gmail.com

Received: 2022/08/20

Accepted: 2022/10/28



This work is licensed under a Creative Commons Attribution-NonCommercial 4.0 International license (<https://creativecommons.org/licenses/by-nc/4.0/>). Non-commercial uses of the work are permitted, provided the original work is properly cited.

primitive palatal shelf, and posterior migration of the cells from the nasal pit creates the primitive nasal cavity³.

ETIOLOGY

Although the exact etiology of arhinia remains unknown, Treacher Collins syndrome and autosomal dominant inheritance with reduced penetrance have been detected in some cases^{4,5}. Besides, antenatal history of maternal gestational diabetes mellitus and polyhydramnios has been reported³.

PATHOPHYSIOLOGY

The exact pathophysiology of congenital arhinia is unclear, however, several causes such as defective growth of the medial and lateral nasal processes, overgrowth and early fusion of the nasal medial processes, and defective resorption of the nasal epithelial plugs have been suggested².

CASE DESCRIPTION

Our procedure was performed on a 20-year-old male patient who was born with no nose and corresponding airway channels. From 2010 to 2012 another team had decided to drill out the cavity to improve the patient's breathing. In 2010 under general anesthesia original tiny nasal canal (2 mm

diameter) was dilated by drilling in four stages to reach a bigger canal diameter of 15 mm and a stent was put into the canal. The canal was epithelialized and for prevention of restenosis a stent was placed in the canal (Figure 1).

ETHICS CONSIDERATION

The patient was assured that non-participation in the study would not prevent him from receiving routine care. He was assured that he would be free to withdraw from the cooperation at any time, so the principles of Ethics Medicine, The Helsinki Declaration, were observed. Written informed consent was obtained from the patient for publication of this case report and accompanying images. A copy of the written consent is available for review by the Editor-in-Chief of this journal on request.

In 2012 the patient presented to our center (Panzdah-e Khordad Hospital, Department of Plastic Surgery, Shahid Beheshti University of Medical Sciences, Tehran, Iran). He was a 20-year-old man who had almost complete arhinia with only a rudimentary concavity in the middle face. The eyes were moved laterally. Arch of the hard palate was slightly increased but the soft palate was normal. On physical examination, there was a hole with a diameter of 15 mm in the midface and no external structural units of the nose. Visual acuity

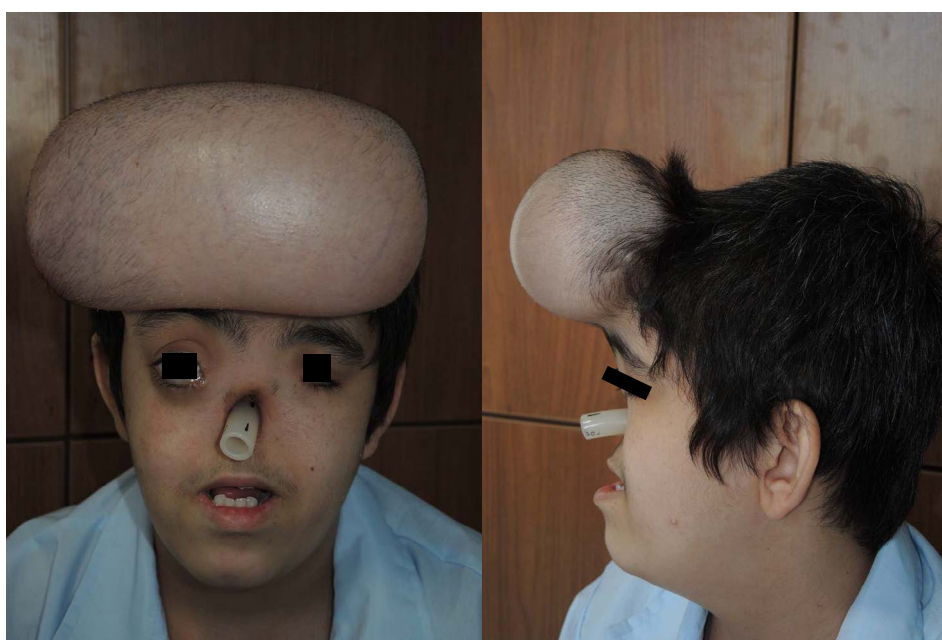

Figure 1: The patient with a 15 mm diameter stent in the nasal canal

in the right eye was 10/10 with normal anatomy. On the psychological assessment, he was self-conscious about his condition. On computed tomography (CT) scans, nasal bones were absent. The maxillary sinuses were present and connected with ethmoidal sinuses that were completely hypoplastic. Bone formation in the median sagittal fissure at the top of the hard palate's arch was present and there was a hole in the airway between the oropharynx and ambient space. The orbital cavity on either side was normal. The skull also seemed normal. In a three-dimensional CT scan, a hole was seen in the anterior part of the face. In the first stage of reconstructive surgery under general anesthesia, a rectangular tissue expander with an 8×12cm diameter (Mentor Corporation) was placed under the forehead skin for 5 months. It was inflated every week with 20-30

cc of normal saline until reaching the total capacity of 800 ccs (Figure 2).

In the second stage, two forehead flaps each with a pedicle diameter of 5 cm were designed on the expanded tissue of the forehead (Figure 3).

Before incision of skin flaps, by transillumination through the expanded forehead skin we became confident that each pedicle had a feeding artery (Figure 4). Then the markings were incised over to elevate flaps. The flap which was used to cover the future columella and the tip of a longitudinal skin strip was de-epithelialized on both sides (Figure 3). The other flap (reverse one) was used to cover the inside of the nose. Then the nasal stent was removed. Simultaneously a second team made a 4 cm incision on the right side of the chest wall over the seventh and eighth ribs to harvest a 6 cm block of rib bone

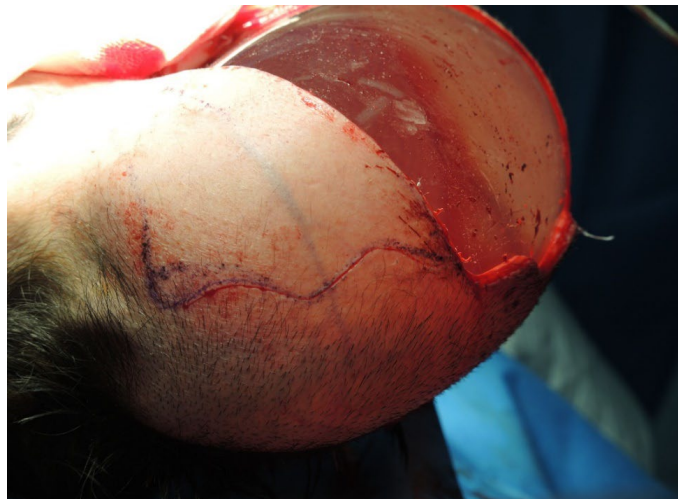

Figure 2: Patient after tissue expansion under forehead skin and reaching a total capacity of 800 cc

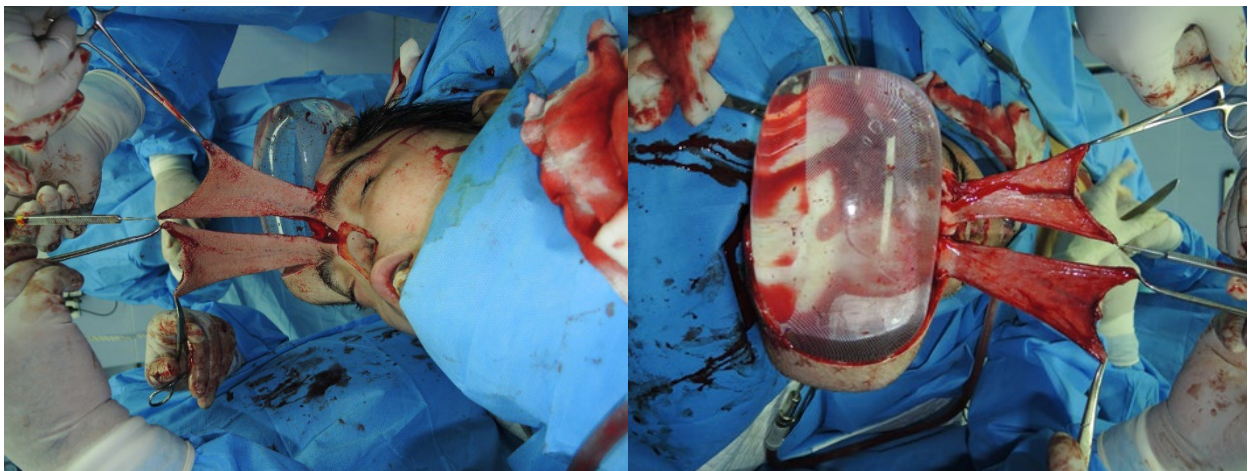


Figure 3: Drawing two flaps with a 5 cm pedicle

and a triangular 4 cm block of flat cartilage. After harvesting the rib and cartilage the perichondrium and the periosteum were repaired by PDS 4.0 and then we made sure that no pneumothorax occurred during harvest and closed the skin. On the side table, the block of the rib was sliced into 4 mm diameter and 5.5cm length stripes (Figure 5). The cartilage was divided into some pieces as needed. Two alae each of them with 3 cm length were designed, 3 mm height and 0.6 cm width, and one piece for septum with 2.5 cm length, 3 mm height, and 1.5 cm width. Then a framework was made and also reshaped as needed (Figure 5 and Figure 6).

After the formation of bone and cartilage, the bone

in the midline on the frontal bone was fixed as a cantilever graft. The tip of the nose was reshaped with cartilage grafts as well. To create an arc of the alae, cartilage was fixed between flaps. Subsequently, the cartilage harvested from the rib which was placed as a columella between the dorsum and maxilla was sutured by nylon 5.0 to reproduce the final shape of the nose. On both sides, the new cartilaginous septum was covered with the de-epithelialized skin flap. A frontal flap was used for the mucous layer and the other one was applied as the outer cutaneous layer. The flap was sutured all around and infolded at the site of the alae. The donor area of the frontal flap was closed completely by primary approximation

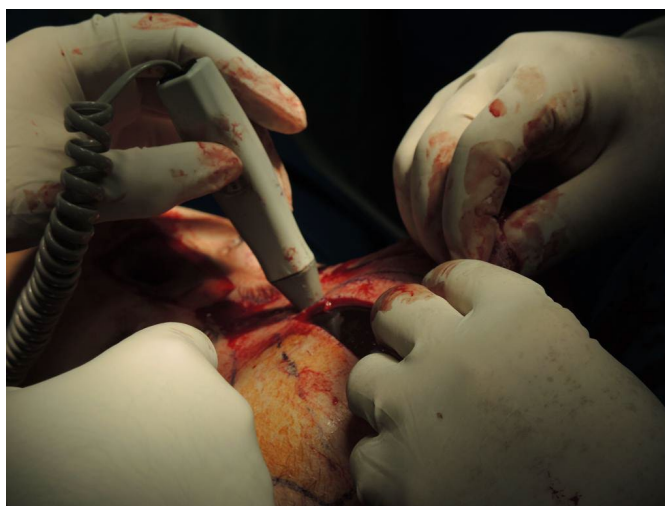

Figure 4: Finding feeding arteries on pedicles by transillumination

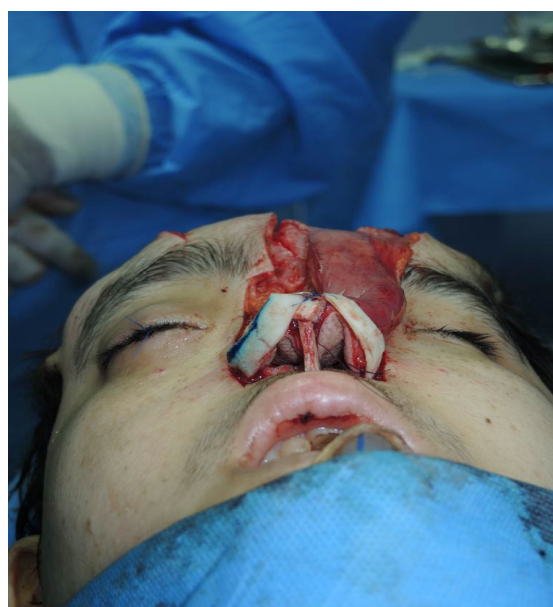

Figure 5: Divided a block of cartilage into some pieces as columella and septum

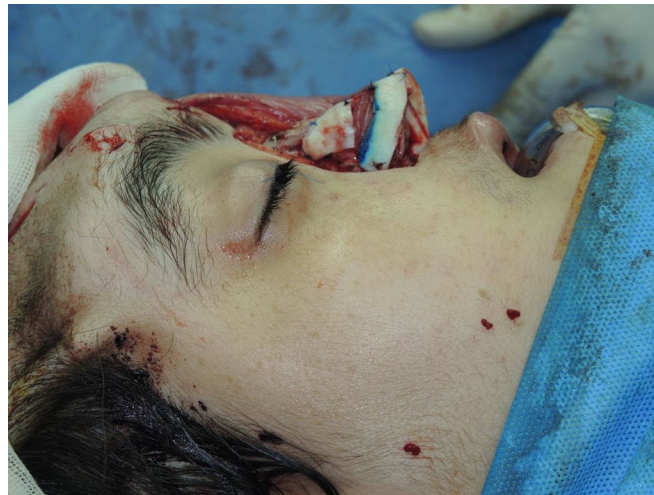

Figure 6: Framework of bone and cartilage as dorsum and septum

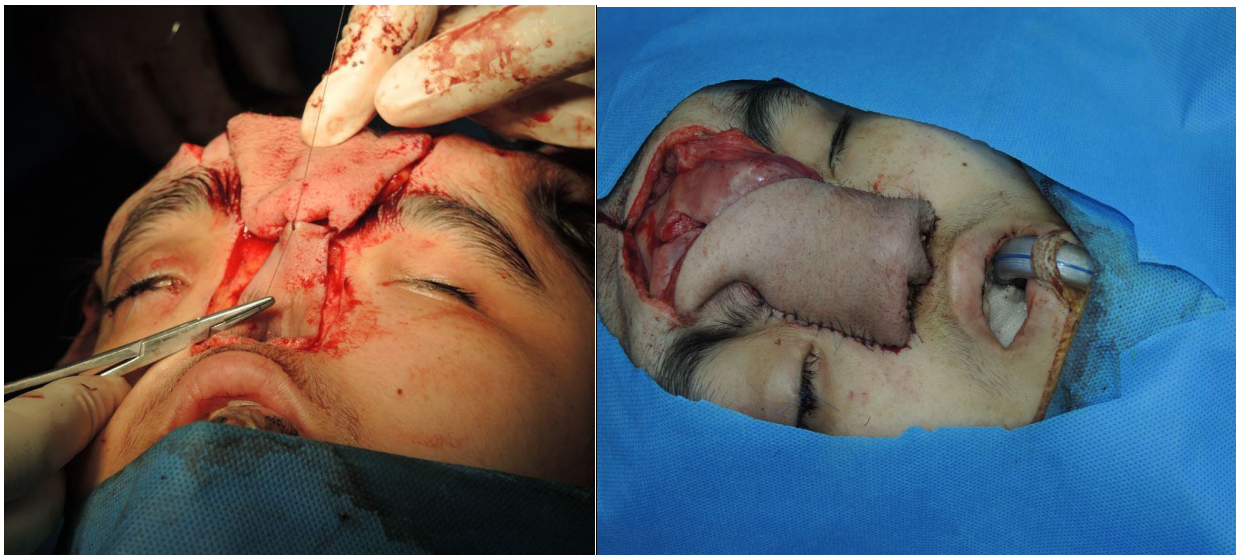

Figure 7: Frontal flaps used as mucous and outer cutaneous layers

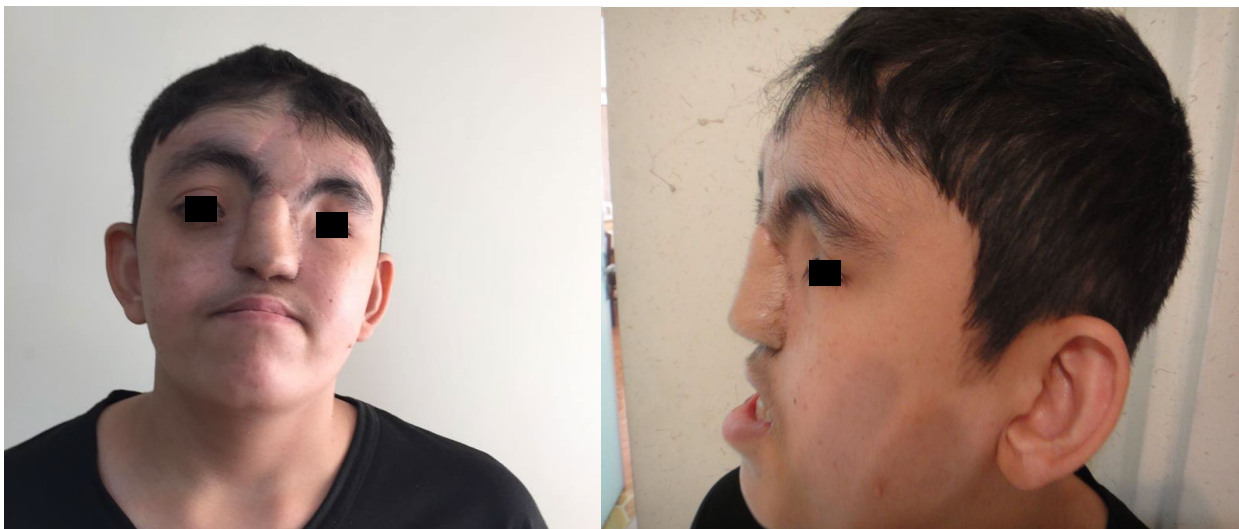

Figure 8: 2 years after the last operation

(Figure 7). In the postoperative period, no problem was encountered. After 2 months, the patient was able to breathe through the nose, no chest pain or problem was present and he did well in daily activities. The patient was monitored for two years, meanwhile, no respiratory problems, stenosis of nasal airways, or chest pain occurred during daily activities. After 3 months, he was able to exercise without pain in the area of the chest wall on which the cartilage and ribs were harvested.

DISCUSSION

There are various classifications regarding congenital nasal deformities. According to Losee et al. ⁶, they are classified as follows:

Type I. Nasal hypoplasia and atrophy

Type II. Nasal hyperplasia and duplication

Type III. Nasal clefts

Type IV. Neoplasms and vascular anomalies

Type I category comprises a spectrum of nasal tissue deficiency from the partial absence of parts to arhinia.

Rosen called the absence of the nose alone arhinia and the absence of the nose along with the complete absence of the olfactory system total arhinia ⁷. Arhinia is usually diagnosed after birth, however, ultrasound and magnetic resonance imaging may be helpful for prenatal diagnosis ⁸.

Because of the rarity of arhinia, no standardized treatment protocol is available.

Gifford et al. reported two cases with congenital absence of the nose and anterior nasopharynx. Surgical establishment of nasal airways was helpful in both patients ⁹. Rodolphe Meyer presented a multi-staged surgical treatment of arhinia in a child. In the first stage, a forehead flap and a rib graft were used to construct the external nose ¹⁰. Boynuyogun et al. presented a 38-day-old patient with arhinia. Pyramid-shaped cartilage grafts were used for the nasal framework and the skin coverage was done with an expanded paramedian forehead flap ¹¹. Spiller et al. presented a multi-staged reconstructive approach to arhinia with stereolithography in an 11 year-old-patient ¹². The advantage of our technique over previous techniques is that the operation was performed in only two stages and at the end of the procedure, the patient had the final shape of the nose and could breathe normally. Also, our technique can be performed for all age groups while in most

previously mentioned techniques surgery were done before school age.

CONFLICT OF INTEREST

The authors declare that they have no conflicts of interest to disclose.

REFERENCES

1. Mondal U, Prasad R. Congenital Arhinia: A Rare Case Report and Review of Literature. *Indian J Otolaryngol Head Neck Surg* 2016;**68**(4):537-9.
2. Harrison LM, Anderson SR, Spiller KE, Pak KY, Schmidt SP, Mancho SN. Reconstruction of congenital arhinia with stereolithographic modeling: case correlate and literature review. *Cleft Palate Craniofac J* 2021;10556656211012859.
3. Alansari H, Fawzi A, Alshaikh R, Althawadi N, Janahi W, Alsaad I. Congenital Arhinia. *Bahrain Medical Bulletin* 2018;**40**(4).
4. Thiele H, Musil A, Nagel F, Majewski F. Familial arhinia, choanal atresia, and microphthalmia. *Am J Med Genet* 1996;**63**(1):310-3.
5. Cesaretti C, Gentilin B, Bianchi V, et al. Occurrence of complete arhinia in two siblings with a clinical picture of Treacher Collins syndrome negative for TCOF1, POLR1D and POLR1C mutations. *Clin Dysmorphol* 2011;**20**(4):229-31.
6. Losee JE, Kirschner RE, Whitaker LA, Bartlett SP. Congenital nasal anomalies: a classification scheme. *Plast Reconstr Surg* 2004 Feb;**113**(2):676-89.
7. Rosen Z. Embryological introduction to congenital malformations of the nose. *Int Rhinol* 1963;**1**(10).
8. Golpayegani G, Jafari M, Karimi A. Arhinia and Bilateral Anophthalmia: Report of a Rare Case and Review of Literature. *Acta Med Iranica* 2021;**59**(10):621.
9. George H Gifford J, Swanson L, Maccollum Dw. Congenital absence of the nose and anterior nasopharynx: Report of two cases. *Plast Reconstr Surg* 1972;**50**(1):5-12.
10. Meyer R. Total external and internal construction in arhinia. *Plast Reconstr Surg* 1997;**99**(2):534-42.
11. Boynuyogun E, Tuncbilek G. A Clinical Report of the Complete Nasal Agenesis: Reconstruction of Congenital Arhinia and Review of the Literature. *Cleft Palate Craniofac J* 2022;10556656221075939.
12. Spiller K, Pak K, Harrison LM, Anderson S, Schmidt S, Mancho S. Reconstruction of Congenital Arhinia with Stereolithography. 2021. <https://corescholar.libraries.wright.edu/cgi/viewcontent.cgi?article=1004&context=msrs>