

# Comparison of the Outcomes of Surgical Repair of Cleft Palate Performed by Modified Von Langenbeck and Bardach (Two-Flap Palatoplasty) Methods

Mehran Peyvasteh<sup>1</sup>, Shahnam Askarpour<sup>1</sup>, Negin Moradi<sup>2</sup>, Adel Mansouri<sup>1\*</sup>

1. Department of Surgery, Ahvaz Jundishapur, University of Medical Sciences, Ahvaz, Iran.
2. Department of Speech Therapy, Ahvaz Jundishapur, University of Medical Sciences, Ahvaz, Iran

## ABSTRACT

**Background:** Cleft lip and cleft palate are one of the most common congenital craniofacial abnormalities in the skull and face. We aimed to investigate the prevalence of complications after primary cleft palate repair surgery, performed on patients referred to a children's hospital, and to use the information and results obtained from it to reduce the complications and improve the results of these surgeries.

**Methods:** In this cross-sectional-analytical study, using a census sampling method, the medical records of 94 consecutive cleft palate patients treated in Abuzar Hospital in Ahvaz, southern Iran, in the years 2019 to 2021 were studied. The rate of postoperative complications during the first week in terms of wound opening and flap necrosis and one month later in terms of fistula formation after surgery were also extracted from the files.

**Results:** Ninety-four patients with congenital cleft palate (57.4% male and 42.6% female) were enrolled. The gap width in all studied patients was  $14 \pm 5$  mm. The frequency of complications of surgical wound opening, flap necrosis, oronasal fistula and hypernasality in von Langenbeck group was 9.5%, 0.15% and 28.1% respectively, and in Bardach group was 9.5 %, 15% and 33.3% respectively.

**Conclusion:** There were no significant differences between the two surgical methods in terms of postoperative complications. Besides, what is important in choosing a surgical method is the patient's clinical condition, the surgeon's experience and skill, and his choice.

## KEYWORDS

Cleft lip, Cleft palate, Craniofacial Abnormalities, Palatoplasty

## Please cite this paper as:

Peyvasteh M., Askarpour S., Moradi N., Mansouri A. Comparison of the Outcomes of Surgical Repair of Cleft Palate Performed by Modified Von Langenbeck and Bardach (Two-Flap Palatoplasty) Methods. *World J Plast Surg.* 2023;12(3):94-99.  
doi: 10.61186/wjps.12.3.94

## \*Corresponding Author:

Dr. Adel Mansouri,

Department of Surgery, Ahvaz Jundishapur, University of Medical Sciences, Ahvaz, Iran.

Email: [dr.adel.mansouri@gmail.com](mailto:dr.adel.mansouri@gmail.com)

Received: 3/05/2023

Accepted: 7/07/2023

## INTRODUCTION

Cleft lip and palate are one of the most common congenital craniofacial deformities in the skull and face area. The abnormality is characterized by the loss of integrity of the lip muscles, alveolar bone, and hard and soft palate. The severity of the deformity can vary from a small hole in the lip to a wide fissure extending to the roof of the mouth and nose<sup>1</sup>.

The optimal goals of cleft palate repair are construction of a complete anatomical and functional closure with normal speech production,

lack of regurgitation of fluids or food into the nasal cavity, no maxillary growth disturbance, and minimization of hearing loss<sup>2, 3</sup>. The treatment process in these patients is best managed in a group and multidisciplinary manner to achieve the desired result<sup>4</sup>.

A number of specialties such as ENT, maxillofacial or plastic surgeons, nutritionists, and speech therapists are involved as a team for improving these patients' quality of life<sup>5</sup>. Although cleft palate abnormalities have been described hundreds of years ago, there is still no consensus on best surgical technique to treat these patients<sup>6</sup>.

Modified von Langenbeck (two bi-pediced flaps, mVL) palatoplasty and Bardach (two-flap palatoplasty, 2FP) are both surgical techniques that aim to repair a cleft palate. In mVL palatoplasty, after making two medial and lateral (along the alveolar ridge) longitudinal incisions on each side of the cleft, two bipedicle flaps of tissue are raised on opposite sides of the cleft palate and brought together in the midline to create a continuous palate. This procedure also involves the incision of the levator veli palatini muscles on either side of the cleft and suturing them together transversely (Intravelar veloplasty) in order to achieve proper velopharyngeal function (VPF). The flaps are mainly based on the greater palatine arteries and are mobilized as pedicles<sup>7</sup>.

In Bardach palatoplasty, two flaps are also used, but they are created differently. Instead of being raised from tissue on either side of the cleft, two separate flaps of oral and nasal mucosa are created. These flaps are then brought together and sutured along the midline to create a continuous palate.

This procedure is sometimes preferred for patients with a wide cleft palate<sup>8</sup>. Like any other surgical intervention, postoperative complications can occur, which may lead to a sub-optimal result or even a complete failure of achieving the desired goals<sup>9</sup>. Some of the most important complications after surgery are the wound dehiscence, fistula formation between the oral and nasal cavities, and necrosis of the mucosal flaps<sup>10</sup>.

Measurement of the surgical results is important in the estimation of the results of cleft repair and improvement in its quality<sup>11</sup>. Efforts to reduce the incidence of these complications have always been the focus of studies conducted in various reconstructive surgery centers around the world. We aimed to clinically evaluate and compare the

prevalence of complications after primary cleft palate repair surgery using the mVL or Bardach (2FP) techniques.

## MATERIALS AND METHODS

In this cross-sectional-analytical study, using a census sampling method, the medical records of 94 consecutive cleft palate patients treated in Abuzar Hospital in Ahvaz, southern Iran, in the years 2019 to 2021 were studied. Children suffering from submucosal or syndromic cleft palate or having a history of previous cleft palate repair surgery in another center were excluded. The surgical repairs were performed by a pediatric surgeon highly proficient in cleft surgery, and the surgical method used for each patient was determined by his judgment.

The following information was collected: date of birth, age (months) of the patient at the time of primary palate repair surgery, gender, type of cleft (based on the Veau system, the type of cleft was divided as follows: Veau type I: cleft soft palate, type II: cleft soft palate/hard palate, type III unilateral cleft lip/palate, type IV: bilateral cleft lip/palate).

Data of the postoperative complications recorded during the first week post-op visit in terms of wound dehiscence and flap necrosis, as well as first month post-op visit in terms of fistula formation after surgery, was also extracted from the files. Pittsburgh Fistula Classification System (PFCS) was used to classify the type of oronasal fistula based on its anatomical location as follows: uvula (I), soft palate (II), junction of the hard and soft palates (III), hard palate (IV), and junction of the primary and secondary palates (V). Also, the hyper-nasality assessment data for the operated patients who had reached the eligible age (>3 years) for undergoing the perceptual tests of cul-de-sac hypernasality resonance, as explained by Williams et al.<sup>14</sup> during the study period were also extracted. This study was approved by the Golestan Hospital Research Ethics Committee (Ethics code: IR. AJUMS. HGOLESTAN. REC.1401.033).

### Statistical Analysis

The obtained data were analyzed using IBM SPSS ver. 22 software (IBM Corp., Armonk, NY, USA). Descriptive data, presented as mean and standard

deviation (or median and interquartile range) were used in quantitative variables and frequency and percentage were used in qualitative variables. *t*-test (Mann-Whitney), chi-square test, Pearson (Spearman) correlation coefficient and analysis of variance (KruskalWallis) were used for univariate data analysis. A *P*-value of < 0.05 was considered for statistical significance.

## RESULTS

Ninety-four patients with congenital cleft palate (54 males and 40 females) participated in this study. Their average age at the time of palatoplasty surgery was  $18 \pm 7$  months. The demographic and clinical characteristics of patients in each treatment group are presented in **Table 1**. Statistically, there was no significant difference between the treatment groups in terms of gender or age at the time of repair. The mean gap width in all studied patients was  $14 \pm 5$  mm. This extent was  $13 \pm 5$  mm and  $15 \pm 5$  mm in the mVL and 2FP groups, respectively (*P*-value = 0.764). The frequency of type II, III, and IV clefts (according to Veau classification) was 52 (55.3%), 37 (39.4%), and 5 (5.3%), respectively. All patients with type II cleft underwent mVL operation and all patients with type IV cleft underwent Bardach operation, but in patients with type III cleft, 22

patients were repaired by mVL method and 15 patients were repaired by Bardach method.

Assessment of the data showed that 24 patients had suffered postoperative complications. Ten patients (7.44%) developed wound dehiscence. Seven patients were in the mVL group and 3 patients were in the Bardach group. In all cases, the dehiscence occurred at the junction of the soft and hard palate. In the Bardach repair group, one case had a complication of flap necrosis, which was later repaired using a buccal flap and healed without complications. Ten cases of oronasal fistula were developed. Seven cases in mVL group and 3 cases in Bardach group. In fact, all the patients who had suffered from wound dehiscence eventually developed an oronasal fistula. The hyper-nasality assessment tests were performed on 44 patients (32 patients from the mVL group and 12 patients from the Bardach group). Evidence of hyper-nasality was seen in 13 patients (9/32 in mVL group and 4/12 in Bardach group). There was no significant difference in terms of hyper-nasality score between the two groups. **Table 2** shows the amount and difference in the prevalence of complications between the different techniques used.

**Figure 1** shows Two-flap (bardach) palatoplasty technique for cleft palate repairing. Also, modified von Langenbeck palatoplasty for cleft palate repairing is provided in **Figure 2**.

**Table 1:** Demographic and clinical characteristics of patients

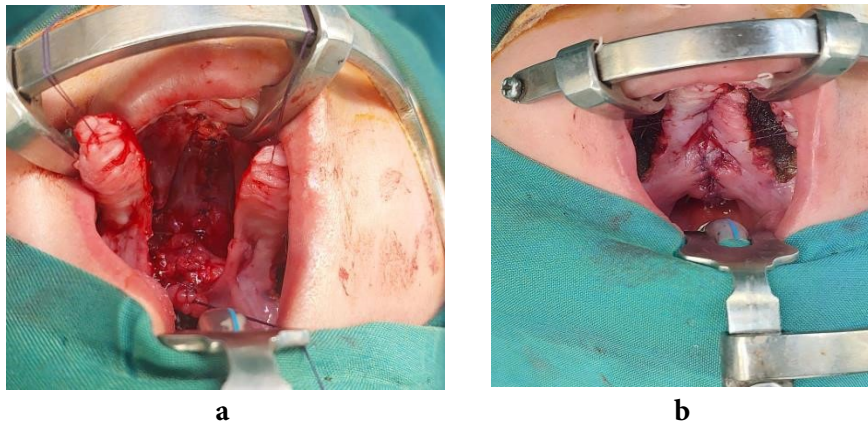
Variable	mVL	2FP	Total	P-value
Age at repair (months), mean $\pm$ SD	19 $\pm$ 7	17 $\pm$ 7	18 $\pm$ 7	0.537
Sex, n, %	Male	12 (60)	54 (57.4)	-
	Female	8 (40)	40 (42.6)	
Cleft width (mm), mean $\pm$ SD	13 $\pm$ 5	15 $\pm$ 5	-	0.764
<b>Veau type, n</b>				
Type II	52	0	52	-
Type III	22	15	37	
Type IV	0	5	5	
Total cases	74	20	94	

mVL, modified von Langenbeck repair; 2FP, two-flap palatoplasty.

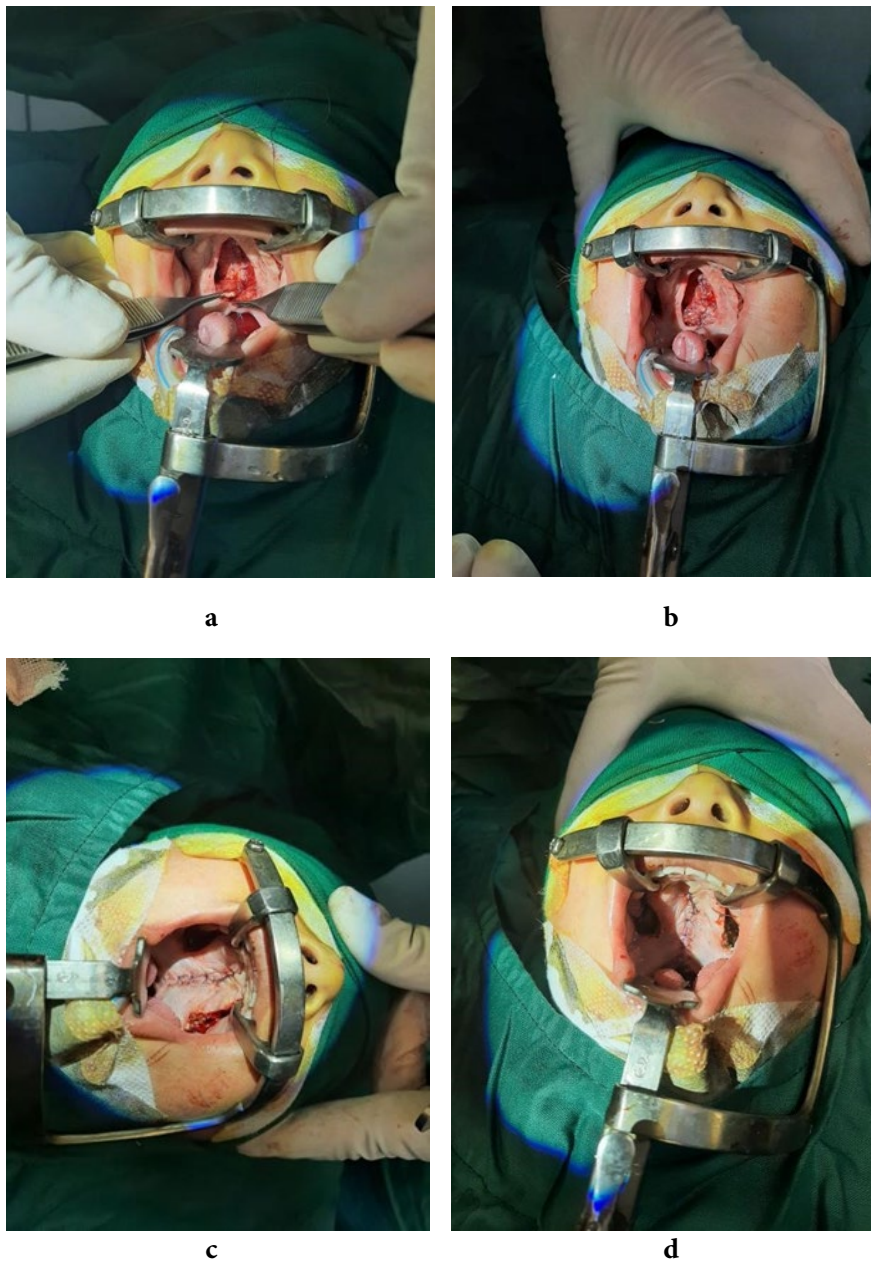
**Table 2:** The prevalence of complications and differences between the two palatoplasties

Complication	Repair technique			P-value
	mVL, n (%)	2FP, n (%)	Total, n (%)	
Dehiscence	7 (9.5)	3 (15)	10 (10.6)	0.732
Flap necrosis	0	1 (5)	1 (1.06)	0.341
Oronasal fistula	7 (9.5)	3 (15)	10 (10.6)	0.732
Hypernasality	9/32 (28.1)	4/12 (33.3)	13/44 (29.5)	0.860

mVL, modified von Langenbeck repair; 2FP, two-flap palatoplasty



**Figure 1 (a-b):** Two-flap (Bardach) palatoplasty technique for cleft palate repairing



**Figure 2 (a-d):** Modified von Langenbeck palatoplasty for cleft palate repairing



## DISCUSSION

The assessment of the outcomes of different techniques for surgical repair of cleft palate is important to evaluate their effectiveness in repair, identify the potential post-operative complications, inform the development of guidelines for surgery, improve the outcomes by selecting best technique for each patient and provide data for comparative analysis and research leading to more improvement in surgical techniques and patient care<sup>12-14</sup>.

The present study was conducted with the aim of comparing the postoperative outcomes of patients with cleft palate who underwent surgical repair by a modified VL, or 2FP (Bardach) technique. Wound dehiscence, which often occurs early in the postoperative period, may heal spontaneously or convert to an oronasal fistula<sup>15</sup>. The prevalence of wound dehiscence may be influenced by multiple factors, such as the difference in surgical techniques, the patient's medical, nutritional, or socioeconomic characteristics, as well as variation in postoperative care<sup>16</sup>.

In our study, the entire patient who had suffered from dehiscence eventually developed a fistula, all of whom were located in the area of soft/hard palate junction, which is one of the most susceptible and prevalent sites for developing wound dehiscence and subsequent fistula<sup>17</sup>.

The prevalence of wound dehiscence and fistula formation between the two-studied group was not statistically different. This finding is consistent with other studies<sup>15,17</sup>. Although they had reported 40 to 50 percent spontaneous healing of wound dehiscence and attributed this finding to low tension on closure line achieved by using delicate surgical technique and relaxing incisions<sup>15,17</sup>. They also emphasized the importance of appropriate postoperative nursing care, and thorough instructions that include a liquid diet only regimen, no sucking action, and keeping oral hygiene for at least 3 weeks<sup>15</sup>.

One of the major aims of cleft repair surgeries is reasonable speech development, which can be assessed by hyper-nasality tests. In this study, the prevalence of hyper-nasality was not statistically different between the two studied groups. This result is consistent with other studies<sup>18,19</sup>.

Some of the limitations of this study are retrospective nature of the study, restricted period of follow-up, and small size of the groups. Therefore, we propose well-

designed RTCs to attentively address these limitations and produce new algorithms or statistical models to help the surgeons in choosing the suitable technique based on the medical condition of the patient and the anatomical characteristics of the cleft.

## CONCLUSION

The complications of wound dehiscence, flap necrosis, oronasal fistula and hyper-nasality were not significantly different in the two studied groups and choosing the appropriate procedure for each patient can be mainly based on the experience and the decision of the surgeon and the clinical conditions of the patients.

## ACKNOWLEDGEMENTS

The authors are thankful for the Clinical Research Development Department and Cleft Lip & Palate Clinic staff of Abuzar Hospital for their assistance.

## CONFLICT OF INTERESTS

There is no conflict of interests.

## FUNDING

None to declared.

## REFERENCES

1. Candotto V, Oberti L, Gabrione F, et al. Current concepts on cleft lip and palate etiology. *J Biol Regul Homeost Agents* 2019 May-Jun;33(3 Suppl. 1):145-51. Dental supplement.
2. Deshpande GS, Campbell A, Jagtap R, et al. Early complications after cleft palate repair: a multivariate statistical analysis of 709 patients. *J Craniofac Surg* 2014 Sep;25(5):1614-8.
3. Salari N, Darvishi N, Heydari M, Bokae S, Darvishi F, Mohammadi M. Global prevalence of cleft palate, cleft lip and cleft palate and lip: A comprehensive systematic review and meta-analysis. *J Stomatol Oral Maxillofac Surg* 2022 Apr;123(2):110-20.
4. Namdar P, Etezadi T, Raisolsadat SMA, Lal Alizadeh F, Shiva a. Treatment goals in individuals with orofacial clefts: A literature review. *Clinical Excellence* 2020;9(4):45-55.
5. Ishaq I, Fayyaz GQ. Recurrent palatal fistula and nasal regurgitation: Anteriorly based dorsal tongue flap: A reliable solution. *The Professional Medical Journal*

- 2013;**20**(03):390-8.
6. Williams WN, Seagle MB, Pegoraro-Krook MI, et al. Prospective clinical trial comparing outcome measures between Furlow and von Langenbeck Palatoplasties for UCLP. *Ann Plast Surg* 2011 Feb;**66**(2):154-63.
  7. Smith KS, Ugalde CM. Primary palatoplasty using bipedicle flaps (modified von Langenbeck technique). *Atlas Oral Maxillofac Surg Clin North Am* 2009 Sep;**17**(2):147-56.
  8. Bardach J. Two-Flap palatoplasty: Bardach's technique. *Operative Techniques in Plastic and Reconstructive Surgery* 1995 1995/11/01;**2**(4):211-4.
  9. Schultz RC. Management and timing of cleft palate fistula repair. *Plast Reconstr Surg* 1986 Dec;**78**(6):739-47.
  10. Adesina OA, Efunkoya AA, Omeje KU, Idon PI. Postoperative complications from primary repair of cleft lip and palate in a semi-urban Nigerian teaching hospital. *Niger Med J* 2016 May-Jun;**57**(3):155-9.
  11. Abdurrazaq TO, Micheal AO, Lanre AW, Olugbenga OM, Akin LL. Surgical outcome and complications following cleft lip and palate repair in a teaching hospital in Nigeria. *Afr J Paediatr Surg* 2013 Oct-Dec;**10**(4):345-57.
  12. Paine KM, Tahiri Y, Wes AM, et al. An Assessment of 30-Day Complications in Primary Cleft Lip Repair: A Review of the 2012 ACS NSQIP Pediatric. *Cleft Palate Craniofac J* 2016 May;**53**(3):283-9.
  13. Nguyen C, Hernandez-Boussard T, Davies SM, Bhattacharya J, Khosla RK, Curtin CM. Cleft palate surgery: an evaluation of length of stay, complications, and costs by hospital type. *Cleft Palate Craniofac J* 2014 Jul;**51**(4):412-9.
  14. Raghavan U, Vijayadev V, Rao D, Ullas G. Postoperative Management of Cleft Lip and Palate Surgery. *Facial Plast Surg* 2018 Dec;**34**(6):605-11.
  15. Sakran KA, Liu R, Yu T, Al-Rokhami RK, He D. A comparative study of three palatoplasty techniques in wide cleft palates. *Int J Oral Maxillofac Surg* 2021 Feb;**50**(2):191-7.
  16. Swanson MA, Auslander A, Morales T, et al. Predictors of Complication Following Cleft Lip and Palate Surgery in a Low-Resource Setting: A Prospective Outcomes Study in Nicaragua. *Cleft Palate Craniofac J* 2022 Dec;**59**(12):1452-60.
  17. Li F, Wang HT, Chen YY, et al. Cleft relapse and oronasal fistula after Furlow palatoplasty in infants with cleft palate: incidence and risk factors. *Int J Oral Maxillofac Surg* 2017 Mar;**46**(3):275-80.
  18. Kara M, Calis M, Kara I, Kulak Kayikci ME, Gunaydin RO, Ozgur F. Comparison of speech outcomes using type 2b intravelar veloplasty or furrow double-opposing Z plasty for soft palate repair of patients with unilateral cleft lip and palate. *J Craniomaxillofac Surg* 2021 Mar;**49**(3):215-22.
  19. Paniagua LM, Collares M, Costa S. Comparative study of three techniques of palatoplasty in patients with cleft of lip and palate via instrumental and auditory-perceptive evaluations. *Int Arch Otorhinolaryngol* 2010;**14**(1):18-