

Efficacy of Digital Anesthesia: Comparison of Two Techniques

Muhammad Ahmad*

Department of Aesthetic Plastic Surgery,
Islamabad Private Hospital, Islamabad,
Pakistan

ABSTRACT

BACKGROUND

Digital nerve block is commonly performed by care providers in medical fields. This study compares the blocks in terms of effectiveness of anesthesia and pain.

METHODS

Patients were divided into two groups. First group underwent digital block whereas 2nd group had transmetacarpal digital block. The subcutaneous ring block was performed by two injections of 3 ml of 2% lignocaine in a 3 ml syringe with a 26G needle at the level of phalangeal/palmer crease. One prick was performed on either side of the finger base extending on dorsal and volar aspects of the digit. The transmetacarpal block received lignocaine identically at dorsal aspect of metacarpo-phalangeal joint. 1.5ml of the solution was injected in dorsal and 1.5ml in palmer side on either side of the finger. When sensation of needle was felt, 1ml of the solution was injected. Then the needle was withdrawn injecting another 1ml and finally the last 1ml was injected close to the dorsal skin. The pain prick was recorded after 30 seconds.

RESULTS

The mean time to complete abolition of sensation was 9.1 minutes in group I and 9.0 minutes in group II. The mean duration of anaesthesia was 202 minutes in group I and 206.8 minutes in group II. The mean pain scale was 5.67 (range=4–7) in group I and 4.2 (range=3–7) in group II.

CONCLUSION

Subcutaneous ring block and transmetacarpal techniques are good in digital anesthesia and involve the administration of the local anaesthetic through two injections.

KEYWORDS

Digital anesthesia; Subcutaneous ring block; Transmetacarpal technique

***Corresponding Author:**
Muhammad Ahmad, MD;
Plastic, Reconstructive & Hair Restora-
tive Surgeon,
Islamabad Private Hospital,
2nd floor, Zahoor Plaza, Blue Area,
Block-A,
East-38, Jinnah Avenue,
Islamabad, Pakistan
E-mail: plasticsurgeonpk@yahoo.com
Received: March 18, 2016
Revised: August 29, 2016
Accepted: September 4, 2016

Please cite this paper as:

Ahmad M. Efficacy of Digital Anesthesia: Comparison of Two Techniques. *World J Plast Surg* 2017;6(3):351-355.

INTRODUCTION

Digital nerve block is one of the most commonly performed blocks by care providers in several medical fields.¹ Various studies have been conducted demonstrating the efficacy and safety of local anaesthesia as a digital block.²⁻⁵ There are various

methods of performing this procedure including (i). the traditional subcutaneous block with one or two punctures, (ii). circumferential subcutaneous ring block at the finger base, (iii) the transmetacarpal block via two dorsal punctures, (iv) transthecal block and, (v) SIMPLE block (Single subcutaneous Injection in Medline of Phalanx with Lignocaine and Epinephrine).⁶⁻⁸ Dorsal skin is said to be less painful to needle punctures than the volar glabrous skin. The classic two injections dorsal approach was originally described by Braun and Harris.⁹ The transmetacarpal and the ring blocks have not been compared in any local study. Both of these require two injections on either side. The objective of the study was to compare the blocks in terms of effectiveness of anesthesia and pain.

MATERIALS AND METHODS

This study was conducted in a private setup from January 2013 to December 2013. The study goal was to compare time to abolition of distal sensations and pain from the procedure. The patients were divided into two groups. First group comprised of the patients undergoing digital block whereas 2nd group consisted of the patients having transmetacarpal digital block. All the patients underwent surgery distal to the proximal phalanx crease. The patients were randomly selected for either group. Informed consent was obtained and only adult patients >18 years of age were included. Any patient having history of allergic reaction to Lignocaine, neurological disease, peripheral vascular disease, diabetes mellitus was excluded from the study.

All the blocks were performed by the single investigator and all the testing was also performed by the same investigator. The same dose and concentration of local anaesthetic was used for each technique. The subcutaneous ring block was performed by two injections of 3 ml of 2% lignocaine in a 3 ml syringe with a 26G needle at the level of phalangeal/palmer crease (Figure 1). One prick was performed on either side of the finger base extending on dorsal and volar aspects of the digit. The transmetacarpal block was performed by injecting 3 ml of 2% lignocaine through the dorsal aspect at the level of metacarpo-phalangeal joint. 1.5ml of the solution was injected in dorsal and 1.5ml in palmer side on either side of the finger.

The tip of the surgeon's finger was placed on

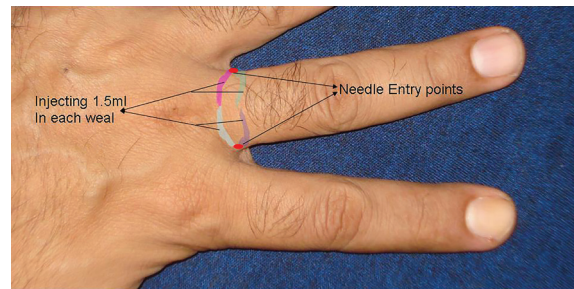


Fig. 1: Ring Block.

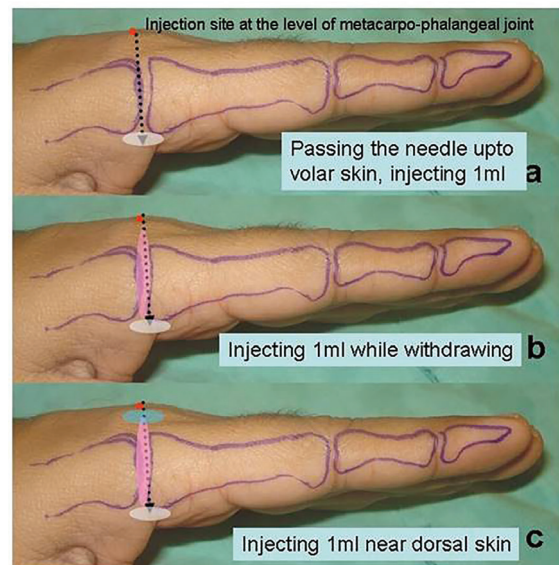


Fig. 2: Transmetacarpal block.

palmer side. The needle was pushed through and through but not out of the palmer skin. The feel of the needle was felt and about 1ml of the solution was injected. Then the needle was withdrawn injecting another 1ml in the way and finally last 1ml was injected close to the dorsal skin. The same procedure was repeated on the other side (Figure 2). Time was noted while administering the injections. The sensations to pain prick was noted after 30 seconds. The patient was asked about the pain according to the Pain Scale (0–10) (Table 1).

RESULTS

Fifteen patients were included in either group. Mean age of the patient was 29.2 years in group I (ring block) and 27.4 years in group II (transmetacarpal block). Male to female ratio was 2:1 and 1.5:1 in group I and II respectively. The mean time to complete abolition of sensation was 9.1 minutes in group I and 9.0 minutes in group II (range: 7-11 and 7-11 respectively). The mean duration of anaesthesia was 202 minutes in

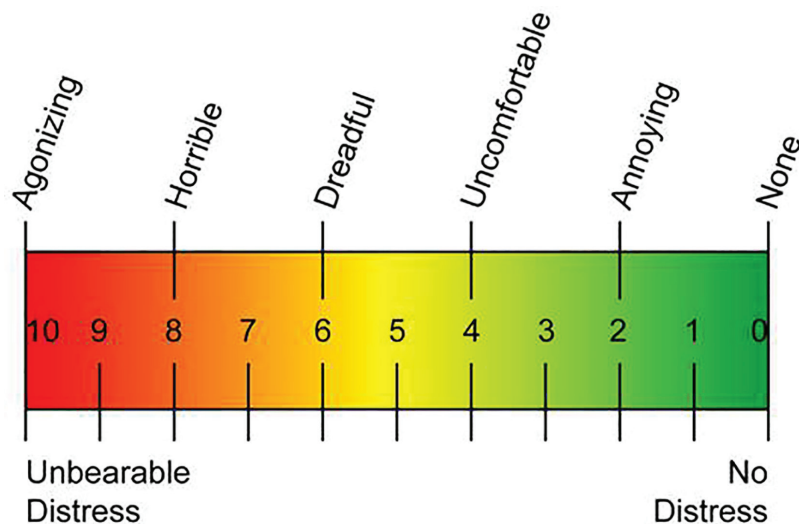


Table 1: Pain scale.

group I and 206.8 minutes in group II. The mean pain scale was 5.67 (range=4–7) in group I. The mean pain scale in group II was 4.2 (range=3–7).

DISCUSSION

The ideal method of digital block anaesthesia would have a quick onset, painless and result in complete anaesthesia of the whole digit including volar as well as dorsal digital skin. The level of anaesthesia should provide total abolition of pain and light touch sensations. Various techniques of digital block have been described.⁶⁻⁸ Digital subcutaneous ring block involves the injection on either side of the base of finger extending the needle to dorsal and volar side. Transmetacarpal block involves the injection from the dorsal skin at the base of metacarpo-phalangeal joint.⁶⁻⁸

In the present study, we compared the two techniques, i.e., transmetacarpal block and digital nerve block. Both these techniques require two injections (one on either side) to abolish the sensations. The transmetacarpal block involved the puncture of dorsal skin advancing to the palmer side, where feel of the needle was felt by the surgeon's other hand, thereby avoiding skin puncture. The mean time between the two techniques was insignificant.

The mean pain score in ring block was 5.67 as compared to 4.2 in transmetacarpal block. This is in contrast to the observation noted by Knoop *et al.* which revealed no significant pain rating,⁴ whereas the time for abolition of sensation was 6.35 minutes vs 9.1 minutes and 2.82 minutes vs 9.0 minutes. The reason for this obvious

difference in time may be due to the fact that we checked the pain sensation on the injured/affected finger whereas in the study by Knoop *et al.*, the sensation was checked on the opposite side of the injured finger.⁴

Failure rate to achieve complete anaesthesia was 23% and 3% in subcutaneous block and transmetacarpal block respectively in the study by Knoop *et al.* whereas no case of failure to achieve anaesthesia was seen in the present study.⁴ The reason is that Knoop *et al.* used different doses of lidocaine for each method. But similar doses and volumes were used in the present study in both the groups (i.e., 3ml of 2% lidocaine without adrenaline).⁴ Various other studies have been conducted to compare the results of transthecal and transmetacarpal blocks,^{2,3,10} and the results of transthecal and subcutaneous blocks.¹¹ No study has been found comparing the results of subcutaneous ring block and transmetacarpal block in the local literature.

Various theoretical drawbacks are associated with transmetacarpal block. Firstly, the adjacent finger is also anesthetized. Secondly, there is a theoretical chance of having a direct injury to a nerve or vessel because, needle passes very close to the neurovascular bundle but none was found in the present study. Pulling back the plunger of the syringe before injecting confirms the needle is not in the vessel. The comparison of the present study is shown in Table 2 with some of the other studies already conducted. Subcutaneous ring block and transmetacarpal techniques both are good in achieving digital anaesthesia. Both of them involve the administration of the

Table 2: Comparison of various studies

Study	Journal	Year	Techniques	Sample size	Pain scale	Mean Score	Mean time to anesthesia	Failed anaesthesia	Conclusion
Ahmad et al. (Pakistan)	Current study	2010	Ring block & Transmetacarpal block	15 each	Analogue pain scale 0-10	5.67 & 4.2	9.1 & 9.0	NIL	Both effective
Hill et al. ³ (USA)	Ann Emerg Med	1999	Transthecal & Traditional Digital Block	31 volunteers	Visual analogue	Mean analog score 1.7 & 1.4	188 & 152		Both equal
Knoop et al. ⁴ (USA)	Ann Emerg Med	1994	Digital block & metacarpal block	30 patients	Non segmental visual analogue	Mean analogue score 2.53 & 3.38	2.82 & 6.35 minutes	3% & 23%	Digital block more effective
Bashir et al. ¹⁰ (Pakistan)	J Coll Physicians Surg Pak	2008	Dorsal digital block & Volar block	30 patients	Pain scale score 0-10	5.27+1.05 & 4.27+0.87			Volar block more effective
William et al. ⁸ (Canada)	Plast Reconstr Surg	2006	Dorsal block & Volar block	27 volunteers					No significant difference
Hung et al. ¹ (USA)	J Hand Surg (B)	2005	Subcutaneous, Metacarpal & Transthecal	50 volunteers	Analogue pain score				Subcutaneous block preferred
Brutus et al. ¹³ (Belgium)	Chir Main	2002	Transthecal, Subcutaneous & Combination of both	30 patients	Visual analogue pain scale	83.3%		16.7%	Subcutaneous preferred
Low et al. ¹¹ (USA)	J Hand Surg (Am)	1997	Transthecal & Subcutaneous	20 volunteers					Subcutaneous preferred
Cannon et al. ¹² (UK)	Emerg Med J	2010	Subcutaneous & Digital nerve block	37 & 39	NIL (clinician satisfaction)	89% & 82%			Subcutaneous preferred

local anesthetic through two injections.

CONFLICT OF INTEREST

The authors declare no conflict of interest.

REFERENCES

- Hung VS, Bodavula VKR, Dubin NH. Digital anaesthesia: comparison of the efficacy and pain associated with three digital nerve block techniques. *J Hand Surg* 2005;**30**:581-4.
- Cummings AJ, Tisol WB, Meyer LE. Modified transthecal digital anaesthesia of the finger. *J Hand Surg* 2004;**29A**:44-8.
- Hill Jr RG, Patterson JW, Parker JC, Bauer J, Wright E, Hiller MB. Comparison of transthecal digital block and traditional digital block for anaesthesia of the finger. *Ann Emerg Med* 1995;**25**:604-7.
- Knoop K, Trott A, Syverud S. Comparison of digital versus metacarpal blocks for repair of finger injuries. *Ann Emerg Med* 1994;**23**:1296-1300.
- Torok PJ, Flim SD, Shin AY. Transthecal digital block at the proximal phalanx. *J Hand Surg* 2001;**26B**:69-71.
- Chui DT. Transthecal digital block: flexor tendon sheath used for anaesthetic infusion. *J Hand Surg* 1990;**15A**:471-7.
- Ramamurthy S, Hickey R. Anaesthesia. In: Green DP, Hotchkiss RN, Pederson WC, Eds. *Green's Operative Hand Surgery*. Philadelphia, Churchill-Livingstone, 1999; 22-47.
- William JG, Lalonde DH. Randomized comparison of the single-injection volar subcutaneous block and the two-injection dorsal block for

- digital anaesthesia. *Plast Reconstr Surg* 2006;**118**:1195-2000.
- 9 Braun H, Harris ML. Operations on the extremities. In: Braun H, Harris ML, eds. *Local Anaesthesia: its scientific basis and practical use*. 2nd ed. New York: Lea & Febiger, 1924; pp. 366-7.
 - 10 Bashir MM, Khan FA, Afzal S, Khan BA. Comparison of traditional two injections dorsal digital block with volar block. *J Coll Physicians Surg Pak* 2008;**18**:768-70.
 - 11 Low CK, Vartany A, Engstrom JW, Poncelet A, Diao E. Comparison of transthecal and subcutaneous single injection digital block techniques. *J Hand Surg* 1997;**22A**:901-5.
 - 12 Cannon B, Chan L, Rowlinson JS, Baker M, Clancy M. Digital anaesthesia: one injection or two? *Emerg Med J* 2010;**27**:533-6.
 - 13 Brutus JP, Baeten Y, Chahidi N, Kinnen L, Ledoux P, Moermans JP. Single injection digital block: comparison between three techniques. *Chir Main* 2002;**21**:182-7.