

Aesthetic and Functional Consequences of Spreader Graft without Suturing To the Upper Lateral Nasal Cartilage: A Randomized Double-Blinded Clinical Trial

Seyed Esmail Hassanpour ^{1*}, Mohadeseh Amini ¹, Abdolreza Rouientan ¹

1. Department of Plastic Surgery, Educational Hospital of 15th Khordad, Shahid Bheshti University, Tehran, Iran

ABSTRACT

Background: Considering the importance of the spreader graft technique in order to prevent collapse and airway retention and the importance of its effect on the dorsal aesthetic line and nasal width, in this study we compared the outcome of suturing spreader graft to septum _upper lateral cartilageas the classic technique to suturing spreader graft only to septum.

Methods: This comparative observational study was conducted on 50 consecutive patients referred to Rhinoplasty Department in 15 khordad Hospital from 2019 - 2020 . The study participants were randomly assigned into two groups which scheduling the new spreader graft technique without suturing the upper lateral cartilage (n = 25) or the frequent spreader graft technique with suturing to both septum and upper lateral nasal cartilage (n = 25). The nasal obstruction degree, the status and health-related quality of life, patients' satisfaction, and subjective mental image of the nasal structure were the study endpoint. The patients were followed-up for six months.

Results: The two groups were matched for gender and age. Although all study endpoints significantly improved in both groups, but the six-month trend of the change in each parameter was different in the two groups with superior improvement in those who planned for spreader graft technique without suturing the upper lateral cartilage.

Conclusion: In patients scheduling for selective rhinoplasty, new procedural technique including spreader graft without suturing to upper lateral cartilage can lead to more postoperative favorable outcome with regard to patients' satisfaction of the procedure, lack of obstructive symptoms, aesthetic feature, and health-related quality of life as compared to suturing to both septum and upper lateral cartilage.

KEYWORDS

Aesthetic; Functional consequences; Nasal cartilage

Please cite this paper as:

Hassanpour SE., Amini M., Rouientan A. Aesthetic and Functional Consequences of Spreader Graft without Suturing To the Upper Lateral Nasal Cartilage: A Randomized Double-Blinded Clinical Trial. World J Plast Surg. 2023;12(3):24-30.
doi: 10.61186/wjps.12.3.24

*Corresponding Author:

Seyed Esmail Hassanpour

Professor, Department of Plastic Surgery, Educational Hospital of 15th Khordad, Shahid Bheshti University, Tehran, Iran

Tel.: +98912 1712348

Email: hassanpour1394@sbmu.ac.ir

Received: 2023.08.11

Accepted: 2023.11.26

INTRODUCTION

According to statistics from the American Society of Plastic Surgeons Rhinoplasty is one of the most popular plastic surgery in the world.¹. Rhinoplasty is a surgical procedure that provides a new look to the face

along with preserving nasal function. In this regard, concha hypertrophy, septal deviation or narrowing of the internal nasal valve may lead to respiratory problems. In rhinoplasty, creating a new middle vault and widening the angle of the inner nasal valve (INV) plays an essential role in maintaining the nasal airway^{2,3}. The middle valve is the nasal fulcrum, which includes the nasal bone, septal cartilage, and upper lateral cartilage, but hump reduction and dorsal surgery lead to disruption of the integrity of this structure, and inadequate reconstruction of this area leads to deformity and collapse of the INV⁴. The etiology of INV collapse include congenital deformity, previous rhinoplasty, septal deviation, lower turbinate hypertrophy, tip ptosis, facial paralysis, cancers, trauma, and autoimmune diseases.

In an effort to quickly and smoothly correct small defects in the nasal cavity, a standard technique is to place a spreader graft with fibrin glu between septum and upper lateral cartilage. Spreader graft makes a supporting component in middle vault reconstruction. Spreader grafts are widely considered to be the mainstay of treatment for insufficient internal nasal valve. Spreader graft was first introduced by Sheen in 1984 to prevent functional collapse of the nasal valve following reduction in rhinoplasty⁵. Subsequently, the use of spreader graft was developed to correct septal deviation and reconstruct the dorsal aesthetic line. Both the spreader graft and the auto-spreader flap can be used to maintain the repair of the angle of the inner valve and to maintain the beauty of the dorsal nose⁶. However, there are some potential limitations to the spreader technique. The spreader graft is not able to adequately lateralize the lateral wall of the nose effectively, and this affects the functional outcome⁷. Additionally, the malfunction of the upper respiratory tract after rhinoplasty has a negative effect on quality of life⁸.

The use of a spreader graft between the septum and the medial surface of the upper lateral cartilage is the standard surgical procedure for the problem of INV stenosis⁹. There are questions that grafts in addition to lateralizing the upper lateral cartilage, they occupy the airway space. Recently, methods such as upper lateral cartilage (ULC) suspension with suture on maxillary wall through sub-orbital incision and Onlay cartilage grafts implants have been introduced¹⁰.

Considering the importance of the spreader graft

technique in order to prevent collapse and airway retention and the importance of its effect on the dorsal aesthetic line and nasal width, in this study we compared the outcome of the spreader graft with concurrently suturing to septum and the upper lateral nasal cartilage as the classic technique and without suturing it to upper lateral cartilage.

MATERIALS AND METHODS

Study population

Fifty consecutive patients who undergo selective rhinoplasty in 15 Khordad Hospital Tehran, Iran between 2019 - 2020, were enrolled in this study. Those patients with the history of previous rhinoplasty, history of asthma or allergy, history of trauma, known body dysmorphic disorders, or history of multiple cosmetic surgeries were all excluded from our intervention.

The study protocol was ethically approved by the ethical committee at Shahid Beheshti University of Medical Sciences (ethical code of IR.SBMU.MSP.REC.1398.555). Written informed consent was taken from all study participant after explaining the study aims and protocols and before any intervention.

Study intervention

Using a computerized number random table, the study participants were randomly assigned into two groups which scheduling the new spreader graft technique without suturing the upper lateral cartilage (n = 25) or the frequent spreader graft technique (n = 25). Spreader graft was made from septum (with a length of 25 to 30mm and a thickness of 3mm). The cephalic end of graft was set below the bony dorsum and the caudal end at the septal angle. It could be also placed in a higher visible a lower invisible position along the septum. In control group, the graft was sutured to septum and also to upper lateral cartilage using 5-0 pds yarn and horizontal mattress method, but in the intervention group, the graft was sutured only to septum.

Study assessments

The study subjects were assessed by the following approaches: 1) photography viewing the nasal structure as well as PNS CT scanning of Paranasal

sinuses before and also 1 and 6 months after surgery; 2) measuring the nasal obstruction degree by the Nasal Obstruction Symptom Evaluation (NOSE) questionnaire that is a brief questionnaire consisting of 5 self-rated items, each scored from 0 to 4 that the NOSE score represents the sum of the responses to the 5 individual items and ranges from 0 to 20, 3) assessing health status and health-related quality of life in chronic rhinosinusitis using the sino-nasal outcomes Test-22 (SNOT-22) that each item quantifies symptoms severity from 0 (no problem) to 5 (worst symptom) and the sum of each item results in a maximum score of 110, higher score indicates poorer outcome, 4) assessing the patients' satisfaction using the visual analogue scale scaled as 0 (completely dissatisfied) to 10 (completely satisfied), and 5) assessing the outcome of aesthetic rhinoplasty (the improvement of quality of life and mental image of the individual) using the OAR inventory that basically consists of two parts. The first part of the questionnaire consists of five questions and includes patient ideas concerning body appearance related to nasal view and quality of life. The patients give a point between one and five for every question (1 is the lowest and 5 is the highest). The second part of the questionnaire consists of the evaluation of the nasal view of the cases using VAS (1 means very ugly and 10 means very nice). All measurements were done before and also 1 and 6 months after intervention.

Statistical analysis

For statistical analysis, results were presented as mean \pm standard deviation (SD) for quantitative variables and were summarized by frequency (percentage) for categorical variables. Continuous variables were compared using t test or Mann-Whitney test whenever the data did not appear to have normal distribution or when the assumption of equal variances was violated across the study groups. Categorical variables were, on the other hand, compared using chi-square test. The trend of the change in study parameters was assessed by the Repeated measure ANOVA test. *P* values of ≤ 0.05 were considered statistically significant. For the statistical analysis, the statistical software SPSS version 23.0 for windows (IBM, Armonk, New York) was used.

RESULTS

Two groups of patients as the intervention group (suturing to septum alone) ($n = 25$, 10 men and 15 women) and the control group (suturing concurrent to septum and upper lateral cartilage) ($n = 25$, 9 men and 16 women) were included into our clinical trial. The two groups were similar in gender ($P = 0.224$) and age ($P = 0.456$) (Figure 1).

The mean VAS score (the satisfaction level) in the intervention and control group was 6.76 ± 1.96 and

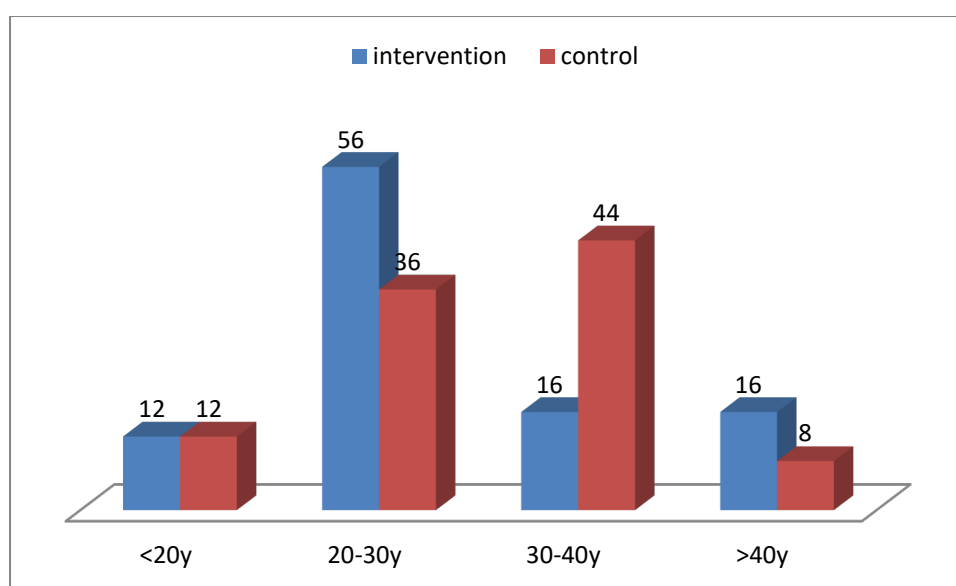


Figure 1: Age distribution in both intervention and control group

6.44±1.87 before surgery ($p = 0.245$), 8.16±1.17 and 7.76±1.23 one month after operation and 9.28±1.02 and 8.88±1.01 six months after operation respectively indicating significant increasing in the level of satisfaction within six-month following-up in both groups, as well as with significant trend of the change across the two groups ($P= 0.002$).

Assessing the SNOT-22 score in the two groups showed that the mean baseline score in the intervention and control groups was 29.56±7.13 and 29.60±7.15, 1-month score was 25.80±4.29 and 26.00±4.78 and 6-month score was 23.84±2.60 and 23.36±2.09 respectively indicating a significant downward trend in SNOT-22 score in both groups. In this regard, the trend of the change in SNOT-22 score was also different between the intervention and control group ($P = 0.008$).

The mean NOSE score at baseline as well as 1 and 6 months after operation was 19.84±9.48, 15.24±5.18 and 12.72±3.38 in intervention group and 17.60±3.38, 14.08±4.45 and 12.32±2.11 in control group respectively indicating significant decrease in both groups, but with higher decreasing in the intervention group ($P = 0.016$).

Regarding the change in OAR score within the 6 months follow-up, mean preoperative, 1-month and

6-month postoperative OAR score in intervention group was 11.92±6.36, 8.72±4.37, and 7.16±3.33 and in control group was 14.64±4.88, 10.12±3.24, and 7.32±2.13 respectively indicating significant changes in the pointed score in each group, as well as significant difference between the two group ($P = 0.001$).

As summarized in Table 1, the changes in all study parameters remained insignificant between men and women and thus gender variable did not affect the changes in the parameters. Similarly, as presented in Table 2, the changes in all study parameters were independent to patients' age.

In assessing final level of satisfaction of operation (Figure 2), in intervention and control groups, 13 and 5 patients completely satisfied, 8 and 16 partially satisfied and 4 and 4 dissatisfied of operation outcome respectively showing higher satisfaction level in the former group ($P < 0.001$).

DISCUSSION

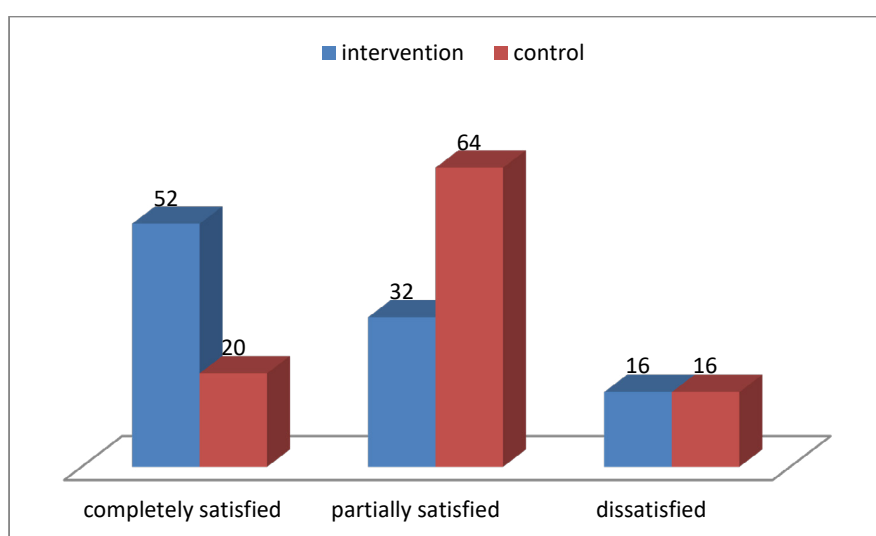
In the present interventional study, employing spreader graft technique without suturing the upper lateral cartilage led to more favorable outcome with respect to patients' satisfaction, health-related

Table 1: The change in study parameters in the two groups considering gender

Characteristics	Intervention group (n = 25)		P value	Control group (n = 25)		P value
	Women	Men		Women	Men	
VAS score			0.226			0.456
Baseline	5.33±2.63	5.20±2.39		4.43±1.82	4.77±2.33	
1 month later	7.26±1.48	8.00±1.82		6.81±1.51	7.22±0.97	
6 month later	8.26±1.43	9.00±1.63		7.81±1.60	8.22±1.39	
P value	<0.001	<0.001		<0.001	<0.001	
SNOT score			0.123			0.079
Baseline	28.13±5.66	31.70±8.78		30.68±7.57	27.66±6.26	
1 month later	25.46±4.42	26.30±4.27		26.31±4.72	25.44±5.12	
6 month later	23.60±2.72	24.20±2.52		23.12±1.74	23.79±2.46	
P value	<0.001	<0.001		<0.001	<0.001	
NOSE score			0.556			0.778
Baseline	19.20±8.71	20.80±10.95		16.43±6.87	16.66±8.94	
1 month later	15.00±4.89	15.60±5.83		13.12±2.33	14.45±3.45	
6 month later	12.20±2.17	13.50±4.69		11.81±1.37	12.26±1.12	
P value	<0.001	<0.001		<0.001	<0.001	
OAR score			0.076			0.656
Baseline	13.00±6.61	10.30±5.94		14.75±5.05	14.44±4.85	
1 month later	9.40±4.15	7.70±4.71		10.12±2.94	10.11±3.91	
6 month later	7.53±3.54	6.60±3.09		6.93±1.69	8.00±2.73	
P value	<0.001	<0.001		<0.001	<0.001	

Table 2: The change in study parameters in the two groups considering age groups

Age group	Group	VAS	OAR	SNOT-22	NOSE
<20y	Intervention				
	Preoperative	6.66±3.21	8.33±4.93	29.66±6.02	16.66±3.51
	1 month	9.00±1.00	7.00±3.46	25.33±4.16	13.66±2.51
	6 months	10.00±1.00	5.66±1.15	23.00±1.00	11.33±0.57
	Control				
	Preoperative	3.00±1.00	20.00±4.58	27.33±3.05	15.33±3.05
20-30y	Intervention				
	Preoperative	5.28±2.36	14.85±6.76	28.50±7.42	18.85±10.36
	1 month	7.42±1.55	10.42±4.79	24.92±3.75	14.71±5.84
	6 months	8.28±1.58	8.28±4.02	23.50±2.21	13.00±4.18
	Control				
	Preoperative	5.00±2.17	13.22±3.41	27.22±4.60	16.88±4.34
30-40y	Intervention				
	Preoperative	5.25±3.09	8.25±3.86	29.50±6.65	23.25±10.99
	1 month	7.75±2.62	6.75±3.50	26.00±3.26	15.50±2.51
	6 months	8.75±1.89	6.00±2.00	23.00±2.00	11.75±0.95
	Control				
	Preoperative	4.90±1.75	14.72±5.67	31.09±9.24	18.36±11.20
>40y	Intervention				
	Preoperative	4.25±2.36	8.00±1.82	23.25±9.24	22.25±9.32
	1 month	6.75±0.50	6.00±1.15	29.00±6.83	18.00±6.48
	6 months	8.25±1.25	5.55±0.57	26.50±4.12	13.75±3.09
	Control				
	Preoperative	3.00±2.82	12.50±0.70	35.50±4.94	2.00±9.89
	1 month	6.00±1.41	9.00±1.41	27.00±1.41	15.00±4.24
	6 months	7.00±1.41	7.50±0.70	23.50±0.70	11.50±0.70

**Figure 2:** Postoperative satisfaction level in both intervention and control group

quality of life, obstructive symptoms, and overall outcome of aesthetic rhinoplasty regarding mental image of the individual as compared to suturing septum and upper lateral cartilage.

In other words, both subjective and objective parameters improved more in suturing to septum alone within 6 months of selective rhinoplasty. In fact, considering suturing the upper lateral cartilage might not be necessary to improve operation-related outcome following rhinoplasty and thus considering new technique with less invasive nature can result in significantly more improvement in different outcome postoperative dimensions.

However, it should be noted that in both new and classic procedures, significant improvement in both appearance and functional features occurred within 6 months of initial procedures. Upper lateral cartilage plays an essential role in rhinoplasty and manages the length and rigidity of the upper lateral cartilage in relation to the septum valve function. In this regard, it seems that suturing graft to septum alone without suturing to upper lateral cartilage seems to be helpful and suture only to septum is enough to achieve proper nasal functional status, higher patients' satisfaction level and ultimately higher patients' quality of life.

With the aim of achieving more appropriate postoperative results, procedural techniques have been considerable modified in recent years. For instance, as indicated by Wurm et al ¹¹, flaring spreader flaps along with the upper lateral advancement technique represented reliable methods in the reconstruction of the internal nasal valve and treatment of inverted-V deformities. In a study by Manavbaşı et al ¹², the bridging suture technique using cephalic extensions of the upper lateral cartilage is an improvement of the spreader flap technique to obtain a straight, smooth, and single-unit dorsum in rhinoplasty patients. As shown by Erickson et al in 2016 ¹³, This study provides an agreement of objective measurement of internal nasal valve function, endonasal cartilagenous spreader grafts in combination with septoplasty and inferior turbinoplasty has been shown to be safe procedure in patients suffering nasal obstruction with internal nasal valve collapse.

Our described technique in line with the techniques introduced previously could improve postoperative

consequences in both subjective and objective post procedural measurements.

CONCLUSION

As the final conclusion, in patients scheduling for selective rhinoplasty, new procedural technique including spreader graft without suturing to upper lateral cartilage can lead to more postoperative favorable outcome with regard to patients' satisfaction of the procedure, lack of obstructive symptoms, aesthetic feature, and health-related quality of life as compared to suturing to both septum and upper lateral cartilage.

ACKNOWLEDGMENTS

With thanks from professors of department of Plastic Surgery, Educational Hospital of 15th Khordad, Shahid Bheshti University, Tehran, Iran.

This Paper extracted from Mohadeseh Amini Student Thesis with 29 Thesis ID in Shahid Beheshti Medical Science University.

CONFLICT OF INTEREST

The authors declare that there is no conflict of interests.

REFERENCES

1. Fichman M, Piedra Buena IT. *Rhinoplasty* 2022, StatPearls Publishing, Treasure Island (FL). PMID: 32644396.
2. Macionis V. History of plastic surgery: Art, philosophy, and rhinoplasty. *J Plast Reconstr Aesthet Surg* 2018; **71**:1086-92. doi: 10.1016/j.bjps.2018.03.001
3. Ho OYM, Ku PKM, Tong MCF. Rhinoplasty outcomes and trends. *Curr Opin Otolaryngol Head Neck Surg* 2019; **27**:280-286. doi: 10.1097/MOO.0000000000000554
4. Kantas I, Balatsouras DG, Vafiadis M, Apostolidou MT, Korres S, Danielidis V. Management of inner nasal valve insufficiency. *J Otolaryngol Head Neck Surg* 2008;**37**(2):212-218.
5. Samaha M, Rassouli A. Spreader graft placement in endonasal rhinoplasty: Technique and a review of 100 cases. *Plast Surg* 2015; **23**:252-254. doi:10.4172/plastic-surgery.1000944
6. Sazgar AA, Razmara N, Razfar A, Sazgar AK, Amali

- A. Outcome of rhinoplasty in patients undergoing autospreader flaps without notable dorsal hump reduction: A clinical trial. *J Plast Reconstr Aesthet Surg* 2019;**72**: 1688-1693. doi: 10.1016/j.bjps.2019.06.022
7. Teymoortash, A., Fasanla, J.A. and Sazgar, A.A. The value of spreader grafts in rhinoplasty: a critical review. *European Archives of Oto-Rhino-Laryngology* 2012; **269**:1411-1416. doi: 10.1007/s00405-011-1837-y.
 8. Yeung A, Hassouneh B, Kim DW. Outcome of Nasal Valve Obstruction After Functional and Aesthetic-Functional Rhinoplasty. *JAMA Facial Plast Surg* 2016;**18** :128-134. doi:10.1001/jamafacial.2015.1854
 9. Albergo L, Desio E, Revelli VE, Acosta MB. Spreader Graft for Severe Deviation of Nasal Septum with Obstruction of the Internal Nasal Valve: Clinical and Functional Results. *Facial Plast Surg* 2020;**36** :635-642. doi:10.1055/s-0040-1713794
 10. Manavbaşı YI, Başaran I. The role of upper lateral cartilage in dorsal reconstruction after hump excision: section 1. Spreader flap modification with asymmetric mattress suture and extension of the spreading effect by cartilage graft. *Aesthetic Plast Surg* 2011; **35**:487-493. doi:10.1007/s00266-010-9641-4
 11. Wurm J, Kovacevic M. “Flaring spreader flaps” und “upper lateral advancement”. Modifizierte Techniken zur Rekonstruktion der inneren Nasenklappe [Flaring spreader flaps and upper lateral advancement. Modified techniques in the reconstruction of the internal nasal valve]. *HNO* 2012; **60**:597-604. doi:10.1007/s00106-011-2427-4
 12. Manavbaşı YI, Kerem H, Başaran I. The role of upper lateral cartilage in correcting dorsal irregularities: section 2. The suture bridging cephalic extension of upper lateral cartilages. *Aesthetic Plast Surg* 2013; **37**:29-33. doi:10.1007/s00266-012-9967-1
 13. Erickson B, Hurowitz R, Jeffery C, et al. Acoustic rhinometry and video endoscopic scoring to evaluate postoperative outcomes in endonasal spreader graft surgery with septoplasty and turbinoplasty for nasal valve collapse. *J Otolaryngol Head Neck Surg* 2016; **45**:2. doi:10.1186/s40463-016-0115-9