

# A Rare Case of Orthokeratinized Odontogenic Cyst (OOC) in the Posterior Mandible of a Young Adult 18-Year-Old Boy

Masoud Torkzadeh <sup>1</sup>, Zahra Jafari <sup>2</sup>, Ali Labafchi <sup>3</sup>, Alireza Shirzadeh <sup>4</sup>,  
Nooshin Mohtasham <sup>5</sup>, Bahar Khatibi <sup>2</sup>, Sahand Samieirad <sup>4\*</sup>

1. Oral and Maxillofacial Surgery, Student Research Committee, Faculty of Dentistry, Mashhad University of Medical Science, Mashhad, Iran.
2. Student Research Committee, Faculty of Dentistry, Mashhad University of Medical Sciences, Mashhad, Iran.
3. Faculty of Dentistry, Mashhad University of Medical Sciences, Mashhad, Iran
4. Oral and Maxillofacial Surgery Department, Mashhad Dental School, Mashhad University of Medical Sciences, Mashhad, Iran.
5. Oral and Maxillofacial Pathology Department, Mashhad Dental School, Mashhad University of Medical Sciences, Mashhad, Iran.

## ABSTRACT

Orthokeratinized Odontogenic Cyst (OOC) is a rare odontogenic cyst, which is important because it has a low recurrence potential, but it has a percentage of the potential for malignant changes. OOC characteristics can be different from OKC (odontogenic keratocyst), which was once classified in its category. The microscopic view of OOC cyst is the reason for its easy identification from OKC, the orthokeratinized epithelial covering and the clear granular layer, and the hyperplasia of the basal layer, and the smooth surface of this cyst. OOC cyst treatment is conservative and can be usually carried out by enucleation. In terms of gender predominance, it is often reported in men. Furthermore, OOC is more common in the 3rd and 4th decades of life. Hereby, we report a rare case of OOC in the posterior mandible of a young adult 18-year-old boy and its treatment method. The clinical and diagnostic points of view and the treatment options were discussed in this article.

## KEYWORDS

OOC (Orthokeratinized Odontogenic Cyst); OKC; treatment, diagnosis

## Please cite this paper as:

Torkzadeh M, Jafari Z, Labafchi A, Shirzadeh A, Mohtasham N, Khatibi B, Samieirad S. A Rare Case of Orthokeratinized Odontogenic Cyst (OOC) in the Posterior Mandible of a Young Adult 18-Year-Old Boy. *World J Plast Surg.* 2023;12(1):80-85.  
doi: 10.52547/wjps.12.1.80

## INTRODUCTION

The description of odontogenic keratocyst (OKC) as an entity dates back to 1956 by Phillippsen <sup>1-5</sup>, it is one of the developmental odontogenic cysts and is considered one of the common cysts of the oral cavity <sup>3</sup>. About 11% of the cystic lesions of the oral cavity are OKC <sup>3, 6</sup>. In the past years, different natures have been attributed to it. First, until 2005, it was considered an odontogenic cyst in the WHO category, but due to its high invasion and significant recurrence rate, and its connection with the PTCH gene mutation, during the years 2005 to 2017, it was classified as an odontogenic tumor and again in 2017, it returned to the category of cystic lesions due to insufficient evidence of being a tumor <sup>1, 7, 8</sup>. Orthokeratinized Odontogenic Cyst (OOC) is a rare developmental odontogenic cyst <sup>3, 9-11</sup>, arising from the remnants of the dental lamina <sup>3, 5, 9-13</sup>. Schultz in 1927 first recognized OOC as a dermoid cyst <sup>10, 12</sup>. Phillippsen in 1945 remarked it as a variant of Odontogenic Keratocyst

## \*Corresponding Author:

Sahand Samieirad

Associate Professor, Oral and Maxillofacial Surgery Department, Mashhad Dental School, Mashhad University of Medical Sciences, Mashhad, Iran.

Tel.: +98912 8137859

Email: [samieerads@mums.ac.ir](mailto:samieerads@mums.ac.ir)

Received: 01/01/2023

Accepted: 04/03/2023



This work is licensed under a Creative Commons Attribution-NonCommercial 4.0 International license (<https://creativecommons.org/licenses/by-nc/4.0/>). Non-commercial uses of the work are permitted, provided the original work is properly cited.

(OKC)<sup>2</sup>. Wright in 1981 considered it as an independent entity<sup>10-12</sup> and then various titles were attributed to it, but later, Li et al. in 1998 proposed the title of orthokeratinized cystic lesion, which is still acceptable today<sup>9,10</sup>.

Among its histopathological features, one of the things that plays a role in differentiating it from other lesions such as OKC whose covering is parakeratinized, is its orthokeratinized epithelial covering<sup>5,9-11</sup>.

Although high recurrence is a common feature of OKC<sup>1, 2, 4-6, 8, 10-12</sup>; the recurrence rate of OOC is low<sup>5, 9-13</sup> and there is no need for invasive methods for treatment, and OOC can be treated with conservative methods, resulting in fewer and undesirable complications for the patient<sup>11</sup>.

Though the tendency of OKC to become malignant is considered unlikely<sup>12</sup>, the tendency of OOC to become malignant is more, this characteristic of OOC is very worthy of attention due to the difference in treatment and prognosis of a malignant lesion. Unlike OKC, OOC is not related to Gorlin-Gotz syndrome, which is characterized by multiple OKCs<sup>10-12, 14</sup>.

Like some other oral lesions, it is often detected accidentally in routine dental imaging<sup>10</sup>. From the point of view of radiography, one of the special features of OOC is here, which would also be used in its differential diagnosis, is that it does not give root resorption<sup>10</sup>. Also, like OKC, it is often has been reported in the lower jaw<sup>9,10,12</sup>. In terms of gender predominance, it is often reported in men<sup>3,9-11</sup>. The occurrence of OOC was observed more in the 3rd and 4th decades of life<sup>10,11</sup>, on the contrary, the case reported in this article was 18 years old.

Hereby, we report a rare case of OOC in the posterior mandible of a young adult 18-year-old boy and its treatment method. The clinical and diagnostic points of view and the treatment options were discussed in this article.

## CASE PRESENTATION

All procedures performed in this study involving the human participant were in accordance with the ethical standards of our institutional research committee and with the 1964 Helsinki declaration. The patient's ethical consent form was signed and approved by the patient. This study was approved by the Ethics and Research Committee of Mashhad

University of Medical Sciences (IR.MUMS.REC.1401.217).

An 18-year-old male with the chief complaint of swelling of the posterior left mandible was referred to the Oral and Maxillofacial Department of Mashhad Dental School, Mashhad University of Medical Sciences, Iran, in February 2022.

The patient had no history of systemic diseases. All laboratory tests were within normal ranges. No history of bleeding or pus discharge from the lesion was observed.

In intraoral clinical examination, no mobility of teeth was noted. However, the displacement of left lower second and third molar teeth and swelling of the posterior mandible was observed. Extra-orally, no lymphadenopathy or inflammation was observed.

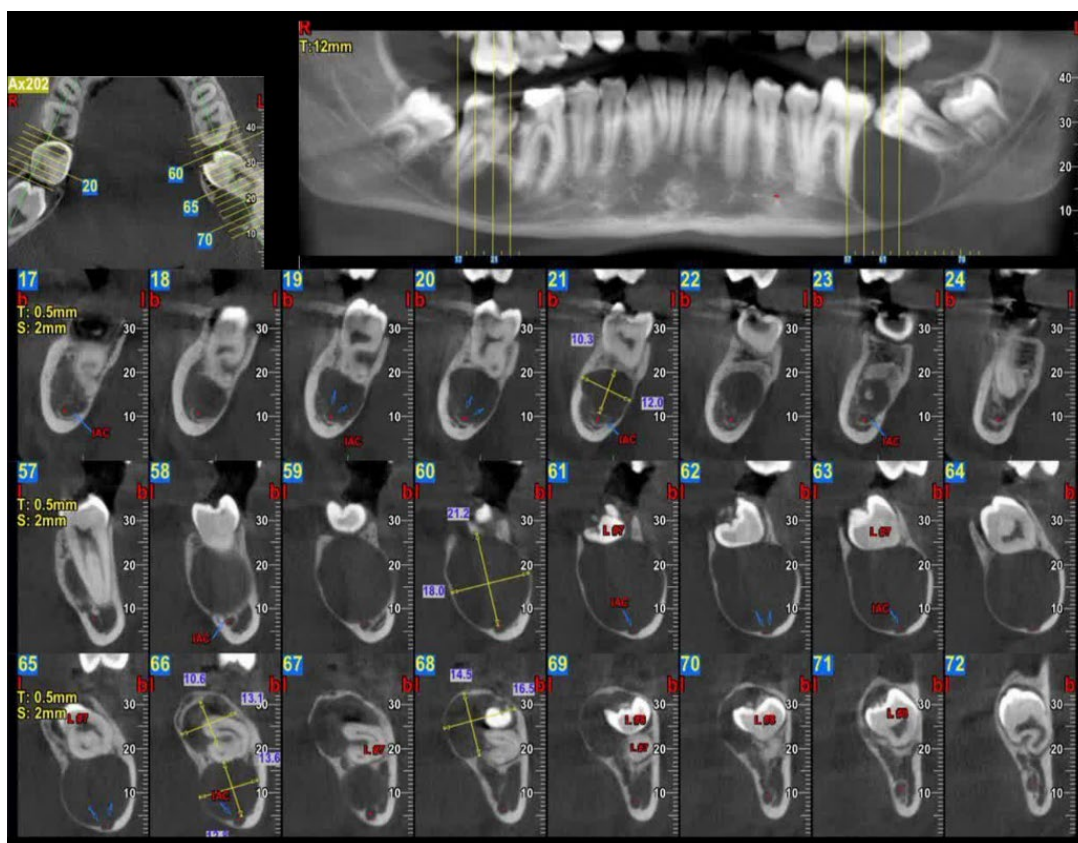
In the radiography, the presence of two multilocular radiolucencies with corticated margins, situated between 1st molar and posterior region of 2nd molar in the ramus of both left and right sides of the mandible was detected. The inferior alveolar nerve (IAN) had displaced inferiorly. The lesion on the left side was larger, and had caused root movement of the left 2nd and 3rd molars. (Figure 1) Cone beam computed tomography (CBCT) showed buccolingual expansion (Figure 1).

Differential diagnoses of this case include cysts like OKC, dentigerous cyst, COC, and malignant lesions like osteosarcoma and chondrosarcoma.

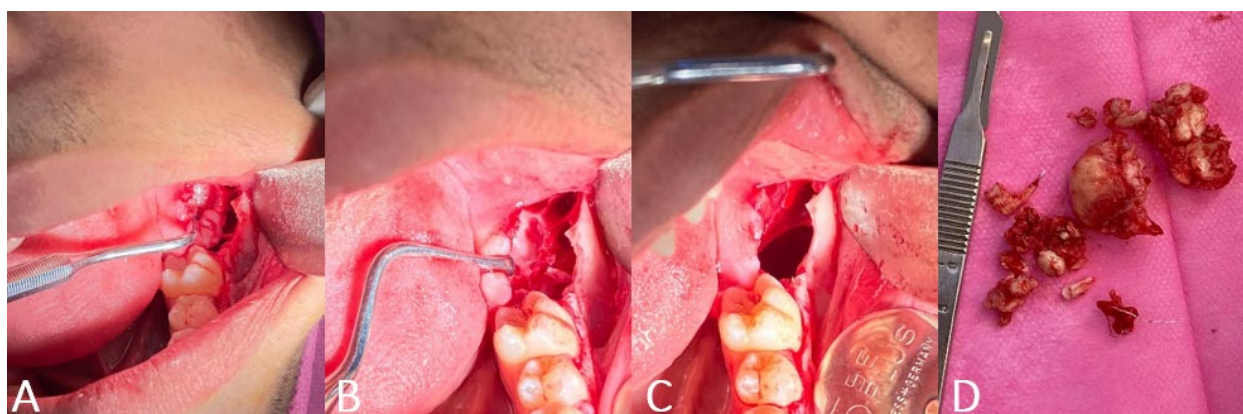
The surgery was performed under local anesthesia (Lidocaine 2% with 1:80000 epinephrine (Daropakhsh, Tehran, Iran)). A sulcular incision was made from the left second premolar to the posterior crestal ridge of the third molar region, using two releasing incisions. The flap was elevated subperiosteally and access to the bone was extensively established. Good access to the cyst was happened by removing the impacted second and third molar teeth. It was interesting that after the teeth were removed, a cheesy white liquid came out, which indicated that it was an odontogenic keratocyst. The sample of the lesion was completely removed and sent to the laboratory. The Inferior alveolar nerve was not damaged during surgery and was preserved.

Finally, the flap was sutured with Vicryl 3/0 (Supa, Tehran, Iran) in a tension-free manner (Figure 3).

After the operation, the lesion was submitted for a thorough histopathological examination



**Figure 1:** CBCT view showed two multilacunar radiolucent lesions on both sides of the posterior mandible.



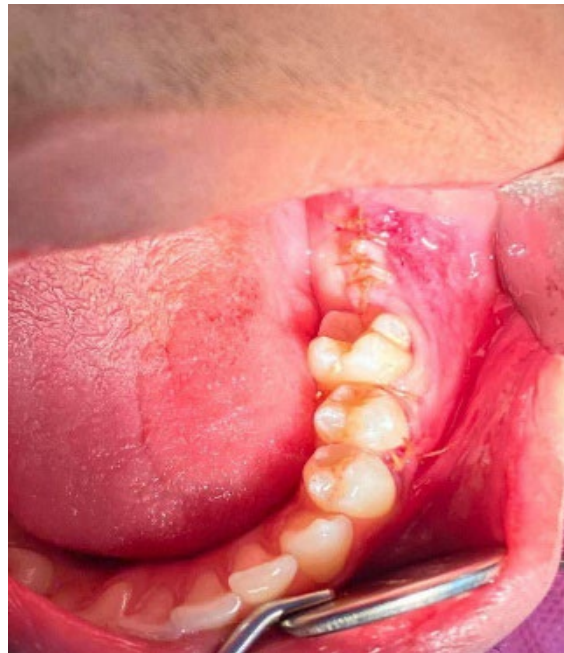**Figure 2:** A) View part of the tumor in posterior mandible, B) The multilocularity of the tumor can be seen well, C) Tumor enucleation, D) Macroscopic view of the tumor mass.

using Hematoxylin and Eosin staining. The histopathological analysis confirms the diagnosis of Orthokeratinized Odontogenic Cyst (OOC) in this case. Under light microscope evaluation with a magnification of 200 X, odontogenic epithelium which was stratified squamous and uniform was seen. In the lumen of cyst, layers of keratin were seen. This

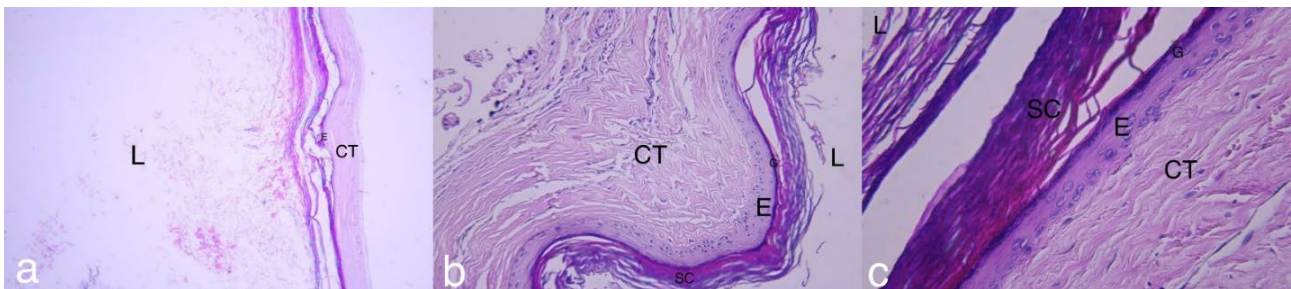
is an orthokeratinized pattern which means nuclei aren't seen in keratin. Under the stratum corneum, stratum granulosum was seen (Figure 4).

The patient had no problem or recurrence during the 6-month follow-up sessions. Unfortunately, he did not attend for another mandibular side pathologic lesion treatment, due to Covid-19 infection.





**Figure 3:** After surgical enucleation, the flap was sutured with vicryl 3/0 (Supa, Tehran, Iran).



**Figure 4:** Histopathologic feature (H&E staining). a)40 X, b)200 X and c)400 X magnification under microscope; L: lumen, E: epithelium, CT: connective tissue, G: stratum granulosum, SC: stratum corneum.

## DISCUSSION

OOC (orthokeratinized odontogenic cyst) originates from the cellular remains of the dental lamina, and is one of the developmental cysts of the jaw with a low incidence<sup>3,9-11</sup>.

Shultz recognized OOC for the first time in 1927<sup>10, 12</sup>, and Wright separated it from OKC in 1981<sup>10-12</sup>. According to the WHO classification, OOC has been considered as an independent lesion from OKC for several years<sup>3,5,9-13</sup>.

Microscopically, it has an orthokeratinized epithelial covering, that is, a clear granular layer can be seen on the surface and keratin strands inside the lumen. In fact, the granular layer and keratin strands are not seen in the OKC epithelial cover, and hence it is called parakeratinized<sup>5,9-11</sup>.

Both of these lesions have been seen more in the lower jaw<sup>5,9-12</sup>, as in our case, OOC was found in the lower jaw.

Among the studies, in one the superiority of one gender in the occurrence of OOC is not relevant<sup>12</sup>; however, in other literature, men were often involved with OOC<sup>3,5,9-11</sup>.

The most common age of occurrence of this cyst is the 2nd, 3rd, 4th and 5th decades<sup>3,9-12</sup>. Although in most of the presented cases, the age period was in the 3rd and 4th decades<sup>9-11</sup>, our case was interestingly an 18-year-old boy.

The most common symptom of OOC is swelling, our case also had a chief complaint of swelling. In some cases, pain is also mentioned as a symptom of OOC. However, most of the cases usually had no symptoms<sup>11,12</sup>, so cyst identification occurs during

routine diagnostic images<sup>10</sup>.

OOC might be unilocular or multilocular in the radiographic view, and it is diverse in different cases. Resercers considered the probability of each occurrence to be equal<sup>10</sup>, but in two other studies, unilocular characteristics prevailed over multilocular<sup>9, 11</sup>, and interestingly, our case was multilocular.

As it is clear in the radiograph view of OOC reported by this article, the cyst is associated with impacted teeth (second and third molars); there are controversies in different articles regarding the association of this cyst with impacted teeth<sup>9-11</sup>.

In the present case, OOC caused the displacement of the inferior alveolar nerve, which was reported to occur in some cases<sup>10</sup>. Unlike ameloblastoma and OKC, OOC does not cause root resorption<sup>10, 11</sup>, which can be seen in our case.

The treatment plan of OOC in this article was enucleation, and complete removal of the cyst, as well as the surgical extraction of impacted teeth. Due to the low recurrence of OOC<sup>5, 9-13</sup>, its treatment plan is conservative and enucleation is the recommended method<sup>10, 11</sup>. However, OOC has a greater tendency to become malignant than OKC. So it requires more attention from experts and oral and maxillofacial surgeons to accurate follow-ups, as well as the careful diagnosis and separation of this cyst from OKC, based on clinical and microscopic differences.

## CONCLUSION

Regarding the rare incidence and high potential of malignancy, the OOC clinical and diagnostic points of view, as well as, the treatment plans and accurate follow-ups are very important to oral and maxillofacial surgeons.

## ACKNOWLEDGMENTS

The authors would like to thank the Research and Technology Vice-Chancellor of Mashhad Faculty of Dentistry and Student Research Committee of Mashhad University of Medical Sciences for their cooperation. This study was self-funded.

## CONFLICTS OF INTEREST

None declared.

## REFERENCES

- Mohanty S, Dabas J, Verma A, Gupta S, Urs AB, Hemavathy S. Surgical management of the odontogenic keratocyst: A 20-year experience. *Int J Oral Maxillofac Surg* 2021 Sep;**50**(9):1168-76.
- Bande CR, Prashant MC, Sumbh B, Pandilwar PK. Prevalence, treatment and recurrence of odontogenic keratocyst in central India. *J Maxillofac Oral Surg* 2010 Jun;**9**(2):146-9.
- Ravi J, Wadhwan V, Gotur SP. Orthokeratinized versus parakeratinized odontogenic keratocyst: Our institutional experience. *J Oral Maxillofac Pathol* 2022 Jan-Mar;**26**(1):60-4.
- Gupta A, Bansal P, Sharma R, Sharma SD. Treatment of Keratocystic Odontogenic Tumours: A Prospective Study of 30 Cases. *J Maxillofac Oral Surg* 2016 Dec;**15**(4):521-7.
- Li TJ, Kitano M, Chen XM, et al. Orthokeratinized odontogenic cyst: a clinicopathological and immunocytochemical study of 15 cases. *Histopathology* 1998 Mar;**32**(3):242-51.
- Borrás-Ferreres J, Sánchez-Torres A, Alberdi-Navarro J, Aguirre-Urizar JM, Mosqueda-Taylor A, Gay-Escoda C. Therapeutic management of the odontogenic keratocyst. An energetic approach with a conservative perspective and review of the current therapeutic options. *J Clin Exp Dent* 2020 Aug;**12**(8):e794-e9.
- Jung HD, Lim JH, Kim HJ, Nam W, Cha IH. Appropriate follow-up period for odontogenic keratocyst: a retrospective study. *Maxillofac Plast Reconstr Surg* 2021 Jul 1;**43**(1):16.
- Consolo U, Setti G, Tognacci S, Cavatorta C, Cassi D, Bellini P. Histological changes in odontogenic parakeratinized keratocysts treated with marsupialization followed by enucleation. *Med Oral Patol Oral Cir Bucal* 2020 Nov 1;**25**(6):e827-e33.
- Dong Q, Pan S, Sun LS, Li TJ. Orthokeratinized odontogenic cyst: a clinicopathologic study of 61 cases. *Arch Pathol Lab Med* 2010 Feb;**134**(2):271-5.
- González Galván Mdel C, García-García A, Anitua-Aldecoa E, Martínez-Conde Llamosas R, Aguirre-Urizar JM. Orthokeratinized odontogenic cyst: a report of three clinical cases. *Case Rep Dent* 2013;**2013**:672383.
- Kamat M, Kanitkar S, Datar U, Byakodi S. Orthokeratinized odontogenic cyst with calcification: A rare case report of a distinct entity. *J Oral Maxillofac Pathol* 2018 Jan;**22**(Suppl 1):S20-s3.

12. da Silva MJ, de Sousa SO, Corrêa L, Carvalhosa AA, De Araújo VC. Immunohistochemical study of the orthokeratinized odontogenic cyst: a comparison with the odontogenic keratocyst. *Oral Surg Oral Med Oral Pathol Oral Radiol Endod* 2002 Dec;**94**(6):732-7.
13. Macdonald-Jankowski DS. Orthokeratinized odontogenic cyst: a systematic review. *Dentomaxillofac Radiol* 2010 Dec;**39**(8):455-67.
14. Peighoun M, Samieirad S, Mohtasham N, Tohidi E, Moeini S. Surgical Ciliated Cyst of the Posterior Maxilla in an Old Male, Mimicking Residual Cyst or Odontogenic Keratocyst: A Case Report. *World J Plast Surg* 2022 Mar;**11**(1):132-7.