

# Schwannoma of Posterior Interosseous Nerve: A Case Report and Review of Literature

Navneet Sharma<sup>1</sup>, Shilpi Karmakar<sup>1\*</sup>, Lokesh Rana<sup>2</sup>, Umesh Dhiman<sup>3</sup>

1. Department of Burns and Plastic Surgery, All India Institute of Medical Sciences, Jodhpur, India.
2. Department of Radiology, All India Institute of Medical Sciences, Bilaspur, Himachal Pradesh, India.
3. Department of Surgery, Dr. Rajinder Prasad Government Medical College, Tanda, Himachal Pradesh, India.

## ABSTRACT

Schwannomas constitute only 5% of tumors of upper limb. Schwannoma of the posterior interosseous nerve is rare. A thorough search of literature revealed only three case reports of this entity. A 33-year old female presented with insidious onset swelling over extensor aspect of right forearm for one year and deficit of extension of fourth and fifth finger for a month. Magnetic Resonance Imaging and Fine Needle Aspiration Cytology were suggestive of low- grade nerve sheath tumor. The tumor was excised under tourniquet control and magnification, using microsurgical technique. Histopathology confirmed schwannoma. Result. Patient regained her full extension of fourth and fifth finger within 1.5 months. As schwannoma does not infiltrate the nerve fibers, so a complete surgical excision is the treatment of choice. We wrote this article to draw clinicians' attention to this unusual entity. Schwannoma of PIN is a relatively rare condition. Till date, there are only three cases reported in literature. Meticulous attention to detail is required while excising large schwannomas, as there is a risk of fascicular injury during dissection. Use of magnification and microsurgical technique prevents inadvertent nerve injury.

## KEYWORDS

Schwannoma; Soft tissue neoplasms; Tumour; Extension

## Please cite this paper as:

Sharma N, Karmakar S, Rana L, Dhiman U. Schwannoma of Posterior Interosseous Nerve: A Case Report and Review of Literature. *World J Plast Surg.* 2023;12(1):86-89.  
doi: 10.52547/wjps.12.1.86

## \*Corresponding Author:

Dr. Shilpi Karmakar

Assistant Professor,

Department of Burns and Plastic Surgery, OPD room 403, All India Institute of Medical Sciences, Jodhpur, Rajasthan, India - 342005.

## Email:

[drshilpikarmakar@rediffmail.com](mailto:drshilpikarmakar@rediffmail.com)

Received: 01/01/2023

Accepted: 04/03/2023

## INTRODUCTION

Schwannoma, also known as neurilemoma, originate from schwann cells<sup>1</sup>. More commonly affected nerves are median and ulnar<sup>1</sup>. Schwannoma of the posterior interosseous nerve (PIN) is almost unheard of. A thorough search of literature revealed only three case reports of this entity<sup>1-3</sup>. We share the clinical information of a young woman, who presented with swelling in proximal forearm and weakness in finger extension.

## CASE REPORT

A 33 year old female presented with insidious onset swelling over extensor aspect of right forearm for last one year, which was painless and progressively increasing in size. For the last one month, there was



This work is licensed under a Creative Commons Attribution-NonCommercial 4.0 International license (<https://creativecommons.org/licenses/by-nc/4.0/>). Non-commercial uses of the work are permitted, provided the original work is properly cited.

development of deficit of extension of fourth and fifth finger (Figure 1). Examination revealed single, non-tender, firm, non-mobile and smooth-surfaced swelling of size approximately 4x3 centimeter over extensor aspect in proximal forearm.

There was no sensory loss. Tinel's sign was absent. Magnetic Resonance Imaging (MRI) demonstrated oval-shaped mass in posterior compartment of forearm, measuring 5.4x3.5x3 centimeter, which was heterogeneous but predominantly hyperintense in both T1-weighted and proton density-weighted images. (Figure 2) Split fat sign and fascicular sign was present. This was suspicious for peripheral nerve sheath tumour (one of the types of which, is schwannoma) (Figure 2). The mass was noted to be compressing the PIN within the interosseous space. Fine Needle Aspiration Cytology was suggestive of low-grade nerve sheath tumor.

The work has been performed at Department of Burns and Plastic Surgery, All India Institute of Medical Sciences, Bilaspur, Himachal Pradesh, India. Informed consent was taken for surgery, photography and publication of photographs. Surgery was performed under brachial block with tourniquet control and loupe magnification. A curvilinear incision was applied over swelling. The muscles were retracted. The tumour and the nerve was exposed. (Figure 3) The tumor was seen abutting the PIN. The tumor was enveloped by a true capsule which consisted of the perineurium of the nerve and condensed epineurium. Gentle dissection between the planes of the tumor capsule and the epineurium,

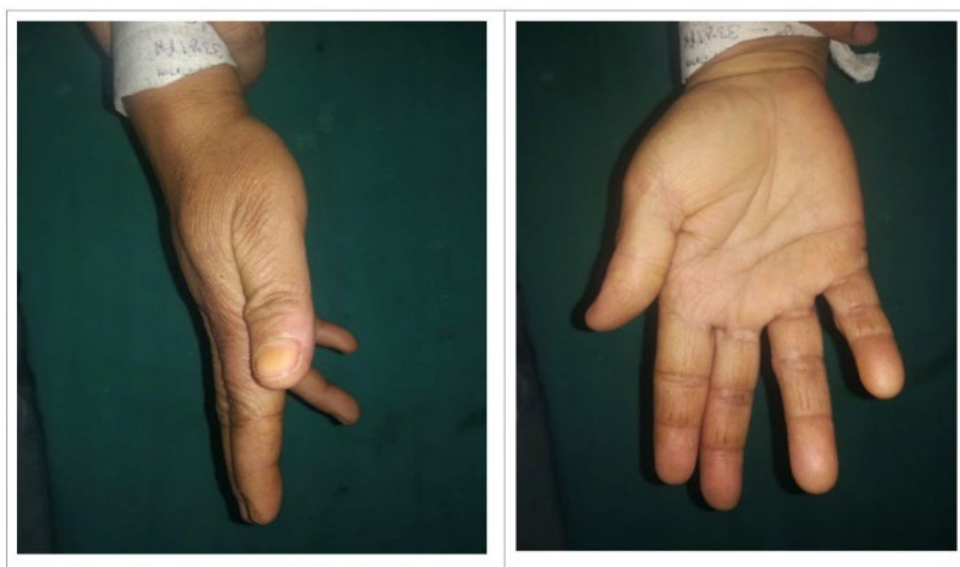
using microsurgical technique, allowed the tumor to be shelled out as a whole without disturbing the nerve fascicles (Figure 4a, 4b). Tourniquet was deflated and hemostasis was achieved. Closure was done in layers. Recovery of patient was uneventful. Patient regained her full strength of extension of fourth and fifth finger within 1.5 months.

Histopathology examination of the excised tissue exhibited cell arrangement in hypercellular (Antony A) and hypocellular (Antony B) patterns along with hyalinized vessels with features suggestive of schwannoma. The patient has now been followed for more than two years and there are no signs of recurrence.

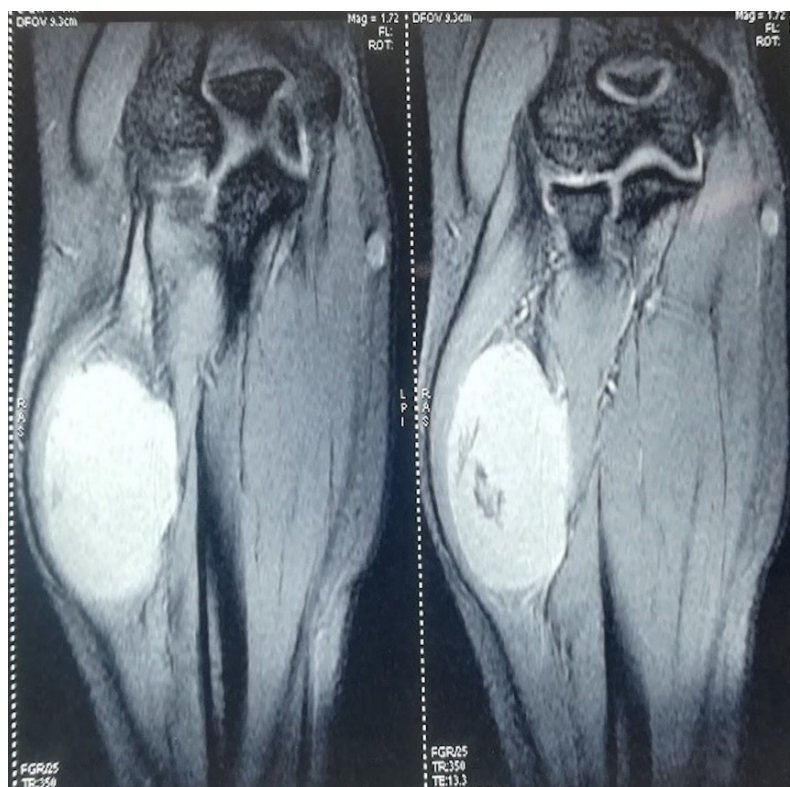## DISCUSSION

Among tumors of the upper limb, the incidence of schwannoma is only 5%<sup>4</sup>. Schwannoma has higher incidence on flexor aspect of upper limb, probably due to higher concentration of nerve fibers in this region as compared to extensor surface<sup>4</sup>. The most commonly affected nerves are ulnar and median nerves, with relative sparing of radial nerve. PIN palsy due to compression by schwannoma is a rare phenomenon.

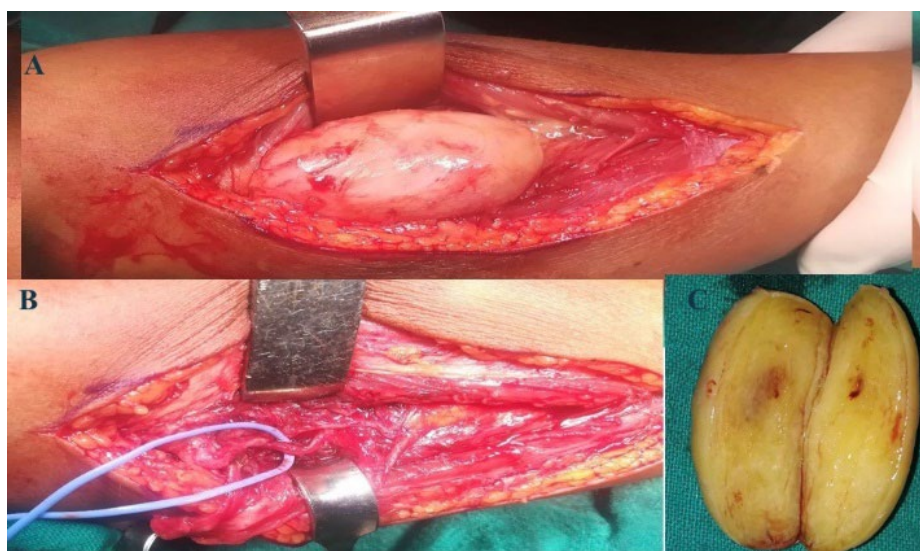
PIN palsy due to compression at arcade of Frohse or trauma are commoner causes<sup>1</sup>. The likelihood of PIN palsy occurring secondary to a tumor is relatively less. PIN palsy has been previously reported secondary to some soft tissue tumor, but, to the best of our knowledge, there has been only three



**Figure 1:** Preoperative picture, showing weak extension of fourth and fifth metacarpophalangeal joints.



**Figure 2:** Magnetic Resonance Imaging coronal proton density-weighted images, showing a well-defined, heterogenous, predominantly hyperintense signals in lesion of 5.5 x 3.5 x 3 centimeter in posterolateral right forearm, dissecting the inter-muscular planes.



**Figure 3:** a. Intraoperative picture, showing the tumors displacing muscles laterally. b. Intraoperative picture, showing preserved PIN (held by loop) after tumors is dissected out. c. Cut section of the tumors. The tumour was well encapsulated and extra-capsular dissection was possible.

prior reports of a schwannoma causing PIN palsy<sup>1-3</sup>. As these are slow growing benign lesion, hardly any symptoms appear in early period. As the size increases, symptoms become apparent<sup>2</sup>. Also, the slow-growing nature of tumor allows nerve fibers to

adapt themselves to pressure effect, so there is further delay in presentation of the patient to health facility<sup>5</sup>. In our case too, tumor grew to a significant size before producing any symptoms. In the case reported by Ichikawa et al, the lesion came to the attention of the

patient, when he developed impairment of extension of metacarpophalangeal joints, without any sensory disturbance<sup>1</sup>. In the case reported by Tadros et al, the lesion came to light earlier, as the patient was under treatment of an unrelated condition<sup>2</sup>.

As PIN is a purely motor nerve, so symptoms vary from mild to severe degrees of weakness in thumb and fingers extension. Wrist extension is relatively spared, as extensor carpi radialis longus is supplied by the radial nerve<sup>6</sup>. Tinel's sign is indicative of varying degrees of axonal discontinuity or disruption. In our case, there was weakness of extension of fourth and fifth fingers, but Tinel's sign was absent. The injury was neurapraxia (according to Seddon classification) and there was full recovery of all neurological deficits within a short span of six weeks<sup>7</sup>. Ichigawa's patient recovered full range of motion in six months, after excision in toto.<sup>1</sup> Tadros et al closely monitored their patient, as he had no significant signs<sup>2</sup>. Schwannoma is frequently misdiagnosed before surgery as neurofibroma, ganglion, or xanthomatous giant cell tumor<sup>2</sup>. MRI is useful for demonstrating the origin and the tumors' relationship to surrounding structures. Visualisation of a nerve entering or exiting the mass allows distinction from other soft tissue tumors<sup>3</sup>. However, MRI is insufficient for distinguishing between schwannoma and neurofibroma, both of which are peripheral nerve sheath tumor, and final diagnosis must rest on histopathology<sup>1</sup>.

As schwannoma does not infiltrate the nerve fibers, so a complete surgical excision is the treatment of choice<sup>8</sup>. In this case, the tumor was carefully dissected free from PIN and whole tumor was excised along with its capsule. Literature is unanimous as to the superiority of extracapsular excision over intracapsular excision, as long as all nerve fibers can be preserved<sup>8</sup>.

## CONCLUSION

Schwannoma of PIN is a relatively rare condition. Till date, there are only three cases reported in literature. Meticulous attention to detail is required

while excising large schwannomas, as there is a risk of fascicular injury during dissection. Use of magnification and microsurgical technique prevents inadvertent nerve injury. We wrote this article to draw clinicians' attention to this unusual entity.

## ACKNOWLEDGMENTS

No financial support was received for this study.

## CONFLICT OF INTEREST

The authors do not have any potential conflicts of interest with respect to this manuscript.

## REFERENCES

- 1) Ichikawa J, Sato E, Haro H, Anayama S, Ando T, Hamada Y. Posterior Interosseous nerve palsy due to schwannoma: case report. *J Hand Surg Am* 2008;**33**:1525-1528. doi:10.1016/j.jhsa.2008.05.033.
- 2) Tadros AS, O'Boyle MK, Chen KC. Schwannoma of the posterior interosseous nerve. *Ultrasound Q* 2016;**32**:376-379. doi:10.1097/RUQ.0000000000000221.
- 3) Terlemez R, Palamar D, Doğu B, Yilmaz F, Kuran B. Nadir görülen bir önkol ağrısı nedeni: Posterior interosseöz sinir Schwannomu [A rare cause of forearm pain: Schwannoma of the posterior interosseous nerve]. *Agri* 2018;**30**(2):99-101. doi:10.5505/agri.2016.04127.
- 4) Tang CYK, Fung B, Fok M, Zhu J. Schwannoma in the upper limbs. *BioMed Res Int* 2013;**2013**:167196. doi:10.1155/2013/167196. Epub 2013 Sep 4
- 5) Boufettal M, Azouz M, Rhanim A, Abouzahir M, Mahfoud M, Bardouni AE, Berrada MS, Yaacoubi ME. Schwannoma of the median nerve: diagnosis sometimes delayed. *Clin Med Insights Case Rep* 2014;**7**:71-73. doi:10.4137/CCRep.S16686.
- 6) Wheeler R, DeCastro A. Posterior Interosseous Nerve Syndrome. [Updated 2022 Jan 19]. In: StatPearls [Internet]. Treasure Island (FL): StatPearls Publishing; 2022. Available from: <https://www.ncbi.nlm.nih.gov/books/NBK541046/>
- 7) Kaya Y, Sarikcioglu L. Sir Herbert Seddon (1903-1977) and his classification scheme for peripheral nerve injury. *Childs Nerve Syst* 2015;**31**:177-180. doi: 10.1007/ s00381-014-2560-y.
- 8) Anesly AM, Ameer F, Pal HK. Case report of schwannomas: Benign tumour of peripheral nerve sheath. *EMJ Neurol* 2020;**8**:103-107. doi:10.33590/emjneuro/19-00203.