

The Safety and Outcomes of Simultaneous Open Rhinoplasty, Alar Reduction, and Upper Lip-Lift through One Surgery

Masoud Saman¹, Alireza Sharifi^{2,3*}

1. Saman Rhinoplasty and Facial Plastic Surgery Centre, Manhattan, New York, USA
2. Otorhinolaryngology Research Centre, Tehran University of Medical Sciences, Tehran, Iran
3. Department of Otolaryngology Head and Neck Surgery, Amir Al'am Hospital, Tehran University of Medical Sciences, Tehran, Iran

ABSTRACT

Background: The safety and outcomes of performing a simultaneous Alar reduction, Lip lift, and Open rhinoplasty Surgery (ALOS) through independent incisions have not been reported in any study, therefore, we aimed to evaluate the safety and outcomes of this combination procedure.

Methods: This retrospective review study was conducted on all cases of simultaneous ALOS, lip-lift, and alar reduction performed from 2018-2022, at Facial Plastic Surgery Clinic, New York, USA. Alar reduction involved complete through-and-through resection of alar wedge, and the type of lip lift technique was bullhorn design with excision of skin and Superficial Musculo-Aponeurotic System. Primary open rhinoplasty with inverted V-columellar incision was performed. The follow up period ranged between 4 months to 2 years, but all of patients were followed up at 6 days, one, and two months post-operatively.

Results: Fifty one cases were enrolled. We reviewed criteria of complications including infection, vascular events (such as necrosis, or partial ischemia), and poor scarring, fortunately, we did not have any infection or vascular issues. In 2 cases, columellar scar was "less than optimal", but in all other cases, this scar was "not perceivable" based on the patient survey. In 4 cases, the lip lift procedure scar was considered "less than optimal" showed slight indentation of white scar of lip lift in 9/44 cases. Additionally, all columellar and alar incisions had nearly invisible scarring.

Conclusion: In primary rhinoplasty cases, without any other surgeries or previous trauma in the oronasal region, performing concomitant lip lift, open rhinoplasty, and alar wedge resection is safe and does not negatively affect vascularity or scarring.

KEYWORDS

Rhinoplasty; Lip-lift; Alar; Simultaneous; Safety

Please cite this paper as:

Saman M, Sharifi A. The Safety and Outcomes of Simultaneous Open Rhinoplasty, Alar Reduction, and Upper Lip-Lift through One Surgery. *World J Plast Surg.* 2024;13(1):32-36.

doi: 10.61186/wjps.13.1.32

*Corresponding Author:

Alireza Sharifi, MD

Amir-Alam hospital, North Saadi Ave, Tehran, Iran

Tel.: +98 (21) 66703037

Email: sharifi.ali.rz@gmail.com

Received: 11/10/2023

Accepted: 3/12/2024

INTRODUCTION

Rhinoplasty is performed for the correction of cosmetic or functional deficits of the nose. Most rhinoplasty surgeons prefer the open approach¹ citing better direct visualization of underlying anatomy² and anatomical safety³. In this approach, the external incision is marked along the narrowest portion of the columella with different patterns⁴.

In addition, marking incisions in order to an alar base reduction are usually reserved for the end of the open rhinoplasty ⁵.

Manipulation of the alar is done in 15% to 90% of rhinoplasty procedures ⁶. There are several types of incision for alar reduction, but traditionally, an incision is marked along 1 to 2 mm anterior to the alar-facial groove ⁵. Complications reported for alar reduction might include scarring, notching, and asymmetry ⁶.

Upper lip lift is a surgical procedure that aims to shorten the distance between the vermilion border and the nasal base. In recent years there has been a resurgence of interest in this procedure. Typically, the superior incision is marked at the junction of the upper lip and the nasal base with the inferior incision marked to parallel the superior line ⁷.

In-depth understanding of vascular anatomy and thoughtful placement of incisions are basic tenants of any surgical operation as compromise vascular supply may result in untoward outcomes including necrosis of the area supplied by the compromised vessels ⁸.

Concomitant alar reduction and open rhinoplasty are generally considered safe to perform from a vascular supply standpoint ⁹. Furthermore, upper lip lift and open approach rhinoplasty with columellar incision are commonly performed together and shown to be safe from a vascular standpoint ¹⁰⁻¹². To our knowledge, the safety and outcomes of performing a simultaneous alar reduction, lip lift, and open rhinoplasty surgery through independent incisions have not been reported in any study, therefore, we aim to evaluate the safety and outcomes of this combination procedure.

METHODS

This retrospective review study was conducted on all cases of simultaneous open rhinoplasty, lip-lift, and alar reduction performed between Jan, 2018 and Dec, 2022, at Facial Plastic Surgery Clinic, New York, USA. Chart review of these patients treated by senior author (M.S.) pre- and post-operatively was performed.

The ethical code and informed consent were waived due to the nature of this project. Inclusion criteria was simultaneous primary open rhinoplasty, lip-lift, and alar reduction with true trans-alar incision. We excluded patients who underwent revision rhinoplasty, weir excisions, minor wedge excisions and had history of surgery/ trauma.

Surgical technique

Open rhinoplasty was performed by inverted V-shaped incision at the posterior third of the columella. The incision was preserved along the caudal margin of the lateral and medial crura of the lower lateral cartilage. The open rhinoplasty was carried out after the elevation of skin soft-tissue envelope.

To perform the lip-lift, the bullhorn design with excision of skin and Superficial Musculo Aponeurotic System (SMAS) was made. The amount of skin, that was excised, was customized based on the need to achieve over the center or more lift laterally of the lip. Also, alar reduction was performed in all patients. All of them involved complete through-and-through resection of alar wedge. The incisions of each cosmetic procedure are highlighted in detail in Figure 1.

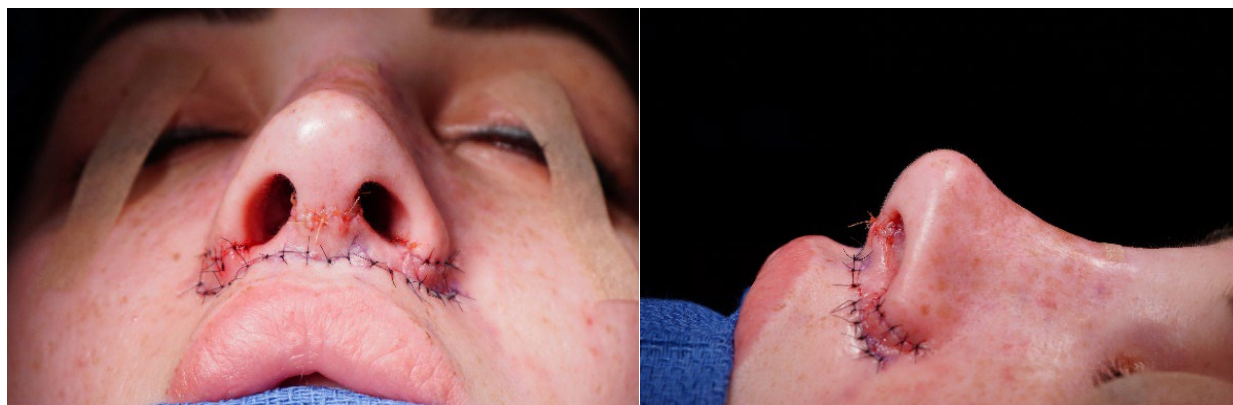

Figure 1: The incisions of open rhinoplasty, alar base reduction, and lip-lift.

Follow up examinations were performed routinely for all patients at 6 days (for removing suture), one and two months after combined operations. At this regular intervals after surgery, patients were evaluated in terms of complications such as infection, vascular event (necrosis and/or partial ischemia), and poor scarring. Also, the follow up process, after this regular intervals, ranged between 4 months and 2 years.

All the data were analyzed using IBM SPSS Statistics for windows, version 26 (IBM Corp., Armonk,

N.Y., USA). We reported frequency (number and percentile) for descriptive variables.

RESULTS

In total, the charts of 51 patients who underwent primary open rhinoplasty, lip-lift, and alar reduction, simultaneously, were assessed. Intra-operative photos were available in 68.6% (n=35) of cases. Frequency of complications based on patient- and surgeon-reported outcomes are summarized in Table 1.

Table 1: Frequency of complications based on patient- and surgeon- reported outcome.

			Frequency No. (%)
Patient-reported outcome	Columellar scar	Less than optimal	2 (3.9)
		Good	49 (96.1)
	Lip-lift scar	Less than optimal	4 (7.8)
		Good	47 (92.2)
Surgeon-reported outcome	Lip-lift scar	Indentation	9 (17.6)
		Nearly Invisible	42 (82.4)
	Columellar Scar	Indentation	0 (0.0)
		Nearly Invisible	51 (100)
	Alar scar	Indentation	0 (0.0)
		Nearly Invisible	51 (100)

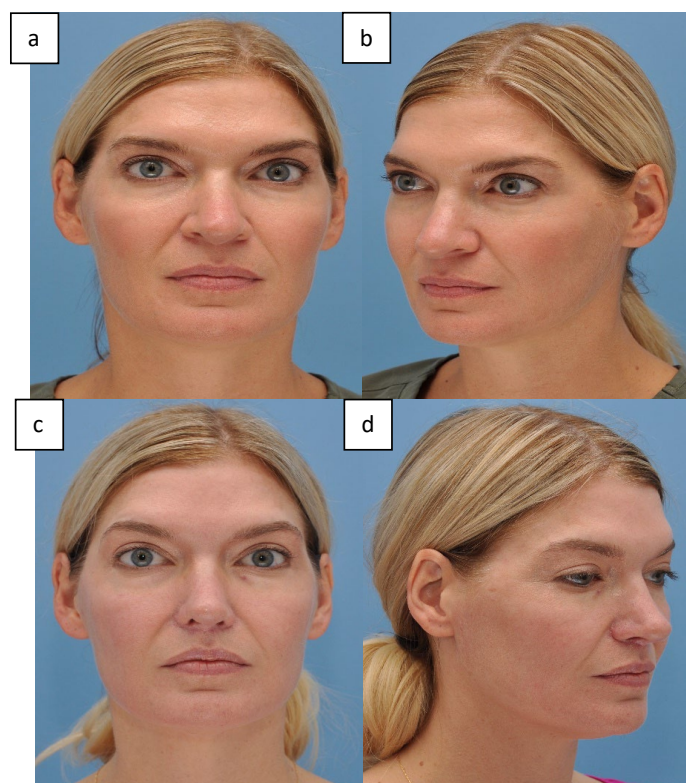

Figure 2: Patient 1, 40 years old, Pre-op and 1 month post-op images (a and b: pre-op frontal and oblique view / c and d: 1 month post-op frontal and oblique view).




Figure 3: Patient 1, 40 years old, Pre-op and 2 month post-op images (a and b: pre-op frontal and oblique view / c and d: 2 month post-op frontal and oblique view).

There have been no cases of infection and vascular issues such as necrosis and/or partial ischemia. Based on the patient-reported outcome, columellar scar (for open rhinoplasty) was less than optimal in 2/51 (3.9%). Though, rest of patients reported their scars were not perceivable. In addition, the scar that was related to the lip-lift was less than optimal in 4/51 (7.8%). It is noteworthy to mention that 2 of these 4 cases were the same patients that had poor columellar scar, and they did not have any underlying disease. However, all other cases did not report any unsatisfaction about their lip-lift and alar reduction scars.

Objective evaluation of scars by senior author (M.S.) at 1 year after surgery were available in 86.27% (n=44) of cases. Senior author (M.S.)-reported outcome showed slight indentation of white scar of lip-lift in 17.64% (n=9) of cases. Though, all columellar and alar incisions had nearly invisible scarring. Additionally, the Pin-prick test was conducted for all patients at the end of surgery and one week after surgery. Its result was positive for bright red bleeding, which showed good vascularity, in all patients. Pre-p and 1 month post-

op photos of a 40-year-old female were depicted in Figure 2. She underwent revision open rhinoplasty, alar reduction, and lip-lift simultaneously. Also, pre-p and 2 month post-op photos of a 26-year-old female were depicted in Figure 3. She underwent primary open rhinoplasty, alar reduction, and lip-lift simultaneously.

DISCUSSION

Some studies have combined the close or open rhinoplasty, with both endonasal and cutaneous incision, with lip lift. It has several benefits for both the surgeon and the patient¹³. For the patient, it allows for performing multiple aesthetic corrections through one operating session, overlap of recovery times, limited anesthetic exposure, and expedited results. For surgeon, improved patient experience and increased efficiency will be the most important advantages¹¹. On the other hand, type of technique and the ability to carry out multiple aesthetic procedures simultaneously in one operating session without sacrificing quality or safety play the most challenging role in determining the

outcome. This is because the increase in number of cosmetic procedures through one surgery might increase the probability of damaging to the nasal arteries. The current study used the Pin-prick test in order to evaluate the nasal vascularity status post-operation. Its findings were normal, and no arterial complications were found. It means that current approach is safe in terms of damaging to nasal arteries.

Studies have used different techniques to perform rhinoplasty and lip-lifting simultaneously. One of them by Bessler et al.¹² has performed these two cosmetic procedures using a single incision line. However, the present study used separate incisions. Another study¹⁴ has carried out this multiple cosmetic procedures with effective and safe findings. They used closed approach for rhinoplasty, but open approach was used in current study. Our findings showed that both of objective and subjective-reported outcomes were optimal, and no serious complication was reported. Spiegel et al.¹¹ has also used similar technique through separate incisions, and their findings are in consistent with current study.

There were some limitations for the current study: 1) The lack of angiographic data in our clinic to evaluate the function of arteries, 2) the retrospective nature of study, and 3) the limited number of participants.

CONCLUSION

In primary rhinoplasty cases, without any other surgeries or previous trauma in the oronasal region, performing concomitant lip lift, open rhinoplasty, and alar wedge resection was safe and did not negatively affect vascularity or scarring.

CONFLICT OF INTEREST

There is no conflict of interest between authors.

REFERENCES

1. Rohrich RJ, Afrooz PN. Primary open rhinoplasty. *Plast Reconstr Surg* 2019;**144**(1):102e-17e.
2. Rohrich RJ, Afrooz PN. Rhinoplasty refinements: the role of the open approach. *Plast Reconstr Surg* 2017;**140**(4):716-9.
3. Bafaqeeh SA, Al-Qattan MM. Simultaneous open rhinoplasty and alar base excision: is there a problem with the blood supply of the nasal tip and columellar skin? *Plast Reconstr Surg* 2000;**105**(1):344-7.
4. Ors S, Ozkose M, Ors S. Comparison of various rhinoplasty techniques and long-term results. *Aesthetic Plast Surg* 2015;**39**:465-73.
5. Hudise JY, Aldhabaan SA, Nassar RS, Alarfaj AM. Evaluation of scar outcome after alar base reduction using different surgical approaches. *J Oral Maxillofac Surg* 2020;**78**(12):2299. e1-. e8.
6. Choi JY. Alar base reduction and alar-columellar relationship. *Facial Plastic Surgery Clinics* 2018;**26**(3):367-75.
7. Salibian AA, Bluebond-Langner R. Lip lift. *Facial Plastic Surgery Clinics* 2019;**27**(2):261-6.
8. Spiegel JH. The modified bullhorn approach for the lip-lift. *JAMA Facial Plastic Surgery* 2019;**21**(1):69-70.
9. Tellioglu AT, Vargel İ, Çavuşoğlu T, Çimen K. Simultaneous open rhinoplasty and alar base excision for secondary cases. *Aesthetic Plast Surg* 2005;**29**:151-5.
10. Marechek A, Perenack J, Christensen BJ. Subnasal lip lift and its effect on nasal esthetics. *J Oral Maxillofac Surg* 2021;**79**(4):895-901.
11. Insalaco L, Spiegel JH. Safety of simultaneous lip-lift and open rhinoplasty. *JAMA Facial Plastic Surgery* 2017;**19**(2):160-1.
12. Bessler S. Combining rhinoplasty with upper lip-lift using a single incision line. *JAMA Facial Plastic Surgery* 2018;**20**(2):166-7.
13. Üstün GG, Konas E, El H, et al. The effects of maxillary movements on nasal aesthetics following orthognathic surgery. *J Craniofac Surg* 2020;**31**(3):796-800.
14. Pascali M, Marchese G, Diaspro A. The rhino-lip-lifting: a novel proposal for midface profileplasty performed as a single surgical procedure. *Facial Plast Surg* 2021;**37**(03):340-7.