

Syndactyly in Twins: A Case Report

Hossein Akbari¹, Amir Saraee^{1*}, Yousef Shafaei¹, Mohammad-Reza Akhoondinasab¹,
Peyman Akbari²

1. Department of Plastic and Reconstructive Surgery, School of Medicine, Iran University of Medical Sciences, Tehran, Iran
2. School of Medicine, Tehran University of Medical Sciences, Tehran, Iran

ABSTRACT

Syndactyly is a common inherited and clinically heterogeneous malformation which can be syndromic or non-syndromic. It also varies phenotypically between the families. In this study, we present twins who experienced bilateral syndactyly and underwent reconstruction using the Gilbert method. These female twin toddlers were referred to Hazrat Fatemeh Clinic of Hand Surgery in Tehran, Iran, in 2022 with bilateral syndactyly of the middle and ring fingers. In both, fingers were fused along their entire length. One of them underwent the separation of the middle finger and ring finger of the right hand by the Jibert method, and the other underwent surgery for the separation of her left hand at the age of one and a half. She was presented with a contracture of the middle finger and third web space, corrected with a Z-plasty of the middle finger and the V-M flap for the web space.

KEYWORDS

Syndactyly; Congenital anomaly; Twin syndactyly

Please cite this paper as:

Akbari H, Saraee A, Shafaei Y, Akhoondinasab MR, Akbari P. Syndactyly in Twins: A Case Report. *World J Plast Surg.* 2025;14(2):1-5.
doi: 10.61186/wjps.14.2.**

INTRODUCTION

The rate of congenital anomalies in twins was 405.8/10000 and is more in monozygotic twins than dizygotic twins¹. Syndactyly (i.e., fusion of fingers, typically across tissues) is a common inherited and clinically heterogeneous malformation. It can be syndromic, comprising more than 300 different anomalies², or non-syndromic, occurring as one of nine non-syndromic forms³. It also varies phenotypically between the families. A patient's phenotype may be severe or mild, unilateral or bilateral, symmetrical or asymmetrical, complete or incomplete, cutaneous or bony. It may involve different bones, with phenotypic variations between limbs².

In this article, we present monozygotic twins who experienced bilateral syndactyly of hand and underwent surgery.

*Corresponding Author:

Amir Saraee

Department of Plastic and Reconstructive Surgery, School of Medicine, Iran University of Medical Sciences, Tehran, Iran

Email: dr.a.saraee@gmail.com

Received: ***

Accepted: ***

CASE PRESENTATION

Ethics approval and informed consent

Informed consent was obtained from the patient's father as the legal guardian, and ethical considerations were duly observed.

Three-and-a-half-year-old monozygotic twin girls toddlers were brought to Hazrat Fatemeh Clinic of Hand Surgery in Tehran, Iran, in 2022 with syndactyly of the middle and ring fingers on both hands. The entire length of both fingers was fused (Figure 1 A, B). Serial maternal ultrasonography showed that the twins had normal growth, and no other problems were detected. No maternal medical history or exposure to teratogenic substances during pregnancy was found. The mother had not nutritional deficiencies like folic acid deficiency, rubella infection, occupational and travel history or underlying condition such as diabetes, smoking and alcohol use. The mother had no problems during

delivery. Moreover, the younger sister of these twins has no problems. This problem did not exist in the patient's mother or maternal family. Father of the twins had bilateral syndactyly. He had bilateral hand middle and ring finger syndactyly; his right hand was operated on and separated at the age of eleven, but his left syndactyly remained. This problem was present in the patient's paternal family. Of course, only the male children in the father's family have had problems. The father's maternal grandfather, father's uncle, and father's cousin had syndactyly fingers. No genetic testing was done for the father or daughters. Family tree of disease is shown in figure two (Figure 2).

No other anomalies were found. Physical examination of the twins showed everything was normal except the fingers. They brought them to us when they were three and a half years old. We presented the plans, potential complications, and expected outcomes to the parents, and they agreed to proceed with the operation for the twins.

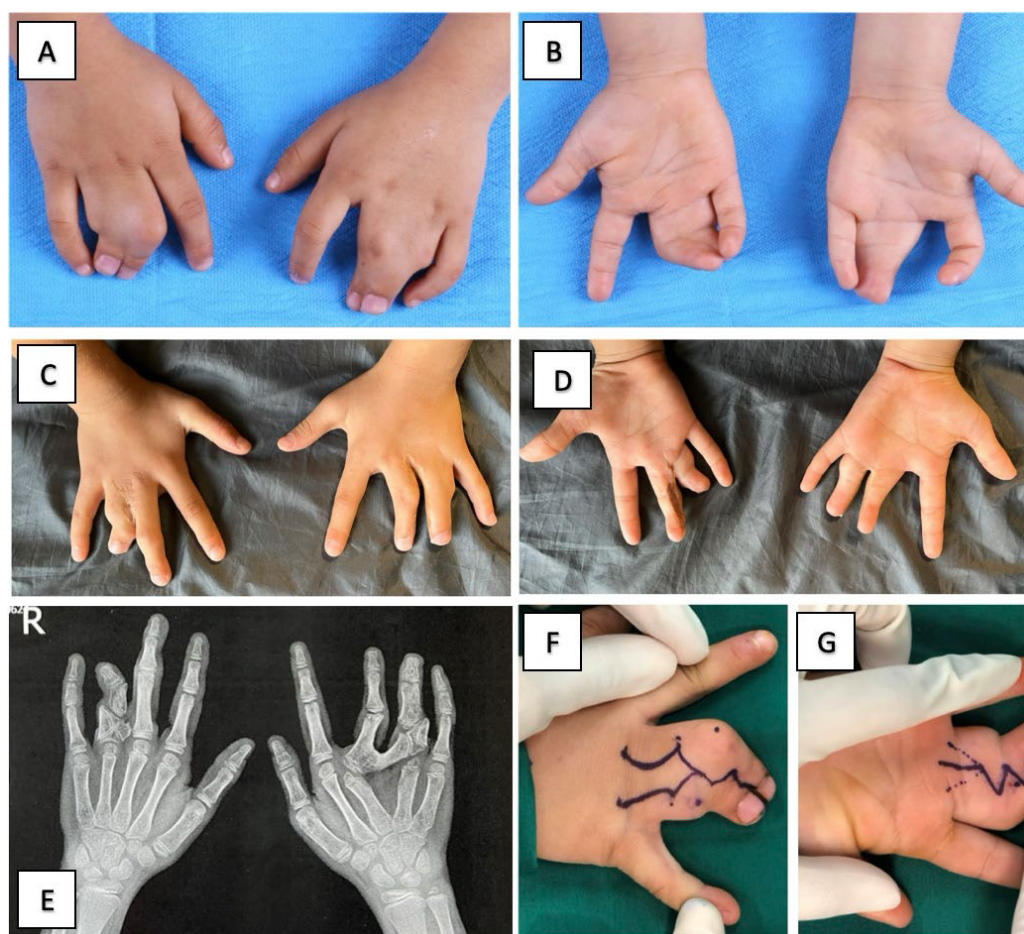


Figure 1: A,B: Before operation of syndactyly. C,D: 7 years after operation. E: Radiologic imaging at 7 years after operation. F, G: Flap design for syndactyly correction (Jilbert Method)

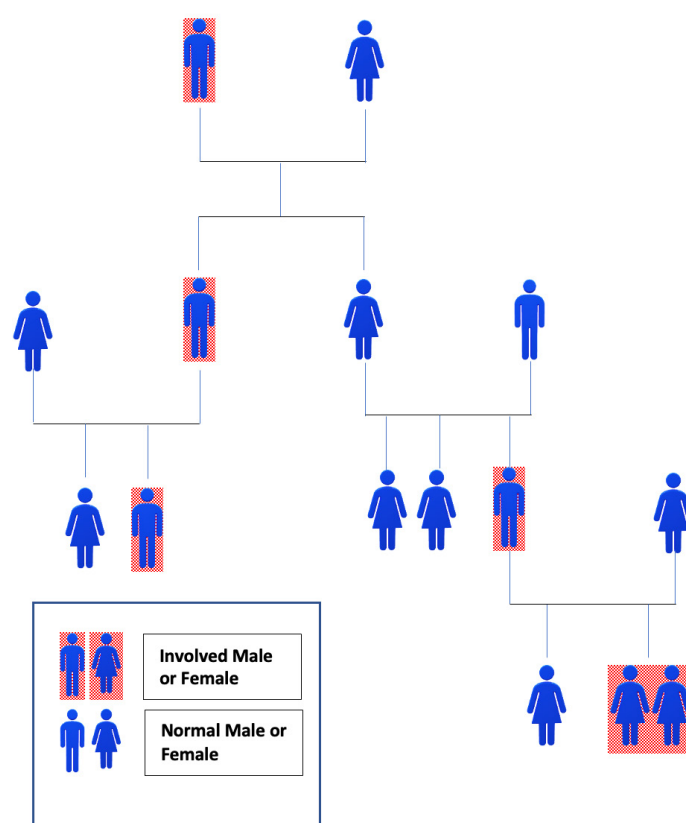


Figure 2: Family tree of disease. The involved persons is shown with a red box

After obtaining informed consent, pediatric and anesthesiologist consultations were conducted. Each hand and patient exhibited different types of syndactyly.

Right-hand middle and ring finger separation were performed on one of them using the Jibert method due to its angulation and deformity (Figures 1F, G). The skin defect of the fingers was repaired with a total thickness skin graft harvested from the right groin. K-wire passed for both fingers.

The other twin sister underwent surgery for syndactyly on her left hand at the age of one and a half. This operation was complicated with a third web space contracture corrected with Z-plasty of the middle finger and V to M for web space. FTSG was harvested from the left groin to cover the remaining defect.

The dressing was changed five days after the operation. Regular post-operation care and visits were done, and plans were made for the other hand of both patients. The patients were visited seven years after the operation, and their radiology and photography are shown in Figure 1C, D, E. During this time, they had a third sister, who was healthy and did not suffer from syndactyly.

DISCUSSION

Syndactyly is the most common congenital anomaly, which involves the fusion of toes or fingers, ranging from incomplete webbing of the skin of two digits to the complete form where bones and nails are fused. It has several degrees of severity and is twice as common in males in the Caucasian population^{2,3}. The third and fourth web spaces are more frequently affected than the first and second^{4,5}.

Molecular genetic methods, such as DNA analysis, can aid in diagnosing unclear medical conditions. Although prenatal diagnosis of finger syndactyly is possible through ultrasonography, it cannot be performed for the toes⁶.

Differentiation and morphogenesis are time-controlled processes. At this period, if any problem occurs, it can cause congenital malformation⁶. In the absence of apoptosis in the interdigital mesenchyme between the seventh and eighth week of pregnancy, the lack of differentiation in five consecutive processes—fertilization, cleavage, implantation, gastrulation, and organogenesis—occurs^{2,3,5}.

Two signal centers—the apical ectodermal ridge (AER) and the zone of polarizing activity (ZPA)—

control the position and structure of human limbs⁷⁻⁹. Syndactyly, a condition where fingers or toes are fused, can occur sporadically or run in families, often presenting as an autosomal dominant trait^{4, 5}. This condition can be caused by multiple factors, such as exposure to teratogens during pregnancy (such as diseases, drugs, or heavy metals, especially during the first trimester) or genetic mutations^{7, 10}. Due to the radiological findings' impossible diagnosis of syndactyly, it is recommended that a gene screening panel be used during the prenatal period. In non-syndromic syndactyly, GJA, HOXD₁₃, and FGF₁₆ genes are diagnostic choices. Deregulation of the LMBR₁, LRP₄, and HOX₁₃ genes are seen in syndromic and non-syndromic forms of syndactyly, but ROR₂, SOST, and GLI₃ are represented in syndromic form¹¹.

There are different ways of categorizing syndactyly. One classification includes:

- Complete syndactyly occurs when the involved fingers are joined together.
- Incomplete syndactyly is when only parts of the finger sides are joined.
- Simple syndactyly happens when the skin and flesh between fingers are joined together.
- Complex Syndactyly occurs when bones are fused¹².

Winter and Tickle classification is based on the pattern of mechanism for the community of people during the development of limb bud secondary modeling¹³.

Stoll et al. classified non-syndromic syndactyly into different types and documented those eight genes are associated with it^{9, 14}.

Syndactyly or webbing can cause functional problems and limitations in hand movements. Surgery is usually recommended in such cases within the first few years of life¹⁴. If the thumb, index, and ring fingers are involved, the surgery be performed sooner, between six to 12 months, and multiple-digit involvement should be addressed first. Delayed correction of these deformities can result in complications such as rotation and angulation. Other potential surgery complications include web creep, finger deviation, and complications from other surgical procedures¹⁶.

Surgery may be required urgently depending on the patient's age and the type of anomaly. In cases where the ulnar or radial side of the fingers needs to be released, surgeons should wait for at least six

months so as not to risk damaging the fingers¹⁷.

It is recommended to perform surgery during the preschool years to minimize the impact on their psychological and social functions when interacting with other children. Follow-up should continue until skeletal maturity¹⁷.

CONCLUSION

Syndactyly is a complex condition that can be challenging to diagnose genetically. There are nine identified types of syndactyly, each with its genetic analysis. Due to the variability of the disease, it can be challenging to make a genetic-based diagnosis, such as carrier testing, and most diagnoses are made after birth. More research is needed to determine the causes and origins of syndromic or non-syndromic syndactyly. Although our knowledge of syndactyly is improving, treatment still depends on age, functional issues, and severity of the condition. It is crucial to advise expectant mothers to avoid taking herbal and teratogenic medications during pregnancy. Surgeons must take a proper medical history and physical examination before surgery. Performing surgery appropriately and providing good follow-up care can prevent further complications and deformities.

CONFLICT OF INTEREST

The authors declare that there is no conflict of interests.

REFERENCES

1. S.V. Glinianaia, J. Rankin, C. Wright, Congenital anomalies in twins: a register-based study, *Hum Reprod* 2008; 23 (6): 1306-1311, <https://doi.org/10.1093/humrep/den104>
2. Mcmillan JA, Oski FA. *Oski's Pediatrics : Principles & Practice*. Lippincott Williams & Wilkins; 2006.
3. Willis Cohoon Campbell, S Terry Canale, Beaty JH. *Campbell's Operative Orthopaedics*. Mosby/ Elsevier; 2013.
4. Wolfe SW, Pederson WC, Kozin SH. *Green's Operative Hand Surgery E-Book*. Elsevier Health Sciences; 2010.
5. Burke FD, McGrouther DA, Paul John Smith. *Principles of Hand Surgery*.; 1990.
6. Chorionic Villus Sampling and Amniocentesis: Recommendations for Prenatal Counseling. www.cdc.gov. Accessed June 27, 2024. <http://www.cdc.gov/mmwr/preview/mmwrhtml/00038393.htm>

7. Mariani FV, Martin GR. Deciphering skeletal patterning: clues from the limb. *Nature* 2003; 423(6937):319-325. doi:<https://doi.org/10.1038/nature01655>
8. Saunders JW. The proximo-distal sequence of origin of the parts of the chick wing and the role of the ectoderm. *J Exp Zool* 1948;**108**(3):363-403. doi:<https://doi.org/10.1002/jez.1401080304>
9. Todt WL, Fallon JF. Posterior apical ectodermal ridge removal in the chick wing bud triggers a series of events resulting in defective anterior pattern formation. *Development* 1987;**101**(3):501-515. doi:<https://doi.org/10.1242/dev.101.3.501>
10. Kliegman RM. *Nelson Textbook of Pediatrics*. 21st ed. Elsevier; 2020.
11. Cassim A, Hettiarachchi D, Dissanayake VHW. Genetic determinants of syndactyly: perspectives on pathogenesis and diagnosis. *Orphanet J Rare Dis* 2022 **17**(1): 198. <https://doi.org/10.1186/s13023-022-02339-0>
12. B AE, Akhator A. Bilateral webbed fingers in a set of fraternal twins - case report. *Zenodo* (CERN European Organization for Nuclear Research). Published online November 4, 2010. <https://doi.org/10.5281/zenodo.3528003>
13. Winter RM, Tickle C. Syndactylies and Polydactylies: Embryological Overview and Suggested Classification. *Eur J Human Genet* 1993;**1**(1):96-104. doi:<https://doi.org/10.1159/000472392>
14. Rankin J, Strachan T, Lako M, Lindsay S. Partial cloning and assignment of WNT6 to human chromosome band 2q35 by in situ hybridization. *Cytogenet Cell Genet* 1999;**84**(1-2):50-52. doi:10.1159/000015212
15. Syndactyly (Webbed Fingers). www.eatonhand.com. <https://www.eatonhand.com/hw/hw019.htm>
16. Jordan D, Hindocha S, Dhital M, Saleh M, Khan W. The epidemiology, genetics and future management of syndactyly. *Open Orthop J* 2012; **6**:14-27. doi:10.2174/1874325001206010014
17. Ermito S, Dinatale A, Carrara S, Cavaliere A, Imbruglia L, Recupero S. Prenatal diagnosis of limb abnormalities: role of fetal ultrasonography. *J Prenat Med* 2009; **3**(2):18-22.