

Critical Evaluation of Keystone Reconstruction: A Retrospective Series of 32 Cases

Abhinav Singh^{1*}, Abhishek Sharma², Rohini Singh³, Kuldeep Singh², RB Singh⁴,
Aksha Mohan⁵

1. Department of Burns and Plastic Surgery, AIIMS, Saket Nagar, Bhopal - 462020 (MP) India

2. Department of Burns and Plastic Surgery, Postgraduate Institute of Medical Sciences (PGIMS), University of Health Sciences, Rohtak (UHRS), Haryana, India

3. Department of Dermatology, AP, LNCT Medical College and Research Center, Bhopal- 462042, Madhya Pradesh, India

4. Department of Burns and Plastic Surgery & Hypospadias and VVFs Clinic, Postgraduate institute of Medical Sciences (PGIMS), University of Health Sciences, Rohtak (UHRS)

5. Department of Orthopedics, Postgraduate Institute of medical Sciences (PGIMS), University of Health Sciences, Rohtak (UHRS), Haryana, India

*Corresponding Author:

Abhinav Singh. MS. MCh.

Department of Burns and Plastic Surgery, AIIMS, Saket Nagar, Bhopal - 462020 (MP), India

Email: abhi2889@gmail.com,
dr_rb_singh@rediffmail.com

Received: ***

Accepted: ***

ABSTRACT

Background: We aimed to create focus and awareness about versatility of keystone flap in safe re-surfacing of small to medium and large sized skin defects in single stage with minimal donor site morbidities and maximum anatomical, functional and aesthetic results.

Methods: Retrospective study was conducted between October 2021–December 2022 on 26 males and 5 females aged 20-70 years who underwent 32 Keystone flap reconstruction (type IIA n=11, type IIB n=7 type III n=6, Type IV n=8) in diversity of defects following: domestic electric burn on pulp of thumb (n=2), chronic discharging sinus over clavicle (n=1), post-traumatic wounds on eighteen legs (n=19), excision of unstable scar over shin of tibia (n=4), exit wound on medial aspect of foot (n=3) and excision of non-healing ulcer over heel (n=3). Flaps were designed in a way to keep maximum perforators in pedicular area and to ascertain maximum mobility. After debridement, wound area ranged from 4mm x 4mm to 17 x 8 cm. The flap size ranged from 5mm x 5mm to 18cm x 8cm. Follow-up ranged from 1 month to 12 months.

Results: Three cases developed partial wound dehiscence which were managed subsequently. None of the flap had partial or total loss. Over-all results were satisfying.

Conclusion: Our series highlighted that keystone flaps have defect adaptive design and are technically easy to perform, cost and time effective and can be designed from head to toe (omnipresence) with excellent outcome. We advocate their use as robust reconstructive tool for Plastic surgeons, Orthopedic surgeons and Dermatologist.

KEYWORDS

Keystone flap; Omnipresence; Perforator

Please cite this paper as:

Singh A, Sharma A, Singh R, Singh K, Singh RB, Mohan A. Critical Evaluation of Keystone Reconstruction: A Retrospective Series of 32 Cases. World J Plast Surg. 2025;14(2):1-19.
doi: 10.61186/wjps.14.2.**

INTRODUCTION

Keystone flap was first described by Behan FC in 2003¹. It is a trapezoidal shaped local advancement flap based upon multiple cutaneous perforators consisting of two conjoined V-Y island flaps. The name is derived from the flap's resemblance to the shape of an architectural keystone within an ancient Roman arch. It has simple bio- geometry, technical ease, handy, reliable, utilizes "like" tissue without major post-

operative complications. It is time and cost effective having aesthetically acceptable results for small to medium and large skin defects, therefore this retrospective study is being reported.

This is a retrospective case series involving patients who underwent standard surgical procedures using the Keystone flap, which has been widely used across various centres for many years. As the study does not involve any experimental intervention or prospective research component, hence formal ethical approval was not required. Informed written consent was obtained from all individual participants for participation and for the use of clinical data and photographs for academic and

publication purposes.

MATERIAL AND METHODS

This retrospective study was conducted from Oct 2021–Dec 2022 in the Department of Plastic Surgery of Postgraduate Institute of Medical Sciences (PGIMS), Rohtak, Haryana, India. Thirty two (type IIA n=11, type IIB n=7 type III n=6, Type IV n=8) Keystone flaps were raised, in 26 males and 5 females aged between 20-70 yr, to treat skin defects as elective as well as emergency cases following: domestic electric burn on pulp of thumb n=2 (Figure 1), chronic discharging sinus over

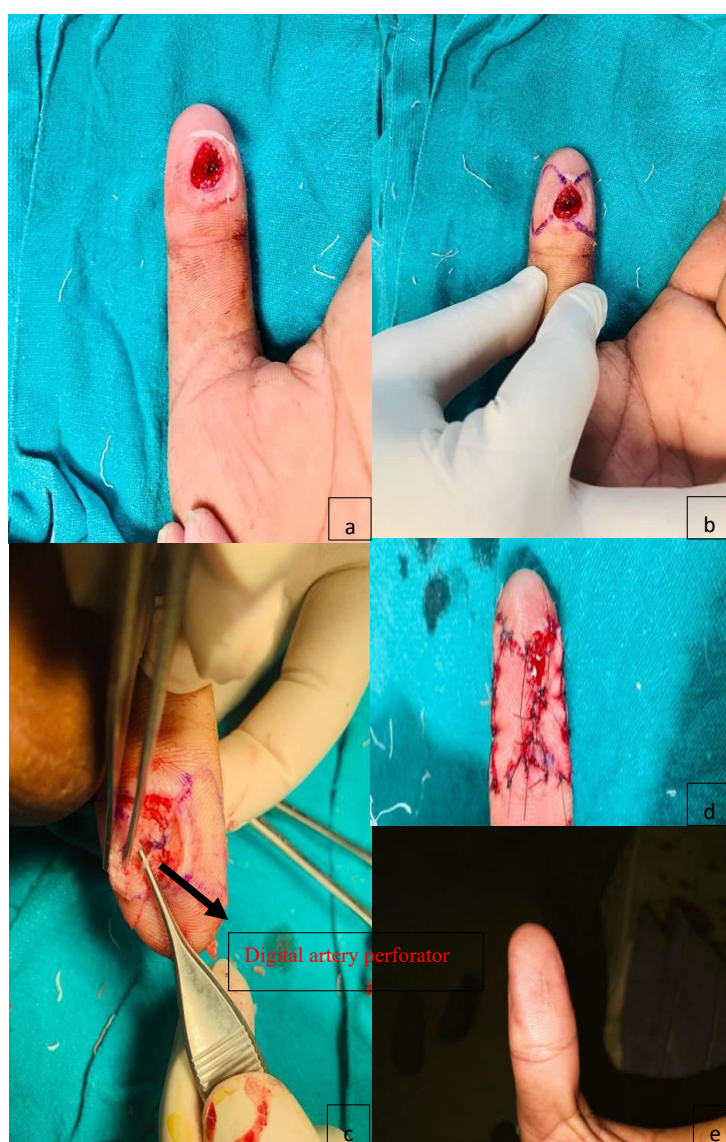

Figure 1: Clinical case 1. (a) Entry wound on pulp of thumb, (b) After debridement defect measured 4mm X 4 mm, Type III double opposing mini- Keystone flap designed for coverage, (c) Digital artery perforator visible (arrowed), (d) Final inset given, (e) Post-operative picture at 5 months of follow up

clavicle n=1 (Figure 2), post-traumatic wounds on eighteen legs n=19 (Figures 3, 4, 5, 6, 7), excision of long linear unstable adherent scar over shin of tibia n=4 (Figure 8), exit wound on medial aspect of foot n=3 (Figure 9) and excision of non-healing ulcer over heel n=3 (Figure 10) (Table 1). Associated co-morbidities were hypertension n=5 and diabetes mellitus n=4. In our series the size of defects ranged from 4 mm to 17 cm X 8 cm.

Our primary goal was to critically access the utility of Keystone flap in various types of defects, showing its omnipresence, its types and modification, dissection technique, physiology and neurovascular response, flap dimensions ranging from mini to major, fundamental principles, geometry, hospital stay, operation time and complication.

Exclusion criteria

1. Deeply burnt tissues.
2. Concealed avulsion injury.
3. Irradiated tissue.
4. joints region with deficient skin laxity.
5. Too large defects.
6. Active infection or inflammation.
7. Deep cavitary wounds.
8. Intra-nasal and intra-oral defects.

Surgical technique- Informed consent was sought. Operative procedures were performed under general, spinal or local anesthesia. Average operating time was 60 to 120 min. The operations were performed under magnification loupes (3.5-4.5X) and tourniquet control. The etiology, size, site and characteristics of defect and surrounding area were analyzed. Standard principles were followed while planning, designing and harvesting keystone flaps. Type and modification of Keystone flap was determined intraoperatively, taking into consideration the laxity and movement of surrounding tissues. Skin with maximum laxity around defect was chosen as donor site. After thorough debridement or complete excision of lesion and fixation of fracture, the defect was converted in to elliptical or circular shape. A right angle is created at the longitudinal axis of excision to create keystone design. The length and width of defect was measured and flap designed with a flap to defect ratio of 1:1 in routine, and for large defect two opposing flaps were designed, each flap smaller than the width of defect. In lower limb, where a known vessel was present adjacent to defect, perforators were dopplered by

hand held doppler and marked to preserve them. In few cases, flaps were raised in random pattern leaving only center area of flap (pedicular area) having micro-perforators. Skin was incised down to fascia then circumferentially undermining done in sub-fascial plane around pedicular area having fasciocutaneous or musculocutaneous perforators and continued till flap could be advanced to provide tension-free cover to defect whereas peripheral borders are advanced in V-Y fashion. Utmost care was taken to preserve maximum of hot spot area. Where single flap was not sufficient to cover the defect, another flap from opposite side of defect was raised. Where sensory nerves or superficial veins were found during dissection, these were preserved to maintain sensation and vascularity of flap, if not restricting flap movement. After achieving hemostasis, first suture was taken at the center of flap where maximum tension is present, then closure of both ends aligned in V-Y apposition resulting in narrowing of defect then periphery was sutured by standard technique using interrupted, vertical or horizontal mattress sutures. Drains were inserted. Slab was given wherever necessary. A window was made over dressing for monitoring purpose and patient was advised for limb elevation. Few of our selected cases of clinical importance and of teaching and learning significance are briefly described below:

Case presentation

Clinical case 1. (Figure 1a-e). A 25-yr male presented with painful entry wound over pulp of thumb. Debridement resulted in 4 mm x 4 mm circular defect of which primary closure was not aesthetically possible. Type III double opposing mini-Keystone flaps were raised for reconstruction. Incision was given all around in territory of both flaps. Digital artery perforators were encountered and preserved to safeguard vascularity of flap. Both flaps were advanced and both defects closed primarily. At 5 months of follow up, aesthetically acceptable results and sensations were obtained.

Clinical Case 2.-(Figure 2a-h). A 32 yr male had post traumatic osteomyelitis and discharging sinus in right clavicle. Complete excision of sinus and a small segment of clavicle were done. Resultant defect measured 3 X 4 cm. Type IIA supraclavicular

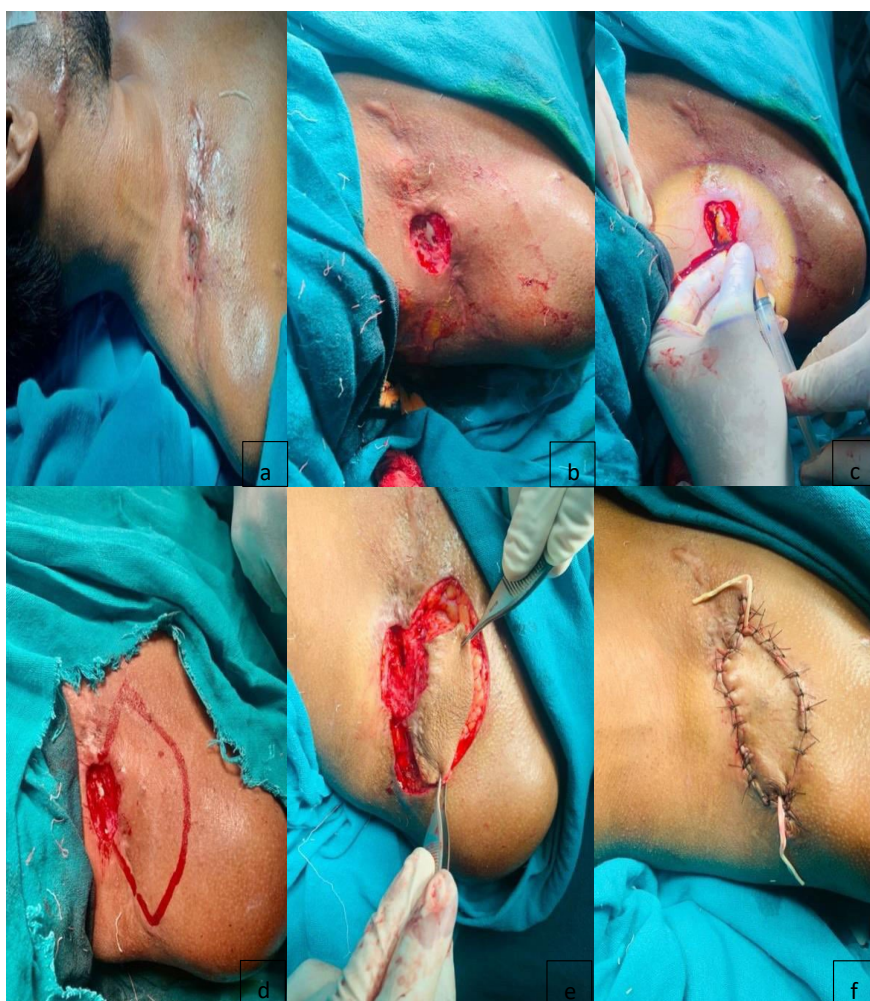

Figure 2: Clinical case 2. (a) Post traumatic osteomyelitis of clavicle with discharging sinus, (b) Debridement, excision of sinus tract and removal of small segment of clavicle, (c) Betadine hydrogen peroxide wash given, (d) Type IIA Keystone flap designed, (e) Flap dissected circumferentially and elevated, (f) Immediate post-operative picture

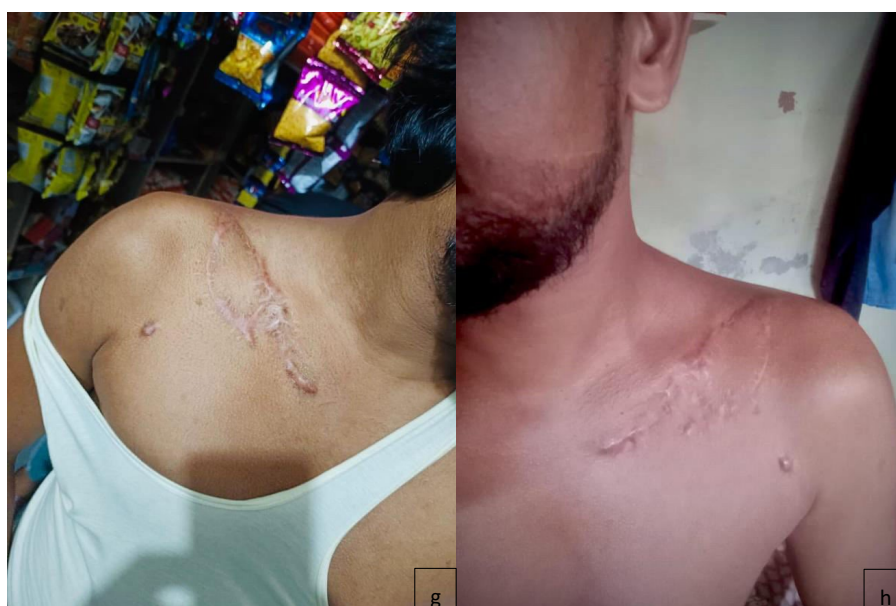

Figure 2: Clinical case 2. (g) and (h) Post operative result at 8 and 12 of follow up

Keystone flap was raised and advanced for primary closure of both defects. Glove drain kept. Keloidal tendency was not noticed at 8 and 12 months of follow up.

Clinical case 3. (Figure 3a-e). A 48-yr male presented in emergency with Gustilo IIIa compound fracture at upper leg following road traffic accident. Examination revealed 9 cm X 9 cm defect over anterior aspect of leg. Debridement resulted in defect measuring 10 X 11 cm. Perforators of posterior tibial artery were marked before inflation of tourniquet. Type IV Keystone flap was raised with Sub-fascial undermining leaving perforators intact. Negative suction drain was kept. Primary defect was closed. Secondary defect was closed primarily in lower part and its upper one third area was grafted. At 1 month of follow up a good contour and acceptable aesthetic results were obtained.

Clinical Case 4. (Figure 4a-g) A 65 yr male presented in emergency with Gustilo IIIa compound fracture with long elliptical pre-tibial defect on middle third of leg. External fixator was applied. Debridement resulted in 17 X 8 cm defect. Type III Keystone flap 17 X 8 cm for reconstruction from lateral side was chosen. Perforators of peroneal artery were dopplered. Sub-fascial undermining was done leaving perforators area intact. Flap could not be advanced to cover the defect because of too many adhesions, therefore, it was decided to design another Type III Keystone flap 17 X 3.5 cm from medial side. Perforators of posterior tibial artery were dopplered. Medial flap was advanced and sutured with lateral flap in a fashion of double opposing flaps (Type III). Drains were kept. Donor area of lateral flap was grafted and of medial flap was primarily closed. Bone lengthening was done by Ilizarov apparatus after 6 months of healing. At 7 months, results were acceptable.

Clinical case 5. (Figure 5a-c). A 50 yr male presented in emergency with Gustilo IIIB compound fracture with periosteal stripping at middle third of leg after road traffic accident. Examination revealed 14 X 5 cm defect. External fixator was applied. Radical debridement resulted in defect of 16 X 6 cm. Type IIB Keystone flap was designed from medial side. Perforators of posterior tibial artery were dopplered and marked. Flap was elevated and advanced.

Negative suction drain kept. Secondary defect was grafted. Patient reported healed wound, ambulatory and asymptomatic but did not come for follow up because of family reasons.

Clinical case 6. (Figure 6a-g) A 69-yr male presented with two separate Gustilo II wounds after road traffic accident, one on middle one-third and other on lower one-third of leg. Debridement resulted in upper defect measuring 9 X 4 cm and lower 6 X 3 cm. Two separate Type IIB Keystone flaps from medial side of leg were designed. Perforators of posterior tibial artery were marked. For upper defect, flap was raised and advanced to cover defect leaving perforators area undisturbed. For lower defect, because of limited laxity and availability of tissues, flap was islanded on perforator and wound closed. Drains were inserted. Donor sites were grafted. At 14 months of follow up both flaps were settled and graft well taken.

Clinical case 7. (Figure 7a-d). A 68-yr male presented in emergency with two adjacent wounds with Gustilo II fracture. After debridement, upper defect measured 5 X 3.5 cm and lower defect measured 7 X 5 cm. Both defects were converted into one large defect measuring 12 X 5 cm. Type IV large Keystone flap was raised on dopplered perforators of posterior tibial artery. However, when flap advancement was initiated, difficulty was encountered in closure, therefore it required its islanding. On contacting patient, he reported healed wound, asymptomatic and ambulatory but was unable to come for follow up.

Clinical case 8. (Figure 8a-f). A 49 yr male had long linear unstable adherent scar measuring 9 cm X 3 cm over shin of tibia. Elliptical excision resulted in a defect measuring 10 X 4 cm with exposed tibial bone. In lower part of leg, because of less laxity of tissue and tight compartment, primary closure was not possible. Type IIA Keystone flap from lateral side was planned. Perforators of posterior tibial artery were dopplered and marked. Flap was raised with sub-fascial undermining leaving perforators undisturbed. During dissection, superficial peroneal nerve came into view safeguarded and shifted laterally with the flap to preserve sensory supply to flap and lateral foot. Secondary defect was closed primarily. Results at 5 weeks of follow up showed well settled flap and healed wound.

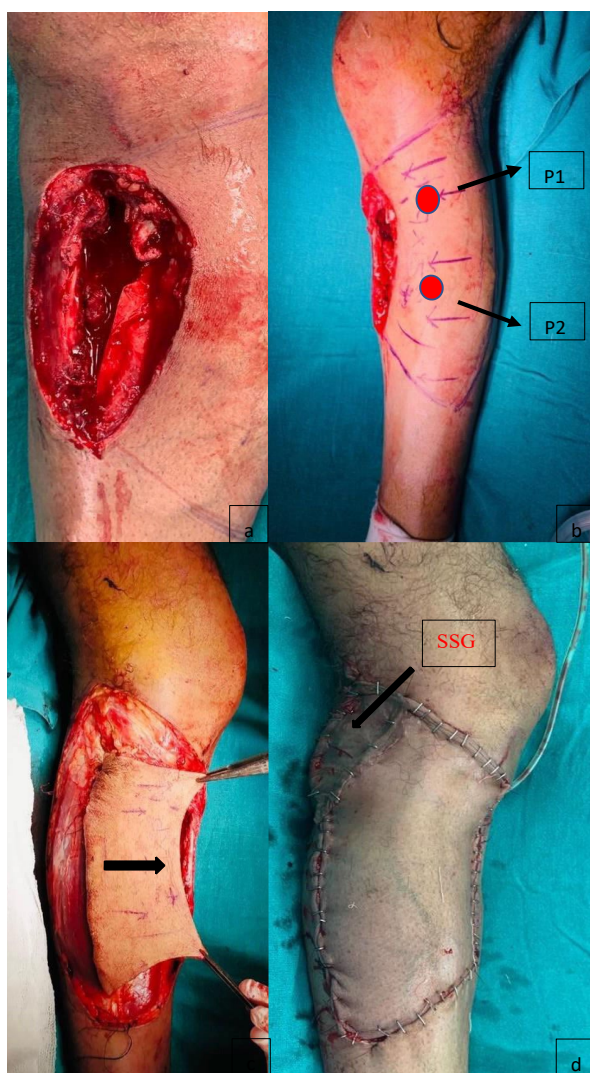


Figure 3: Clinical Case3. (a) Gustilo IIIa Compound fracture upper leg, wound measured 9 X 9 cm, (b) Two perforators P1 and P2 dopplered on medial aspect of wound and marked (arrowed), after debridement resultant defect measured 10 X 11 cm, Type IV Keystone flap chosen for reconstruction, (c) Flap incised circumferentially and advanced, (d) Upper one-third of donor area split skin grafted (SSG), immediate post-operative picture

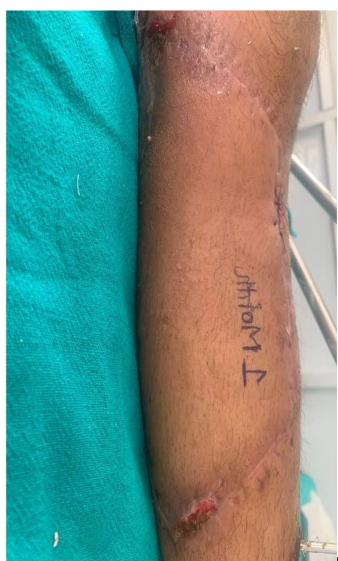

Figure 3: Clinical case 3. (e) Post operative result at 1 month of follow up

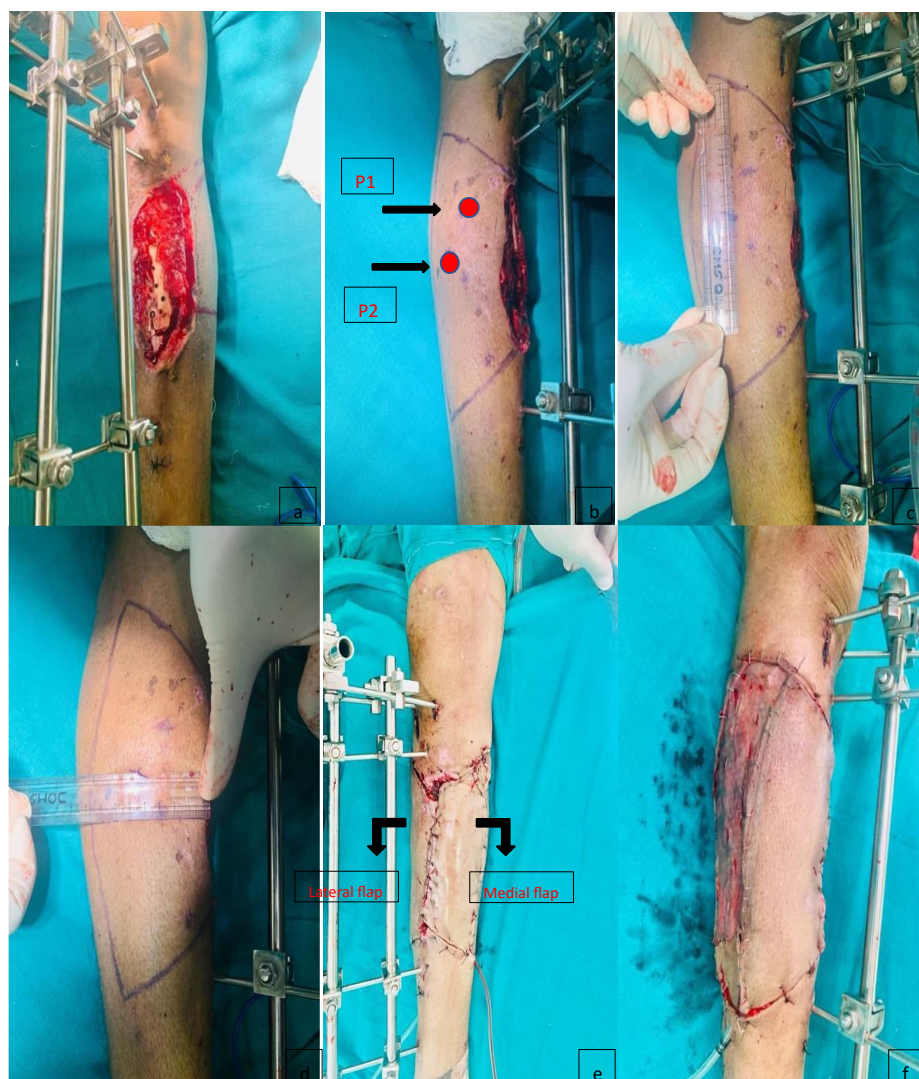


Figure 4: Clinical case 4. (a) Gustilo IIIA defect, after debridement resulting defect measured 17 X 8 cm, from lateral side Type IIB Keystone flap was chosen, (b) Lateral perforators P1, and P2 dopplered and marked (arrowed), (c) and (d) Showing flap measuring 17 cm long and 8 cm wide, (e) Type IIA medial and lateral Keystone flaps advanced towards each other, two separate drains inserted and inset given, Immediate post-operative result, (f) Donor site of lateral flap grafted and of medial flap primarily closed



Figure 4: Clinical case 4. (g) Post-operative outcome at 7 months of follow up

Clinical case 9. (Figure 9a-d). A 20-yr male had exit wound over medial aspect of foot due to high tension line. Debridement resulted in defect measuring 4 x 3 cm with exposure of tendon of flexor hallucis longus (FHL). Primary closure was impossible because of glabrous skin and deep plantar fascia. Type IIA Keystone Flap was raised with sub-fascial undermining leaving pedicular area intact. Both defects were closed primarily. At 7 months of follow up, flap healed well with normal movement of big toe.

Clinical Case 10. (Figure 10a-f). A 70-yr male presented with chronic ulcer for 7 months over posterior heel following spoke wheel injury. Excision of ulcer resulted in exposure of underlying bone. Primary closure of circular defect measuring 4 X 4 cm was impossible. Type IIA Keystone flap was raised with sub-fascial undermining, leaving pedicular area intact. Glove drains were kept. Flap was advanced and final inset given. He telephonically reported about healed wound and was able to walk without discomfort.

In our case series all donor sites were closed primarily except for fifteen wherein split skin

grafting was done. Sutures were removed on 10th to 21st post-operative day. Follow-ups ranged from 1 month to 12 months. Three patients did not come for follow up due to various reasons.

RESULTS

In our series, all defects healed primarily except for three cases. One had wound dehiscence on 15th post-operative day managed with regular dressing and later on split skin grafting. Second had partial disruption of wound after 1 months of surgery due to underlying collection, repeated dressings were done and a transposition flap was designed from other healthy side of defect to provide cover (Figure 11a, b, c). Third case had limited wound disruption after two months on one side of suture line, after wound debridement, a transposition flap was designed from the body of previously positioned keystone flap to provide cover to exposed bone (Figure 12a, b). All the three wounds healed successfully. There was no major complication like flap loss. The flap in deltoid region and on clavicular region did not show any evidence of keloid formation at 8 and 12 months of follow-up. Average hospital stay was 5-7 d.

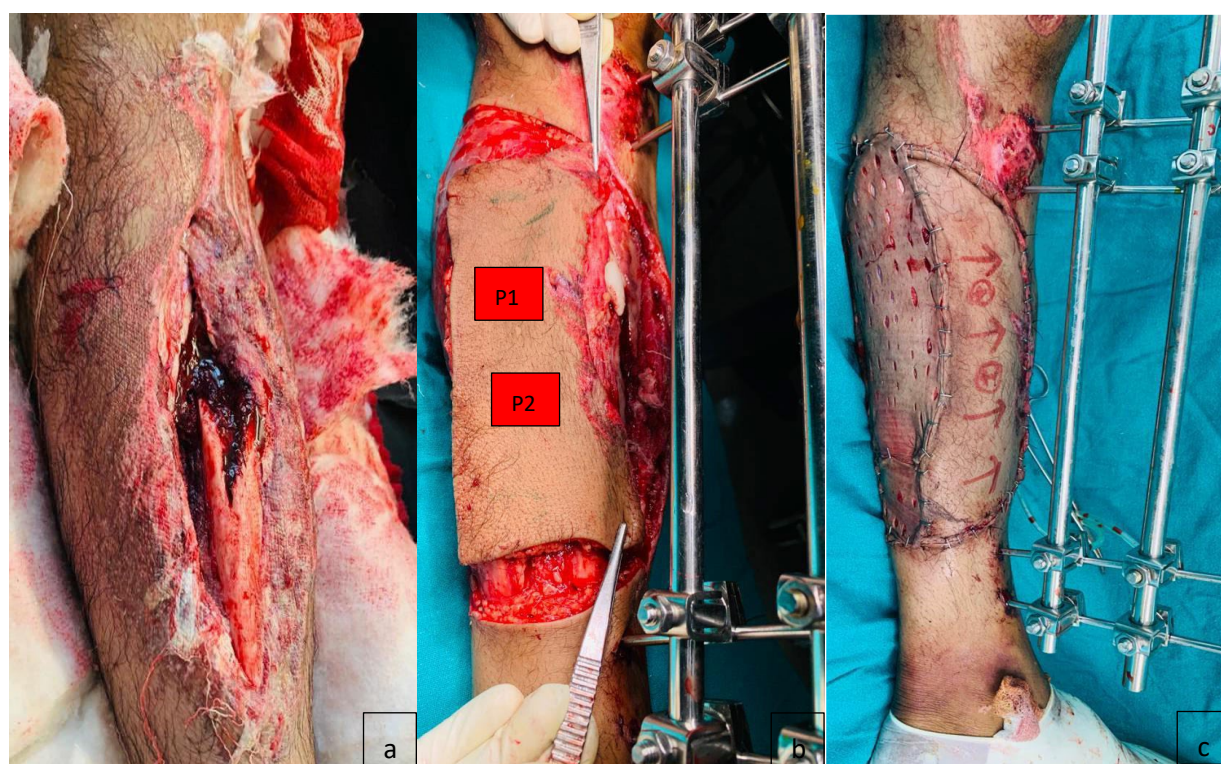


Figure 5: Clinical case 5. (a) Gustilo IIIB defect with fractured tibia, (b) External fixator applied, after debridement, resulting defect measured 16 X 6 cm, from medial side of wound the perforators dopplered (P1, P2) and marked Type IIB Keystone flap designed and elevated for reconstruction, (c) Immediate postoperative result

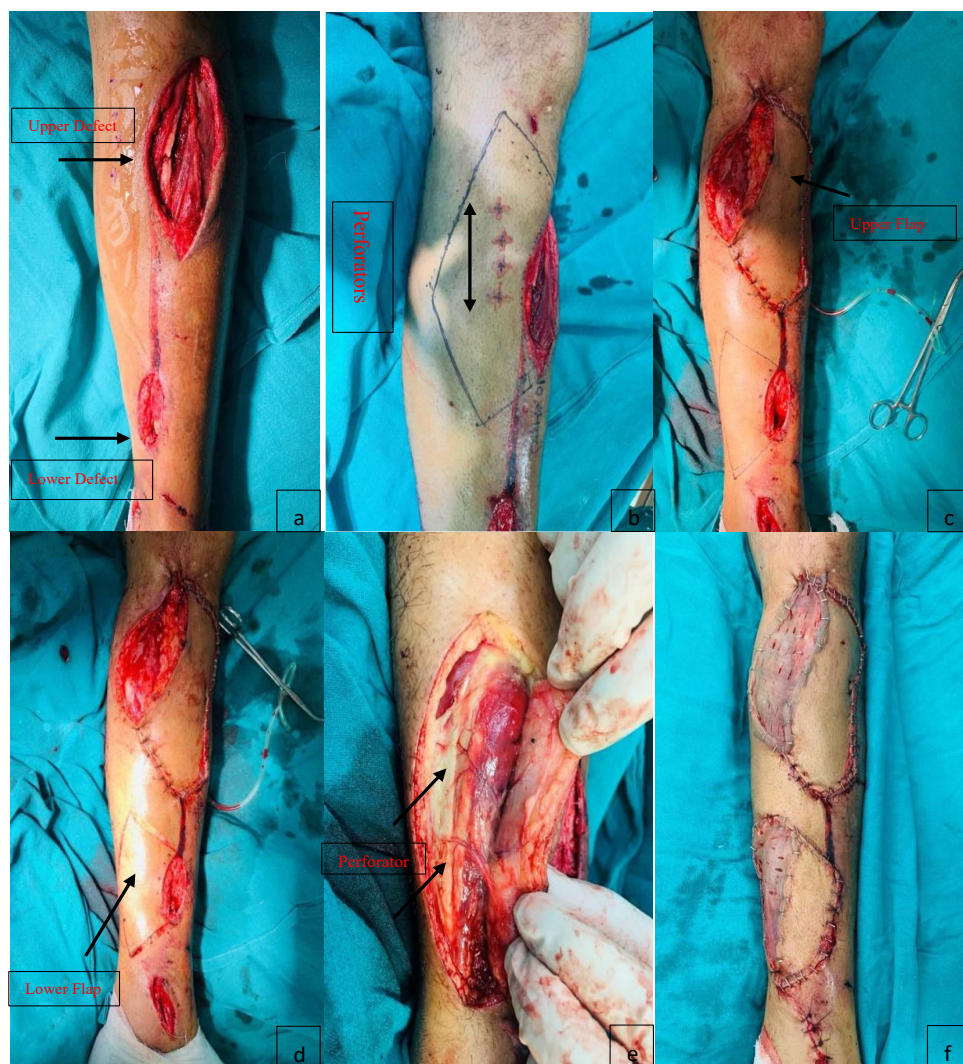


Figure 6: Clinical case 6. (a) Two separate post traumatic defects in leg (arrows), (b) Two separate Type IIB Keystone flaps designed for reconstruction. Medially the perforators dopplered and marked (arrow) for upper defect, (c) Upper Keystone flap designed (arrow) and advanced, (d) Perforators dopplered from medial side of lower defect, lower Keystone flap designed (arrow) and advanced, (e) Lower flap islanded on posterior tibial artery perforator (arrowed), (f) Immediate post-operative result of both defects

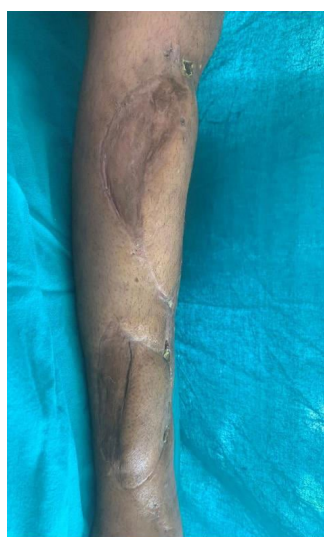

Figure 6: Clinical case 6. (g) Post-operative result at 14 months of follow up

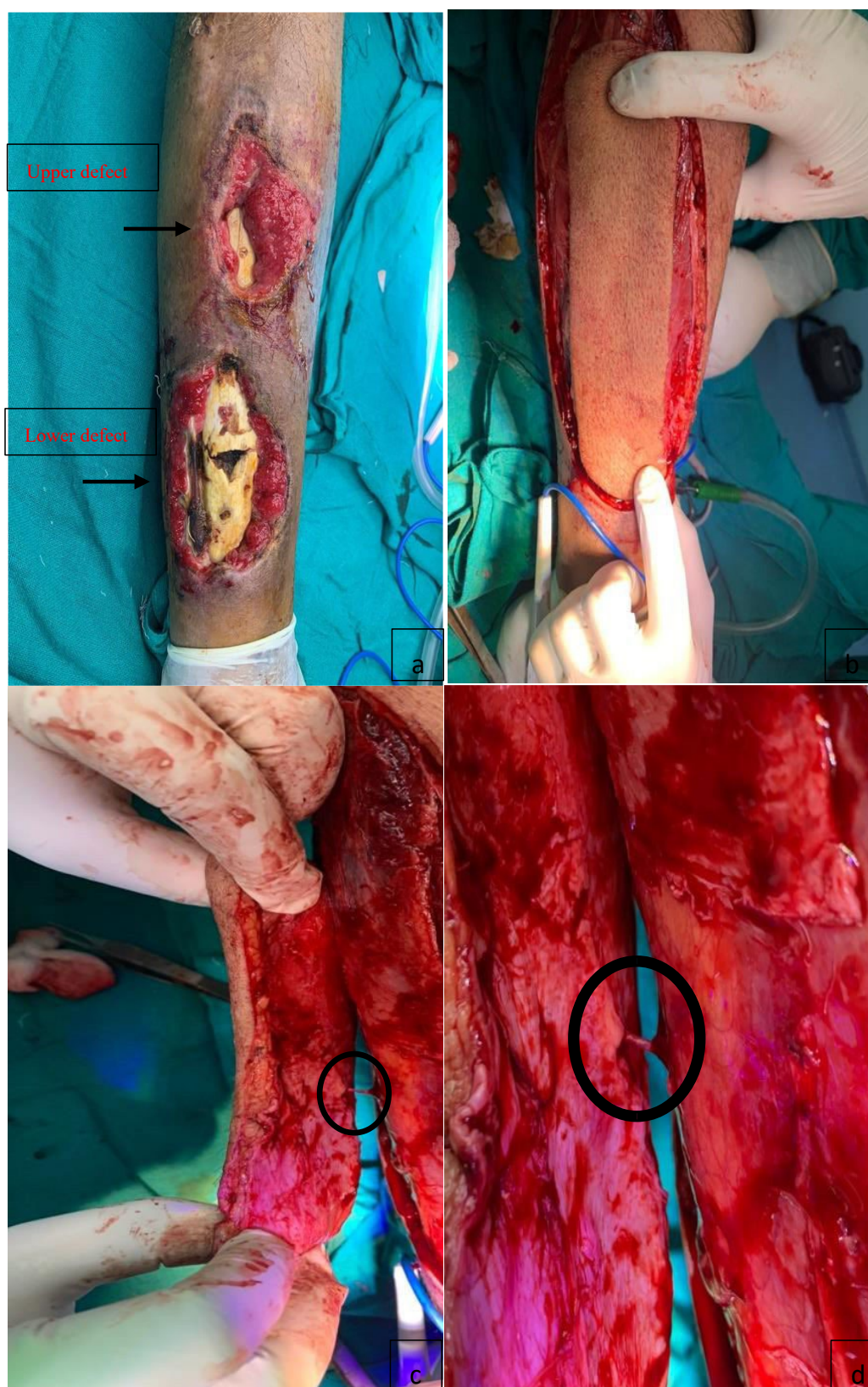


Figure 7: Clinical case 7. (a) Gustilo IIIB Two separate leg defects adjacent to each another, (b) Converted in to one large defect, one large Type IV Keystone flap designed for reconstruction and dissected circumferentially, (c) Flap islanded on single perforator (small circle), (d) Adequate release of all fascial strands around the perforator having good diameter and caliber (bigger circle). When contacted on his mobile phone, he reported complete healing of wound but did not come for follow up being asymptomatic

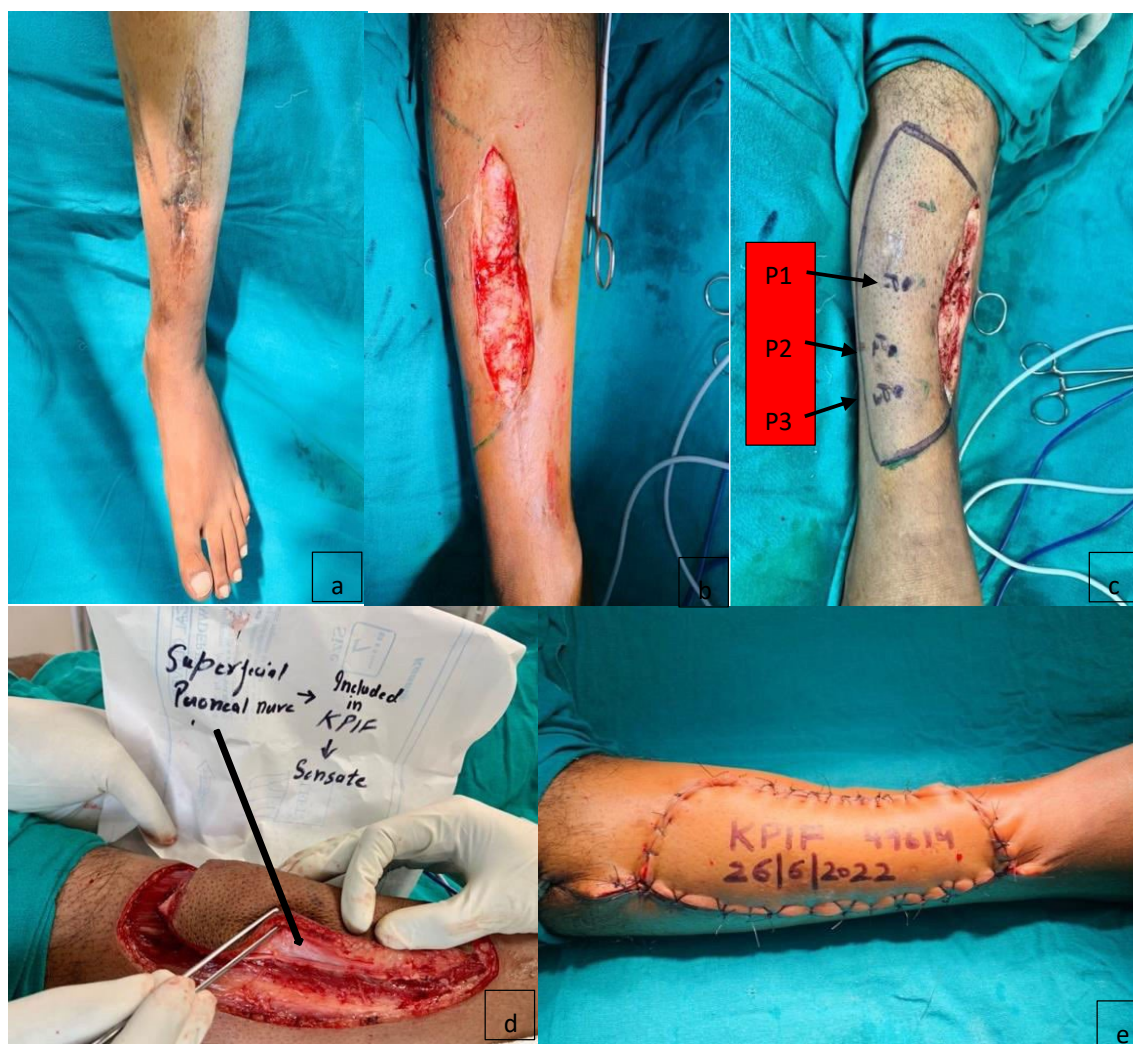

Figure 8: Clinical case 8. (a) Long unstable scar over shin of tibia, (b) Lesion excised elliptically with resultant defect measuring 10 X 4 cm, (c) Laterally, the perforators mapped by hand held doppler and marked (P1, P2, P3), Type IIA Keystone flap chosen for reconstruction, (d) During dissection, superficial peroneal nerve was encountered (arrowed) left intact and shifted with the flap, (e) Immediate post-operative picture

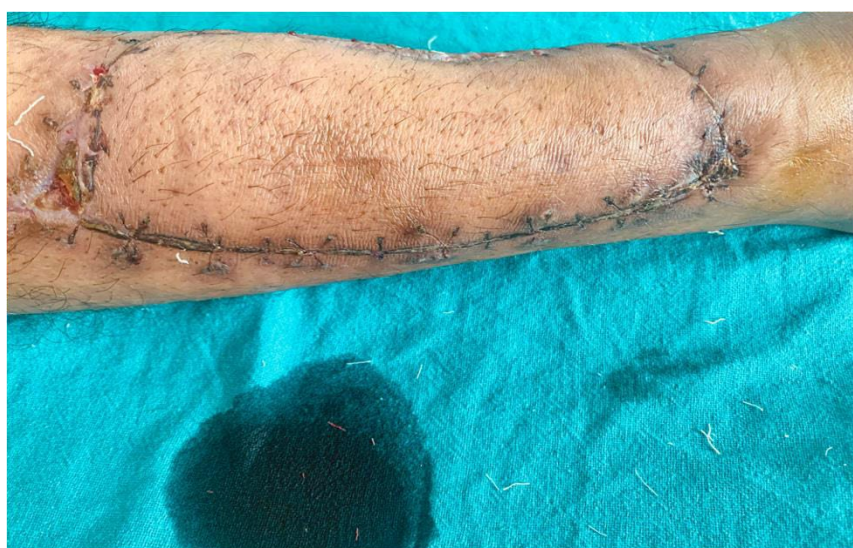

Figure 8: Clinical case 8. (f) Post-operative view at 5 weeks of follow up

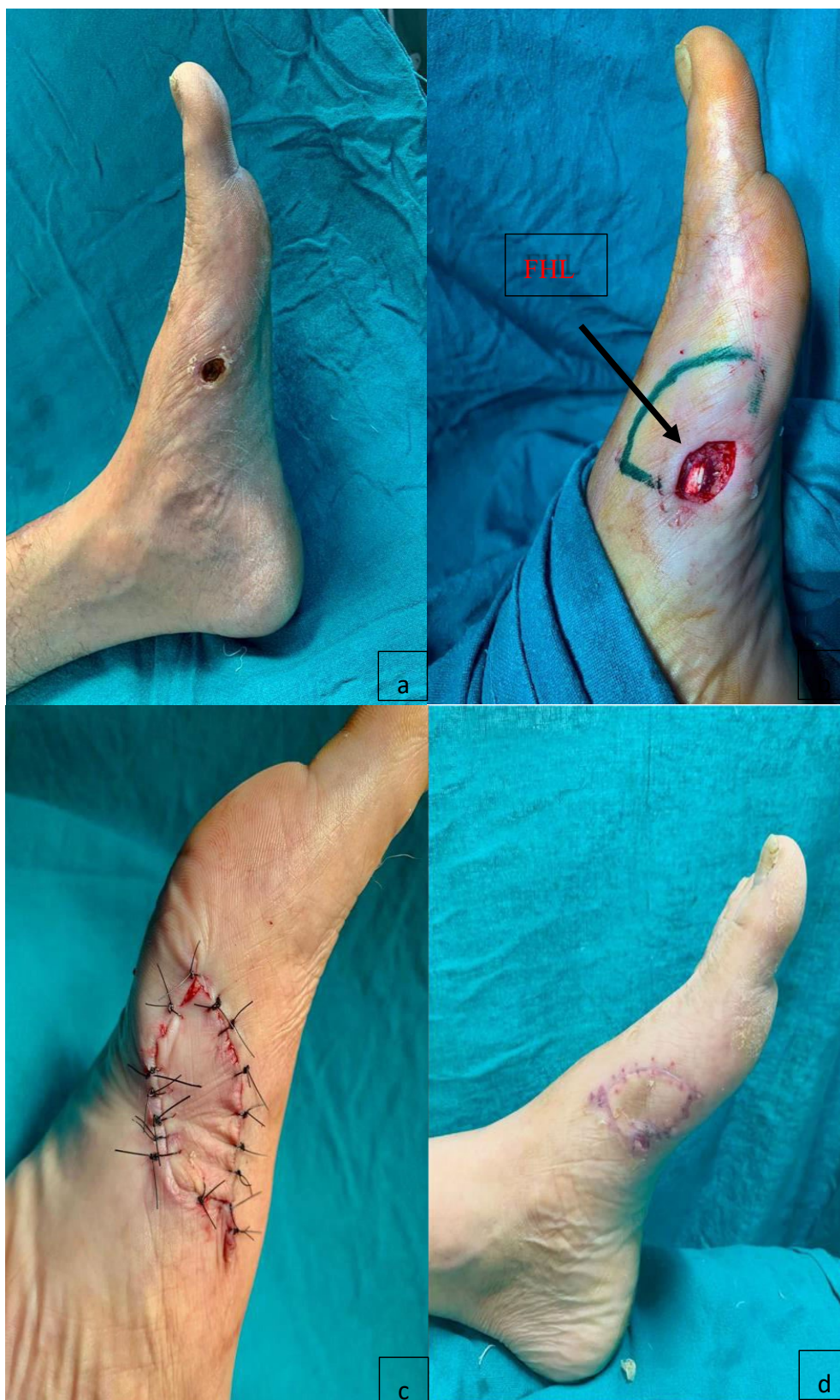

Figure 9: Clinical Case 9. (a) Exit wound over medial aspect of foot, (b) After debridement resultant defect measured 4 X 3 cm and flexor hallucis longus (FHL) tendon (arrowed) got exposed, Type IIA Keystone flap planned, (c) Immediate post-operative picture, (d) Post operative outcome at 7 months of follow up

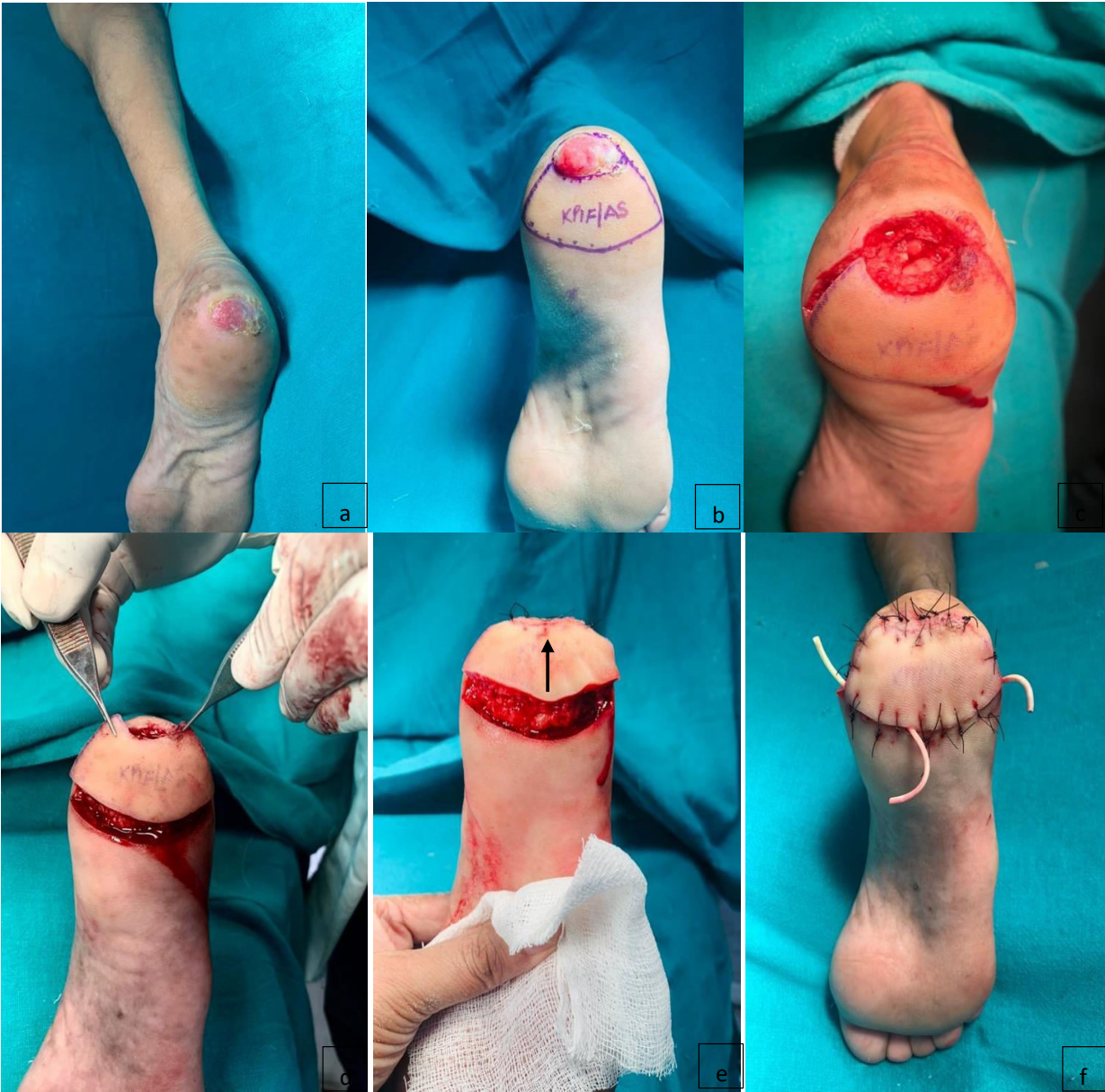

Figure 10: Clinical case 10. (a) Chronic ulcer over posterior heel, (b) Type IIA Keystone flap designed, (c) Excision of hypertrophic organized granulation on calcaneum, (d) Flap incised all around and elevated, (e) Flap advanced (arrow) and sutured, (f) Immediate post-operative result. On contacting, he was asymptomatic, ambulatory and busy in farming, therefore he did not come for follow up

Table 1: Anatomical distribution of Keystone Flaps

S. No	Anatomical location of defect.	Etiology.	Keystone flap (n)
1	Upper limb: Hand	Entry wound on thumb	2
2	Trunk: Upper chest	Chronic discharging sinus on clavicular area	1
3	Lower limb: Upper one-third of leg	Trauma caused by road traffic accident	6
	Middle one-third of leg	Trauma caused road traffic accident	10
	Lower one- third of leg	Trauma caused by road traffic accident	3
4	Shin region	Old post-traumatic long unstable scar	4
5	Foot region	Exit wound on medial aspect	3
6	Heel region	Post traumatic non-healing ulcer	3

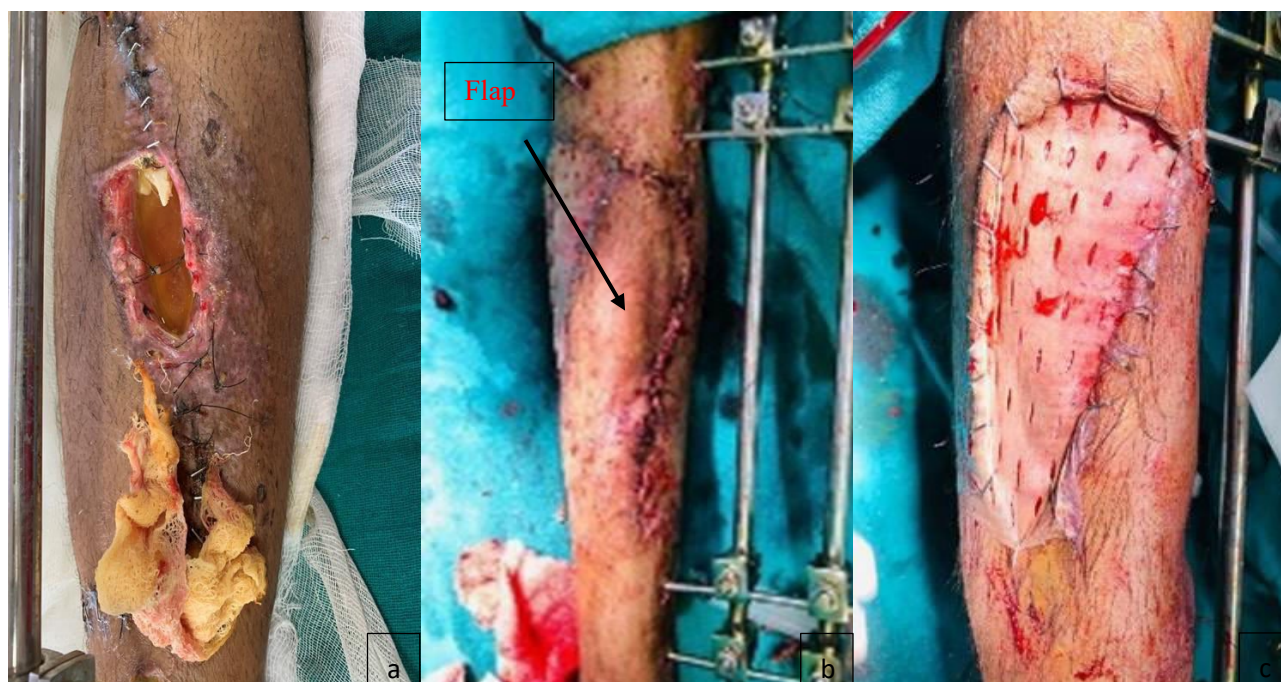

Figure 11: (a) Wound dehiscence after 1 months of follow up, (b) and (c) Wound resurfaced by transposition flap, raised from other side and its secondary defect split skin grafted (SSG)

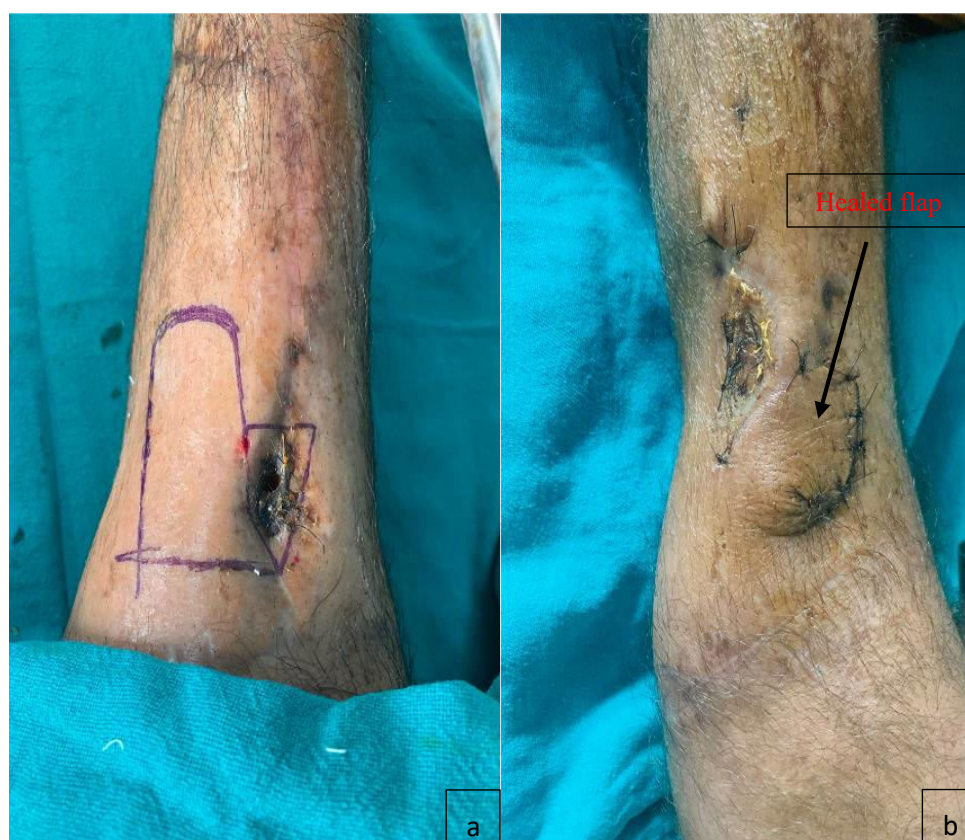

Figure 12: (a) Wound dehiscence at 2 months of follow up, Transposition flap designed from body of previously designed Keystone flap, (b) Post-operative result at 15th day with well settled flap and graft

DISCUSSION

Development of Keystone flaps has revolutionized the scenario of re-surfacing of small and medium to large skin defects with high success. In routine, dopplering of perforators and subfascial undermining ensures vascularity and increases mobility of flap. Extensive dissection around pedicular area could injure perforator plexus. Splints must be given for limbs for 4-5 d. Physiotherapy, graft pressure therapy, massage therapy must be advised in cases where skin grafting has been done. Post-operative immobilization, regular change of dressing, limb elevation and antibiotics are key points. Key surgical technique was to leave one-third attachment of deep surface to preserve random vascular integrity of flap to ensure viability. Since the innovation of Keystone flap, number of modifications have been done by different authors with different motives i.e., to (i) provide cover to circular defects³ and to keep a part of skin bridge intact on outer convex border of flap⁴, (ii) preserve 2/3rd of pedicular area during sub-fascial dissection of flap for maintaining maximum vascularity⁵, (iii) increase extent of advancement of flap by sub-fascial dissection of pedicular area up to 90% and retaining only 10%⁶, (iv) design and raise flap as random pattern without identifying perforators with hand held doppler and without fear of jeopardizing its vascularity because of presence of micro-perforators which cannot be localized by hand-held doppler⁷, (v) use for large trunk defects⁸ and islanding of flap and (vi) define hot spot theory and cold spot regions as specified by Mohan et al⁹. On an average 374 major perforators all over the body are described by Taylor and Palmer¹⁰.

The original classification of KDPIFs by Behan having four types¹ was added two more types of modification of keystone flaps i.e., (i) omega variant and (ii) Sydney melanoma unit modification⁴ (Figure 13).

Neuro-vascular response during flap elevation:

There is hyperemia in flap due to vasodilation shown by red-dot sign (Figure 14), after that there is vasoconstriction due to release of catecholamines by division of cutaneous and sympathetic nerves. Vascular flare is due to angiogenesis in flap^{1,6}. Postoperative period is pain free due to temporary denervation by division of cutaneous nerves.

PACES characteristics of Keystone flap given by Felix Behn^{1,6} which refers to “pain-free aesthetics appearance with minimal complication and efficiency” in both times for healing and operating.

- P. pain-free.
- A. aesthetics- ‘like with like’ obeying Gillis’s principle.
- C. complications- rarely seen.
- E. economics- the surgical timeframe is less.
- S. somatic - sensory recovery and swelling and edema resolves.

Compared to regional and distant (pedicled and free) flaps, Keystone flap have gained popularity because of under mentioned advantages, which are:

1. Simple bio-geometry (Figure 15).
2. Simple dissection.
3. Designed from head to toe.
4. Safe, sensate and reliable advancement flap based on perforators.
5. Application of Ilizarov apparatus for limb lengthening is possible through Keystone flaps.
6. Results are pleasing anatomically, functionally and aesthetically.
7. Technical easy with short learning curve.
8. Possible to design on pinchable skin anywhere.
9. Size of flaps could range from mini (4 mm) to large (28x16 cm) depending upon size of defect.
10. Possible to design single, double opposing and two separate flaps for distantly located defects.
11. Time and cost effective, minimal hospitalization, early return to work.
12. Property of adaptation and molding to cover elliptical, circular defects.
13. Post-operative period is painless and requires minimal medication and monitoring.
14. Vascular flap having uniformly distributed tension.
15. Signals on dopplering through islanded flap confirms its viability.
16. Possible to design on broad or on islanded pedicle.
17. Parallel and right-angle designed flaps are equally viable.
18. Axial and random pattern flaps are equally effective.
19. No risks of compartment syndrome in limbs.
20. Post-operative complications are wound dehiscence and temporary neuropraxia.
21. Possible to use as a propeller flap after islanding.
22. Can be raised under local, regional or general anesthesia.

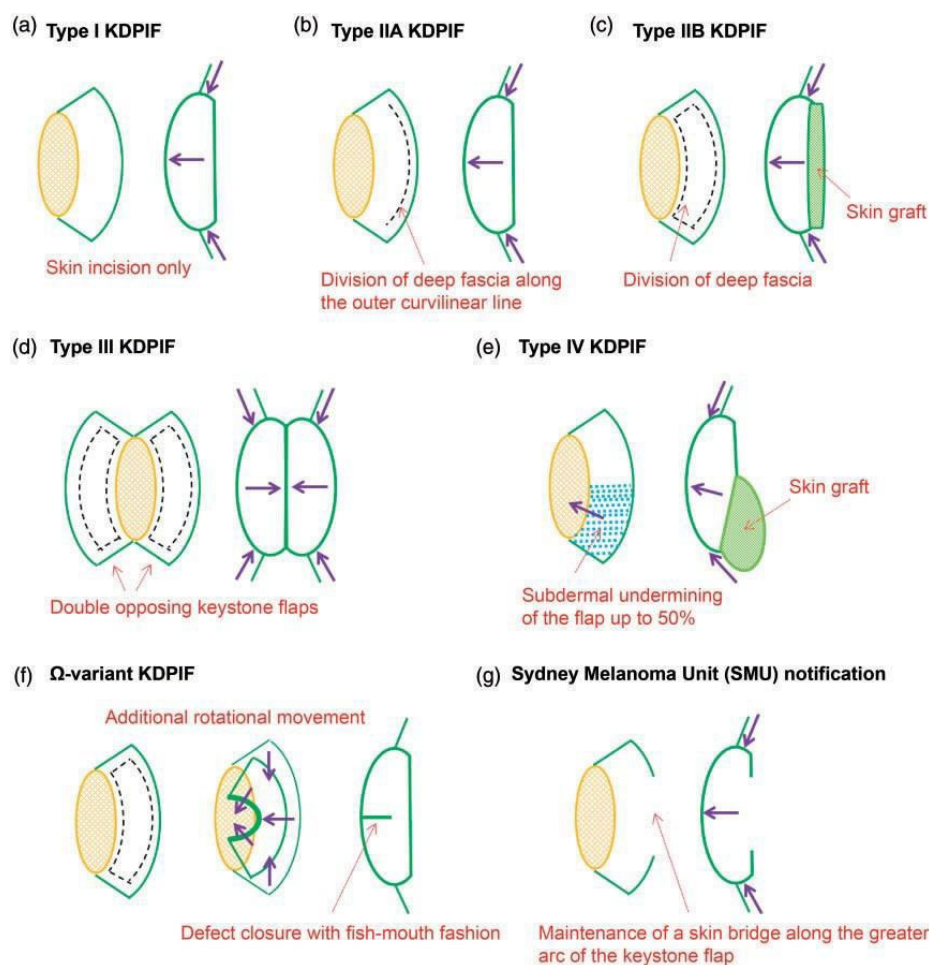


Figure 13: Schematic illustration of traditional classification and representative modifications of the keystone design perforator island flap (KDPIF). (a) Type I KDPIF (skin incision only). (b) Type IIA KDPIF (division of the deep fascia along the outer curvilinear line). (c) Type IIB KDPIF (division of the deep fascia and skin graft to the secondary defect). (d) Type III KDPIF (opposing keystone flaps designed to create a double-keystone flap). (e) Type IV KDPIF (keystone flap with undermining of up to 50% of the flap subfascially). (f) The omega-variant KDPIF (defect closure in fish-mouth fashion). (g) Sydney Melanoma Unit modification (maintenance of a skin bridge along the greater arc of the KDPIF)

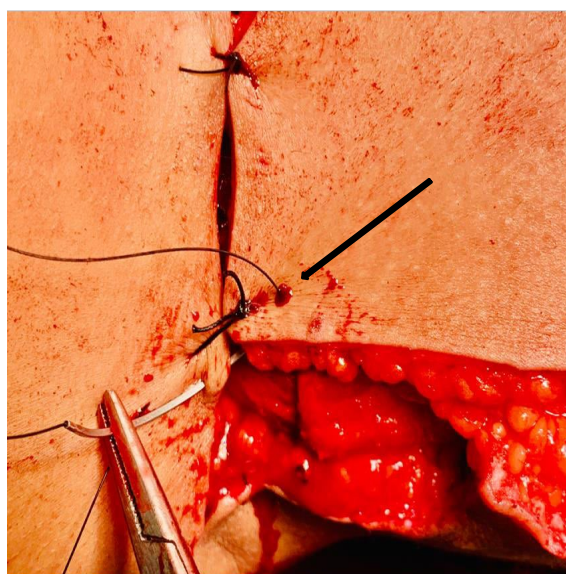


Figure 14: Red Dot sign seen while suturing (arrowed) because of increased vascularity due to vasodilation

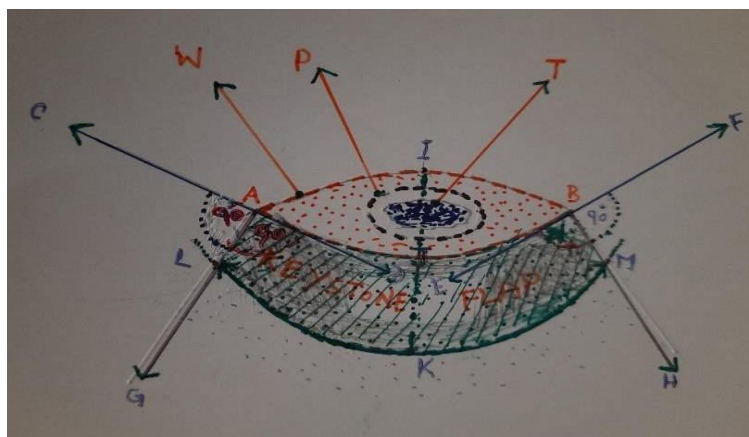


Figure 15: Standard Geometry of KDPIF. T- Tumor. P- Perimetry of excision. A and B- ends of elliptically created defect. W- Margin of defect adjacent to healthy intact skin. IJ- Width of defect. JK- Width of keystone flap. AJB- The concave margin of KDPIF is extended towards C and F. At point A and B, right angles are drawn towards G and H. From I, an arch is drawn with the divider opened twice the width of defect (I J) cutting BH and AG at point L and M. The tissue bounded by AJBMKLA is the keystone boundary. Division of deep fascia all around the flap will increase its movements of advancement.

Islanding the flap will further increase its advancement. The donor site must have plenty of dispensable loose and lax skin
(Drawn by Dr. Abhinav Singh. MS. MCh. Assistant Professor, AIIMS. Bhopal (MP). INDIA).

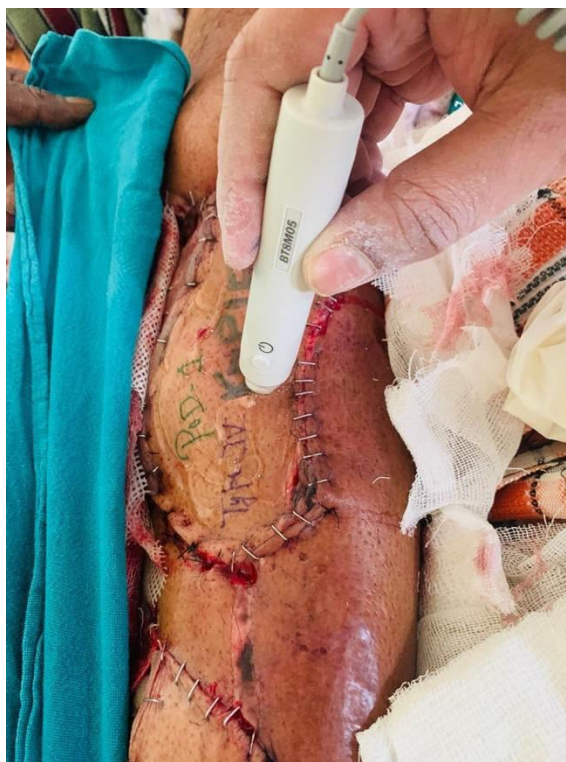

Figure 16: Checking perforator signals through flap at postoperative day one

23. Does not require sophisticated instruments, equipment and infra-structure or microsurgery.
24. Muscle flaps are avoided.
25. Easily practiced by beginners or residents.
26. No contour deformity.
27. Single operative field.
28. No dog ears.

29. Multiple micro perforators ensuring flap survival.
30. Provides tissue having similar color and texture.
31. Protective sensations are preserved.
32. Can be done as day care.
33. Superior to skin graft (rapid healing, aesthetics and weight bearing).
34. The previously-positioned flap can be safely

elevated from its bed after three weeks maintaining central 2/3rd pedicular area and advanced to provide flap cover to disrupted area.

35. A small local flap can be designed out of body of previously placed keystone flap to cover small disruption
36. Flap can successfully cover exposed bone, screws and implants.

Therefore, KDPF meets all requirements of surgeons and patients without any major post-operative complication, hence deserve to be designated as “omnipresent flap with universal safety”.

Disadvantages are: long scars beyond the limits of defect, does not have osseous component and can't be done in intranasal and intraoral defects.

Technical points that we learnt by these cases are:

convert the defect in elliptical or circular shape, design flaps on the side having greater skin laxity, design width of flap either equal or slightly larger than defect, if defect is not covered by single flap then design double opposing flaps having width smaller than defect width, asymmetrical designing of angles can be done if incision is crossing any joint crease, lymphatics basins or any neurovascular structure, type or modification of keystone flap must be decided intraoperatively and not pre-operatively, try to preserve hot spot area or center area of flap for perforators, localizing perforators facilitate more dissection and increased flap mobility, start suturing from center of flap where there is maximum tension then go to other areas for closure, if any nerve or vein encountered during dissection, try to preserve them, to prevent trapdoor deformity on face, give pressure garments or massage therapy post operatively, red dot sign during suturing¹³ is good response of flap, avoid keystone flap if defect is extensive or much of dead space is present there then, achieve meticulous hemostasis and put drain carefully, do proper bone fixation, can be designed for any size of defect (small to large), in leg plan flap from posterior compartment where greater laxity is present, aggressively undermining can be done to increase mobility of flap if known perforator is encountered, horizontal mattress suturing technique is useful in distributing tension all around the flap, flap viability can be ensured post-operatively by checking signals of perforators by hand held doppler, flaps can be done in emergency and during elective surgery, Omega or Sydney melanoma unit

modification flaps can be done on circular defects, avoid dissection around pedicular area to avoid perforator plexus injury, inflate tourniquet after marking of perforators by doppler, respect fascial aesthetic subunits, in questionable indication, other back up flaps should be planned, maintain proper position of operated part post-operatively, hand held doppler signals could be detected through advanced flap to ascertain its viability (Figure 16)

CONCLUSION

This flap is excellent reconstructive tool for Plastic surgeons, Orthopedic Surgeons and Dermatologists. Keystone flaps proved ideal with superior results with universal safety and uses in re-surfacing defects from head to toe with occasional minor post-operative wound disruption. It is based upon multiple perforators and does not require exhaustive post-operative monitoring. It provides sensate cover with minimal post-operative pain which allows early mobilization. Design-modification permits the use of flap in complex defects; therefore, it should be included in surgical armamentarium as a reliable tool for soft tissue reconstruction.

Disclosures

- 1- It was self-funded and no financial help was sought from any outside source.
- 2- There does not exist any academic or financial conflict among authors.
- 3- The clearance from ethical committee for this retrospective study was not required because this flap has been in use since long in different centers and this retrospective study is neither experimental nor research.

CONFLICT OF INTEREST

The authors declare that there is no conflict of interests.

REFERENCES

1. Behan FC. The Keystone design perforator island flap in reconstructive surgery. ANZ J Surg 2003; 73(3):112–120. doi:10.1046/j.1445-2197.2003.02638.x. PMID:12608972

2. Behan FC, Sizeland A. Keystone perforator island flaps in major head and neck surgery – The P.A.C.E. perspectives. *World J Surg Surg Res* 2021;4:1293.
3. Huang J, Kim CW, Wang X, Zhao Y, Yu N, Zhao R, et al. Successful application of modified Keystone flaps following skin tumor ablation. *Medicine (Baltimore)* 2019; 98(40):e17469. doi: 10.1097/MD.00000000000017469.
4. Kong YT, Kim J, Shin HW, Kim KN. Keystone flap with Omega variation and Sydney Melanoma Unit Modification to cover small-and moderate-sized defects in the anterior lower leg. *J Wound Manag Res* 2021;17(2):94–101. doi:10.22467/jwmr.2020.01452.
5. Behan FC, Rozen WM, Lo CH, Ashton MW, Hunter-Smith DJ, Findlay MW, et al. The omega-variant designs (Type A and B) of the Keystone perforator island flap. *ANZ J Surg* 2011;81(9):650–652. doi: 10.1111/j.1445-2197.2011.05833.x. PMID: 22295410.
6. Gomez OJ, Baron OI, Penarredonda ML. Keystone flap: overcoming paradigms. *Plast Reconstr Surg Glob Open* 2019;7(3):e2126 doi: 10.1097/GOX.0000000000002126.PMID:31044108;PMCID:PMC6467614.
7. Sinna R, Boloorchchi A, Mahajan AL, Qassemyar Q, Perrow R, Dardour JC, et al. What should define a “perforator flap”? *Plast Reconstr Surg* 2010; 126(6):2258–2263. doi: 10.1097/PRS.0b013e3181f61824. PMID: 21124168.
8. Rini IS, Gunardi AJ, Marsaulina RP, Aryandono T, Dachlan I, Dwiraphasto I. A systematic review of the Keystone design perforator island flap in the reconstruction of trunk defects. *Arch Plast Surg* 2020; 47(6):535–541. doi:10.5999/aps.2020.00094. Epub 2020 Nov 15. PMID: 33238340; PMCID: PMC7700866.
9. Mohan AT, Sur YJ, Zhu L, Morsy M, Wu PS, Moran SL, et al. The concepts of propeller, perforator, Keystone, and other local flaps and their role in the evolution of reconstruction. *Plast Reconstr Surg* 2016; 138(4):710e–729e. doi:10.1097/PRS.0000000000002610. PMID: 27673542.
10. Taylor GI, Palmer JH. The vascular territories (angiosomes) of the body: experimental study and clinical applications. *Br J Plast Surg* 1987; 40(2):113–141. doi: 10.1016/0007-1226(87)90185-8. PMID: 3567445.