

# Anatomical Variations of Anterolateral Thigh Flap: A Fresh Cadaver Dissection Study

Mahdi Gholami <sup>1,2</sup>, Baratollah Shaban <sup>2</sup>, Arya Hejazi <sup>3</sup>, Ghasem Sazegar <sup>4</sup>,  
Rashid Soufizadeh <sup>2\*</sup>

1. Oral & Maxillofacial Diseases Research Center, Mashhad University of Medical Sciences, Mashhad, Iran
2. Department of Oral and Maxillofacial Surgery, School of Dentistry, Mashhad University of Medical Sciences, Mashhad, Iran
3. Legal Medicine, Member of Legal Medicine Research Center, Legal Medicine Organization, Mashhad, Iran
4. Department of Anatomy and Cell Biology, School of Medicine, Mashhad University of Medical Sciences, Mashhad, Iran

## ABSTRACT

### BACKGROUND

The anterolateral thigh (ALT) flap is one of the fasciocutaneous flaps in the thigh region based on the septocutaneous or musculocutaneous perforators derived from the lateral circumflex femoral artery (LCFA). This cadaveric study aimed to explore the variability of ALT flap anatomy.

### METHODS

Ten ALT flaps were dissected (2016-20117, Mashhad Legal Medicine Organization) in 10 fresh cadavers (7 males and 3 females). Flaps were marked in a 15 cm area centered on the middle point of a line drawn from anterior superior iliac spine to the lateral surface of the patella. Dissection began by searching the skin perforators and then continued along the pathway of the vascular pedicle.

### RESULTS

The average distance of ASIS-Patella was 44.6 cm. The mean number of skin perforators was 2.4 (ranged from 0 to 4). In one case, we did not find any skin perforator. The majority of skin perforators were musculocutaneous from descending branch of LCFA (66.7%) and the remaining were septocutaneous (33.3%). The mean length of vascular pedicle was 10.17 cm. The average diameter of vascular pedicle was 2.78 mm for the artery and 3.79 mm for the vein. The average time of flap harvesting was 85.3 min (ranged from 50 to 125 min).

### CONCLUSION

The skin perforators supplying the ALT flap showed significant variability in number, location and course. The cadaveric study could enhance the anatomic knowledge and operative skills of ALT flap harvesting.

### KEYWORDS

Anterolateral thigh flap; Cadaveric study; Skin perforator

### Please cite this paper as:

Gholami M., Shaban B., Hejazi A., Sazegar G., Soufizadeh H. Anatomical Variations of Anterolateral Thigh Flap: A Fresh Cadaver Dissection Study. *World J Plast Surg.* 2021;10(2):18-24.  
doi: 10.29252/wjps.10.3.18

### \*Corresponding Author:

Rashid Soufizadeh

Department of Oral and Maxillofacial Surgery, School of Dentistry, Mashhad University of Medical Sciences, Mashhad, Iran.

Tel.: +98-9112743156

Email: rashidsoufizadeh@mums.ac.ir

Received: 04 Sep 2019

Revised: 18 Oct 2020

Accepted: 2 September 2021

## INTRODUCTION

The anterolateral thigh (ALT) flap is one of the fasciocutaneous flaps in the thigh based on the septocutaneous or musculocutaneous perforators derived from the lateral circumflex femoral artery (LCFA). The LCFA has 3 main branches names ascending, transverse and descending and in some cases a fourth branch named innominate. The main branch of LCFA that gives perforators to ALT flap is descending branch<sup>1-4</sup>. The

ALT flap was first described by Song et al in 1984 as a flap based on septocutaneous vessels running in between the rectus femoris and vastus lateralis muscles<sup>5-7</sup>. However, in the majority of cases there were only musculocutaneous perforators and both septocutaneous and musculocutaneous perforators could originate from vessels other than the descending branch of the lateral femoral circumflex artery<sup>6-8</sup>.

This flap has a vascular pedicle with good length and diameter and the donor site can easily be primary closed, but the main disadvantage of this flap is variety of its vascular supply that make it more technique sensitive and difficult to perform<sup>9</sup>.

In this study, we describe the anatomic variations of ALT flap and its vascular supply characteristics based on dissection of flap on fresh cadavers.

## METHODS AND MATERIALS

This study approved by Ethics Committee of Mashhad University of medical Science by referral code IR.mums.sd.REC.1394.323.

We did 10 ALT flaps on fresh cadavers and evaluated some features of it. The parameters we assessed were:

1. ASIS – Patella distance (in centimeter)
2. Origin of perforators
3. number and type of perforators in flap (cm)
4. distance of perforators from ASIS (cm)

5. length of vascular pedicle from cut point to the first perforator (cm)

6. diameter of artery and vein in origin of vascular pedicle (cm)

7. harvesting time duration (in min)

The type of perforators classified as musculocutaneous or septocutaneous perforators.

Branches of LCFA for defining origin of perforators divided in; ascending, transverse, descending and innominate.

The flap harvesting technique that we used was the sub-fascial technique and the operation steps were: With the patient in the supine position, a line is drawn from the anterior superior iliac spine (ASIS) to the super lateral border of the patella. This line represents the intermuscular septum between the rectus femoris and

Vastus lateralis (VL) muscles. Next, a circle with a 5 cm radius is marked at the midpoint of this line. The required size of the skin flap is then marked incorporating this circle in a fusiform (Figure 1).

We started dissection from medial border of designed flap in subfascial plane. The incision made through the deep fascia, the flap raised laterally for a short distance until the intermuscular septum between the rectus femoris, and vastus lateralis is reached. Then dissection of lateral border of flap started until we got to the septum (Figure 2).

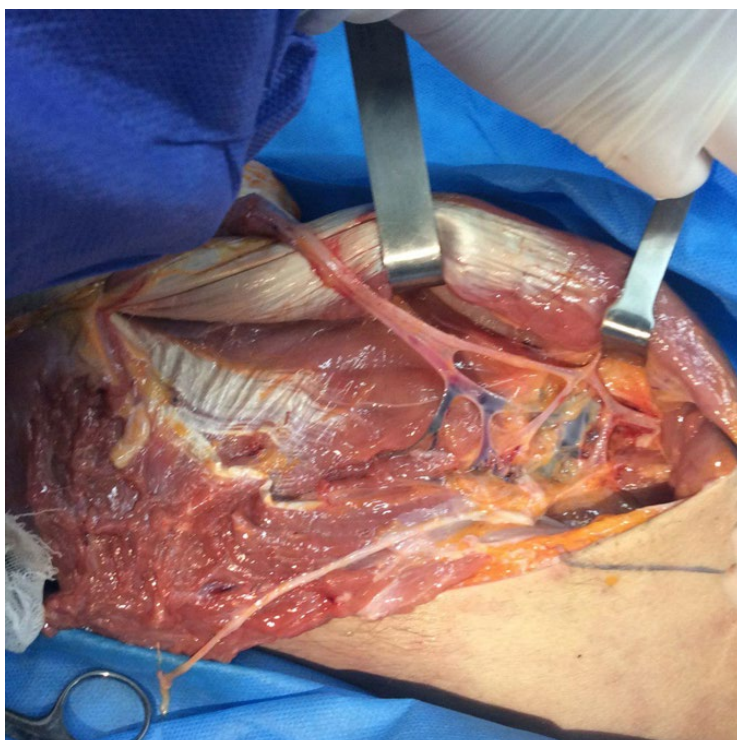
The vessels supplying the skin are either

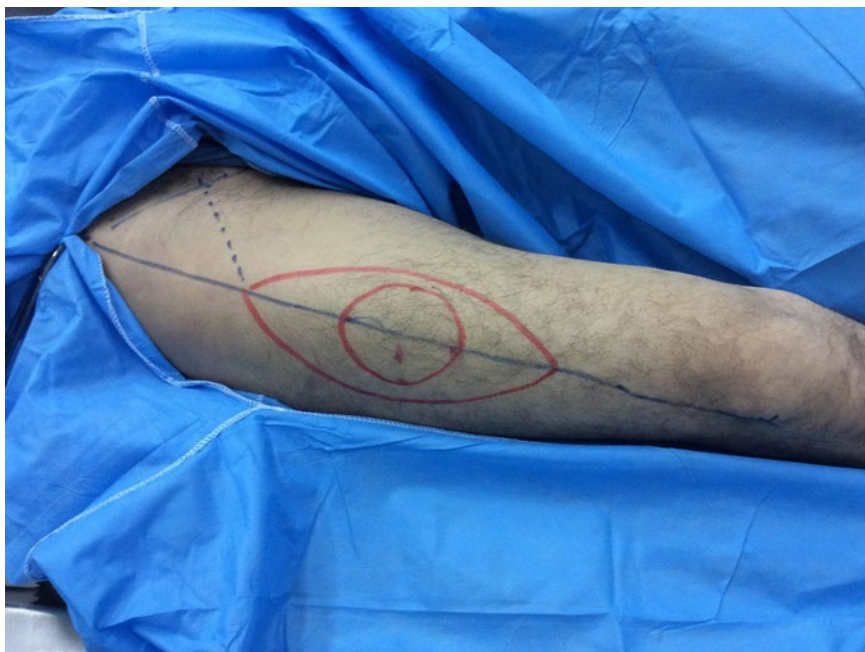
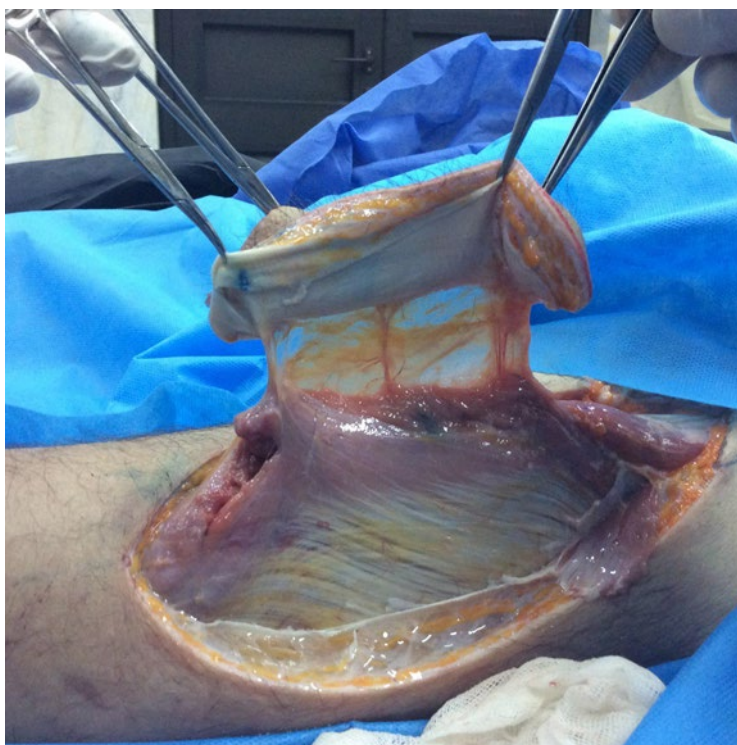
Fig. 1: Design of fusiform flap around a middle circle



**Fig. 2:** Completion medial and lateral border of flap and perforators seen in flap



**Fig. 3:** LCFA and its branches as vascular pedicle of flap

septocutaneous or musculocutaneous perforators and commonly lie within this septum. If the vessel supplying the flap is a septocutaneous vessel,

this is simply mobilized and flap harvest can be expediently completed. For musculocutaneous perforators, intramuscular dissection is needed for

Table 1: Demographic data

Case	Gender	Age (yr)
1	M	50
2	M	60
3	M	45
4	M	55
5	M	35
6	M	60
7	M	45
8	F	40
9	F	60
10	F	35
<b>Mean</b>	<b>F= 3 , M=7</b>	<b>48.5</b>

Table 2: Perforator's information

Case	Number of perforators	MC-D	MC-T	SC-D	SC_T
1	3	1	0	2	0
2	3	2	0	1	0
3	4	2	0	2	0
4	2	1	0	1	0
5	2	1	0	1	0
6	3	3	0	0	0
7	1	0	1	0	0
8	3	2	0	0	1
9	3	3	0	0	0
10	0	0	0	0	0
<b>Sum</b>	<b>24</b>	<b>15</b>	<b>1</b>	<b>7</b>	<b>1</b>
<b>Mean</b>	<b>2.4</b>	<b>1.5</b>	<b>0.1</b>	<b>0.7</b>	<b>0.1</b>

MC-D: Musculocutaneous from Descending  
 SC-D: Subcutaneous from Descending

MC-T: Musculocutaneous from Transverse  
 SC-T: Subcutaneous from Transverse

mobilization. Dissection starts with the unroofing of the muscle covering the perforator. The septum is then explored by using a Metzsenbaum scissor until we find the vascular branch that perforators come from. Dissecting scissors are inserted into this plane and the muscle above it gently tented up. The perforator can thus be traced from the point it pierces the deep fascia to the point it joins the main pedicle. Once traced to the main branch, the fascia layer covering the pedicle is cut. The main branch distal to the point at which the perforator joins the pedicle can be ligated and divided.

The flap can then be completely islanded. The flap is lifted gently off its bed, presenting the inferior surface of the perforator to the surgeon. The surgeon

lifts the flap gently off its bed with his nondominant hand while the assistant retracts the muscle laterally and inferiorly with retractors. This clearly presents the posterior aspect of the perforators. The pedicle is mobilized proximally and harvested at a point just proximal to descending branch's beginning point, which is the main vessel supplying the flap (Figure 3). To measuring the diameter of artery and vein in origin of vascular pedicle, we used a rhinoplasty caliper and a digital caliper with accuracy of 0.01 mm.

The flap was restored to its place after completion of measurements.

The collected data were analyzed using Microsoft excel 2010 and reported as mean (averages) values.



**Table 3:** Characteristics of vascular pedicle

Case	Length of pedicle(cm)	Diameter of Artery(mm)	Diameter of Vein(mm)
1	10	3.1	5
2	11.5	1.7	2.5
3	11	3	5
4	11	3.8	3.1
5	9	2.3	4.5
6	10	3.2	3.8
7	10	2.1	4.1
8	9	2.8	4.2
9	10	3	1.9
<b>Mean</b>	10.17	2.78	3.79

**Table 4:** Information about distances to ASIS

Case	ASIS-Patella (cm)	ASIS-Perforator1 (mm)	ASIS-Perforator (mm)	ASIS-Perforator3 (mm)	ASIS-Perforator4 (mm)
1	40	16	20	24	-
2	42	18	20	22	-
3	46	21	23	29	31
4	46	19	27	-	-
5	46	20	23	-	-
6	47	18	22	27	-
7	43	16.5			-
8	48	18	22	25	-
9	46	16	25	32	-
10	42	-	-	-	-
<b>Mean</b>	44.6	18.05	22.75	26.5	31
<b>Mean</b>			24.57		

**Table 5:** Harvesting time

Case	1	2	3	4	5	6	7	8	9	10	Mean
Time	105	125	95	115	75	95	60	75	50	58	85.3

## RESULTS

We had 3 female and 7 male cadavers and worked on 4 Right and 6 Left legs (Table 1).

We found 24 perforators from 10 ALT flaps. The mean of perforator's number was 2.4. In 1 case we did not any perforator and maximum of perforators that we found was 4 perforators in 1 case. Sixteen (66.7%) perforators were musculocutaneous and 8 (33.3%) of them were septocutaneous. Moreover, 22 (91.7%) perforators were from descending branch of LCFA and 2 (8.3%) of them were from transverse branch of LCFA (Table 2).

The mean length of vascular pedicle of flap was 10.17cm. The average diameter of pedicle's artery

and vein were 2.78mm and 3.79mm (Table 3).

The mean distance of ASIS-Patella was 44.6 (40-48cm). The mean distance between the ASIS and perforators was 24.57 cm (Table 4).

The average time for harvesting of flap was 85.3 min and the range of harvesting time was between 50 to 125 min (Table 5).

## DISCUSSION

Reconstruction of head and neck defects is always a challenge for surgeons. Most of these defects were reconstructed with a pedicled skin flap from adjacent areas<sup>9</sup>. In the past two decades, the use of free tissue transfer of microvascular free flaps has become

common. In these flaps, one part of the patients own body is transferred to another region and because the vessels from donor site is transferred to recipient site, we call them ((Free))<sup>10,11</sup>.

In our review of ALT flap, most of the perforators were musculocutaneous that passed through VL muscle. This finding was similar to Valdatta and Smith<sup>12,13</sup>. Designing of ALT flap based on musculocutaneous perforators and including a cuff of VL muscle to protect these perforators from damaging during dissection, can be helpful in flap survival. This was mentioned in a study on cadavers<sup>14</sup>. However, septocutaneous perforators also exist in few percent of ALT flaps and because of easier dissection compared to musculocutaneous perforators, their integrity can be assessed during and after flap harvesting. In our study, septocutaneous perforators consisted 33.3% of overall perforators.

Most of the perforators in our study were from descending branch of LCFA and only two perforators were from transverse branch of LCFA. This was similar to another study<sup>15</sup>.

When perforators originate only from descending branch, dissection of flap is easier, because there is no need to extend the dissection to find the transverse branch and so, the flap harvesting procedure will be faster.

The mean length of vascular pedicle in our species was 10.17 cm, which is similar to other studies. For example in a study this value was 11.4 cm<sup>16</sup>. Racial differences, technique of surgery and surgeon's decision during surgery can affect the pedicle length. Racial differences as an influencing factor on vascular anatomy of region is stated<sup>9</sup>.

In our study, the mean diameter of artery of vascular pedicle was 2.7 mm and the mean diameter of vein was 3.79 mm. This diameter of artery and vein make the anastomosis of them to head and neck vessels easier. There is no similar study which evaluates the diameter of vessels of vascular pedicle in ALT flap as a determinant factor on be suitable of them for anastomosis in head and neck area and most of studies evaluate the vascular pedicle length and sometimes the diameter of perforators<sup>17</sup>.

The diameter of vessels of vascular pedicle is important because microvascular anastomosis practices usually done on the vessels with 0.8-1.5 mm diameter on animals and presence of artery and vein with such a diameter can make the anastomosis easier for a trained surgeon<sup>18</sup>.

The mean distance of perforators was 24.75 cm and according to mean distance of ASIS-Patella (44.6 cm), considering the midpoint of ASIS-Patella distance and drawing a circle with 5cm radius around this point, can help in finding the proper perforators.

According to Kimata et al, in 5.4% of designed flaps there were no perforators<sup>15</sup>. In our study, we did not find any perforator in one case. In surgical procedures on patients, in this situations that there is no perforator in anterolateral side of leg, treatment plan can be changed to anteromedial thigh flap or other leg can be used to harvest an ALT flap.

One of the problems we may encounter during flap harvesting is very fatty leg that makes the flap harvesting harder. We had one case with huge and fatty leg that flap harvesting and finding the perforators was harder than other samples.

Another problem that we had during flap harvesting was the presence of femoral nerve adjacent to descending branch of LCFA. The nerve was very close to descending branch in some cases and it was ruptured due to dissection and traction. Lots of studies reported the presence of this nerve adjacent to descending branch and emphasized on carefully dissection in this area to prevent damages to it<sup>4,12,19</sup>.

## CONCLUSION

The skin perforators supplying the ALT flap showed significant variability in number, location and course. The cadaveric study could enhance the anatomic knowledge and operative skills of ALT flap harvesting.

## ACKNOWLEDGMENTS

All authors declare that they have no financial relationships to this article.

## CONFLICT OF INTEREST

The authors declare no conflict of interest.

## REFERENCES

- Shieh SJ, Chiu HY, Yu JC, Pan SC, Tsai ST, Shen CL. Free anterolateral thigh flap for reconstruction of head and neck defects following cancer ablation. *Plast Reconstr Surg* 2000;**105**(7):2349-57. doi: 10.1097/00006534-200006000-00006.

2. Rolski D, Kostrzewa-Janicka J, Zawadzki P, Zycinska K, Mierzwinska-Nastalska E. The Management of Patients after Surgical Treatment of Maxillofacial Tumors. *Bio Med Res Int* 2016;**2016**:7. doi: 10.1155/2016/4045329
3. Ren ZH, Wu HJ, Wang K, Zhang S, Tan HY, Gong ZJ. Anterolateral thigh myocutaneous flaps as the preferred flaps for reconstruction of oral and maxillofacial defects. *J Craniomaxillofac Surg* 2014;**42**(8):1583-9. doi: 10.1016/j.jcms.2014.04.012.
4. Kuo YR, Seng-Feng J, Kuo FM, Liu YT, Lai PW. Versatility of the free anterolateral thigh flap for reconstruction of soft-tissue defects: review of 140 cases. *Ann Plast Surg* 2002;**48**(2):161-6. doi: 10.1097/00000637-200202000-00008
5. Song YG, Chen GZ, Song YL. The free thigh flap: a new free flap concept based on the septocutaneous artery. *Br J Plast Surg* 1984;**37**(2):149-59. doi: 10.1016/0007-1226(84)90002-x.
6. Wong CH, Wei FC. Anterolateral thigh flap. *Head Neck* 2010;**32**(4):529-40. doi: 10.1002/hed.21204.
7. Koshima I, Fukuda H, Utunomiya R, Soeda S. The anterolateral thigh flap; variations in its vascular pedicle. *Br J Plast Surg* 1989;**42**(3):260-2. doi: 10.1016/0007-1226(89)90142-2.
8. Koshima I, Fukuda H, Yamamoto H, Moriguchi T, Soeda S, Ohta S. Free Anterolateral Thigh Flaps for Reconstruction of Head and Neck Defects. *Plast Reconstr Surg* 1993;**92**(3):429-30.
9. Lim S, Atwi N, Long S, Toshav A, Lau FH. Abstract: Variations in the Anterolateral Thigh Flap's Vascular Anatomy in African Americans. *J Reconstr Microsurg* 2017;**5**(9 Suppl):96. doi: 10.1055/s-0037-1604087.
10. Zhang Q, Qiao Q, Gould LJ, Myers WT, Phillips LG. Study of the neural and vascular anatomy of the anterolateral thigh flap. *J Plast Reconstr Aesthet Surg* 2010;**63**(2):365-71. doi: 10.1016/j.bjps.2008.09.028.
11. Nierengarten MB. The Revolution and Evolution of Free Flaps in Facial Reconstructive Surgery. <http://www.enttoday.org/article/the-revolution-and-evolution-of-free-flaps-in-facial-reconstructive-surgery> (1 September 2013)
12. Valdatta L, Tuinder S, Buoro M, Thione A, Faga A, Putz R. Lateral circumflex femoral arterial system and perforators of the anterolateral thigh flap: an anatomic study. *Ann Plast Surg* 2002;**49**(2):145-50. doi: 10.1097/00000637-200208000-00006.
13. Smith RK, Wykes J, Martin DT, Niles N. Perforator variability in the anterolateral thigh free flap: a systematic review. *Surgical and radiologic anatomy. Surg Radiol Anat* 2017;**39**(7):779-89. doi: 10.1007/s00276-016-1802-y.
14. Kavita M, S. LT, Vinaya C. Vascular Anatomy of Anterolateral Thigh Flap. *Laryngoscope* 2008;**118**(4):589-92. doi: 10.1097/MLG.0b013e31815ed0e8.
15. Kimata Y, Uchiyama K, Ebihara S, Nakatsuka T, Harii K. Anatomic variations and technical problems of the anterolateral thigh flap: a report of 74 cases. *Plast Reconstr Surg* 1998;**102**(5):1517-23. doi: 10.1097/00006534-199810000-00026.
16. Eitezaz FA, Rashid M, Yousaf S, Ur-Rehman I, Fatima S, Masud M, et al. Can The Anterolateral Thigh Flap Replace The Rectus Abdominis Free Flap In The Reconstruction Of Complex Maxillary Defects?. *J Ayub Med Coll Abbottabad* 2018;**30**(1):74-7.
17. Kawai K, Imanishi N, Nakajima H, Aiso S, Kakibuchi M, Hosokawa K. Vascular anatomy of the anterolateral thigh flap. *Plast Reconstr Surg* 2004;**114**(5):1108-17. doi: 10.1097/01.prs.0000135332.97062.7f.
18. Yonekawa Y, Frick R, Roth P, Taub E, Imhof H-G. Laboratory training in microsurgical techniques and microvascular anastomosis. *Oper Neurosurg* 1999;**2**(3):149-58. doi: 10.1016/S1092-440X(99)80007-3.
19. Park CW, Miles BA. The expanding role of the anterolateral thigh free flap in head and neck reconstruction. *Curr Opin Otolaryngol Head Neck Surg* 2011;**19**(4):263-8. doi: 10.1097/MOO.0b013e328347f845.