

# Functional and Aesthetic Outcomes of the Anterolateral Thigh Flap in Reconstruction of Upper Limb Defects: A Systematic Review

Ahmed Hagiga <sup>1\*</sup>, Mohamed Aly <sup>2\*</sup>, Murtaza Kadhum <sup>1</sup>, Georgios Christopoulos <sup>1</sup>

1. Queen Victoria Hospital NHS Foundation Trust, East Grinstead, United Kingdom.

2. Barts Health NHS Trust, London, United Kingdom.

\*: Both authors contributed equally to the manuscript.

## ABSTRACT

**Background:** Soft tissue coverage in the upper limb after trauma, burn injury, or tumour removal is a commonly addressed problem by the plastic surgeon. The anterolateral thigh flap (ALT) is recognized as a popular free flap option for covering various types of soft tissue defects due to its versatility. We aimed to assess the functional and aesthetic outcomes of the ALT flap for reconstruction of upper limb defects.

**Methods:** Four electronic databases were searched (MEDLINE (PubMed), Scopus, Web of Science, and Cochrane) from inception to Feb 2021. Two reviewers independently extracted the data and performed risk assessment using the modified Downs and Black (MDB) quality assessment tool and the modified Newcastle Ottawa Scale for case series.

**Results:** This review included seven studies for quantitative assessment. The eligible studies had 67 patients. Included studies had used a varied number of validated upper extremity functional scoring systems; the most commonly used score was QuickDASH with mean of 21.24, DASH score was 15.5. In regard to aesthetic outcome, an overall satisfactory result was reported. A secondary debulking procedure was performed in 7 patients.

**Conclusion:** Further studies are recommended to ascertain the functional and aesthetic outcomes of the ALT free flap for upper limb defects, especially using standardized outcome scoring systems. This may be supplemented with a questionnaire that addresses common patient concerns (such as colour, contour, texture and hair growth) for the aesthetic outcome. Nevertheless, based on our review, the ALT flap may be a good reliable reconstructive option for upper limb defects with good functional outcome and satisfactory aesthetic results.

**Keywords:** Upper limb reconstruction; Anterolateral thigh; Free flap; Anterolateral thigh flap; Aesthetic outcome

## Please cite this paper as:

Hagiga A, Aly M, Kadhum M, Christopoulos G. Functional and Aesthetic Outcomes of the Anterolateral Thigh Flap in Reconstruction of Upper Limb Defects: A Systematic Review. World J Plast Surg. 2022;11(3):13-22. doi: 10.52547/wjps.11.3.13

## \*Corresponding Author:

Ahmed Hagiga

Queen Victoria Hospital NHS Foundation Trust, East Grinstead, United Kingdom, RH19 3DZ.

Email: [ahmed.tarekhagiga@nhs.net](mailto:ahmed.tarekhagiga@nhs.net)

Received: 2022/07/09

Accepted: 2022/10/27

## INTRODUCTION

Soft tissue coverage in the upper limb after trauma, burn injury, or tumor removal is a commonly addressed problem by the plastic surgeon. In most cases, this is a quite challenging task as the provided soft tissue coverage should be robust and pliable, resulting in the optimal functional and aesthetic outcome <sup>1</sup>. Regional flaps, such as radial forearm and posterior



This work is licensed under a Creative Commons Attribution-NonCommercial 4.0 International license (<https://creativecommons.org/licenses/by-nc/4.0/>). Non-commercial uses of the work are permitted, provided the original work is properly cited.

interosseous, provide an excellent reconstructive option, but the size of the defect usually constrains their use. Other reconstructive options include the pedicled groin flap which may provide coverage for larger defects, however is limited by a longer period of upper limb restriction and post-operative stiffness<sup>2</sup>.

Following the idea of the reconstructive elevator and our continuously growing knowledge on perforator anatomy, free flaps have now become one of the first options for upper limb coverage. More specifically, the anterolateral thigh flap (ALT) is recognized as a popular free flap option for covering various types of soft tissue defects due to its versatility<sup>3</sup>. Moreover, the possible thinning of the ALT flap during the harvest or before the inset has significantly added to its popularity pertaining to further debulking surgery<sup>4</sup>.

The survival rate and complications of the ALT flap have been widely discussed in the literature<sup>5</sup>, however the functional and aesthetic outcomes for upper limb defects specifically have not yet been reviewed. We aimed to evaluate the quality and strength of the evidence for the use of the ALT flap in the upper limb, focusing on the functional and aesthetic outcomes.

## METHODS

### Search Strategy

The protocol for this systematic review has been registered in the PROSPERO database CRD42021239007. Four different databases MEDLINE (PubMed), Scopus, Web of Science, Cochrane Library and Embase, were searched from inception to Feb. 2021 by two independent investigators (A.H and M.A.); The following keywords and Boolean operators were used: (Upper Extremity [Mesh] OR (upper limb) OR (hand) OR (wrist) OR (elbow) OR (arm) OR (forearm)) AND ((Esthetics[Mesh] OR (aesthetic) OR (Function)) AND ((anterolateral thigh) OR (anterolateral free flap)). Additionally, the reference lists of the retrieved publications were checked manually, followed by forward snowballing of all eligible articles using Web of Science and Google Scholar databases.

### Selection and Eligibility

Two independent investigators (A.H and M.A.) judged the eligibility of retrieved articles; first by reading the title, then reading the abstracts, and

finally by reading through the whole article. If disagreement existed, a consensus was reached through discussion. Each article had to satisfy the eligibility criteria to be fully included; we did not exclude any paper based on quality. The inclusion criteria included case series or higher quality evidence, which assess patient-reported outcome measures (PROMS) from patients with anterolateral thigh free flap reconstruction of upper extremity defect. We excluded case reports, review or proof of concept studies, non-English articles or if other flaps were utilized in combination with the ALT flap.

### Data Extraction

Two reviewers independently extracted the following parameters from the selected studies: author names, year of publication, patient demographics including age and gender, anatomical location of the defect, mechanism of injury, associated injuries, flap dimensions, flap survival rate, functional outcome, aesthetic result and follow-up period (Table 1, 2). When data were missing, authors of the included studies were contacted.

### Risk of Bias Assessment

The risk of bias of the included studies was assessed using the Modified Downs and Black (MDB) quality assessment tool for comparative studies. This tool consists of 15 questions that assess four criteria: reporting, internal validity, external validity, and statistical power<sup>6</sup>; each question was scored between 0, 0.5, and 1 with the total summative quality indicating score ranging from 0 to 15. Where results were not applicable (N/A), no score was given. Additionally, the risk of bias for the case series was evaluated using the modified Newcastle Ottawa Scale (NOS)<sup>7,8</sup> based on a pre-defined set of five criteria (selection, ascertainment, causality, and reporting); each criterion was evaluated by a 'Yes' or 'No' response, with the total possible score ranging from 0 to 5. The included study's overall quality was subsequently considered low quality, medium quality or high quality.

## RESULTS

### Search results

Our search strategy identified a total of 487 articles after duplicates were removed. After screening the titles and abstracts of these articles, 462 papers were excluded. Twenty-five studies were deemed eligible

**Table 1:** Study Designs and Patients' Demographics

Study	Number of patients	Mean age (range)	Sex (% Male)	Study design	Exclusion Criteria
Zermeño et al. 2014 <sup>12</sup>	7	12 (2-28)	86%	Case Series	N/A
Ellabban et al 2021 <sup>10</sup>	18	28 (5-45)	78%	Case Series	Patients with severe chronic illnesses and peripheral vascular diseases
Gideroglu et al. 2009 <sup>11</sup>	13	33 (18-55)	85%	Case Series	
di Summa et al., 2019 <sup>9</sup>	7	45 (18-77)	71%	Case Series	N/A
Cherubino et al., 2020 <sup>14</sup>	ALT group:	6	52 (21-82)	Cohort (retrospective)	N/A
	sALT group:	5	55 (24-77)		
Zhang et al., 2019 <sup>13</sup>	7	38 (25-48)	57%	Case Series	Severe chronic illness and those with injury to the donor site were excluded
Lee et al., 2016 <sup>19</sup>	4	51 (42-56)	75%	Case Series	Bone deformity, cases with double-folded fingertip free flaps, lost to follow-up

ALT – anterolateral thigh, N/A – not available, sALT- sandwich anterolateral thigh

for full paper review; 8 were excluded based on the absence of subjective PROMs, 3 were reviews, 2 were case reports and letters, 2 discussed the donor site morbidities only and 3 did not focus on upper extremity patients. As a result, 7 papers remained and were included in our review (Figure 1). All included papers were retrospective studies, and six were case series<sup>9-13</sup>. One study was comparative comparing the standard ALT with a sandwich ALT (sALT) technique<sup>14</sup>.

### Study Population

The eligible studies had 67 participants who underwent ALT flap to cover elbow and elbow defects. The age of patients ranged from 2 to 82 years. There was 50 males (74.6%) and 17 females (25.4%) across the included studies. Trauma or burn injury were the most common mechanism of injury, occurring in 64 patients (96%). Otherwise, defects were also reported post-necrotising fasciitis debridement (1 patient) and oncological surgery (2 patients)<sup>9</sup>. Two studies reported associated injuries in combination with the soft tissue damage<sup>9,13</sup>. The follow up of the included participants ranged from 7 to 72 months (Table 1).

### Evaluation of Functional Outcome

Included studies have used a variable number of validated upper extremity functional scoring systems. The Disabilities of the Arm, Shoulder and Hand (DASH) score consisting of 30 questions scored from 0 to 100<sup>14</sup> was used in 3 studies<sup>10</sup>. The

QuickDASH scoring system, which is a shortened 11-item version of the DASH<sup>15</sup> was used in two studies<sup>10,12</sup>. The reported score had a range from 4.5 to 50 % for 25 patients (mean 21.24)<sup>10,12</sup>, and the DASH score was 15.5 (+/-1.5) for the hand and wrist and 23 (+/-1.4) for the forearm and elbow<sup>9</sup> (Table 2). Chen scoring, which is a four-grade system assessing functionality according to the ability to resume original work, joint motion, sensitivity and muscle power<sup>16</sup> was used in 2 studies<sup>9,11</sup>. Seven patients had Chen II grades, and ten patients had Chen I. Michigan Hand Questionnaire Scoring (MHQ) assesses hands' functionality based on six scales (scored from 0-100, of which 100 is the best possible ability)<sup>17</sup> was used for assessment in only one study<sup>13</sup>. Lastly, the Upper Extremity Functional Scale (UEFS), which consists of 20 items (from zero to 4) with a score range from 0 to 80<sup>18</sup> was also used in one study only<sup>13</sup>. UFES scores resulted in 60.25 (+/-3.8) with standard ALT and 70.75 (+/-3.6) with sALT (Table 2).

### Evaluation of aesthetic Outcome

Two of the included studies reported using the Likert Scale to assess four items: appearance/hair distribution, contour, colour, and texture. Studies compared the outcome with the normal extremity on a scale of 1 (strongly disagree) to 5 (strongly agree) with the panel and patients giving scores<sup>10,12</sup>. The overall score for appearance ranged from 3.11 to 4.1, with a mean score for hair distribution being 3.8, for the contour 3.48, for the colour 3.6 and the texture

Table 2: Primary Outcome Results (Functional and Aesthetic Outcomes)

Study	Anatomical location of the defect	Mechanism of Injury	Flap Dimensions	Complications	Scoring System	Functional Outcome Results	Aesthetic outcome	Follow-up (Months)
Zermeño et al. 2014 <sup>12</sup>	3 Hand, Left 4th Finger 1, forearm and hand 1, 2 distal forearm	Trauma and Burn	Thickness 5 cm (4-6) Mean size (13 x 8.2 cm)	N/A	Aesthetic Outcome: Likert Scale  QuickDASH Score	mean 21.88% (4.5 % - 50% )	mean 15.4 (14-18.8) Appearance 3.60 (3.11-4.1)	11.5 months (7-18)
							Contour 3.85 (3.28-4.42) Colour 3.91 (3.47-4.35) Texture 3.97 (3.62-4.31)	
Ellabban et al 2021 <sup>10</sup>	Elbow 1 m Middle 1/3 of forearm 4, Distal 1/3 number 7, Distal forearm and hand 6)	Acute Trauma 14 Post Traumatic in 4 Patients	Thickness 2.3 cm (1-3.2) After thinning 5mm (4-9mm ) Flap Length 18x9cm	Two partial tip necrosis infection=2 arterial thrombosis salvage=1	Aesthetic Outcome: Likert Scale Other fracture from scale compared from 1-5 with the normal extremity QuickDASH Scale	Mean 21 % (3-41) worst score in dorsal hand and distal forearm  ROM 80% of normal value (30-100), power grip of the reconstructed hand 78% of the normal hand	Mean for the Panel 19.7 (14.6 - 20) Hair Distribution 3.8(1.6-4.4) Contour 3.8 (2.8-4.5) Colour 4.2 (3-4.8) Texture 4.4(3.8-4.8)	12 months
							Mean for the Patient 18.1(13-21) Hair distribution 3.5(1.5-3.9) Contour 3.4(2.5-4.3) Colour 3.5(3-3.8) Texture 4(3-4.5)	
Gideroglu et al. 2009 <sup>11</sup>	Hand 6 Forearm 7	Trauma 9 Burn 1 Tumour Excision 2 Unstable scar excision 1	11x16 cm	Two marginal necrosis	Chen Classification	Chen I = 6 patients Chen II = 5 patients Chen III = 2	Acceptable 12 patients	44 months (22-72 months)
di Summa et al., 2019 <sup>9</sup>	Forearm/elbow 4 Hand/Wrist 3	Tumour Resection 2 Trauma 2 Burn 2	16x9 cm	-	ROM a goniometer Muscle strength scored M0-M5 Visual	Chen I = 4 Chen II = 3 Hand/Wrist DASH score 15.5+/-1.5 Forearm/elbow DASH score 23+/-1.4	-  39.4(12-75)	

Continued Table 2: Primary Outcome Results (Functional and Aesthetic Outcomes)

Study	Anatomical location of the defect	Mechanism of Injury	Flap Dimensions	Complications	Scoring System	Functional Outcome Results	Aesthetic outcome	Follow-up (Months)
		Necrotizing Fasciitis 1			Analogue Scale DASH	ROM degree loss in Hand/wrist compared to unaffected side 37+/-4 ROM degree loss in Forearm/elbow compared to unaffected side 5+/-5		
						ROM		
						Hand/Wrist : MCP 85 , PIP (0-90) , DP (0-30) , mean loss 37% (33-45%).		
						Forearm/elbow mean ROM 116 (minimum 100 , maximum 125) mean loss 5%		
			ALT Flap 13.1 cm x 7.1 cm (Range 9-18x6-8 cm)				Overall Aesthetic satisfaction to the patient for SALT group.	over 12 months
			Mean SALT Group					
			14.1 cmx7.8cm(15.5-12.5 x 5.5-12 cm)	3 infections in ALT Group	UEFS (Upper extremity functional scale)	UEFS ALT Group 60.25+/-3.8		
		Trauma/Burn	Thickness ALT Group 2-3.8cm			UEFS SALT Group 70.75+/-3.6	3 patients in ALT group required a secondary debulking procedure	
			SALT Group 1.1-2.4 cm					
			ALT ranged from 7-18 x 4-18 cm	-	MHQ Score for function	MHQ 37.8 (31.5-59.6)	-	11.1 months (6-15)
		Burn 1 Trauma 6						
			ALT 5x 9.2 cm ranged from 4-8 cm) x (7-12 cm)	hyperpigmentation	Aesthetic satisfaction questionnaire	-	Percentile range= 53% - 84% Mean = 66.5%	minimum 1.5 years
		Trauma						

ALT- anterolateral thigh free flap,DASH- The disabilities of the arm, shoulder and hand, DP- distal phalanx, MCP- metacarpophalangeal, MHQ- Michigan Hand Outcomes Questionnaire, ROM- Range of motion, UEFS the Upper Extremity Functional Scale

Figure 1 PRISMA Flowchart

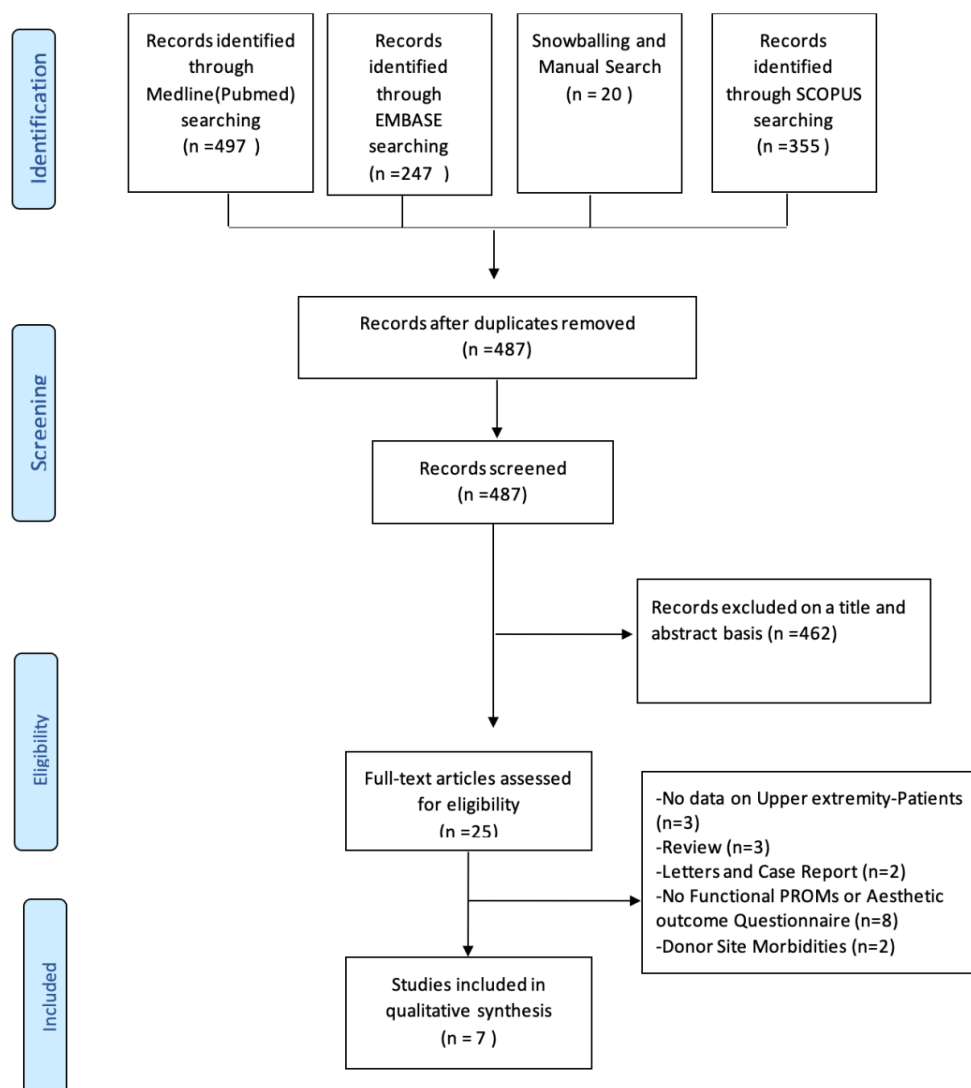


Figure 1: PRISMA Flowchart

3.9. One study reported aesthetic satisfaction based on eight questions produced by the Michigan Hand Outcome Questionnaire (MHQ) with an overall score from 0 to 100% satisfaction. The overall results were 53%-84%, with a mean of 66.5%<sup>19</sup>. Other included studies have reported overall satisfaction with the results (Table 2).

#### Estimation of secondary outcomes and complications

The range of motion was assessed in two studies<sup>9, 10</sup>. The combined mean loss of normal range of motion (ROM) for the metacarpophalangeal joint was 34.3%, for the elbow was 5%<sup>9</sup>, and for the wrist was 21%. The mean power grip of the reconstructed hand was estimated at 78% of the normal<sup>10</sup>.

One study evaluated the sensory function post-reconstruction, reporting a S2 grade recovery (partial recovery from superficial pain and tactile sensitivity)<sup>13, 20</sup>. Two studies reported that all their participants who had a sensate flap reconstruction had regained sensitivity<sup>11, 12</sup>; the 2-point discrimination was 10mm in the proximal part and 12mm in the distal part of the flap<sup>12</sup>. In the non-innervated flap, the 2-point discrimination was reported as 48.3mm (40-55 mm)<sup>9</sup>. Temperature was regained by 85%<sup>12</sup> (Table 3).

A secondary debulking procedure was performed in 7 patients<sup>13, 14</sup>. Overall, there was no complete flap failure. 4 flaps had partial marginal necrosis<sup>10, 11</sup>, five infections<sup>10, 14</sup>, and one flap had arterial

**Table 3:** Secondary Outcomes

Study	Innervated ALT Flap	Sensory outcome	Debulking Procedure
Zermeño et al. 2014 <sup>12</sup>	Yes	Pain and Touch Present 100% Temperatures 85% 2PP = Proximal 8.57 mm (8-20), Distal 9.71mm (8-20)	Same 1ry Procedure
Ellabban et al 2021 <sup>10</sup>	No	N/A	Same 1ry Procedure
Gideroğlu et al. 2009 <sup>11</sup>	Five patients	Protective Sensibility in all flaps with 12 months	N/A
di Summa et al., 2019 <sup>9</sup>	No	Forearm/elbow 2 Point Discrimination = 3.5cm HaWristsit Group = 5 cm	N/A
Zhang et al., 2019 <sup>13</sup>	No	Pain score 32.9+/-23.4 points Sensation was S2	Secondary debulking in 4 cases

**Table 4:** Modified Downs and Black quality assessment scores for included studies

Study	Number of the question															Total
	Reporting										External Validity	Internal Validity		Power		
												Bias	Confounding			
Cherubino et al., 2020 <sup>14</sup>	1	2	3	4	5	6	7	8	9	10	11	12	13	14	15	15
	1	1	0	1	1	NA	1	1	1	1	1	1	1	0*	0	11

0: No or UTD\*, 1: Yes

**Table 5:** Assessment tool for included Case series

Domain	Queries	Zermeño et al. 2014 <sup>12</sup>	Ellabban et al 2021 <sup>10</sup>	Gideroglu et al. 2009 <sup>11</sup>	di Summa et al., 2019 <sup>9</sup>	Zhang et al., 2019 <sup>13</sup>	Lee et al., 2016 <sup>19</sup>
Selection	Patients' resemblance to real clinical setting						
	Clear selection method to avoid inappropriate exclusion	0	1	0	0	1	1
Ascertainment	Ascertainment of exposure	1	1	1	1	1	1
	Ascertainment of outcome measures	1	1	1	1	1	1
Causality	Adequacy of follow-up period	1	1	1	1	1	1
	Sufficient description of patient's population						
Reporting	to permit research replication and to improve external validity (or applicability)	0	1	0	0	1	1

thrombosis and was salvaged<sup>10</sup>. Hyperpigmentation was reported in one patient<sup>19</sup> (Table 3).

### Risk of Bias

Based on MDB scoring system (Table 4), one study<sup>14</sup> scored 11 out of 15 and was deemed of good

methodological quality. This study, however, did not report its sample size calculations, exclusion criteria for study participants and did not mention follow-up losses. Six studies<sup>9-13, 19</sup> were case series. Three studies scored 3 out of 5 at the NOS (Table 5) for not reporting exclusion criteria of the participants,



which affected the score for reporting and selection domains<sup>9, 11, 12</sup> indicating a medium quality. Two studies score 5 out of 5, indicating a high quality<sup>10, 19</sup>. The overall median quality is four.

## DISCUSSION

Upper extremity reconstruction is challenging. The optimal flap should meet certain requirements like pliability, durability, minimal donor-site morbidity, good vessel match, and avoidance of intraoperative change in the patient's position<sup>25</sup>. The ALT flap is a septocutaneous or musculocutaneous flap based on perforators of the descending branch of the lateral circumflex femoral artery, firstly described by Song et al. in 1984<sup>21</sup>. It is considered one of the most popular flaps with benefits including versatility, a long pedicle, and low donor site morbidity<sup>22, 23</sup>. The ALT free flap has been utilized in reconstruction across the whole body, including the head and neck, abdominal wall, extremities, and breast<sup>24-27</sup>. A recent systematic review has shown that it is gradually becoming the workhorse for upper limb soft tissue<sup>5</sup>.

### *Evaluation of the outcome with an ALT flap reconstruction*

Several studies have been conducted in an attempt to evaluate the ALT flap usage for upper limb reconstruction. Studies that compare surgeons and patient's aesthetic outcome showed that surgeons scored better than the patients<sup>10, 12</sup> which is rather expected as the latter have higher expectations based on the pre-injured extremity appearance.

Regarding the functional outcomes, QucikDASH revealed better results in the forearm compared to the hand (combined forearm = 18.1, distal forearm, hand and wrist = 31.98%)<sup>12</sup>. This result was reaffirmed by the study of di Summa et al.<sup>9</sup> with the DASH score being better in the forearm than the wrist. These studies validate the logical conception that forearm defects are generally more suitable for the ALT's elliptical skin paddle. The functional results are significant when the wrist joint or the hand is spared. Moreover, patients with delayed reconstruction experienced better post-operative results having the opportunity to adapt to the injury, in contrast to an early reconstruction<sup>12</sup>.

Ellabban et al.<sup>10</sup> included 18 patients and concluded that the worst functional outcomes were witnessed in patients with dorsal hand and distal forearm ALT

flaps. Gideroğlu et al.<sup>9</sup> included 13 cases between 2002 and 2007 for which an ALT was used to cover hand and wrist defects providing a good outcome. One study<sup>28</sup> has met the primary inclusion criteria. However, the sample included in this study were patients who underwent hand or foot reconstruction with an ALT flap. After reviewing the full paper text, hand and foot outcome data were not discrete. Thus, out of the reviews' definitive inclusion scope. Authors have been contacted to provide separate information for hand patients; however, no response obtained. That being said, there was an overall good satisfaction and functional outcome noted in the study in both feet and hand ALT flaps.

Regarding the donor site, a pooled meta-analysis concluded that morbidity for thigh-flaps is minimal and appears to be well tolerated by the majority of patients<sup>29</sup>. Donor site selection is an essential factor in flap choice influenced by the patient's preference and surgeon's experience. Nevertheless, it is highly individualised, and patients must be informed of potential complications and morbidities specific to each flap during the consultation. Wang et al.<sup>30</sup> described that closure of the donor site is always performed over a drain. Defects up to 22 cm in length and 8 cm in width can usually be closed primarily. However, larger defects may require a skin graft compromising the final aesthetic outcome.

### *Evaluation of ALT flap reconstruction technique*

Some surgeons prefer to incise the distal part lateral to the anterolateral intermuscular septum and to dissect the tissue medially, which facilitated the identification of the perforator because it provided full exposure with no tension of the severed covering skin or fascia lata<sup>31</sup>. In 2008, Adler et al.<sup>32</sup> published a different medial incision starting technique for harvesting complex lateral femoral circumflex chimeric free tissue transfers. However, a study concluded that medial incision is more efficient than starting with a lateral incision<sup>33</sup>.

Generally, flap raising is influenced by thigh thickness and adiposity. The classic harvesting technique for the ALT flap is based on anatomic markers. It involves an open surgical procedure in which perforators are identified intra-operatively without a prior systematic investigation<sup>33</sup>. Thinning of the flap was initially described by Kimura et al.<sup>34</sup> after a clear understanding of the perforasome concepts<sup>35</sup>. This study involved 31 patients for six



years; there were variations in width and length, but the average was 7.7 by 14.7 cm to preserve flap vascularity and survival. Ultrathin flap's thickness was determined around 6mm. Maruccia et al.<sup>28</sup> compared super-thin with the conventional ALT flaps reporting that a thin flap with a suprafascial dissection could be performed safely without compromising flap outcome or survival.

### Limitations

There were no comparative studies in our review. On the other hand, the inclusion of case series may increase the risk of survivorship bias. Additionally, due to heterogeneity of the functional outcome and aesthetic outcome scoring system and no comparison group, a meta-analysis was not conducted. Different scoring systems were used to assess function, and only three studies addressed the aesthetic outcome with a questionnaire. However, other studies reported overall satisfaction aesthetic results by the patients. Also, some studies included children, making the functional assessment more difficult<sup>10, 12</sup>. Finally, the complexity of the injury varied in the study population, with some patients having an underlying tendon or bone injury, which may have affected the overall functional outcome.

### CONCLUSION

Further studies are recommended to ascertain the functional and aesthetic outcomes of the ALT free flap for upper limb defects, especially using standardized outcome scoring systems. This may be supplemented with a questionnaire that addresses common patient concerns (such as color, contour, textile and hair growth) for the aesthetic outcome. Nevertheless, based on our review, the ALT flap may be a good reliable reconstructive option for upper limb defects with good functional outcome and satisfactory aesthetic results.

### FUNDING

The author(s) received no financial support for the research, authorship, and/or publication of this article.

### CONFLICT OF INTEREST

The authors declare that there is no conflict of interest.

### REFERENCES

1. Levin LS, Erdmann D. Primary and secondary microvascular reconstruction of the upper extremity. *Hand Clin* 2001 Aug;**17**(3):447-55, ix.
2. Yildirim S, Taylan G, Eker G, Akoz T. Free flap choice for soft tissue reconstruction of the severely damaged upper extremity. *J Reconstr Microsurg* 2006 Nov;**22**(8):599-609.
3. Graboyes EM, Hornig JD. Evolution of the anterolateral thigh free flap. *Curr Opin Otolaryngol Head Neck Surg* 2017 Oct;**25**(5):416-21.
4. Adani R, Tarallo L, Marcoccio I, Cipriani R, Gelati C, Innocenti M. Hand reconstruction using the thin anterolateral thigh flap. *Plast Reconstr Surg* 2005 Aug;**116**(2):467-73; discussion 74-7.
5. Zhang Y, Gazyakan E, Bigdeli AK, Will-Marks P, Kneser U, Hirche C. Soft tissue free flap for reconstruction of upper extremities: A meta-analysis on outcome and safety. *Microsurgery* 2019 Jul;**39**(5):463-75.
6. Downs SH, Black N. The feasibility of creating a checklist for the assessment of the methodological quality both of randomised and non-randomised studies of health care interventions. *J Epidemiol Community Health* 1998 Jun;**52**(6):377-84.
7. Wells G SB, O'connell D, Peterson J, Welch V, Losos M, Tugwell P (2016) The Newcastle-Ottawa Scale (NOS) for assessing the quality of nonrandomised studies in meta-analyses. Ottawa Hospital Research Institute, Ottawa 2009. Available in March.
8. Murad MH, Sultan S, Haffar S, Bazerbachi F. Methodological quality and synthesis of case series and case reports. *BMJ Evid Based Med* 2018 Apr;**23**(2):60-3.
9. diSumma PG, Sapino G, Durand S, et al. Reconstruction of complex soft tissue defects including tendons with anterolateral thigh flap extended to fascia lata: Long term recovery and functional outcomes. *Microsurgery* 2019 Jul 2019;**39**(5):405-15.
10. Ellabban MA, Gomaa AA, Moghazy AM, Elbadawy MA, Adly OA. Aesthetic and functional outcomes of thinned anterolateral thigh flap in reconstruction of complex wounds of the upper limb. *The Journal of hand surgery, European volume* 2021 Feb 2021;1753193421989603.
11. Gideroglu K, Cakici H, Yildirim S, Yazar S, Akoz T. Functional reconstruction in large and complex soft tissue defects of forearm and hand with multifunctional anterolateral thigh flap. *Eklem hastaliklari ve cerrahisi = Joint diseases & related surgery* 2009;**20**(3):149-55.
12. Torres-Ortiz Zermeno CA, López Mendoza J. Aesthetic and functional outcomes of the innervated and thinned anterolateral thigh flap in reconstruction of upper limb defects. *Plastic surgery international* 2014;**2014**:489012.
13. Zhang G, Su H, Ju J, Li X, Hou R, Fu Y. Reconstruction

- of dorsal and palmar defects of hand with anterolateral thigh flaps from one donor site. *Journal of Plastic, Reconstructive and Aesthetic Surgery* 2019 Dec 2019;**72**(12):1917-22.
14. Cherubino M, Stocco C, Ronga M, et al. Comparisons of fascio-cutaneous anterolateral thigh and sandwich fascial ALT free flap in the distal extremity reconstruction. *Microsurgery* 2020 May 2020;**40**(4):452-9.
  15. Beaton DE, Wright JG, Katz JN, Upper Extremity Collaborative G. Development of the QuickDASH: comparison of three item-reduction approaches. *J Bone Joint Surg Am* 2005 May;**87**(5):1038-46.
  16. Zhong-Wei C, Meyer VE, Kleinert HE, Beasley RW. Present indications and contraindications for replantation as reflected by long-term functional results. *Orthop Clin North Am* 1981 Oct;**12**(4):849-70.
  17. Chung KC, Pillsbury MS, Walters MR, Hayward RA. Reliability and validity testing of the Michigan Hand Outcomes Questionnaire. *J Hand Surg Am* 1998 Jul;**23**(4):575-87.
  18. stratford P.W. BJM, Stratford D. Development and initial validation of the Upper Extremity Functional Index. *Physiother Can* 2001; 52 (281): 259-267.
  19. Lee MG, Kim JS, Lee DC, Roh SY, Lee KJ, Choi BK. Fascial Free Flap for Reconstruction of the Dorsolateral Hand and Digits: The Advantage of a Thin Contour. *Archives of plastic surgery* 2016 Nov 2016;**43**(6):551-8.
  20. Yu YD, Zhang YZ, Bi WD, Wu T. Functional sensory function recovery of random-pattern abdominal skin flap in the repair of fingertip skin defects. *Exp Ther Med* 2013 Mar;**5**(3):830-4.
  21. Song YG, Chen GZ, Song YL. The free thigh flap: a new free flap concept based on the septocutaneous artery. *Br J Plast Surg* 1984 Apr;**37**(2):149-59.
  22. Pappalardo M, Jeng SF, Sadigh PL, Shih HS. Versatility of the Free Anterolateral Thigh Flap in the Reconstruction of Large Defects of the Weight-Bearing Foot: A Single-Center Experience with 20 Consecutive Cases. *J Reconstr Microsurg* 2016 Sep;**32**(7):562-70.
  23. Park JE, Rodriguez ED, Bluebond-Langer R, et al. The anterolateral thigh flap is highly effective for reconstruction of complex lower extremity trauma. *J Trauma* 2007 Jan;**62**(1):162-5.
  24. Kaplan JL, Allen RJ, Guerra A, Sullivan SK. Anterolateral thigh flap for breast reconstruction: review of the literature and case reports. *J Reconstr Microsurg* 2003 Feb;**19**(2):63-8.
  25. Kimata Y, Uchiyama K, Sekido M, et al. Anterolateral thigh flap for abdominal wall reconstruction. *Plast Reconstr Surg* 1999 Apr;**103**(4):1191-7.
  26. Koshima I, Fukuda H, Yamamoto H, Moriguchi T, Soeda S, Ohta S. Free anterolateral thigh flaps for reconstruction of head and neck defects. *Plast Reconstr Surg* 1993 Sep;**92**(3):421-8; discussion 9-30.
  27. Pribaz JJ, Orgill DP, Epstein MD, Sampson CE, Hergrueter CA. Anterolateral thigh free flap. *Ann Plast Surg* 1995 Jun;**34**(6):585-92.
  28. Maruccia M, Fallico N, Cigna E, et al. Suprafascial versus traditional harvesting technique for free antero lateral thigh flap: A case-control study to assess the best functional and aesthetic result in extremity reconstruction. *Microsurgery* 2017 Nov;**37**(8):851-7.
  29. Lakhiani C, DeFazio MV, Han K, Falola R, Evans K. Donor-Site Morbidity Following Free Tissue Harvest from the Thigh: A Systematic Review and Pooled Analysis of Complications. *J Reconstr Microsurg* 2016 Jun;**32**(5):342-57.
  30. Wang HT, Erdmann D, Fletcher JW, Levin LS. Anterolateral thigh flap technique in hand and upper extremity reconstruction. *Tech Hand Up Extrem Surg* 2004 Dec;**8**(4):257-61.
  31. Lin PY, Chen CC, Kuo YR, Jeng SF. Simultaneous reconstruction of head and neck defects following tumor resection and trismus release with a single anterolateral thigh donor site utilizing a lateral approach to flap harvest. *Microsurgery* 2012 May;**32**(4):289-95.
  32. Adler N, Dorafshar AH, Agarwal JP, Gottlieb LJ. Harvesting the lateral femoral circumflex chimera free flap: guidelines for elevation. *Plast Reconstr Surg* 2009 Mar;**123**(3):918-25.
  33. Xie RG. Medial versus lateral approach to harvesting of anterolateral thigh flap. *J Int Med Res* 2018 Nov;**46**(11):4569-77.
  34. Kimura N, Satoh K, Hasumi T, Ostuka T. Clinical application of the free thin anterolateral thigh flap in 31 consecutive patients. *Plast Reconstr Surg* 2001 Oct;**108**(5):1197-208; discussion 209-10.
  35. Taylor GI. The angiosomes of the body and their supply to perforator flaps. *Clin Plast Surg* 2003 Jul;**30**(3):331-42, v.